

Case Report

Concurrent Index-to-Little Finger Dorsal Dislocations of the Carpometacarpal Joints with Carpal Bone Fractures

Abstract

A 32-year-old man presented with simultaneous dorsal dislocations of the index-to-little finger carpometacarpal (CMC) joint with carpal bone fractures. Closed reduction was unsuccessful even after general anesthesia. During open dorsal approach, we found interposed joint capsule in the CMC joints and after removal of the joint capsule open reduction was easily achieved. We placed four Kirschner wires through the CMC joint. Furthermore, the fractured dorsal fragments of the trapezoid and hamate were fixed with mini screw in each. During 1-year followup, the patient showed good recovery and no evidence of posttraumatic arthritic changes in plain X-ray. We recommend to fix the dorsal fragment of the carpal bone with screws as well as the transarticular fixation of the CMC joint in case of concurrent CMC joint fracture-dislocation of all four fingers.

Keywords: Carpometacarpal joint, carpometacarpal joint fracture-dislocation, hamate fracture, trapezoid fracture

**Ki-Tae Na,
Sang-Uk Lee,
Sun-Young Joo,
Jin-Young Nho**

*Department of Orthopedic
Surgery, Incheon St. Mary's
Hospital, The Catholic
University of Korea, Incheon,
Korea*

Introduction

The carpometacarpal (CMC) joints articulate the carpal bones with the phalanges and constitute the carpal arch in the palm. Unlike the ulnar-side (ring and little fingers) CMC joints, the radial-side (index and middle fingers) CMC joints are well stabilized by interlocked bony and strong ligamentous structures. Fracture dislocation of the radial-side CMC joints is rare because of this inherited stability. Radial-side injuries result in worse outcomes than ulnar-side injuries.¹

A few studies have reported clinical and radiographic outcomes of concurrent index-to-little finger CMC fracture-dislocations.²⁻⁵ Here, we present a 32-year-old man with concurrent index-to-little finger CMC dislocation with fractures of the trapezoid and hamate.

Case Report

A 32-year-old man injured his dominant right hand by striking a punching bag machine with a clenched fist. Clinical examination revealed that his right hand was markedly deformed and swollen. The range of motion was limited due to pain. He had small bulla formation on the

dorsal aspect of the hand. There was no neurovascular deficit.

Plain radiography and computed tomography revealed dorsal dislocations of the index, middle, ring, and little fingers at the CMC joints and simultaneous fractures of the dorsal aspect of the trapezoid and hamate [Figure 1]. An initial attempt of closed reduction under conscious sedation in the emergency room was unsuccessful.

The surgery was performed through the dorsal aspect of carpus in a zigzag fashion from proximal part of the wrist to the middle part of the metacarpal bone. An interposed dorsal joint capsule in the CMC joints was found which might prevent the initial closed reduction of these joints. After removing the interposed joint capsule, CMC joint reduction was easily achieved under fluoroscopy.

However, we could not achieve stable reduction without fixation. The Kirschner wire fixation was performed while the CMC joints reduced. Under fluoroscopic vision, the first Kirschner wire was inserted retrograde from the base of the fifth metacarpal bone to the hamate. The second Kirschner wire was inserted antegrade from the hamate to the fourth metacarpal bone. The third Kirschner wire was inserted antegrade from the trapezoid toward the

Address for correspondence:

*Dr. Sang-Uk Lee,
Department of Orthopedic
Surgery, Incheon St. Mary's
Hospital, The Catholic
University of Korea, 56
Dongsu-Ro, Bupyeong-Gu,
Incheon 21431, South Korea.
E-mail: self-m@hanmail.net*

This is an open access journal, and articles are distributed under the terms of the Creative Commons Attribution-NonCommercial-ShareAlike 4.0 License, which allows others to remix, tweak, and build upon the work non-commercially, as long as appropriate credit is given and the new creations are licensed under the identical terms.

For reprints contact: reprints@medknow.com

How to cite this article: Na KT, Lee SU, Joo SY, Nho JY. Concurrent index-to-little finger dorsal dislocations of the carpometacarpal joints with carpal bone fractures. *Indian J Orthop* 2019;53:374-6.

Access this article online

Website: www.ijonline.com

DOI:
10.4103/ortho.IJOrtho_550_17

Quick Response Code:



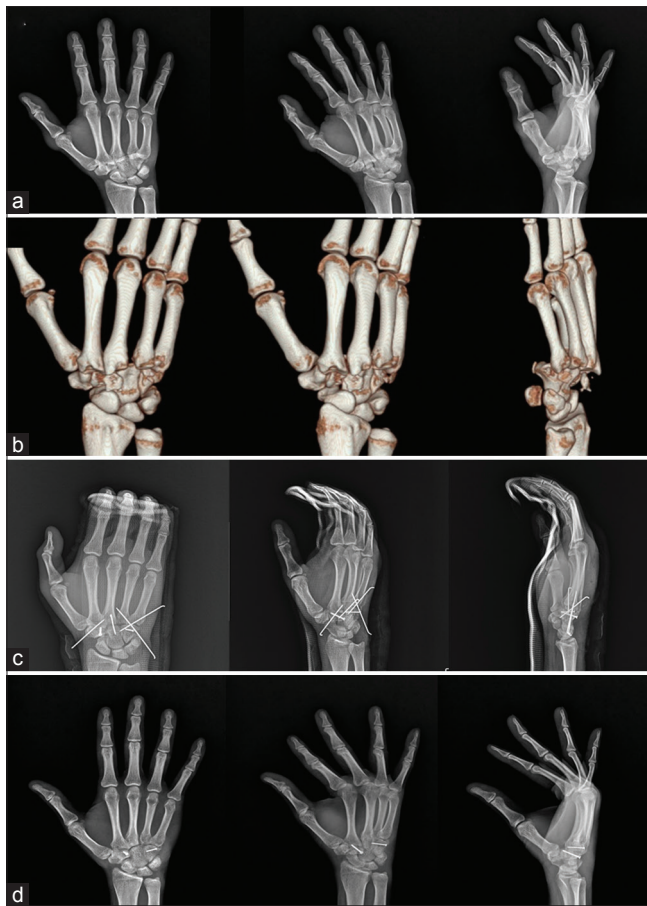


Figure 1: (a) Plain radiography showing concurrent carpometacarpal joint dislocation and fracture of the trapezoid and hamate; (b) Preoperative three-dimensional computed tomography images; (c) Postoperative radiography showing well-reduced carpometacarpal joints; (d) Plain radiography at 1-year followup

second metacarpal bone. The fourth Kirschner wire was inserted retrograde from the third metacarpal bone to the capitate. Finally, dorsal fractures of the trapezoid and hamate bone were reduced and each fracture was fixed with a mini screw (1.5-mm cortical screw, Synthes, West Chester, PA, USA).

After bony fixation, the ruptured dorsal capsule and ligaments of the CMC joint were repaired with absorbable sutures. Postoperatively, the patient remained in a volar above elbow splint in the neutral position for 2 weeks, followed by a below elbow cast for 4 weeks. The Kirschner wires were removed 6 weeks after the operation. Gentle passive range of motion exercise and isometric grip-strengthening exercise were started immediately after the Kirschner wire removal.

The patient had full range of motion in the fingers and wrist with minimal pain 3 months postoperatively. Grip strength (81% of unaffected hand) and pinch strength (85% of unaffected hand) were slightly lower than that of the unaffected hand. He returned to sport activities 6 months postoperatively. One year after the operation,

plain radiography showed a well-preserved “tram-line” and no evidence of posttraumatic arthritic changes. The patient and his family were informed that data from the case would be submitted for publication and they gave their consent.

Discussion

Physicians often encounter ring-and-little finger CMC fracture-dislocations in outpatient clinics or emergency rooms. However, CMC joint fracture-dislocations of the index-to-small finger are rare.⁶ The radial-side CMC joints are more anatomically stable and less vulnerable to injury than the ulnar-side CMC joints due to the interlocking saddle joint structure and strong ligamentous support.

The most common cause of concurrent index-to-small finger dislocations is motor vehicle accident.² Other causes were high-energy trauma, such as run over the car tire, fall from a height with knuckles of clenched fist, and punched the wall with a clenched fist.² In the current study, the patient struck a punching bag machine with a clenched fist. It is a quite rare mechanism for concurrent CMC fracture-dislocation injury. Unlike the conventional punching bag machine, which has no hard parts, the current punching bag machine has a metal pedestal behind the punching area. The patient hit this metal pedestal part by mistake.

According to a previous case report, a 34-year-old female had simultaneous volar radial dislocation of the second, third, fourth, and fifth CMC joints as the tire run over her hand. After adequate wrist block, reduction was obtained by application of longitudinal traction with concomitant pressure over the palmar and radial base of the index, middle, ring, and little metacarpals. After 3 weeks of keeping the splint in a neutral posture, the patient was then started on range-of-motion physical therapy and regained full range of motion with good wrist alignment on radiographic study.⁴

In most other studies, however, closed reduction failed because of severe swelling and interposed soft tissue within the dislocated joints.^{3,5} Peace and Abrams⁵ reported simultaneous dorsal dislocations of the CMC joints of all four fingers. He failed to achieve congruent reduction even after general anesthesia. During the open approach, he found an interposed joint capsule in the CMC joints of the long and index fingers. A total of four Kirschner wires were placed through the base of metacarpal to carpus, but avulsion fracture of capitate was not addressed.

This injury is often accompanied by extensive ligamentous injuries. Due to this extensive ligamentous injury, it is difficult to keep the reduction stable.² Thus, restoring and maintaining the dislocated CMC joint are required in many cases.⁶ However, previous studies have focused on transarticular Kirschner wire fixations and have overlooked the importance of fixing the dorsal fragment of the carpal bones.^{2,3,5} It is widely accepted that a fractured hamate should be fixed with Kirschner wires or screws in ring-

and-little finger CMC fracture-dislocation to prevent redislocation of the CMC joint.⁷ It is also important to reduce and fix the dorsal fragment of the trapezoid and hamate bones in case of concurrent index-to-little finger CMC fracture dislocations.

Concurrent index-to-little finger CMC fracture-dislocations are a rare injury. In addition to the transarticular fixation of the dislocated CMC joint, fixing the fractured carpal bones results in more stable reduction. More stable CMC joint can prevent redislocation, eventually reducing the risk of posttraumatic arthritis. We recommend fixing the dorsal fragment of the carpal bone with screws to improve the stability of the CMC joint.

Declaration of the patient consent

The authors certify that they have obtained all appropriate patient consent forms. In the form, the patient has given his consent for his images and other clinical information to be reported in the journal. The patient understand that his name and initial will not be published and due efforts will be made to conceal their identity, but anonymity cannot be guaranteed.

Financial support and sponsorship

Nil.

Conflicts of interest

There are no conflicts of interest.

References

1. Lawlis JF 3rd, Gunther SF. Carpometacarpal dislocations. Long term followup. *J Bone Joint Surg Am* 1991;73:52-9.
2. Prokuski LJ, Eglseder WA Jr. Concurrent dorsal dislocations and fracture-dislocations of the index, long, ring, and small (second to fifth) carpometacarpal joints. *J Orthop Trauma* 2001;15:549-54.
3. Sharma AK, John JT. Unusual case of carpometacarpal dislocation of all the four fingers of ulnar side of hand. *Med J Armed Forces India* 2005;61:188-9.
4. Slesarenko YA, Wang ED, Most MJ. Simultaneous dislocations of the carpometacarpal joints: A case report. *Hand Surg* 2005;10:275-7.
5. Peace WJ, Abrams RA. Simultaneous dorsal dislocations of the carpometacarpal joints of all four fingers. *Orthopedics* 2010;33:121-3.
6. Büren C, Gehrman S, Kaufmann R, Windolf J, Lögters T. Management algorithm for index through small finger carpometacarpal fracture dislocations. *Eur J Trauma Emerg Surg* 2016;42:37-42.
7. Cain JE Jr., Shepler TR, Wilson MR. Hamatometacarpal fracture-dislocation: Classification and treatment. *J Hand Surg Am* 1987;12:762-7.