

## Possible Vascular Injury Due to Screw Eccentricity in Minimally Invasive Total Hip Arthroplasty

### Abstract

**Background:** Vascular injury during minimally invasive total hip arthroplasty (THA) is uncommon, yet a well-recognized and serious issue. It emerges because of non-visibility of vascular structures proximal to the pelvic bone during reaming, drilling holes, and fixing of screws. Numerous studies have found that screw fixation during cementless THA is beneficial for the initial stability of cup; yet, no anatomical guidelines support angular eccentric screw fixation. **Materials and Methods:** In this study, we obtained the pelvic arterial-phase computed tomographic data of thirty eight humans and reconstructed the three-dimensional models of osseous and vessel structures. We performed the surgical simulation to fix these structures with cementless cups and screws with angular eccentricities. **Results:** The effect of screw eccentricities (angular eccentricities of  $\pm 17^\circ$  and  $\pm 34^\circ$ ) on the vascular injury was determined. Measurement between screw and adjoining vessels was performed and analyzed statistically to ascertain a comparative risk study for blood vessels that are not visible during surgery. **Conclusion:** Authors similarly discussed the significant absence of appreciation of quadrant systems proposed by Wasielewski *et al.* on eccentric screws. Adjustment of quadrant systems provided by Wasielewski *et al.* is required for acetabular implants with eccentric holes for fixation of acetabular screws.

**Keywords:** Acetabular cup, eccentricity, minimally invasive total hip arthroplasty, screw fixation, vessel injury

**MeSH terms:** Replacement, arthroplasty, hip, bone screws, acetabulum

**Nishant Kumar Singh,  
Sanjay Kumar Rai,  
Amit Rastogi<sup>1</sup>**

*School of Biomedical Engineering, Indian Institute of Technology (Banaras Hindu University), <sup>1</sup>Department of Orthopaedics, Institute of Medical Sciences, Banaras Hindu University, Varanasi, Uttar Pradesh, India*

### Introduction

Incidence of minimally invasive total hip arthroplasty (MI-THA) has been increasing for the past 25 years in orthopedics as a result of the rapid upgrade of materials and instrumentation.<sup>1,2</sup> During MI-THA, laceration of major blood vessels during fixation of the screw has been reported.<sup>3-8</sup> However, fixation of the screw is a critical procedure: Correct alignment of a sized screw placed in the right direction and position will avoid vascular injury.<sup>8,9</sup>

In recent years, manufacturers are providing the eccentric hole on cup (up to  $34^\circ$ ); screw fixation into this could result in vascular injury abiding the anatomical guidelines proposed by Wasielewski *et al.*<sup>9</sup>

Therefore, the goal of this study is to obtain spatial information of angular screw eccentricity that affects the vascular structure's proximity to pelvis bone and possible angular screw eccentricity which is tolerable and for due consideration.

This is an open access article distributed under the terms of the Creative Commons Attribution-NonCommercial-ShareAlike 3.0 License, which allows others to remix, tweak, and build upon the work non-commercially, as long as the author is credited and the new creations are licensed under the identical terms.

For reprints contact: [reprints@medknow.com](mailto:reprints@medknow.com)

### Materials and Methods

#### Data acquisition

For our study, we obtained the angiographic computed tomography (CT) image pelvic data of thirty eight patients (24 men, 14 women) from the Radio Diagnosis and Imaging department of our institute. The informed consent was obtained from all patients. All patients were scanned with a 64-slice spiral CT scanner (GE Medical Systems, USA), and 80 ml of omnipaque iohexol was injected intravenously by a high pressure injector through the cubital vein as a contrast medium. Scanning conditions were predefined as follows: 120 kV, 270 mA, 0.625 mm slice thickness with 1 mm spacing, scanned region: third lumbar vertebra to mid of femur bone and subsequent reconstruction distance of 1 mm. The reconstructed data were stored in .dicom format.

#### Three-dimensional model reconstruction

Volumetric data were transferred to medical imaging and editing software Mimics 18.0

**How to cite this article:** Singh NK, Rai SK, Rastogi A. Possible vascular injury due to screw eccentricity in minimally invasive total hip arthroplasty. *Indian J Orthop* 2017;51:447-54.

#### Address for correspondence:

*Dr. Sanjay Kumar Rai,  
School of Biomedical Engineering, Indian Institute of Technology, Banaras Hindu University, Varanasi, Uttar Pradesh, India.  
E-mail: [skrai.bme@iitbhu.ac.in](mailto:skrai.bme@iitbhu.ac.in)*

#### Access this article online

Website: [www.ijoonline.com](http://www.ijoonline.com)

DOI:  
10.4103/ortho.IJOrtho\_224\_16

#### Quick Response Code:



(Materialise, Leuven, Belgium) to reconstruct the three-dimensional (3D) model of pelvis and vessels. Semi-automatic segmentation algorithm applied in conjunction with a region-growing algorithm was used to interpolate the 2D dicom image data, resulting in generation of 3D models.<sup>10</sup> Creation of rectangular patches, smoothing and filling holes on the generated 3D models were done in 3-Matic 9.0 (Materialise, Leuven, Belgium) module and stored in STEP format.

The arteries, veins, and osseous structures were easily distinguished and consequently rendered with red, blue, and light grayish orange [Figure 1]. The common iliac vein and their associated branches (adjacent and posterior to the arteries) except external iliac vein, contained no contrast medium, so they were not identifiable.

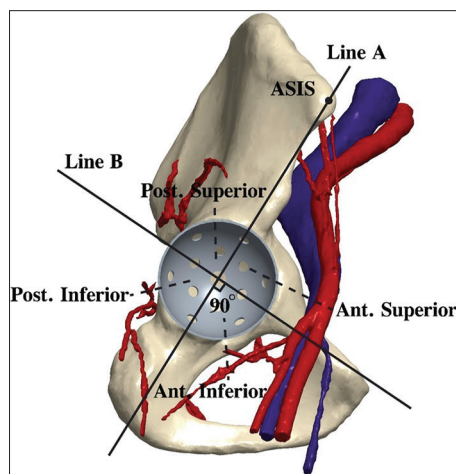
We reconstructed the CT volumetric data of all thirty eight hips into 3D images.

### Surgical simulation and measurements

Creo Parametric 3.0 software (PTC, Inc., Massachusetts, USA) was used to create the 3D model of a proper-sized acetabular cup, and the design of a commercially available acetabular cup with 12 screw holes (Pinnacle, Depuy, Warsaw, IN, USA) was used as a template.

For simulating clinical surgery, acetabular position is adjusted in orthographic coronal and sagittal planes at a level of true acetabulum, oriented at 45° of inclination with 15° and 20° of anteversion [Figure 2].<sup>11</sup> To achieve interference rim fit in reamed acetabulum, we positioned the inferior edge of the cup at the level of the bottom of teardrop line together with cup constraining in both anterior and posterior columns in the transverse plane.

Using a simple acetabular-quadrant system as described by Wasielewski *et al.*, we divided the cup by two perpendicular



**Figure 1:** Three-dimensional computational model of osseous and arterial structures. Schematic diagram illustrating the quadrant system described by Wasielewski *et al.* Pelvic bone rendered with light grayish orange whereas arteries and veins rendered with red and blue color. Surgical simulation performed to fix acetabular cup, augmenting the 13 screw-hole positions

lines.<sup>9</sup> The first (line A) joined the anterosuperior iliac spine to the center of the acetabulum, resulting in an anterior and posterior halves. The second (line B), perpendicular to the first line (line A), also passed through the center of the acetabulum to create superior and inferior hemi-quadrants [Figure 1].

However, to mimic 3D screws, we created 13 standard 25 mm long screws (4 mm inner diameter and 5 mm outer diameter) and placed in each cup hole of all 38 hips using simulated screw fixations with ideal (screw fixed perpendicular to cup surface) and angular eccentric profiles. Screw configuration profiles (SCP) are listed in Table 1 and all possible angular eccentricities from the manufacturer guideline were demonstrated. Each cup was simulated with 12 screws and one polar screw. Further, each screw was rotated in accordance with developed SCP [Table 1]. Fixation of all 12 screws were performed according to their SCP [Figure 3A-E], whereas for polar screw, fixations were made along with subsequent SCP (1–5) as shown in Figure 3F, but it is quite not imaginative in figure so described below as:

SCP-1: In ideal screw fixation, polar screw's axis was lying on the fixed acetabular axis passing through the geometric center of the acetabular cup [Figure 3A].

SCP-2: For polar screw, angular eccentricity is along acetabular axis plane (AXP), toward acetabular plane (AP) inferiorly [Figure 3F].

SCP-3: For a polar screw, angular eccentricity is along AXP, toward AP superiorly [Figure 3F].

SCP-4: For a polar screw, angular eccentricity is along the plane perpendicular to AXP and toward AP posteriorly [Figure 3F].

SCP-5: For a polar screw, angular eccentricity is along the plane perpendicular to AXP and toward AP anteriorly [Figure 3F].

To estimate the relative risk of different eccentric profiles of the screws on blood vessels proximal to pelvic bones, we used analysis tool in Creo Parametric at each level to measure the distance between screw and adjoining blood vessel. We then calculated the contiguous mean distance and their standard deviation from the major blood vessels such as obturator artery, external iliac vein, external iliac artery, inferior gluteal artery, and superior gluteal artery to its adjacent screws in all the 38 patients.

### Initial criteria were setup to consider the risk factor of vessels

C1 - Structures were entirely safe if, they were at a distance >20 mm from the screw.

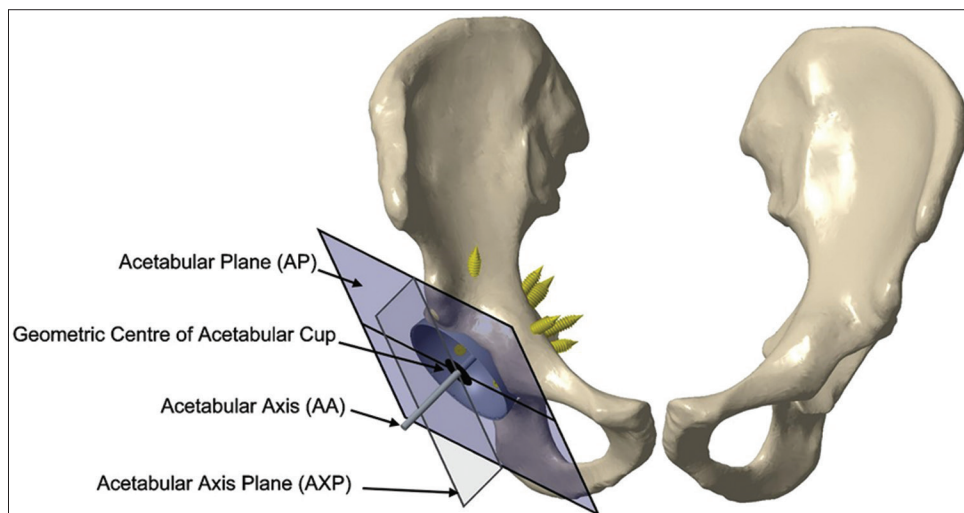
C2 - Structures were considerably safe if screw tip was not directed to blood vessels with a distance >5 mm.

C3 - Structures were considered at risk if, they felt within 5–20 mm from the screw and screw tip was directed to

**Table 1: Set of angular eccentric screw configuration profiles**

SCP	Cup inclination angle (°)	Cup anteversion angle (°)	Screw angular eccentricity (°)	Eighteen developed angular eccentric SCP
SCP-1	45	15	0	SCP-1 (45-15-0)
		20	0	SCP-1 (45-20-0)
SCP-2	45	15	17	SCP-2 (45-15-17)
			34	SCP-2 (45-15-34)
		20	17	SCP-2 (45-20-17)
			34	SCP-2 (45-20-34)
SCP-3	45	15	17	SCP-3 (45-15-17)
			34	SCP-3 (45-15-34)
		20	17	SCP-3 (45-20-17)
			34	SCP-3 (45-20-34)
SCP-4	45	15	17	SCP-4 (45-15-17)
			34	SCP-4 (45-15-34)
		20	17	SCP-4 (45-20-17)
			34	SCP-4 (45-20-34)
SCP-5	45	15	17	SCP-5 (45-15-17)
			34	SCP-5 (45-15-34)
		20	17	SCP-5 (45-20-17)
			34	SCP-5 (45-20-34)

SCP=Screw Configuration Profile



**Figure 2: Schematic diagram showing illustration of the planes and axis of acetabular cup. Line originating from geometric center of acetabular cup, which is perpendicular to acetabular plane, is known as acetabular axis**

blood vessels (The criterion takes into normal anatomical variation plus change in vascular structure position due to hip movement).

C4 - Structures were considered fully insulated if they were hit and punctured by the screw, or structures that touched the tip of screw and/or having a distance <5 mm.

However, we consider that the screws, which lie inside the bone, are entirely safe and hence, do not fall in the above criteria.

Furthermore, we performed one-way analysis of variance followed by a *post hoc* Tukey's Honest significant difference test in graphing and analysis software Origin 9.1 (OriginLab

Corporation, Northampton, USA). This test was performed to ascertain whether there was statistically significant difference between the mean of rotated screw with ideal screw fixation (i.e., no eccentricity). We chose the significance level (*P* value) of 0.05 or below.

### Results

To ascertain a comparative risk study of blood vessels that are not visible during surgery, with different SCP, a relationship was established by measuring the distance between corresponding arteries, veins and all rotated screw according to their respective SCPs. In addition, it was apparently not possible to show all 18 possible ways of

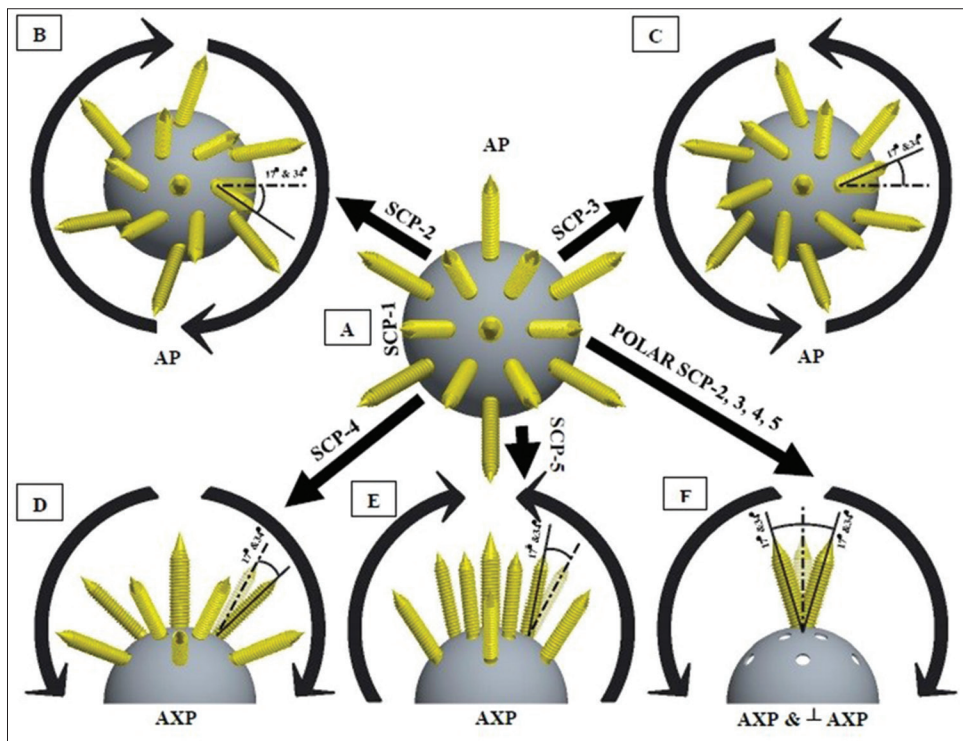


Figure 3: (A-F). The ideal fixation and angular eccentricity fixation of screws. Semi-transparent screw in figure B-F shows the ideal screw fixation and angular arrows are outlined as the screw rotation on specified plane. 17° and 34° rotation contemplated for every screw configuration profiles independently. In figure F, polar screw configuration is demonstrated which is associated with screw configuration profiles-2, screw configuration profiles-3, screw configuration profiles-4, screw configuration profiles-5 consequently

the each angulated screws pictographically. Therefore, we analyzed and engraved all structures with their respective criteria (i.e., C1, C2, C3, and C4) in tabular format [Table 2].

### Statistical results

For obturator artery, screws S0, S1, S4, S7, and S8 were found in its proximity. Screw S0 in SCP-4 (45-20-34) is statistically significant from ideal screw fixation (SCP-1) ( $P < 0.0001$ ) therefore follows criteria C1. Screw S1 in SCP-3 (45-20-34) therefore follows criteria C1. Screw S1 in SCP-3 (45-20-34) has the most significant difference ( $P < 0.0001$ ) from SCP-1 (45-15-0) and therefore lies in criteria C4. We did not test the significance level in screw S4 because, in ideal SCP, the screw had a good bone stock. Exceptionally, screw S4 in SCP-5 (45-20-34) has the most significant distance of 7.60 mm and follows criteria C2. Screw S7 in SCP-2 (45-20-17) was not statistically different ( $P = 0.3493$ ) from SCP-1 (45-20-0) and both lie in criteria C3. Screw S8 for all SCPs follows criteria C3.

External iliac vein lies in anterior quadrant encountered with screws S5, S6, S8, and S9 [Figure 4]. Screw S5 in SCP-5 (45-20-34) having most significant difference ( $P < 0.0001$ ) among all eccentric profiles follows criteria C1. Screw S6 in SCP-3 (45-20-34) was significantly different ( $P < 0.0001$ ) from ideal SCP and follows criteria C3 because of less bone stock. Screw S8 in SCP-3 (45-15-34) (45-20-17) (45-20-34) has most significant difference ( $P < 0.0001$ ) with ideal SCP. Screw S8 in SCP-3 (45-15-34) (45-20-17) follows criteria C1 and in

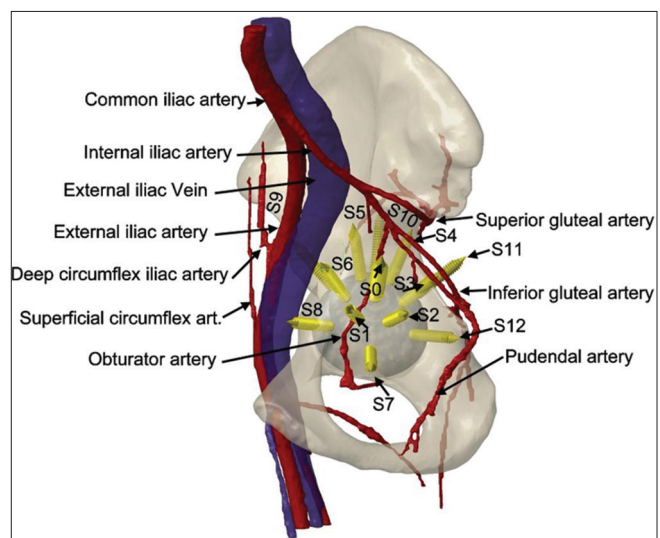


Figure 4: Schematic diagram showing the intrapelvic bony surface anatomy fitted with acetabular cup with 13 screws relative to the iliac arterial and vein system

SCP-3 (45-20-34) follows criteria C3 due to insufficient bone stock. Screw S9 in SCP-2 (45-15-34) having most significant difference ( $P < 0.0001$ ) with ideal SCP follows criteria C3 because of less bone stock.

The external iliac artery was adjacent to the anterior column and was found close to screws S5, S6, S8, and S9 [Figure 4]. Screw S5 in SCP-1 (45-15-0) was significantly different ( $P < 0.0001$ ) from SCP-3 (45-15-17) and lies in

**Table 2: List of screws in all 18 eccentric screw configuration profiles following their respective criteria (i.e., C1, C2, C3, C4) relative to vessel structures proximal to pelvic bone**

SCP	Obturator artery				External iliac vein				External iliac artery				Inferior gluteal artery				Superior gluteal artery			
	C1	C2	C3	C4	C1	C2	C3	C4	C1	C2	C3	C4	C1	C2	C3	C4	C1	C2	C3	C4
SCP-1 (45-15-0)	S4	S7	S8	S0, S1	S5, S6, S8, S9	S6, S8, S9	S5, S6, S8, S9	S5	S5	S6, S9	S8	S8	S0, S2, S3	S0, S2, S3	S12	S12	S3	S3	S12	S12
SCP-1 (45-20-0)	S4	S7	S8	S0, S1	S6, S8, S9	S6, S8, S9	S5, S6, S8, S9	S9	S9	S5, S6, S8	S5, S6, S8	S5, S6, S8	S0, S2, S3	S0, S2, S3	S12	S12	S3	S3	S12	S12
SCP-2 (45-15-17)	S4	S7	S8	S0, S1	S6, S8, S9	S6, S8, S9	S5, S6, S8, S9	S8	S8	S6, S5	S6, S5	S3	S0, S2, S12	S0, S2, S12	S3	S3	S3, S12	S3, S12	S3, S12	S3, S12
SCP-2 (45-15-34)	S0, S4	S7	S8	S1	S6	S6	S5, S9	S8	S9	S8	S5, S6	S5, S6	S0, S2, S3, S12	S0, S2, S3, S12	S3	S3	S3, S12	S3, S12	S3, S12	S3, S12
SCP-2 (45-20-17)	S4	S7	S7, S8	S0, S1	S9	S6, S8	S5	S9	S9	S8	S5, S6, S8	S5, S6, S8	S0, S2, S12	S0, S2, S12	S3	S3	S3, S12	S3, S12	S3, S12	S3, S12
SCP-2 (45-20-34)	S4	S7	S8	S0, S1	S9	S6	S5	S8	S8	S8	S5, S6, S9	S5, S6, S9	S0, S2, S3, S12	S0, S2, S3, S12	S3	S3	S3, S12	S3, S12	S3, S12	S3, S12
SCP-3 (45-15-17)	S4	S7	S8	S0, S1	S6, S8	S6, S8	S5, S9	S8	S8	S5, S6, S8	S5, S6, S8	S9	S0, S2, S3, S12	S0, S2, S3, S12	S3	S3	S3, S12	S3, S12	S3, S12	S3, S12
SCP-3 (45-15-34)	S4	S7	S8	S0, S1	S8	S6	S5, S9	S8	S8	S6, S8	S5, S6, S8	S9	S0, S2, S3, S12	S0, S2, S3, S12	S3	S3	S3, S12	S3, S12	S3, S12	S3, S12
SCP-3 (45-20-17)	S4	S7	S8	S0, S1	S8	S6, S9	S5	S8	S8	S5, S6	S5, S6	S9	S0, S2, S12	S0, S2, S12	S3	S3	S3, S12	S3, S12	S3, S12	S3, S12
SCP-3 (45-20-34)	S4	S7	S0, S8	S1	S6, S8, S9	S6, S8	S5, S9	S8	S8	S5, S6, S8	S5, S6, S8	S9	S0, S2, S3	S0, S2, S3	S0, S2, S3	S0, S2, S3	S3	S3	S3	S3
SCP-4 (45-15-17)	S4	S7	S8	S0, S1	S6, S8	S6, S8	S5, S9	S8	S9	S6	S5, S8	S5, S8	S2, S3	S2, S3	S12	S0	S3	S3	S12	S12
SCP-4 (45-15-34)	S0, S4	S7	S8	S1	S9	S8	S5	S6	S9	S6	S5, S8	S5, S8	S2, S3	S2, S3	S12	S0	S3	S3	S12	S12
SCP-4 (45-20-17)	S4	S7	S8	S0, S1	S9	S6, S8	S5	S6, S8, S9	S9	S6, S8, S9	S5	S5	S2, S3	S2, S3	S12	S0	S3	S3	S12	S12
SCP-4 (45-20-34)	S0, S4	S7	S8	S1	S9	S8	S5	S6	S9	S6, S5	S5	S5	S0, S2, S12	S0, S2, S12	S3	S3	S3	S3	S12	S12
SCP-5 (45-15-17)	S4	S7	S8	S0, S1	S5, S6, S8, S9	S5, S6, S8, S9	S5, S6, S8, S9	S5, S6	S12	S5, S6	S8	S8	S0, S2, S3	S0, S2, S3	S0, S2, S3	S3	S3, S12	S3, S12	S3, S12	S3, S12
SCP-5 (45-15-34)	S4	S7	S8	S0, S1, S4	S5, S6, S8, S9	S5, S6, S8, S9	S5, S6, S8, S9	S6, S8	S12	S6, S8	S9	S5	S0, S2, S3	S0, S2, S3	S0, S2, S3	S3	S3, S12	S3, S12	S3, S12	S3, S12
SCP-5 (45-20-17)	S4	S7	S8	S0, S1	S6, S8, S9	S6, S8, S9	S5, S6, S8, S9	S5, S6, S8	S8	S5, S6, S9	S9	S5	S0, S2, S3	S0, S2, S3	S12	S12	S3	S3	S3	S12
SCP-5 (45-20-34)	S4, S7	S8	S8	S0, S1	S5, S6, S8, S9	S6, S8, S9	S5, S6, S8, S9	S5, S6, S8	S8	S5, S6, S9	S9	S5	S0, S2, S3	S0, S2, S3	S0, S2, S3	S3	S3, S12	S3, S12	S3, S12	S3, S12

SCP=Screw Configuration Profile

criteria C1. Screw S6 in SCP-3 (45-15-34) is statistically different ( $P < 0.0001$ ) with ideal SCP, and lies in criteria C1. Screw S8 in SCP-3 (45-20-17) was having a significant difference ( $P < 0.0001$ ) with ideal SCP and follows criteria C1. Screw S9 in SCP-2 (45-15-34) is statistically different ( $P < 0.0001$ ) and lies in criteria C1.

Inferior gluteal artery found closer to the posterior column was encountered with S0, S2, S3, and S12 screws [Figure 4]. Screw S0 in SCP-5 (45-15-17) has the significant difference ( $P < 0.0001$ ) but lies in C3 because of deficient bone stock. Screw S2 itself was most significant ( $P < 0.0001$ ) from SCP-5 (45-15-17), followed criteria C3 because of less bone stock. Screw S3 in SCP-3 (45-20-17) was statistically different from ideal SCP ( $P < 0.0001$ ) and lies in criteria C1. We did not perform any statistical analysis for screw S12 as the ideal screw lies inside the pelvic bone.

Superior gluteal arteries were close to the pelvic bone at the superior portion of the sciatic notch in the posterior quadrant and encountered with S3 and S12 screws [Figure 4]. Screw S3 in SCP-3 (45-20-17) was statistically different ( $P < 0.0001$ ) from ideal SCP and lies in criteria C1. Statistical analysis was not performed for screw S12 because ideal SCP has the absolute bone stock.

## Discussion

Researchers have published various reports on vascular injuries by placement of screws in context with THA; they are particularly dangerous since they can lead to the elimination or even to the death of the patient.<sup>6,12-20</sup> In addition, external iliac vessel and obturator artery seem to have the most frequent injury because of their close proximity to the anterior column and quadrilateral surface, respectively.<sup>4,18</sup> However, injury to internal iliac vessel, inferior, and superior gluteal vessel also has been reported.<sup>7,21,22</sup>

Wasielowski *et al.* described the quadrant system to prevent the vascular as well as neural structure, proximal to the pelvic bone. They recommended the use of quadrant system to place screws in cementless cup fixation, and hip arthroplasty surgeons already accepted it widely until date. In recent years, optimizing the total hip component, manufacturers are providing the eccentric hole (up to  $34^\circ$ ) for screw fixation in acetabular cup. These eccentric cups may perhaps not abide the quadrant system provided by Wasielowski *et al.* However, we are aware of no similar reports (to our knowledge) on the effect of angular eccentric screws on vascular injury. Apart from this, Hsu *et al.* had studied the mechanical effect of press fit cup on the offset and angular eccentric screw in different experimental as well as the computational environment which is not directly associated with these findings.<sup>23,24</sup> Thus, we sought to determine the effect of the eccentric screw for two angular rotations ( $17^\circ$  and  $34^\circ$ ), along with different configurations [Table 1].

The study used CT angiography scans, and special medical imaging and editing software Mimics18.0 to reconstruct the osseous and vessel structures of the pelvis. We also determined the distance between the intrapelvic blood vessels and impeding screw, following criteria C1, C2, C3, and C4 by Creo 3.0 parametric analysis tool.

From the results of the surgical simulation, measurements, and statistical analysis, it is evident that eccentric screws play a vital role in the vascular injury. Considering the quadrant system (proposed by Wasielowski *et al.*) and our findings, it is evident that the polar position is a rarely used position for a screw, because of deficient bone stock and presence of obturator artery. Thus, we can conclude that screws lying in the polar position were potentially dangerous for obturator artery. Visual determination provided that few screws, which lie in anterior or posterior quadrants in ideal fixation, were directed toward polar positions due to the angular rotation, and thus felt in the dangerous category for vessel structures.

Screws that lie in the posterior superior quadrant were not directed to the external iliac vessels or obturator artery. In addition, some of the SCP of the screws such as S10 of profile SCP-5 (45-15-17) (45-20-17), SCP-4 (45-15-34) (45-20-34), SCP-2 (45-15-17) (45-20-17) (45-15-34) (45-20-34), SCP-1 (45-15-0) (45-20-0) and S4 of profile SCP-4 (45-15-17) (45-20-17) (45-15-34) (45-20-34) and screw S11 of profile SCP-3 (45-15-34) (45-20-34) are not significant for use due to deficient bone stock. However, in ideal screw fixation, screws that lie in posterior superior quadrant or screws directed to the posterior superior quadrant as a result of eccentricity became safe.

Screws directed toward the posterior inferior quadrant lie close to the superior and inferior gluteal artery and pudendal artery, and yet are entirely safe in the vast majority of the angular eccentric profile [Table 1]. S11 might be downright insulted screw because of insufficient bone stock from transition zone of line-B [Figure 4] to the distal portion of the posterior quadrant.

The study addresses the critical issue of screws placed in an anterior quadrant in different eccentric SCP. Screws that lie in superior anterior quadrant or screws directed because of eccentricity occur in proximity to the external iliac artery and vein. Since the external iliac vein is more medial, or close proximal to the polar surface, the screws that lie in the anterior quadrant in ideal or eccentric fixation were possibly unsafe.

Angulated screws that lie in anterior inferior quadrant or screws that originate from other quadrant and are directed to anterior inferior quadrant are potentially dangerous for obturator artery, because the bone stock in this quadrant was significantly less in majority of the patients.

In general, a major finding of our study indicates that the quadrant system represented by Wasielowski *et al.* was

slightly different in relation to the modern prosthetic cup with the eccentric hole for screw fixation. Additionally, screws that were found probably dangerous for vessel structures in Wasielewski findings could be significantly tolerable and benefited for due consideration as a result of angular eccentricity.

Perhaps, the most important result of the study predicts that the eccentric screw fixation is considered safe for criteria C1 and C2 and dangerous for C3 and C4 [Table 2]. As the direction of the eccentric screw tip and bone purchase can seriously affect the vascular structures proximal to pelvic bone, the surgeons are recommended to consider the criterion mentioned in our study [Table 2] together with the quadrant system proposed by Wasielewski.

The study subjects to a few limitations. To start with, we performed the study only on an Indian populace, and the stature of the patients was fairly short. We did not examine the results with other populace, for example, in the Japanese, Chinese, Africans, USA, and Europe.

Second, we did not investigate patients with the hip disease such as osteoarthritis and rheumatoid arthritis, infection, revision surgery, gender, and protrusio. Therefore, our results may not apply to all patients with hip disease because the study was done in normal hip presumed to be undergoing primary THA; complex arthroplasty was not considered. We, however, believe that the present data maybe applicable to the patients requiring THA which are generally older and have atrophy of the muscles around the hip joint due to disuse.

Third, neural structures were not identifiable in angiographic CT. In most cases, these nerves keep company with the homonymous blood vessels in a neurovascular bundle. Along these lines, we tend to trust that a safe zone or dangerous zone for eccentric screws characterized by a vascular structure may be utilized likewise to avoid nerve injury.

Finally, we did not perform study on the aberrant anatomy of vessel structures and developmental dysplasia of hip.<sup>21,25-29</sup> However, in our thirty eight patients' data, no anatomical variants and dysplasia of hip were present.

## Conclusion

Cementless cup with screw fixation in MI-THA is technically demanding. We trust that the data concerning the placement of eccentric screws in modern cup may be helpful in avoiding neurovascular injury. Further, the surgeons must consider the operating procedure to guarantee the safe screw placement with the angular eccentric hole in the prosthetic cup.

## Acknowledgment

The authors would like to acknowledge vice to 64-Slice CT center, Departments of Radio Diagnosis and Imaging, Sir

Sunder Lal Hospital, Institute of Medical Sciences, BHU, Varanasi, India, for providing specific patients' data.

## Financial support and sponsorship

Nil.

## Conflicts of interest

There are no conflicts of interest.

## References

1. Cheng T, Feng JG, Liu T, Zhang XL. Minimally invasive total hip arthroplasty: A systematic review. *Int Orthop* 2009;33:1473-81.
2. Sculco TP. Minimally invasive total hip arthroplasty: In the affirmative. *J Arthroplasty* 2004;19 4 Suppl 1:78-80.
3. Avisar E, Elvey MH, Bar-Ziv Y, Tamir E, Agar G. Severe vascular complications and intervention following elective total hip and knee replacement: A 16-year retrospective analysis. *J Orthop* 2015;12:151-5.
4. Hwang SK. Vascular injury during total hip arthroplasty: The anatomy of the acetabulum. *Int Orthop* 1994;18:29-31.
5. Barrack RL. Neurovascular injury: Avoiding catastrophe. *J Arthroplasty* 2004;19 4 Suppl 1:104-7.
6. Parvizi J, Pulido L, Slenker N, Macgibeny M, Purtill JJ, Rothman RH. Vascular injuries after total joint arthroplasty. *J Arthroplasty* 2008;23:1115-21.
7. Kong EL, Knight MR. Internal iliac artery injury and total hip arthroplasty: Discovery after 10 years. *J Arthroplasty* 2013;28:196.e15-7.
8. Dietze S, Perka C, Baecker H. Blood vessel and nerve damage in total hip arthroplasty. *Orthopade* 2014;43:64-9.
9. Wasielewski RC, Cooperstein LA, Kruger MP, Rubash HE. Acetabular anatomy and the transacetabular fixation of screws in total hip arthroplasty. *J Bone Joint Surg Am* 1990;72:501-8.
10. Suppanee R, Wong P, Esat I, Chizari M, Rajakulendran K, Bardakos NV, *et al.* The kinematics of the hip joint with femoroacetabular impingement may be affected by the thickness of the articular cartilage In: Andreaus U, Iacoviello D, editors. *Biomedical Imaging and Computational Modeling in Biomechanics*. 1<sup>st</sup> ed. Netherlands: Springer; 2013. p. 39-54.
11. Harrison CL, Thomson AI, Cutts S, Rowe PJ, Riches PE. Research synthesis of recommended acetabular cup orientations for total hip arthroplasty. *J Arthroplasty* 2014;29:377-82.
12. Wheelless CR 3<sup>rd</sup>. Screw fixation of acetabular components. Wheelless' Textbook of Orthopaedics. Data Trace Internet Publishing, LLC; 2011. Available from: [http://www.wheellessonline.com/ortho/screw\\_fixation\\_of\\_acetabular\\_components](http://www.wheellessonline.com/ortho/screw_fixation_of_acetabular_components). [Last accessed on 2016 Feb 01].
13. Freischlag JA, Sise M, Quinones-Baldrich WJ, Hye RJ, Sedwitz MM. Vascular complications associated with orthopedic procedures. *Surg Gynecol Obstet* 1989;169:147-52.
14. Nachbur B, Meyer RP, Verkkala K, Zürcher R. The mechanisms of severe arterial injury in surgery of the hip joint. *Clin Orthop Relat Res* 1979;141:122-33.
15. Reiley MA, Bond D, Branick RI, Wilson EH. Vascular complications following total hip arthroplasty. A review of the literature and a report of two cases. *Clin Orthop Relat Res* 1984;186:23-8.
16. Shoenfeld NA, Stuchin SA, Pearl R, Haveson S. The management of vascular injuries associated with total hip arthroplasty. *J Vasc Surg* 1990;11:549-55.

17. Bergqvist D, Carlsson AS, Ericsson BF. Vascular complications after total hip arthroplasty. *Acta Orthop Scand* 1983;54:157-63.
18. Lavernia CJ, Cook CC, Hernandez RA, Sierra RJ, Rossi MD. Neurovascular injuries in acetabular reconstruction cage surgery: An anatomical study. *J Arthroplasty* 2007;22:124-32.
19. Hussain WM, Hussain HM, Hussain MS, Manning DW. A late vascular complication due to component migration after revision total hip arthroplasty. *J Arthroplasty* 2011;26:976.e7-976.e10.
20. Iorio R, Puskas B, Healy WL, Tilzey JF, Specht LM, Thompson MS. Cementless acetabular fixation with and without screws: Analysis of stability and migration. *J Arthroplasty* 2010;25:309-13.
21. Marmor M, Lynch T, Matityahu A. Superior gluteal artery injury during iliosacral screw placement due to aberrant anatomy. *Orthopedics* 2010;33:117-20.
22. Rue JP, Inoue N, Mont MA. Current overview of neurovascular structures in hip arthroplasty: Anatomy, preoperative evaluation, approaches, and operative techniques to avoid complications. *Orthopedics* 2004;27:73-81.
23. Hsu JT, Chang CH, An KN, Zobitz ME, Phimolsarnti R, Hugate RR, *et al.* Effects of screw eccentricity on the initial stability of the acetabular cup. *Int Orthop* 2007;31:451-5.
24. Hsu JT, Lin DJ. Effects of screw eccentricity on the initial stability of the acetabular cup in artificial foam bone of different qualities. *Artif Organs* 2010;34:E10-6.
25. Kawasaki Y, Egawa H, Hamada D, Takao S, Nakano S, Yasui N. Location of intrapelvic vessels around the acetabulum assessed by three-dimensional computed tomographic angiography: Prevention of vascular-related complications in total hip arthroplasty. *J Orthop Sci* 2012;17:397-406.
26. Pai MM, Krishnamurthy A, Prabhu LV, Pai MV, Kumar SA, Hadimani GA. Variability in the origin of the obturator artery. *Clinics (Sao Paulo)* 2009;64:897-901.
27. Sakellariou VI, Christodoulou M, Sasalos G, Babis GC. Reconstruction of the acetabulum in developmental dysplasia of the hip in total hip replacement. *Arch Bone Jt Surg* 2014;2:130-6.
28. Narasimhan R. Complications of management of developmental dysplasia of the hip. *Indian J Orthop* 2003;37:237-40.
29. D'Angelo F, Murena L, Zatti G, Cherubino P. The unstable total hip replacement. *Indian J Orthop* 2008;42:252-9.