

# A comparative study to evaluate the efficacy of platelet-rich plasma and triamcinolone to treat tennis elbow

Vanamali B Seetharamaiah, Amrit Gantaguru, Sunil Basavarajanna

## ABSTRACT

**Background:** Lateral elbow pain is common with a population prevalence of 1%–3%. The study was a comparative trial to validate the efficacy of single injection of platelet-rich plasma (PRP) for tennis elbow as compared with single injections of triamcinolone and placebo (normal saline) over a short term period.

**Materials and Methods:** Comparative trial with 3- and 6-month followup evaluated with visual analog scale (VAS) and facial pain scale (FPS). Our study included a total of eighty patients with unilateral or bilateral tennis elbows. The study population included patients between 20 and 40 years age group belonging to either sex with seventy unilateral and ten bilateral affections for more than 3-month duration. Patients suffering from elbow pain due to other problems or those who have received any form of injection were excluded from the study. One milliliter of 2% Xylocaine injection was given before injecting the proposed formulation under trial. VAS and FPS were used for scoring pain. Kruskal–Wallis test and Mann–Whitney U-tests were used for statistical analyses at 12 and 24 weeks.

**Results:** Overall, 49 females and 31 males were included with thirty elbows in each group. Both the PRP and triamcinolone groups had better pain relief at 3 and 6 months as compared to normal saline group ( $P < 0.05$ ), but at 6 months followup, the PRP group had statistically significant better pain relief than triamcinolone group. In the triamcinolone group, 13 patients had injection site hypopigmentation and 3 patients had subdermal atrophy.

**Conclusion:** Over a short term period, PRP gives better pain relief than triamcinolone or normal saline in tennis elbow which needs to be validated over long term period by further studies.

**Key words:** Lateral epicondylitis, platelet-rich plasma, tennis elbow, triamcinolone, normal saline

**MeSH terms:** Platelets, steroids, saline solution, lignocaine, tendinosis, elbow

## INTRODUCTION

Lateral elbow pain is common with a population prevalence of 1%–3%.<sup>1</sup> The peak incidence occurs at around 40–50 years of age group and in women aged 42–46 years, incidence increases to 10%.<sup>2,3</sup> In the UK, the Netherlands, and Scandinavia, the annual incidence of lateral elbow pain in general practice is 4-7/1000 population.<sup>3,5</sup> The term was coined in 1883 as “Lawn-tennis elbow.”<sup>6</sup> Inflammatory cells are not found in the tendon tissues;

therefore, Nirschl *et al.* coined the term “Angiofibroblastic tendinosis” to describe this condition.<sup>7,8</sup> Its common name, tennis elbow, is somewhat of a misnomer because the condition is often work related and occurs in athletes and nonathletes alike.<sup>9</sup> The condition starts as a micro-tear in extensor carpi radialis brevis.<sup>10</sup> Acute onset of symptoms occurs more often in young athletes; chronic, recalcitrant symptoms typically occur in older patients.<sup>9</sup> Conservative measures are undertaken initially because symptoms in most patients improve with time and rest. Those who fail to respond to conservative therapy are considered for surgical treatment.<sup>11</sup>

The goals of nonoperative treatment are to revitalize the unhealthy pain producing tendinosis tissue.<sup>10</sup> Nonoperative

Department of Orthopaedics, Victoria Hospital, Bangalore Medical College and Research Institute, Bengaluru, Karnataka, India

**Address for correspondence:** Dr. Amrit Gantaguru, Department of Orthopaedics, Victoria Hospital, Bangalore Medical College and Research Institute, Fort Road, KR Market, Bengaluru - 560 002, Karnataka, India. E-mail: amrit.sunny87@gmail.com

Access this article online	
Quick Response Code:	Website: <a href="http://www.ijonline.com">www.ijonline.com</a>
	DOI: 10.4103/ortho.IJOrtho_181_16

This is an open access article distributed under the terms of the Creative Commons Attribution-NonCommercial-ShareAlike 3.0 License, which allows others to remix, tweak, and build upon the work non-commercially, as long as the author is credited and the new creations are licensed under the identical terms.

**For reprints contact:** [reprints@medknow.com](mailto:reprints@medknow.com)

**How to cite this article:** Seetharamaiah VB, Gantaguru A, Basavarajanna S. A comparative study to evaluate the efficacy of platelet-rich plasma and triamcinolone to treat tennis elbow. *Indian J Orthop* 2017;51:304-11.

treatment includes rehabilitative resistance exercise with progression of the exercise program,<sup>10</sup> corticosteroid injection,<sup>12</sup> autologous blood injection,<sup>13</sup> extracorporeal shock wave therapy,<sup>14</sup> botulinum toxin injection,<sup>15</sup> and hyaluronic acid with chondroitin sulfate injection.<sup>16</sup> Platelets, an important reservoir of growth factors in the body, play an important role in many processes such as coagulation, immune response, angiogenesis, and the healing of damaged tissues. Numerous proteins are contained in the alpha-granules of platelets: platelet-derived growth factor, transforming growth factor, platelet factor interleukin, platelet-derived angiogenesis factor, vascular endothelial growth factor, epidermal growth factor, insulin-like growth factor, and fibronectin.<sup>17</sup> Single or multiple injections of platelet-rich plasma (PRP) have been shown to be of significance in the management of tennis elbow. Randomized controlled trial comparing efficacy of PRP with other modalities will validate the usefulness of PRP in lateral epicondylitis (LE).<sup>18</sup>

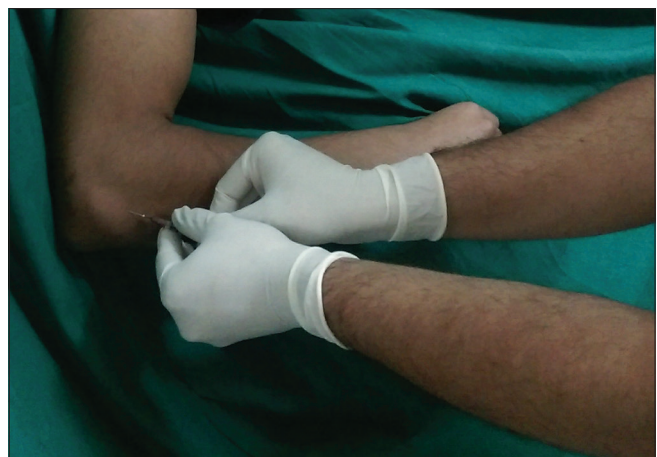## MATERIALS AND METHODS

The study was conducted from August 2013 to May 2015 at our institution after getting Ethical Committee clearance. Patients in the age group of 20–50 years of either sex who were clinically having symptoms suggestive of tennis elbow were included in the study. Patients who had received any previous treatment in the form of local injections of steroid were excluded from the study. Patients who were suffering from symptoms of pain around the elbow due to other reasons such as inflammatory arthropathies, posterior interosseous nerve syndrome, osteochondritis dissecans of elbow, elbow pain referred from cervical spine, or ipsilateral shoulder were excluded from the study. Consent for the procedure was obtained. All patients were subjected to routine blood investigation including the markers for inflammatory arthropathy and radiographic examinations of cervical spine, ipsilateral shoulder, and the elbow under study. Patients clinically diagnosed to have tennis elbow and after excluding all other causes of elbow pain were subjected to ultrasonographic examination of the elbow under study to confirm the diagnosis of tennis elbow. The findings involve hypoechoic signal from the extensor tendons suggestive of edema of the extensor tendon in all cases. The patients were randomized into three groups according to the randomization software. First group of patients was given autologous PRP, the second group was given steroid triamcinolone, and the third group of patients was given normal saline injection as the placebo. The results were recorded by visual analog scale (VAS) score and facial pain scale (FPS). The scores were recorded in the prepared Pro forma on the day of injection before giving the injection, then after

12 weeks and after 24 weeks. The results were analyzed using nonparametric tests such as Kruskal–Wallis test and Mann–Whitney U test. After giving injection, patients were given paracetamol for the initial pain relief in all the three groups. Patients were advised for rest during initial 2 weeks in the form of refraining from strenuous activities by the extremity under study after the injection. Bilateral cases were injected simultaneously, and the postinjection protocol was same.

To prepare PRP around 15 mL of patient's blood was obtained by drawing blood through a scalp vein catheter to avoid turbulence while drawing the blood. The PRP was prepared using differential centrifugation technique with two spins. The blood was collected in three citrate tubes having 0.9% sodium citrate as anticoagulant. The first spin was performed at 1500 rpm for 15 min using laboratory centrifuge. This spin separated the red blood cells from the rest of the components. The upper half of the supernatant was discarded. The lower halves of the supernatant from all the three tubes are transferred into another plain tube for the second spin. The second spin was performed at 2500 rpm for 10 min. The upper half of the supernatant was discarded. One milliliter of lower half was taken into a 1 mL syringe having 0.1 mL of calcium chloride. At the end of preparation of PRP the samples were sent for platelet count and the count compared with patient's platelet count. The second group was given 1 mL of triamcinolone, and the third group was given 1 mL of normal saline.

The site of injection was 5 mm distal to the lateral epicondyle in the extensor tendons, particularly extensor carpi radialis brevis tendon [Figure 1]. The skin was painted with povidone-iodine and ethyl alcohol. One milliliter of 2% lignocaine with adrenaline was injected at the injection site after giving test dose. After 10 min, the proposed injection was injected. The injection was given on and around the



**Figure 1:** A clinical photograph showing injection site

tendon and not inside the tendon. If any resistance was felt during the injection, the needle is withdrawn a bit and again injected. Patients were advised regarding postinjection care. The pain might increase during initial 2 weeks which was explained to the patient. Paracetamol was prescribed for pain relief.

## RESULTS

Eighty patients including 49 females and 31 males in the age group of 20–40 years with ninety elbows were included in the study. The study had thirty elbows in each group. Out of the 49 females with 53 elbows, 18 received PRP, 18 received triamcinolone, and 17 received normal saline. Out of the 31 males with 37 elbows under study, 12 received PRP, 12 received triamcinolone, and 13 received normal saline.

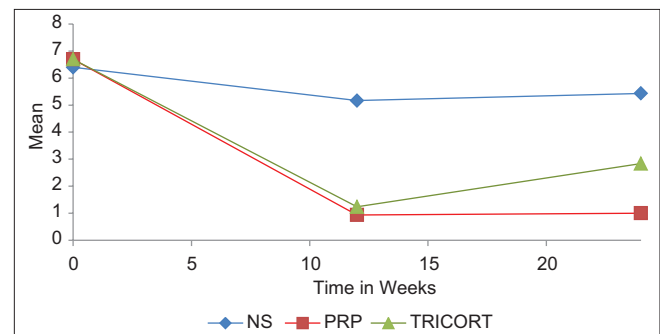
**Table 1: Kruskal-Wallis test to compare the result among all the three groups**

Scores	Kruskal-Wallis test		
	Injection given	n	Mean rank
VAS score day 0	1	30	47.73
	2	30	47.40
	3	30	41.37
	Total	90	
VAS score 12 weeks	1	30	31.98
	2	30	33.87
	3	30	70.65
	Total	90	
VAS score 24 weeks	1	30	24.48
	2	30	45.03
	3	30	66.98
	Total	90	
FPS day 0	1	30	45.82
	2	30	46.15
	3	30	44.53
	Total	90	
FPS 12 weeks	1	30	30.08
	2	30	35.50
	3	30	70.92
	Total	90	
FPS 24 weeks	1	30	22.85
	2	30	44.85
	3	30	68.80
	Total	90	

VAS=Visual analogue scale, FPS=Facial pain scale

For statistical analysis, the three groups are numbered as No. 1, No. 2, and No. 3 to represent PRP, triamcinolone, and normal saline. Kruskal–Wallis test was used to compare the result among all the three groups as shown in Tables 1 and 2. If we analyze the mean ranks, we can see that the mean ranks in all the three groups are similar on the day of injection for both VAS and FPS scores. At 12-week followup, the VAS score mean ranks in PRP group and triamcinolone group improved by 33% and 28.5%, respectively [Figures 2 and 3]. Similarly, at 12 weeks, the improvements in FPS scores were 34% and 23%, respectively, in PRP and triamcinolone group. At 24-week followup, the VAS score mean ranks in PRP group and triamcinolone group improved by 49% and 5%, respectively. Similarly, at 24 weeks, the improvements in FPS scores were 50% and 3%, respectively, in PRP and triamcinolone group. The normal saline group showed worsening of results in VAS score and in FPS score at 12 weeks and 24 weeks. FPS was calculated using appropriate proforma using FPS diagram chart. Hence, the pain scores improved in both PRP and triamcinolone group but worsened in the normal saline group at both 12- and 24-week followup. At 24 weeks, the improvement in pain was more with PRP than with triamcinolone where most patients had a relapse of pain.

We calculated the *P* values in Table 2 which showed that on the day of injection, it is not significant for both VAS score (*P* = 0.517) and FPS score (*P* = 0.960). Hence, on the day of injection, there was no significant difference in pain relief. However, at both 12 weeks and 24 weeks, the *P* < 0.001 for both VAS and FPS scores. As both PRP and



**Figure 2:** A line diagram showing mean visual analog scale for different time points between groups

**Table 2: Kruskal-Wallis test to compare the result among all the three groups**

Test parameters	Test statistics <sup>a,b</sup>					
	VAS score			FPS		
	Day 0	12 weeks	24 weeks	Day 0	12 weeks	24 weeks
$\chi^2$	1.318	47.104	41.083	0.082	49.207	49.205
df	2	2	2	2	2	2
Asymptomatic significant	0.517	<0.001	<0.001	0.960	<0.001	<0.001

<sup>a</sup>Kruskal-Wallis test, <sup>b</sup>Grouping variable: Injection given. VAS=Visual analogue scale, FPS=Facial pain scale

triamcinolone showed improvement in mean ranks, we conclude that PRP and triamcinolone showed statistically significant improvement in pain scores than placebo at 12 weeks and 24 weeks.

Next, in Tables 3 and 4, Mann-Whitney U test was used to compare VAS and FPS scores between PRP and triamcinolone. The mean ranks of both VAS and FPS scores in PRP group showed 1.138% and 4% improvement at 12 weeks, and at 24 weeks, 25% and 28% improvement, respectively. The differences in result were not significant at 12 weeks ( $P = 0.955$  and  $0.496$ ), but at 24 weeks, significant ( $P < 0.001$ ) for FPS scores and for VAS scores ( $P = 0.001$ ).

Similarly, when we compared the VAS and FPS scores between PRP and placebo with Mann-Whitney U test [Tables 5 and 6], we found that the mean ranks of both VAS and FPS scores in PRP group showed 47.4% and 47.19% improvement at 12 weeks, and at 24 weeks, 48.17% and 46.86% improvement, respectively. However, the mean ranks of both VAS and FPS scores in normal saline group

showed worsening at 12 weeks and at 24 weeks. The differences in result were significant ( $P < 0.001$ ) at both 12 weeks and 24 weeks for both VAS and FPS scores.

Table 7 shows  $P$  values among different groups on comparison.

Post hoc analysis was done for the study as shown in Figures 2 and 3, which showed a significant difference between VAS and FPS scores of PRP group than triamcinolone and normal saline group at 24 weeks, but at 12 weeks, the scores were not significant between PRP and triamcinolone groups. Figure 4 is the consort diagram of the study.

No complications were found in the group receiving PRP and placebo. However, out of thirty elbows given triamcinolone hypopigmentation at the injection site was found in 13 patients with associated subdermal atrophy in 3 patients [Figure 5]. No infection was there in any of the patients.

**Table 3: Mann-Whitney U-test ranks of visual analog scale and facial pain scale between platelet-rich plasma as one and triamcinolone as two**

Scores	Injection given	n	Mean rank
VAS score day 0	1	30	30.75
	2	30	30.25
	Total	60	
VAS score 12 weeks	1	30	30.40
	2	30	30.60
	Total	60	
VAS score 24 weeks	1	30	23.15
	2	30	37.85
	Total	60	
FPS day 0	1	30	30.45
	2	30	30.55
	Total	60	
FPS 12 weeks	1	30	29.28
	2	30	31.72
	Total	60	
FPS 24 weeks	1	30	21.95
	2	30	39.05
	Total	60	

VAS=Visual analogue scale, FPS=Facial pain scale

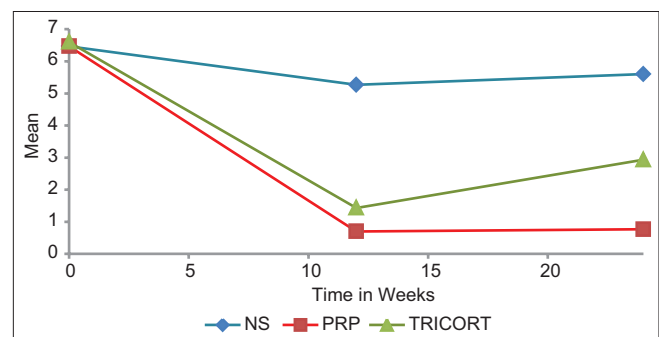
**Table 4: Mann-Whitney U-test statistics to compare visual analogue scale and facial pain scale between platelet-rich plasma and triamcinolone (grouping variable: Injection given)**

Test parameters	VAS score			FPS		
	Day 0	12 weeks	24 weeks	Day 0	12 weeks	24 weeks
Mann-Whitney U-test	442.500	447.000	229.500	448.500	413.500	193.500
Wilcoxon W	907.500	912.000	694.500	913.500	878.500	658.500
Z	-0.120	-0.056	-3.416	-0.026	-0.680	-4.068
Asymptomatic significant (two-tailed)	0.904	0.955	0.001	0.979	0.496	<0.001

VAS=Visual analogue scale, FPS=Facial pain scale

## DISCUSSION

LE is the most common cause of lateral elbow pain in adults that is encountered in day-to-day practice by most orthopedic surgeons. Although it is typically a self-limiting process, there are many nonsurgical and surgical treatment options available if LE becomes chronic and continues to cause pain.<sup>9</sup> With evolution of various nonsurgical options

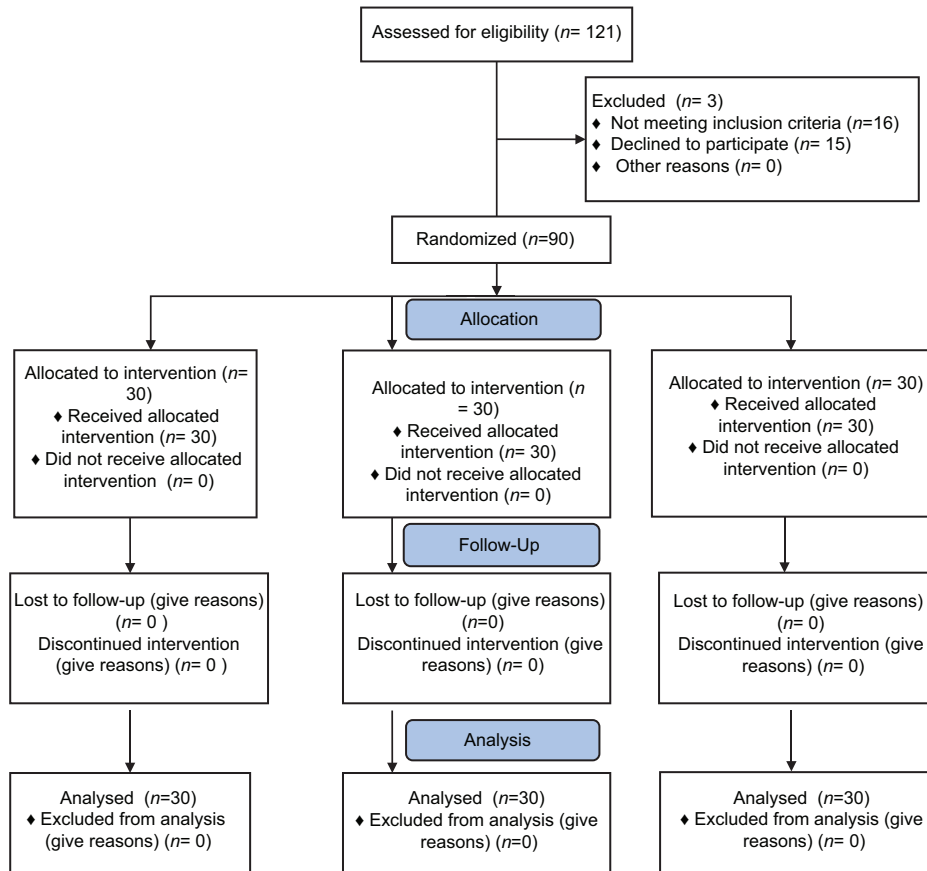


**Figure 3:** A line diagram showing mean facial pain scale for different time points between groups

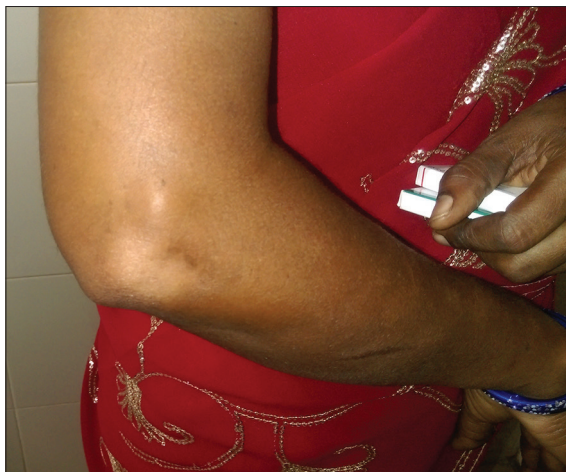

**CONSORT**  
TRANSPARENT REPORTING of TRIALS

Prospective randomized placebo controlled study to evaluate the efficacy of platelet rich plasma to treat tennis elbow



**Figure 4:** CONSORT diagram (flow chart) of the study



**Figure 5:** Clinical photograph showing depigmentation and subdermal atrophy with steroid

available for treatment of tennis elbow, PRP injection has been shown to be a promising option in various multicenter studies. However, there are conflicting reports that state that PRP might not be as effective as predicted.

Krogh *et al.* in their study concluded that at 3-month followup, there was no significant reduction in pain in any of the three groups. A greater decrease in tendon thickness was seen in the glucocorticoid group. The glucocorticoid group also showed a greater decrease in Doppler activity. The injection of PRP was the most painful.<sup>19</sup> However, Brkljac *et al.* in their study concluded that an injection of PRP improves pain and function in patients suffering from LE where conservative management has failed.<sup>20</sup> Similarly, Raeissadat *et al.* in their study found that PRP and autologous whole blood injections are both effective

methods to treat chronic LE and their efficacy persisted during long term followup. PRP was not superior to AWB in long term followup.<sup>21</sup> Peerbooms *et al.* in their study after 1-year followup found that treatment of patients with chronic LE with PRP reduces pain and significantly increases function, exceeding the effect of corticosteroid injection.<sup>22</sup> Gosens *et al.* in their study concluded that treatment of patients with chronic LE with PRP reduces pain and increases function significantly, exceeding the effect of corticosteroid injection even after a followup of 2 years. There were no complications related to the use of PRP.<sup>23</sup> Arirachakaran *et al.* in their study concluded that PRP injection can improve pain and lower the risk of complications, whereas autologous blood injection can improve pain, disabilities scores, and pressure pain threshold but has a higher risk of complications.<sup>24</sup>

In our study, we found that at 12-week followup, the pain relief was better in both PRP and corticosteroid injection groups as compared with the normal saline group, but at 24-week followup, the pain relief was maintained better with PRP than corticosteroid. Patients who had received steroid were asymptomatic at 3-month followup, but at

6-month followup, 33.33% patients complained of a recurrence of pain symptoms that was more than 50% of the initial VAS and FPS score. In PRP group, only 13.33% of patients were symptomatic with VAS score and FPS score more than 50% of the initial value. The difference between PRP and corticosteroid injections was statistically significant.

Krogh *et al.* in their study concluded that the injection of PRP was the most painful.<sup>19</sup> Mishra and Pavelko in their study concluded that treatment of patients with chronic elbow tendinosis with buffered PRP reduced pain significantly. They initially injected bupivacaine with epinephrine into the skin and subcutaneous tissue as a local field block and then 0.5 mL directly into the area of maximum tenderness. Then, 2–3 mL PRP was injected using a 22-gauge needle into the common extensor tendon using a peppering technique. This technique involved a single skin portal and then five penetrations of the tendon.<sup>25</sup>

In our study, we used 2% Xylocaine local infiltration before injection in all three groups and injection was given at the common extensor tendon using peppering technique.

**Table 5: Mann-Whitney U-test ranks to compare visual analogue scale and facial pain scale between platelet-rich plasma as one and placebo as three**

Scores	Injection given	n	Mean rank	Sum of ranks
VAS score day 0	1	30	32.48	974.50
	3	30	28.52	855.50
	Total	60		
VAS score 12 weeks	1	30	17.08	512.50
	3	30	43.92	1317.50
	Total	60		
VAS score 24 weeks	1	30	16.83	505.00
	3	30	44.17	1325.00
	Total	60		
FPS day 0	1	30	30.87	926.00
	3	30	30.13	904.00
	Total	60		
FPS 12 weeks	1	30	16.30	489.00
	3	30	44.70	1341.00
	Total	60		
FPS 24 weeks	1	30	16.40	492.00
	3	30	44.60	1338.00
	Total	60		

VAS=Visual analogue scale, FPS=Facial pain scale

**Table 6: Mann-Whitney U-test statistics to compare visual analogue scale and facial pain scale between platelet-rich plasma and placebo (Grouping variable: Injection given)**

Test parameters	VAS			FPS		
	Day 0	12 weeks	24 weeks	Day 0	12 weeks	24 weeks
Mann-Whitney U-test	390.500	47.500	40.000	439.000	24.000	27.000
Wilcoxon W	855.500	512.500	505.000	904.000	489.000	492.000
Z	-0.933	-6.108	-6.217	-0.178	-6.535	-6.485
Asymptomatic significant (two-tailed)	0.351	<0.001	<0.001	0.858	<0.001	<0.001

VAS=Visual analog scale, FPS=Facial pain scale

Table 7: Summary of P values among different pairs of groups

Dependent variable	Group (I)	Group (J)	Mean difference (I--J)	SE	P
VAS score 12 weeks	PRP	TRICORT	-0.300	0.487	0.812
		NS	-4.233	0.487	<0.001*
	TRICORT	PRP	0.300	0.487	0.812
		NS	-3.933	0.487	<0.001*
	NS	PRP	4.233	0.487	<0.001*
VAS score 24 weeks	PRP	TRICORT	3.933	0.487	<0.001*
		NS	-1.833	0.520	0.002*
	TRICORT	PRP	1.833	0.520	0.002*
		NS	-2.600	0.520	<0.001*
	NS	PRP	4.433	0.520	<0.001*
FPS 12 weeks	PRP	TRICORT	2.600	0.520	<0.001*
		NS	-0.733	0.484	0.289
	TRICORT	PRP	0.733	0.484	0.289
		NS	-3.833	0.484	<0.001*
	NS	PRP	4.567	0.484	<0.001*
FPS 24 weeks	PRP	TRICORT	3.833	0.484	<0.001*
		NS	-2.167	0.477	<0.001*
	TRICORT	PRP	2.167	0.477	<0.001*
		NS	-2.667	0.477	<0.001*
	NS	PRP	4.833	0.477	<0.001*
		TRICORT	2.667	0.477	<0.001*

\*Significant P values. PRP=Platelet-rich plasma, SE=Standard error, FPS=Facial pain scale

Injections were given carefully to avoid directly injecting into the tendon. None of the patient reported pain after PRP injection in our study.

Gautam *et al.* concluded that PRP appeared to enable biological healing of the lesion, whereas corticosteroid appeared to provide short term, symptomatic relief but resulted in tendon degeneration.<sup>26</sup> Park *et al.* in their study concluded that 1.3%–4% people develop hypopigmentation which develops over the initial 1–4 months after the injection and resolves spontaneously over 6–30 months. It can be prevented if intradermal and subcutaneous injections are avoided. Subcutaneous fat atrophy is known to last for 6–12 months after corticosteroid injection, and it is known to be reversible and resolved within 1 year.<sup>27</sup> Our study found that 13 patients out of the thirty patients who received corticosteroid suffered from hypopigmentation at injection site, and three patients suffered from subdermal atrophy. The limitation of the study is that sample size needed for the study was not calculated.

## CONCLUSION

The efficacy of single injection of PRP to relieve the pain of tennis elbow is better than triamcinolone or placebo over a short term followup period. However, still more studies are required at different centers by different research groups to establish the efficacy of PRP over long term followup

period, and multicenter randomized controlled trial would further strengthen evidence-based practice in treatment of LE or tennis elbow.

## Financial support and sponsorship

Nil.

## Conflicts of interest

There are no conflicts of interest.

## REFERENCES

- Allander E. Prevalence, incidence, and remission rates of some common rheumatic diseases or syndromes. *Scand J Rheumatol* 1974;3:145-53.
- Chard MD, Hazleman BL. Tennis elbow – A reappraisal. *Br J Rheumatol* 1989;28:186-90.
- Verhaar JA. Tennis elbow. Anatomical, epidemiological and therapeutic aspects. *Int Orthop* 1994;18:263-7.
- Hamilton PG. The prevalence of humeral epicondylitis: A survey in general practice. *J R Coll Gen Pract* 1986;36:464-5.
- Kivi P. The etiology and conservative treatment of humeral epicondylitis. *Scand J Rehabil Med* 1983;15:37-41.
- Major HP. Lawn tennis elbow. *BMJ* 1883;2:557.
- Kraushaar B, Nirschl R. Tendinosis of the elbow (tennis elbow): Clinical features and findings of histological, immunohistochemical and electron microscopic studies. *JBJS* 1999;81A: 259.
- Nirschl RP, Pettrone F. Tennis elbow: The surgical treatment of lateral epicondylitis. *JBJS* 1979;61A: 832.

9. Brummel J, Baker CL 3<sup>rd</sup>, Hopkins R, Baker CL Jr. Epicondylitis: Lateral. *Sports Med Arthrosc* 2014;22:e1-6.
10. Nirschl RP, Ashman ES. Elbow tendinopathy: Tennis elbow. *Clin Sports Med* 2003;22:813-36.
11. Walz DM, Newman JS, Konin GP, Ross G. Epicondylitis: Pathogenesis, imaging, and treatment. *Radiographics* 2010;30:167-84.
12. Saccomanni B. Corticosteroid injection for tennis elbow or lateral epicondylitis: A review of the literature. *Curr Rev Musculoskelet Med* 2010;3:38-40.
13. Edwards SG, Calandruccio JH. Autologous blood injections for refractory lateral epicondylitis. *J Hand Surg Am* 2003;28:272-8.
14. Chung B, Wiley JP. Effectiveness of extracorporeal shock wave therapy in the treatment of previously untreated lateral epicondylitis: A randomized controlled trial. *Am J Sports Med* 2004;32:1660-7.
15. Galvin R, Callaghan C, Chan WS, Dimitrov BD, Fahey T. Injection of botulinum toxin for treatment of chronic lateral epicondylitis: Systematic review and meta-analysis. *Semin Arthritis Rheum* 2011;40:585-7.
16. Tosun HB, Gumustas S, Agir I, Uludag A, Serbest S, Pepele D, *et al.* Comparison of the effects of sodium hyaluronate-chondroitin sulphate and corticosteroid in the treatment of lateral epicondylitis: A prospective randomized trial. *J Orthop Sci* 2015;20:837-43.
17. Lubkowska A, Dolegowska B, Banfi G. Growth factor content in PRP and their applicability in medicine. *J Biol Regul Homeost Agents* 2012;26 2 Suppl 1:3S-22S.
18. Ahmad Z, Brooks R, Kang SN, Weaver H, Nunney I, Tytherleigh-Strong G, *et al.* The effect of platelet-rich plasma on clinical outcomes in lateral epicondylitis. *Arthroscopy* 2013;29:1851-62.
19. Krogh TP, Fredberg U, Stengaard-Pedersen K, Christensen R, Jensen P, Ellingsen T. Treatment of lateral epicondylitis with platelet-rich plasma, glucocorticoid, or saline: A randomized, double-blind, placebo-controlled trial. *Am J Sports Med* 2013;41:625-35.
20. Brkljac M, Kumar S, Kalloo D, Hirehal K. The effect of platelet-rich plasma injection on lateral epicondylitis following failed conservative management. *J Orthop* 2015;12 Suppl 2:S166-70.
21. Raeissadat SA, Rayegani SM, Hassanabadi H, Rahimi R, Sedighipour L, Rostami K. Is Platelet-rich plasma superior to whole blood in the management of chronic tennis elbow: One year randomized clinical trial. *BMC Sports Sci Med Rehabil* 2014;6:12.
22. Peerbooms JC, Sluimer J, Bruijn DJ, Gosens T. Positive effect of an autologous platelet concentrate in lateral epicondylitis in a double-blind randomized controlled trial: Platelet-rich plasma versus corticosteroid injection with a 1-year followup. *Am J Sports Med* 2010;38:255-62.
23. Gosens T, Peerbooms JC, van Laar W, den Ouden BL. Ongoing positive effect of platelet-rich plasma versus corticosteroid injection in lateral epicondylitis: A double-blind randomized controlled trial with 2-year followup. *Am J Sports Med* 2011;39:1200-8.
24. Arirachakaran A, Sukthuyat A, Sisayanarane T, Laoratanavoraphong S, Kanchanatawan W, Kongtharvonskul J. Platelet-rich plasma versus autologous blood versus steroid injection in lateral epicondylitis: Systematic review and network meta-analysis. *J Orthop Traumatol* 2016;17:101-12.
25. Mishra A, Pavelko T. Treatment of chronic elbow tendinosis with buffered platelet-rich plasma. *Am J Sports Med* 2006;34:1774-8.
26. Gautam VK, Verma S, Batra S, Bhatnagar N, Arora S. Platelet-rich plasma versus corticosteroid injection for recalcitrant lateral epicondylitis: Clinical and ultrasonographic evaluation. *J Orthop Surg (Hong Kong)* 2015;23:1-5.
27. Park SK, Choi YS, Kim HJ. Hypopigmentation and subcutaneous fat, muscle atrophy after local corticosteroid injection. *Korean J Anesthesiol* 2013;65 6 Suppl: S59-61.