

# MRI diagnosis in multiligamentous injuries of knee with associated dislocations and neurovasacular sequelae: a retrospective analysis of injury patterns

Reddy Ravikanth<sup>a</sup>, Manu J. Abraham<sup>b</sup>, Anoop Pilar<sup>b</sup>, Ashok Alapati<sup>b</sup>

<sup>a</sup>Department of Radiology, Holy Family Hospital, Thodupuzha, <sup>b</sup>Department of Orthopaedics, St John's Medical College, Bangalore, India

Correspondence to Reddy Ravikanth, MD, Department of Radiology, Holy Family Hospital, Thodupuzha 685605, India.  
Tel: +91-9074738884; fax: 04862-221061; e-mail: ravikanthreddy06@gmail.com

Received 12 March 2019

Accepted 17 June 2019

**Egyptian Rheumatology & Rehabilitation**  
2019, 46:278–284

## Background

Simultaneous injury of two or more knee ligaments with concurrent tears involving the anterior cruciate and medial collateral ligaments is considered to be associated with femorotibial knee dislocations (KD). The purpose of this study is to characterize multiligamentous knee injury patterns associated with dislocations on MRI and to describe the incidence of their sequelae such as tibial plateau fractures, peroneal nerve injuries, and posterolateral corner (PLC) injuries.

## Participants and methods

After obtaining institutional ethical committee approval, we retrospectively identified 108 multiligamentous knee injuries in 100 patients who met with trauma and were treated at our tertiary care center between April 2014 and December 2018. Descriptive statistics were reported using numbers and percentages for categorical variables in cases of multiligamentous injuries, ipsilateral tibial plateau fractures, ipsilateral femoral fractures, peroneal nerve injury, arterial injury, compartment syndrome, and PLC injuries.

## Results

The most common (39.8%) injury pattern was a combined disruption of the anterior cruciate ligament, posterior cruciate ligament, and PLC. Schenck KD III-M was the most common injury type in KD, constituting 16.7%. Medial-sided injuries were the most common injury patterns seen with KD. There was a significant risk of peroneal nerve injury with lateral-sided injuries.

## Conclusion

KD, though rare, may have devastating clinical sequelae such as compartment syndrome if not recognized and treated. Therefore, it is necessary to recognize imaging findings of femorotibial joint dislocations and associated injuries to the adjacent neurovascular bundles.

## Keywords:

anterior cruciate ligament, dislocation, femorotibial dislocation, knee MRI, multiligamentous injury, posterior cruciate ligament, posterolateral corner, posteromedial corner

Egypt Rheumatol Rehabil 46:278–284

© 2019 Egyptian Society for Rheumatology and Rehabilitation  
1110-161X

## Introduction

Multiligamentous knee injuries are sometimes isolated but more often are the result of high-energy trauma and as such have various comorbidities (Fig. 1). Recent reports have suggested that similar injury patterns are associated with vascular injury and peroneal nerve palsy in 19 and 20% of patients, respectively, and were done in small numbers of participants, which reported wide variations in the rates of associated injuries [1]. Fractures in association with knee dislocations (KD) have been reported to be as high as 60% in patients with high-energy injuries, with 41% noted to have multiple fractures of the extremities [2]. According to previous studies, the incidence of multiligamentous knee injuries ranges from 0.001 to 0.013% in all patients evaluated for orthopedic injuries [3]. There is a surge in numbers from recent years, likely because of the improved survival of the critically injured trauma patient and the increased awareness of ligamentous

injuries [4]. Bicrociate ligament injuries have been reported to be equivalent to KD regarding frequency of major arterial injuries, the mechanism of injury, and severity of ligamentous injury. A missed diagnosis of KD can result in increased morbidity and risk of limb loss [5].

## Anterior cruciate ligament

Approximately 70% of anterior cruciate ligament (ACL) injuries have a noncontact mechanism [6]. The classic history of the noncontact injury involves a sudden deceleration, hyperextension, or twist, accompanied by a 'pop', significant pain, and subsequent swelling of the knee. The mechanism

This is an open access journal, and articles are distributed under the terms of the Creative Commons Attribution-NonCommercial-ShareAlike 4.0 License, which allows others to remix, tweak, and build upon the work non-commercially, as long as appropriate credit is given and the new creations are licensed under the identical terms.

Figure 1

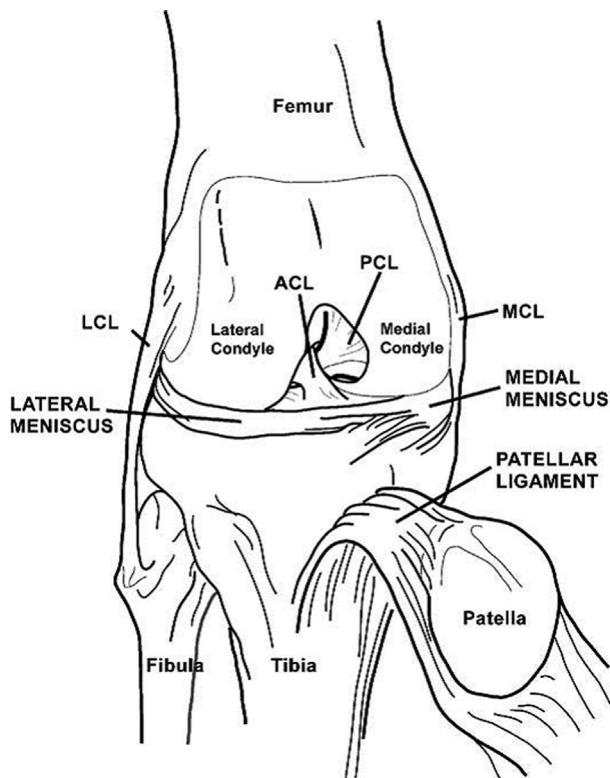


Illustration demonstrating the knee anatomy. ACL, anterior cruciate ligament; LCL, lateral collateral ligament; MCL, medial collateral ligament; PCL, posterior cruciate ligament.

most commonly involves a valgus stress. This cascade of movements occurs when an athlete performs a straight-leg landing or a one-step stop with the knee hyperextended. ACL and posterior cruciate ligament (PCL) injuries rarely occur in isolation and are often associated with injuries to the secondary/supporting ligamentous structures that provide both static and dynamic stability against rotational forces.

#### Posterior cruciate ligament

The two most common mechanisms of PCL tear injury are forced hyperflexion and sustaining a posterior blow to the proximal tibia. Forced hyperflexion is the most common mechanism for an isolated PCL injury. During hyperflexion, the anterolateral component comes under increasing tension with knee flexion. The posteromedial component usually remains intact. A posterior blow to the proximal tibia of a flexed knee occurs with dashboard injuries to the knee during motor vehicle accidents causing to fall on a flexed knee. Hyperextension, most often is associated with a varus or valgus force, can also cause PCL injury.

#### Posterolateral corner injury

Posterolateral corner (PLC) injuries result in posterolateral rotational instability; they rarely

Table 1 Components of posterolateral corner

Popliteus tendon and muscle complex	Dynamic stabilizer
Fibular collateral ligament	Static stabilizer
Arcuate ligament	Static stabilizer
Fabellofibular ligament	Static stabilizer
Posterolateral joint capsule	Static stabilizer
Popliteofibular ligament	Static stabilizer

Table 2 Mechanisms of posterolateral corner injury

Direct blow to anteromedial tibia
External rotation hyperextension
Dashboard injury/high-velocity trauma

occur in isolation [7]. PLC injuries often occur in combination with cruciate ligament disruption, and they are most commonly associated with PCL injury (Table 1). Posterolateral instability is characterized by posterior subluxation and external rotation of the tibial plateau in relation to the femur. Therefore, a PCL injury necessitates careful scrutiny of the PLC structures on MRI. In the setting of trauma, PLC injury is most commonly caused by a direct blow at the anteromedial proximal tibia with a posterolateral force vector and knee in near full extension (Table 2). PLC injury is also seen with high-velocity trauma such as a complete KD. Bone marrow edema at the styloid process of the fibular head without fracture on MRI also warrants close investigation of the PLC structures for associated injury.

#### Posteromedial corner injury

The posteromedial corner (PMC) consists of ligamentous, meniscal, and myotendinous components that provide both static and dynamic constraint of anteromedial tibial rotation, in addition to secondary restraint of anterior tibial translation. The tendinous and ligamentous anatomy of the PMC, though complex, can be consistently identified on routine MRI. The PMC consists of the following structures: the oblique popliteal ligament, semimembranosus tendon, posteromedial capsule, posterior oblique ligament, deep components of the medial collateral ligament (MCL) complex, and the posterior horn of the medial meniscus (Table 3). PMC injuries occur most often during sports-related activities and are frequently overlooked, both clinically and at initial imaging, because they are often overshadowed by the more obvious cruciate and collateral ligamentous injuries. PMC injuries occur in combination with PCL injury, combined PCL and ACL injuries, ACL injury, MCL injury, and O'Donoghue's triad of ACL, MCL, and medial meniscal injury.

**Table 3 Components of posteromedial corner**

Oblique popliteal ligament	Static stabilizer
Semimembranosus tendon and aponeurotic expansions ligament	Dynamic stabilizer
Posteromedial capsule	Static stabilizer
Posterior oblique ligament	Static stabilizer
Posterior horn medial meniscus	Static stabilizer
Deep components of medial collateral ligament complex (meniscolfemoral and meniscotibial)	Static stabilizer

**Table 4 Schenck classification of knee dislocations**

KD I	Multiligamentous injury with the involvement of the ACL or PCL
KD II	Injury to ACL and PCL only (two ligaments)
KD III	Injury to ACL, PCL, and PMC or PLC (three ligaments). KD III-M (ACL, PCL, and MCL) and KD III-L (ACL, PCL, PLC, and LCL)
KD IV	Injury to ACL, PCL, PMC, and PLC (four ligaments) KD IV has the highest rate of vascular injury (5–15%) based on Schenck classification
KD V	Multiligamentous injury with periarticular fracture

ACL, anterior cruciate ligament; KD, knee dislocation; LCL, lateral collateral ligament; PCL, posterior cruciate ligament; PMC, posteromedial corner; PLC, posterolateral corner.

### Femorotibial joint dislocations

Kennedy [8] classified femorotibial joint dislocations based on the position of the tibia with respect to the femur. Anterior, posterior, medial, lateral, and rotary femorotibial dislocations may occur. Rotary femorotibial dislocations are further subdivided to include anteromedial, posteromedial, anterolateral, and posterolateral directions. Schenck *et al.* [9], classified KD by ligamentous involvement. French Society of Orthopedic Surgery and Traumatology Symposium in 2009 [10] described a pathophysiologic approach to the classification, which covers the full range of complex ligamentous lesions occurring in KDs. As per this classification, there are two types of mechanism of injury, which can be evaluated through dynamic and static imaging. The first mechanism of injury, gaping, is a low-energy mechanism without weight bearing in the knee that results in ligament tear. The second mechanism of injury, translation, is a low-energy mechanism with weight bearing in the knee that results in ligamentous detachment. When only a single mechanism is involved, the lesion is classified as simple [11]. Simple translation results in pure anterior or posterior dislocation, whereas simple gaping results in both cruciate ligament lesions [12]. These mechanisms can also occur in combination during high-energy injuries and result in dislocation with peripheral tearing of ligaments.

### Purpose of study

The purpose of this study is to characterize multiligamentous knee injury patterns associated with dislocations on MRI and to describe the

incidence of their sequelae such as tibial plateau fractures, peroneal nerve injuries, and PLC injuries. We have described the mechanism of injury, ligamentous disruptions, and imaging findings of various types of KDs including injuries of the femorotibial, proximal tibiofibular, and patellofemoral joints. A step-by-step approach has been performed to evaluate the following: fractures and bone contusions – effusion and capsular disruption – cruciates – collaterals – menisci – extensor mechanism – posterior, lateral, and medial corner – cartilage – soft tissue. The MRI sequences the authors have used in such assessments were coronal and sagittal proton density, along with fat-suppressed sagittal and axial proton density/T2-weighted images.

## Participants and methods

### Participants

After obtaining institutional ethical committee approval, we retrospectively identified 108 multiligamentous knee injuries in 100 patients who were treated at our tertiary care center between April 2014 and December 2018.

### Inclusion criteria

In this study, the inclusion criteria were multiligamentous injuries to the ACL, PCL, or collateral ligaments and associated KDs on MRI, according to the classification of Schenck [9] (KD II, KD III, and KD IV; Table 4).

### Exclusion criteria

The exclusion criteria were severe intra-articular fractures of the ipsilateral knee and skeletal immaturity.

### Evaluation

We verified multiligamentous injuries by MRI with clinical and surgical findings by fellowship-trained orthopedic specialists. All MRI studies were reviewed and confirmed by a senior radiologist. If discrepancies were noted, we took both MRI and surgical findings into consideration, acknowledging the fact that MRI does not necessarily differentiate between severe ligamentous sprain and discontinuity. MRI included T1-weighted and T2-weighted axial, coronal, and sagittal views and were evaluated for

ligamentous injuries, fracture patterns, and associated KD when assessing ligamentous injury patterns. MRI studies were obtained and evaluated when examination findings suggested KDs or multiligamentous knee injury.

#### Data collection

Data were obtained from the medical records of all 108 knees by using a predefined protocol that included orthopedic examinations, MRI findings, operative notes, and progress notes throughout the hospital course. Demographic information, arterial injuries, nerve injuries, associated fracture patterns, and KDs were recorded from initial evaluation.

#### Statistical analysis

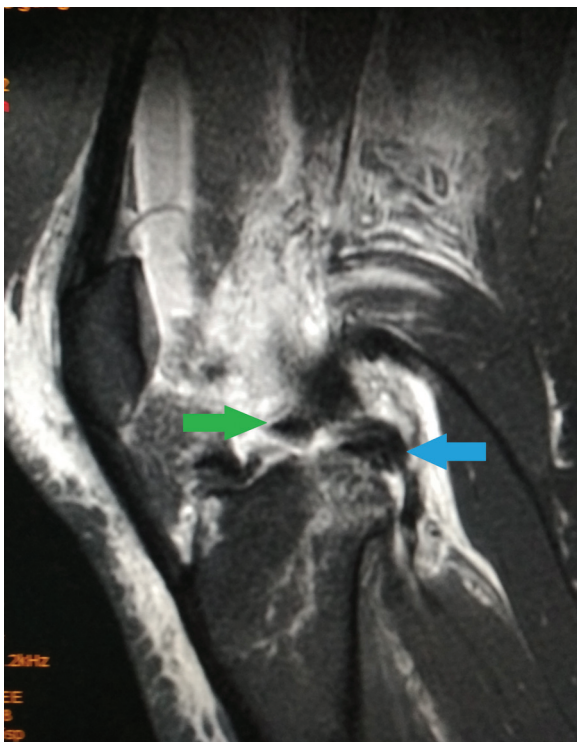
Descriptive statistics were reported using numbers and percentages for categorical variables in cases of multiligamentous injuries, ipsilateral tibial plateau fractures, ipsilateral femoral fractures, peroneal nerve injury, arterial injury, compartment syndrome, and PLC injuries.

### Results

A total of 108 multiligamentous knee injuries in 100 patients who met with trauma during the 4.5 years

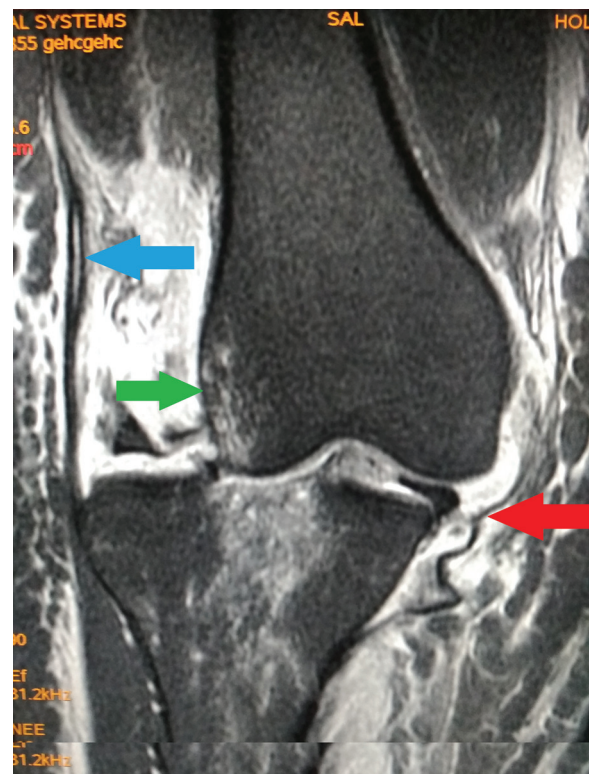
period were evaluated in our tertiary care center. The right knee was affected in 44 of the 100 study patients, the left knee was affected in 56, and bilateral knee injuries occurred in eight. Moreover, 70 patients were male and 30 were female. The average age of the patients was 32 years (range: 18–86 years). The most common (39.8%) injury pattern was a combined disruption of the ACL, PCL, and PLC (Figs 2 and 3). Overall, 30% of knees had associated ipsilateral tibial plateau fractures, and 20% had associated ipsilateral femoral fractures (Figs 4 and 5). Peroneal nerve injury occurred in 30% of knees, arterial injury in 20%, and compartment syndrome in 18%. The incidences of ligamentous injury based on MRI findings were as follows: ACL, 89.8% (97 of 108 extremities); PCL, 79.6% (86 of 108 extremities); PLC, 75.9% (82 extremities); and MCL, 26.8% (29 extremities). The noted injury patterns in multiligamentous knee injuries are shown in Table 5. The injury patterns associated with peroneal nerve injury are noted in Table 6. Peroneal nerve injuries were associated with PLC injuries in 87.5% of cases (28 of 32 knees). Further analysis of the specific injured structures showed that the lateral collateral ligament was involved 93.2% of the time

Figure 2



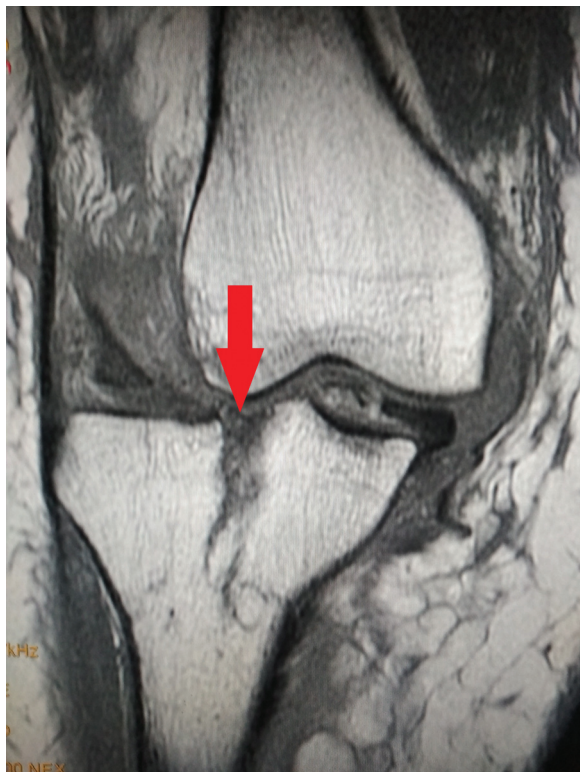Sagittal proton-density FS MRI of the knee joint in a case of multi-ligamentous injury in a 38-year-old woman, demonstrating complete tear of ACL (rightwards arrow) and PCL (leftwards arrow). ACL, anterior cruciate ligament; PCL, posterior cruciate ligament.

Figure 3



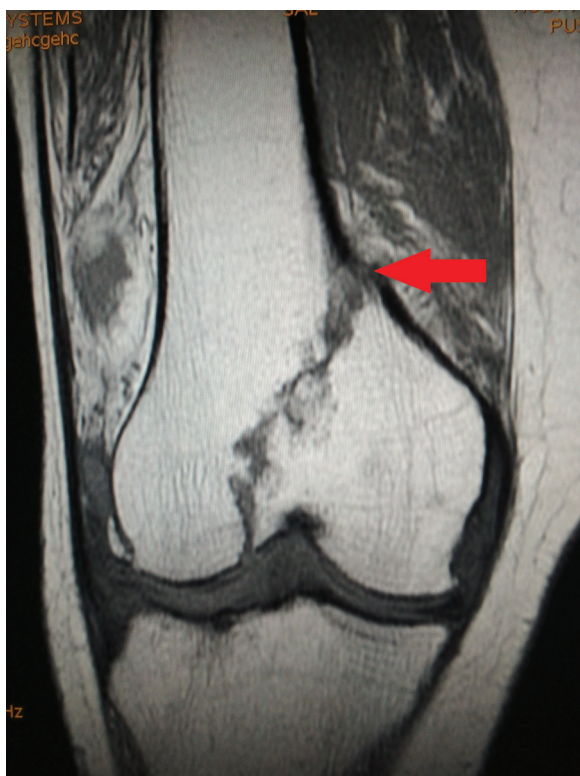
Coronal proton-density FS MRI of the knee joint with trauma demonstrating grade 3 injury of MCL (lower leftwards arrow), partial thickness tear of LCL (upper leftwards arrow), and medial dislocation of femur (rightwards arrow). LCL, lateral collateral ligament; MCL, medial collateral ligament.

Figure 4



Coronal T1-weighted MRI of knee joint demonstrating a Schatzker IV tibial plateau fracture with a depressed component (arrow).

Figure 5



Coronal T1-weighted MRI of knee joint in a 71-year-old woman with trauma demonstrating intra-articular distal femoral fracture involving the medial condyle (arrow) with fracture line extending into the lateral condyle suggesting Hoffa fracture.

Table 5 Patterns of multiligamentous knee injury

Injury pattern	N=108 [n (%)]
ACL-PCL-PLC	43 (39.8)
ACL-PLC	19 (17.6)
ACL-PCL-MCL	18 (16.7)
PCL-PLC	9 (3.3)
ACL-PCL-PLC-MCL	6 (5.5)
ACL-PCL	8 (7.4)
ACL-MCL-PLC	3 (2.8)
PCL-MCL-PLC	2 (1.9)

ACL, anterior cruciate ligament; MCL, medial collateral ligament; PCL, posterior cruciate ligament; PLC, posterolateral corner.

Table 6 Injury patterns associated with peroneal nerve injury

Injury pattern	N=32 [n (%)]
ACL-PCL-PLC	16 (50.0)
ACL-PLC	11 (34.4)
ACL-PCL-MCL	3 (9.4)
ACL-PCL	2 (6.3)
ACL-PCL-MCL	1 (3.1)
PCL-PLC	1 (3.1)

ACL, anterior cruciate ligament; MCL, medial collateral ligament; PCL, posterior cruciate ligament; PLC, posterolateral corner.

Table 7 Posterolateral corner injuries

Injury pattern	N=89 [n (%)]
Popliteus-LCL	44 (49.4)
Popliteus-LCL-BF	28 (31.4)
LCL	9 (10.1)
Popliteus	4 (4.5)
LCL-BF	2 (2.2)
BF	2 (2.2)

BF, biceps femoris; LCL, lateral collateral ligament.

Table 8 Injuries to the affected extremity

Injury pattern	N=108 [n (%)]
Peroneal nerve injury	32 (29.6)
Tibial plateau fracture	32 (29.6)
Arterial injury	22 (20.3)
Femoral fracture	22 (20.3)
Compartment syndrome	19 (17.6)

(83 of 89 knees), the popliteus was involved 85.4% of the time (76 of 89 knees), and the biceps femoris was involved 35.9% of the time (32 of 89 knees). PLC injury patterns are shown in Table 7. Overall, 48% of patients presented with dislocated knees, which is consistent with previously reported rates of ~50%. Injuries to the affected extremity are shown in Table 8.

## Discussion

Multiligamentous knee injuries are complex injuries that often require emergent treatment. Multiligamentous injuries have been defined as a complete cruciate tear (grade III) with a partial/

complete tear of medial/lateral collateral (grade II/III) or a partial or complete tear of the other cruciate ligament (grade II or III). KDs remain the most common cause of multiligamentous injuries with various life-threatening and limb-threatening complications occurring with dislocation of the knee. Our findings suggest that multiligamentous knee injuries might be more prevalent than the 0.001–0.013%, as suggested in the literature [3].

The most important finding in this study was injuries with ACL, PCL, and PLC injuries being the commonest, constituting 39.8%, and Schenck KD III-M was the most common injury type in KDs, constituting 16.7%. The mean age at the time of injury was higher (38.5 years) than in previous studies. In our study, injuries with both cruciate ligaments torn and intact collaterals (KD II) were the least common (7.4%). Common peroneal nerve injuries were present in 29.6%, tibial plateau fractures in 29.6%, and vascular injuries in 20.3% of patients in this study. There were significantly greater odds for both common peroneal nerve injuries and popliteal artery injuries with lateral-sided injuries (KD III-L). Additionally, peroneal nerve injury was significantly associated with vascular injury. Medial-sided injuries were the most common injury patterns seen with KDs. There was a significant risk of peroneal nerve injury with lateral-sided injuries. PLC injuries commonly involved popliteus-lateral collateral ligament combination in 49.4% followed by popliteus-lateral collateral ligament-biceps femoris in 31.4%.

Johnson *et al.* [13] conducted a literature review of multiligamentous knee injuries in 2008 and found that up to 86% of KDs occur in male patients with a mean age between 30 and 32 years and that only 5% of patients present with bilateral injuries. These numbers are similar to our findings, with 70% male patients, ages averaging 32 years, and bilateral injuries present in only 8% of patients.

Robertson *et al.* [14], meta-analysis of previous KD studies, found that 41% of patients had ACL, PCL, and MCL injuries. Mechanisms of injury in our study were similar to those of the studies reviewed, and we found that the combined ACL–PCL–PLC injury pattern was the most prevalent (39.8%), with the ACL–PCL–MCL injury pattern accounting for only 16.7% of cases. PLC injuries might have an increased likelihood of being missed and might therefore have been underreported. PLC injuries had a high prevalence in our study and were noted in 75.9% of injured knees (82 of 108 knees) which is much higher than previously reported in the literature.

The peroneal nerve is susceptible to injury because of its relatively fixed position around the neck of the fibula. The incidence of peroneal nerve injuries occurring in association with KDs has been reported to be ~20% [15]. Our results found a higher incidence of peroneal nerve dysfunction at 30%. Similar to our findings, Niall *et al.* [16], in their review of 55 patients, found associated peroneal nerve injuries in 25% of patients with KDs. In this study, peroneal nerve injuries were associated with PLC injuries in 87.5% of cases (28 of 32 knees). Bottomley *et al.* [17] reported that 44% of KDs with avulsion fracture of the fibular head or soft-tissue avulsion from the fibular head had associated peroneal nerve damage. Our findings show that multiligamentous knee injuries are associated with fibular head fractures and bony avulsions 22% of the time (24 of 108 extremities). Fractures are common in association with multiligamentous knee injuries. Lustig *et al.* [18], in a prospective study of KDs and bicruciate knee injuries, found that 34% of patients had multiple fractures and 17% of the dislocations were associated with ipsilateral limb fracture. Overall, 25% (27/108) of the patients in our study sustained ipsilateral extremity fractures. Moreover, 29.6% of affected knees had ipsilateral tibial plateau fractures, and 20.3% had ipsilateral femoral fractures.

Initial trauma evaluation revealed that 48% of our patients presented with dislocated knees. This rate is consistent with previously reported rates of ~50% [19]. These injuries do not always present with gross deformity, which makes understanding their mechanism and injury patterns more important.

## Conclusion

Multiligamentous knee injuries should be closely evaluated at presentation and during the hospital course as they serve as a marker of concomitant trauma to allow for early intervention for limb-threatening emergencies. KDs, though rare, may have devastating clinical sequelae such as compartment syndrome if not recognized and treated. Therefore it is necessary to recognize imaging findings of femorotibial joint dislocations and associated injuries to the adjacent neurovascular bundles.

## Financial support and sponsorship

Nil.

## Conflicts of interest

There are no conflicts of interest.

---

## References

- 1 Rihn JA, Groff YJ, Harner CD, Cha PS. The acutely dislocated knee: evaluation and management. *J Am Acad Orthop Surg* 2004; 12:334–346.
- 2 Becker EH, Watson JD, Dreese JC. Investigation of multiligamentous knee injury patterns with associated injuries presenting at a level I trauma center. *J Orthop Trauma* 2013; 27:226–231.
- 3 Zhang Y, Zhang X, Hao Y, Zhang YM, Wang M, Zhou Y, *et al.* Surgical management of the multiple-ligament injured knee: a case series from Chongqing, China and review of published reports. *Orthop Surg* 2013; 5:239–249.
- 4 Rochecongar G, Plaweski S, Azar M, Demey G, Arndt J, Louis ML, *et al.* French Society for Arthroscopy (Société française d'arthroscopie, SFA). Management of combined anterior or posterior cruciate ligament and posterolateral corner injuries: a systematic review. *Orthop Traumatol Surg Res* 2014; 100:S371–S378.
- 5 Twaddle BC, Bidwell TA, Chapman JR. Knee dislocations: where are the lesions? A prospective evaluation of surgical findings in 63 cases. *J Orthop Trauma* 2003; 17:198–202.
- 6 Cook S, Ridley TJ, McCarthy MA, Gao Y, Wolf BR, Amendola A, *et al.* Surgical treatment of multiligament knee injuries. *Knee Surg Sports Traumatol Arthrosc* 2015; 23:2983–2991.
- 7 Chahla J, Moatshe G, Dean CS, LaPrade RF. Posterolateral corner of the knee: current concepts. *Arch Bone Jt Surg* 2016; 4:97–103.
- 8 Kennedy JC. Complete dislocation of the knee joint. *J Bone Joint Surg Am* 1963; 45:889–904.
- 9 Schenck RC, Hunter RE, Ostrum RF, Perry CR. Knee dislocations. *Instr Course Lect* 1999; 48:515–522.
- 10 Boisgard S, Versier G, Descamps S, Lustig S, Trojani C, Rosset P, *et al.* Bicuruciate ligament lesions and dislocation of the knee: mechanisms and classification. *Orthop Traumatol Surg Res* 2009; 95:627–631.
- 11 Ríos A, Villa A, Fahandezh H, de José C, Vaquero J. Results after treatment of traumatic knee dislocations. A report of 26 cases. *J Trauma* 2003; 55:489–494.
- 12 Sisto DJ, Warren RF. Complete knee dislocation. A follow-up study of operative treatment. *Clin Orthop Relat Res* 1985; 198:94–101.
- 13 Johnson ME, Foster L, DeLee JC. Neurologic and vascular injuries associated with knee ligament injuries. *Am J Sports Med* 2008; 36:2448–2462.
- 14 Robertson A, Nutton RW, Keating JF. Dislocation of the knee. *J Bone Joint Surg Br* 2006; 88:706–711.
- 15 Baltodano PA, Tong AJ, Chhabra A, Rosson GD. The role of magnetic resonance neurography in the postoperative management of peripheral nerve injuries. *Neuroimaging Clin N Am* 2014; 24:235–244.
- 16 Niall DM, Nutton RW, Keating JF. Palsy of the common peroneal nerve after traumatic dislocation of the knee. *J Bone Joint Surg Br* 2005; 87B:664–667.
- 17 Bottomley N, Williams A, Birch R, Noorani A, Lewis A, Lavelle J. Displacement of the common peroneal nerve in posterolateral corner injuries of the knee. *J Bone Joint Surg Br* 2005; 87:1225–1226.
- 18 Lustig S, Leray E, Boisrenoult P, Trojani C, Laffargue P, Saragaglia D, *et al.* Dislocation and bicruciate lesions of the knee. Epidemiology and acute stage assessment in a prospective series. *Orthop Traumatol Surg Res* 2009; 95:614–620.
- 19 Stannard JP, Bauer KL. Current concepts in knee dislocations: PCL, ACL, and medial sided injuries. *J Knee Surg* 2012; 25:287–294.