

Original Article

Early results of an intraosseous device for arthrodesis of the hallux metatarsophalangeal joint

Efstathios Drampalos, Shen Hwa Vun, Levent Bayam, Irfan Fayyaz

ABSTRACT

Background: Arthrodesis of the hallux metatarsophalangeal (MTP) joint is commonly done as a primary procedure either to correct severe hallux valgus deformities or for rheumatoid arthritis, hallux rigidus, in patients with neuromuscular disorders and as a salvage procedure for failed bunion surgery or infection. Prominent metalwork frequently can cause soft tissue impingement and thus require removal. In contrast, osteosynthesis with a completely intraosseous implant has the advantage of less damage to the periosteal circulation. We describe a surgical technique and the early results of arthrodesis of the hallux metatarsophalangeal (MTP) joint using an intraosseous fixation device.

Materials and Methods: Twelve consecutive patients operated with this method were retrospectively reviewed. The average age was 57 years (range 44–88 years). A retrospective review of radiographs and electronic medical notes was conducted. The patients were also asked to fill a satisfaction questionnaire.

Results: Overall fusion rate was 91% with a mean hallux valgus angle of 15° (range 4–20°) and a mean dorsiflexion angle of 20° (range 7–30°). Complications included a case of failed fusion, a delayed union, and a case of persisting transfer metatarsalgia. At a mean followup of 14 months (range 5–28 months), the mean visual analog scale improved significantly from a mean of 8.4 (range 7–10) preoperatively, to a mean of 3.1 (range 0–7) postoperatively ($P < 0.0001$). The mean American Orthopaedic Foot and Ankle Society hallux score also significantly improved from 29.4 (range 10–54) to a mean of 73.3 (range 59–90) ($P < 0.0001$). The final result was satisfactory for 83% of the patients.

Conclusions: The early results show intraosseous fixation to be a safe and efficient method for the fusion of the hallux MTP joint providing relief from pain and patient satisfaction.

Key words: Hallux valgus, intraosseous fixation, metatarsophalangeal fusion, metatarsophalangeal joint arthrodesis

MeSH terms: Hallux valgus, arthrodesis, foot deformities

INTRODUCTION

Arthrodesis of the hallux metatarsophalangeal (MTP) joint is commonly used as a primary procedure either to correct severe hallux valgus deformities or for rheumatoid arthritis, hallux rigidus, in patients with neuromuscular disorders and as a salvage procedure for failed bunion surgery or infection.^{1–5} The rationale is to preserve the length of the first metatarsal and provide

stability of the first ray so that weight can be transferred to the hallux. Independently from the technique used a stable fixation is of paramount importance to achieve fusion.^{6,7} Furthermore, prominent metalwork frequently can cause soft tissue impingement and thus require removal.⁸ In contrast, osteosynthesis with a completely intraosseous implant has the advantage of less damage to the periosteal circulation⁹ and a reduced risk of soft tissue irritation. The purpose of this study was to retrospectively evaluate the early results of patients treated with hallux MTP joint arthrodesis using an intraosseous fixation device (IO FiX, Extremity Medical™, Parsippany, NJ, USA), a construct consisting of a lag

Department of Orthopaedics, Manchester Royal Infirmary, Manchester, UK

Address for correspondence: Dr. Efstathios Drampalos, Department of Trauma and Orthopaedic, Manchester Royal Infirmary, Oxford Road, Manchester M13 9WL, UK.
E-mail: edrampalos@yahoo.gr

Access this article online

Quick Response Code:



Website:
www.ijonline.com

DOI:
10.4103/0019-5413.205689

This is an open access article distributed under the terms of the Creative Commons Attribution-NonCommercial-ShareAlike 3.0 License, which allows others to remix, tweak, and build upon the work non-commercially, as long as the author is credited and the new creations are licensed under the identical terms.

For reprints contact: reprints@medknow.com

How to cite this article: Drampalos E, Vun SH, Bayam L, Fayyaz I. Early results of an intraosseous device for arthrodesis of the hallux metatarsophalangeal joint. *Indian J Orthop* 2017;51:299-303.

screw in combination with a second screw with an eyelet called X-post [Figure 1].

Implant specifications

There are two different sizes of post with an eyelet available for the hallux MTP joint. The two posts of 4.6 and 6.6 mm head diameter are to be used with a 0.9 and 1.6 mm diameter guidewire, respectively. The minor (core) diameter of the 4.6 mm post is 3 mm and the major (outside) diameter is 4 mm. The minor (core) diameter of the 6.6 mm post is 3.4 mm and the major (outside) diameter is 5 mm [Table 1].

There are also two different sizes of lag screw of 3.0 and 4.0 mm head diameter, respectively. The minor diameter of the 3.0 mm lag screw is 2.1 mm and the major diameter is 3.1 mm. The correspondent diameters for the 4.0 mm lag screw are 3.0 and 4.0 mm [Table 2].

MATERIALS AND METHODS

12 feet in 12 consecutive patients who underwent primary hallux MTP joint fusions performed with the intraosseous

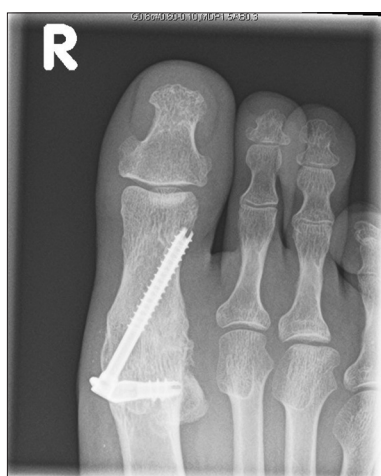


Figure 1: X-ray of fore foot anteroposterior view showing intraosseous fixation device IO FiX that was used for hallux metatarsophalangeal joint fusion

Table 1: X-Post™ specifications

X-Post™ (mm)	Length (mm)	Major diameter (mm)	Minor diameter (mm)
4.6	14, 16, 18	4	3
6.6	15-40 (5 increments)	5	3.4

Table 2: Lag screw specifications

X-Post™ (mm)	Length (mm)	Thread length (standard)	Thread length range (short thread) (mm)	Major diameter (mm)	Minor diameter (mm)
3	20-40 by 2 increments	L - 8	8-12	3.1	2.1
4	20-50	20, 22 mm=L - 12	8-12	4	3
	20-40 by 2 increments 40-50 by 5 increments	24, 50 mm=L - 15			

fixation technique between September 2013 and January 2015 were retrospectively analysed. Patients with available followup until radiographic union had occurred or a decision for revision surgery was made were included in the study. Patients under 18 year age, who underwent revision arthrodesis or primary arthrodesis as a salvage procedure following other operations (i.e., failed bunion correction and hallux varus correction) were excluded. Radiographs and medical records were reviewed retrospectively to identify demographic data, diagnosis, visual analog scale (VAS), the American Orthopaedic Foot and Ankle Society (AOFAS) hallux score, radiologic and clinical union, hallux valgus angle (HA), dorsiflexion angle (DA), complications, and revision surgeries. Patients were also asked to fill outcome assessment scores (AOFAS and VAS) and a subjective satisfaction questionnaire. The indications included severe hallux valgus in seven toes and hallux rigidus in other five toes. The mean age was 57 years (range 44-88 years) including seven female and five male patients.

Radiographic union was evaluated by plain films and considered when there was bony trabeculation crossing the fusion area. HA (between a line parallel to the shaft of the metatarsal and a line parallel to the shaft of the proximal phalanx) and DA (between the axis of the first metatarsal and the axis of the proximal phalanx of the great toe) were measured on standing anteroposterior and lateral radiographs, respectively.

Consent was taken from all patients included in the study. The study was approved by the local Ethical Committee as part of the Clinical Effectiveness and Audit Department (registered number 6649) and was performed in accordance with the ethical standards of the 1964 Declaration of Helsinki as revised in 2000.

Statistical analysis was performed using computer software SPSS for Windows (IBM SPSS Statistics version 19, NY, USA). The Student's *t*-test was used to determine the statistical significance of the difference between the mean preoperative and postoperative value of VAS and AOFAS score. *P* = 0.05 was used for statistical significance level determination.

Operative procedure

A thigh tourniquet was used in each case with the patient under regional or general anesthesia and supine, on a

radiolucent table. A dorsomedial incision was made over the hallux MTP joint protecting the branch of the superficial peroneal nerve. The base of the proximal phalanx and the metatarsal head were exposed with sharp dissection. The articular surfaces were prepared for the fusion with two rasps (Cup and Cone Rasps, Extremity Medical™, Parsippany, NJ, USA). Once the joint was adequately prepared, the MTP joint was provisionally stabilized utilizing a guidewire. The aim was for fusion in 20–25° of dorsiflexion to the inclination angle of the first metatarsal, 15° of valgus and neutral rotation.

The IO FiX™ is a fixed angle device (60°) and the postplacement determines the lag screw trajectory. Preoperatively, the templates provided help determine the optimal size and position construct for the intended application. The appropriate size guidewire is inserted in a medial to lateral fashion into the metatarsal head parallel and in 5–10 mm distance from the joint line. Then, with a depth gauge over the guide wire and down to the bone the length of the desired post to be inserted was determined. The desired size post with an eyelet was placed over the guide wire after drilling and reaming with cannulated instruments (X-Post™, Extremity Medical™, Parsippany, NJ, USA). The post was inserted until flush with cortex facing toward the intended fusion area to optimize the proper trajectory of the lag screw. To gain access to the implant's eyelet, any obstructing bone was removed by using the appropriate size clearing tool. Next, the guidewire for the lag screw was introduced through the eyelet of the post to the appropriate depth and position is verified via fluoroscopy. Measurement of the proper length of the lag screw was done, then pilot drill and finally a lag screw was inserted until tactile compression was felt (Lag Screw, Extremity Medical™, Parsippany, NJ, USA). Intraoperative fluoroscopy was used to evaluate proper implant and bone alignment during the procedure [Figure 2a and b]. The capsule and skin were closed in a routine fashion, and a forefoot compression dressing was placed. Postoperatively, a C-slab is applied, followed by immediate heel weight bearing in stiff soled shoe and after 6–12 weeks, the

patient was allowed for unrestricted activities provided a satisfactory progression of fusion was evident on the followup radiographs.

RESULTS

The mean followup was 15 months (range 5–28 months). Fusion of the MTP joint was obtained in 11 toes (91%) [Figures 3 and 4]. There was one failed fusion, one patient with a delayed union, and a patient who continued to suffer from transfer metatarsalgia after successful fusion. Ten of the 12 toes (83%) had a well aligned hallux. The mean HA was 15° (4–20°) and the mean DA measured was 20° (7–30°).

The AOFAS score improved significantly from a preoperative mean of 29.4 (range 10–54), to a postoperative mean of 73.3 (range 59–90) ($P < 0.0001$), and VAS score improved also significantly from a mean of 8.4 (range 7–10) preoperatively to a mean of 3.1 (range 0–7) postoperatively ($P < 0.0001$). Eleven (91%) patients were able to tolerate conventional or comfort shoes. Ten (83%) of the patients were satisfied with the final outcome and mentioned that they would have the procedure again or would recommend the procedure to a friend or a relative [Table 3].

DISCUSSION

Fusion of the hallux MTP joint is a commonly performed procedure with several different techniques having been

Table 3: Results of physical and subjective evaluation

Parameter	Preoperative	Postoperative	P
AOFAS (range)	29.4 (10-54)	73.3 (59-90)	<0.0001
VAS (range)	8.4 (7-10)	3.0 (0-7)	<0.0001
Percentage of satisfied		83	

AOFAS=American Orthopaedic Foot and Ankle Society, VAS=Visual analog scale

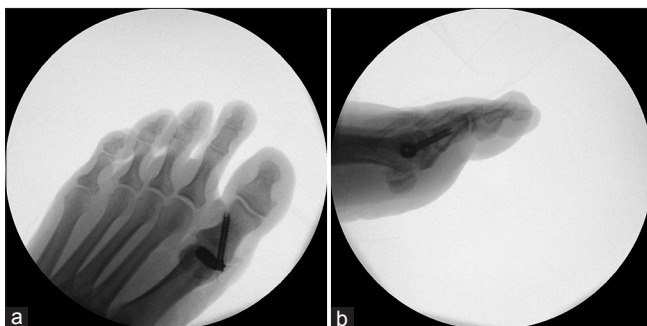


Figure 2: (a and b) Intraoperative fluoroscopy pictures used to evaluate proper implant and bone alignment during the procedure

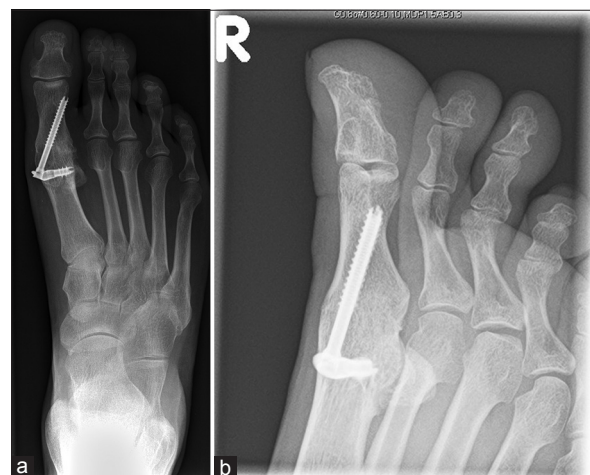

Figure 3: X-ray of foot anteroposterior and oblique views (a and b) showing final assessment of a patient with hallux rigidus treated with an intraosseous implant

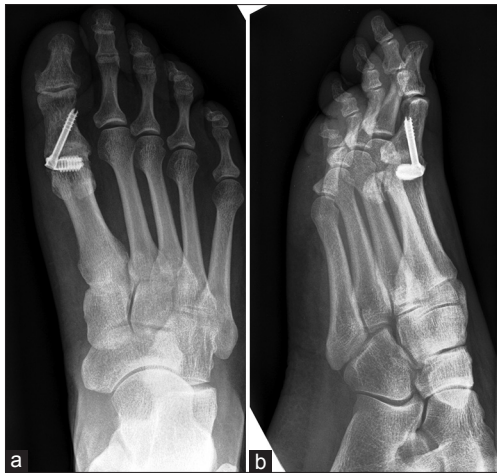

Figure 4: X-ray of foot anteroposterior and oblique views (a and b) showing fusion of metatarsophalangeal joint at final assessment of a patient treated with an intraosseous implant

described including crossed screws and plates. Patient satisfaction is highly correlated to the final alignment and compression across the fusion area.^{8,9} The recommended HVA ranges from 5° to 30° with an average of 15°. ^{10,11} In the sagittal plane, the recommended DA for the arthrodesis varies from 10° to 40° with 20–25° being the most commonly recommended position.¹ Most common occurring complications include nonunion, malalignment, and hardware impingement of the soft tissues.^{5,6,12} Therefore, every technique should enable the surgeon to fuse the joint in the desired position using rigid internal fixation devices.

Intraosseous fixation is considered by many surgeons as the gold standard in joint arthrodesis but has rarely been considered in foot surgery mostly because of the lack of proper implants. Our pilot study aimed to determine the early results of the completely intraosseous device in the examination. The IO FiX implant consists of a lag screw in combination with an anchored postdesigned to distribute the compression forces uniformly across the fusion site through a lag effect of the screw and achieve higher peak compression in comparison to a single lag screw. Another advantage of the intraosseous fixation is that it allows limited stripping of periosteum with preservation of blood supply and limited incision exposure. Furthermore, the device is fully covered from bone and causes less soft tissue irritation which can lead to an additional surgery.

As far as we know there are no published clinical studies with regards to the application of intraosseous devices for the fusion of the hallux MTP joint. In a biomechanical published study, the device in examination was compared with a locked plantar plate used for arthrodesis of the first metatarsocuneiform joint.¹³ The plantar plate created a stronger and stiffer construct than intraosseous fixation,

but one could argue that the biomechanic behavior of both implants on the MTP joint could differ significantly. Furthermore, the plate on the MTP joint is placed dorsally and not to mention that no comparison is made with other fixation constructs like crossed screws.

Rates of fusion of more than 90% have been reported in the literature with different techniques and the 91% fusion rate in our series is similar.^{1,6,12,14} The delayed union in our small series finally reached fusion 6 months after the operation. The patient diagnosed with persisting transfer metatarsalgia had a malalignment with an HA of 4° and although the improvement of the VAS (from 10 preoperatively to 7 after the operation) and of the AOFAS score (from 30 preoperatively to 59 after the operation) was poor, she was satisfied with the result and would have the operation again. The patient with the failed arthrodesis had again only minor improvement from the operation with persisting symptoms but did not want a revision of her MTP fusion. The final measured HA and DA were in the accepted range, and 10 of the 12 toes were well aligned. Patient's satisfaction after MTP arthrodesis varies from 78% to 93%.^{7,10,15,16} In our study, subjective satisfaction was reported in 83% of the patients and even in the case of a patient with questionable radiologic fusion clinical features and reported satisfaction did not warrant any further treatment. There was no patient with hardware impingement as this is expected with an intraosseous device.

The IO FiX intraosseous implant is an internal fixation device approved for use in arthrodesis, osteotomy, and fracture repair in the small bones and joints of the foot and ankle. According to the manufacturer, the intraosseous advantage of IO FiX would include a “low profile,” uniform compression, and stable fixation.¹⁷

Our study has some limitations including being retrospective and with a small number of patients. Obviously, further studies with larger number of patients are needed to compare the intraosseous with other methods of the hallux MTP joint fusion in terms of results, complications, and outcomes. Considering, though the limited literature on intraosseous devices used for the fusion of the hallux MTP joint, this study contributes toward a better understanding of the advantages and disadvantages offered.

CONCLUSION

We used for the first time the implant in examination for the fusion of the hallux MTP joint and found it to be a successful method to achieve good position, bony union, and patient satisfaction avoiding prominent hardware complications from tissue irritation as with plates and screws.

Acknowledgment

The authors thank Mr. Paul Siney (Senior Research Fellow at Wrightington Hospital, UK) for technical assistance and for conducting the statistical analysis model.

Financial support and sponsorship

Nil.

Conflicts of interest

There are no conflicts of interest.

REFERENCES

1. Besse JL, Chouteau J, Laptoiu D. Arthrodesis of the first metatarsophalangeal joint with ball and cup reamers and osteosynthesis with pure titanium staples Radiological evaluation of a continuous series of 54 cases. *Foot Ankle Surg* 2010;16:32-7.
2. Coughlin MJ. Rheumatoid forefoot reconstruction. A long term followup study. *J Bone Joint Surg Am* 2000;82:322-41.
3. Coughlin MJ, Grebing BR, Jones CP. Arthrodesis of the first metatarsophalangeal joint for idiopathic hallux valgus: Intermediate results. *Foot Ankle Int* 2005;26:783-92.
4. Ginsburg AI. Arthrodesis of the first metatarsophalangeal joint: A practical procedure. *J Am Podiatry Assoc* 1979;69:367-9.
5. Grimes JS, Coughlin MJ. First metatarsophalangeal joint arthrodesis as a treatment for failed hallux valgus surgery. *Foot Ankle Int* 2006;27:887-93.
6. Brodsky JW, Passmore RN, Pollo FE, Shabat S. Functional outcome of arthrodesis of the first metatarsophalangeal joint using parallel screw fixation. *Foot Ankle Int* 2005;26:140-6.
7. Mann RA, Oates JC. Arthrodesis of the first metatarsophalangeal joint. *Foot Ankle* 1980;1:159-66.
8. Coughlin MJ. Arthrodesis of the first metatarsophalangeal joint with mini-fragment plate fixation. *Orthopedics* 1990;13:1037-44.
9. Mueller ME, Allgoewer M, Schneider R, Willenegger H. *Manual of Internal Fixation*. Berlin, Germany: Springer-Verlag; 1991.
10. Maher AJ, Metcalfe SA. First MTP joint arthrodesis for the treatment of hallux rigidus: Results of 29 consecutive cases using the foot health status questionnaire validated measurement tool. *Foot (Edinb)* 2008;18:123-30.
11. Mayer SA, Zelenski NA, DeOrio JK, Easley ME, Nunley JA 2nd. A comparison of nonlocking semitubular plates and precontoured locking plates for first metatarsophalangeal joint arthrodesis. *Foot Ankle Int* 2014;35:438-44.
12. Riggs SA Jr., Johnson EW Jr. McKeever arthrodesis for the painful hallux. *Foot Ankle* 1983;3:248-53.
13. Roth KE, Peters J, Schmidtman I, Maus U, Stephan D, Augat P. Intraosseous fixation compared to plantar plate fixation for first metatarsocuneiform arthrodesis: A cadaveric biomechanical analysis. *Foot Ankle Int* 2014;35:1209-16.
14. Mann RA, Thompson FM. Arthrodesis of the first metatarsophalangeal joint for hallux valgus in rheumatoid arthritis. *J Bone Joint Surg Am* 1984;66:687-92.
15. Goucher NR, Coughlin MJ. Hallux metatarsophalangeal joint arthrodesis using dome-shaped reamers and dorsal plate fixation: A prospective study. *Foot Ankle Int* 2006;27:869-76.
16. von Salis-Soglio G, Thomas W. Arthrodesis of the metatarsophalangeal joint of the great toe. *Arch Orthop Trauma Surg* 1979;95:7-12.
17. Chicano D. A closer look at a versatile internal fixation device. *Podiatry Today* 2012;25 (9).