

Early results of thoraco lumbar burst fracture treatment using selective corpectomy and rectangular cage reconstruction

Bowei Liang, Guofeng Huang, Luobing Ding, Liangqi Kang, Mo Sha, Zhenqi Ding

ABSTRACT

Background: Subsidence and late fusion are commonly observed in anterior subtotal corpectomy and reconstruction for treating thoracolumbar burst fractures. The subsidence rate of this surgical method was reported from 19.6% to 75% in the literatures, which would cause treatment failure. Thus, an improvement of anterior surgery technique should be studied to reduce these complications.

Materials and Methods: 130 patients of thoracolumbar burst fractures treated by minimal corpectomy, decompression and U cage, between January 2009 and December 2010 were included in this study. The hospital Ethical Committee approved the protocols. The American Spinal Injury Association (ASIA) scale, visual analog scales, and Oswestry Disability Index (ODI) scores were used for clinical evaluation. The local kyphosis angle, vertebral height (one level above the fractured vertebral to one level below), canal stenosis, and fusion status were used to assess radiological outcome. All complications and demographic data such as number of male/female patients, average age, mode of trauma, burst level involved, mean surgery time and blood lost were reported.

Results: 120 patients were followed up for 24 months. Most patients had improvement of at least 1 ASIA grade, and all experienced pain reduction. The mean ODI score steadily decreased after the surgery ($P < 0.01$). Approximately, 83.3% of patients achieved solid fusion at 3 months and reached 98.3% at 6 months. The kyphosis angle and radiographic height were corrected significantly after the surgery and with a nonsignificant loss of correction at 24 months ($P > 0.05$). The average canal stenosis index was increased from 39% to 99% after surgery. No cage subsidence or implant failure was observed.

Conclusions: The clinical outcomes described here suggest that the selective corpectomy and rectangular cage reconstruction can effectively promote solid fusion and eliminate complications related to subsidence or implant failure.

Key words: Thorocolumbar fracture, lumbar burst fracture, fusion, rectangular cage, selective corpectomy, subsidence

MeSH terms: Spinal fractures, spinal fusion, grafting, bone

INTRODUCTION

Spinal burst fractures commonly occur in the thoracolumbar region in young patients. Complete decompression and reconstruction of the anterior and middle portions of the spine column are facilitated via anterior surgery, which is important for neurological

recovery and reestablishing immediate and permanent spine stability. After subtotal corpectomy, spinal canal could be thoroughly decompressed, and static or expandable cage was then applied for restoration of vertebral height and correction of angular deformity.

As anterior surgery became popular, complications were also observed during followups. High rate of cage subsidence was one of the major concerns of this technique, which was reported from 19.6% to 75% in

Department of Orthopedics, The 175th Hospital of PLA, Affiliated Dongnan Hospital of Xiamen University, Zhangzhou, Fujian 363000, China

Address for correspondence: Dr. Zhenqi Ding, 269 Zhanghua Zhong Road, Zhangzhou, Fujian 363000, China. E-mail: dzqi@xmu.edu.cn

This is an open access article distributed under the terms of the Creative Commons Attribution-NonCommercial-ShareAlike 3.0 License, which allows others to remix, tweak, and build upon the work non-commercially, as long as the author is credited and the new creations are licensed under the identical terms.

For reprints contact: reprints@medknow.com

Access this article online	
Quick Response Code: 	Website: www.ijoonline.com
	DOI: 10.4103/0019-5413.197524

How to cite this article: Liang B, Huang G, Ding L, Kang L, Sha M, Ding Z. Early results of thoraco lumbar burst fracture treatment using selective corpectomy and rectangular cage reconstruction. Indian J Orthop 2017;51:43-8.

treating thoracolumbar and lumbar pathology, with average subsidence of 4–10 mm.¹⁻⁵ It would lead to postoperative pain,⁶ loss of angular deformity correction⁷ which caused treatment failure. One of the reasons was higher contact pressure between cage and endplate.⁸ As healed vertebral body was helpful in sharing load,⁹ fast healing of burst vertebral body may reduce subsidence rate. However, early stage fusion of burst level was challenging. Although the anterior fusion rate reached about 80–90% at final followup, late healing of burst vertebral body still exist.¹⁰ This may be due to the destruction of a large portion of vertebral body structure and blood supply during subtotal corpectomy. In the current study, we try to minimize the corpectomy extent and evaluated if a selective corpectomy could improve early fusion rate while avoiding cage subsidence. A biomechanical stable gate-like rectangular cage¹¹ [Independent R and D, Figure 1] was applied for reconstruction after selective corpectomy. The safety of the device has been evaluated and approved by China Food and Drug Administration, and its biomechanical stability also has been proved previously.¹¹ The ability of spinal canal decompression and angular deformity correction was also discussed in this study.

MATERIALS AND METHODS

130 patients of thoracolumbar burst fractures treated by minimal corpectomy, decompression and U cage between January 2009 and December 2010 were included in this study. The hospital Ethical Committee approved the protocols, and all patients read and signed the consent form. The Thoracolumbar Injury Classification and Severity (TLICS) system¹² was applied at admission to identify eligible patients. Plain radiographs, computed tomography (CT) scans, and magnetic resonance images (MRIs) were done in all cases. The American Spinal Injury Association (ASIA) impairment scale was used to classify neurological status. Inclusion criteria included: (1) One level burst fracture in lumbar region, (2) TLICS

severity score >5 points and without disruption of the posterior ligament complex (PLC), and (3) neurological deficit due to compression from the anterior direction. Exclusion criteria included: (1) Age >60 years, (2) spine deformity or previous fracture or spine surgery, (3) multilevel fracture, (4) compression fracture with intact neurological function, (5) TLICS score <5 points or those patients with disrupted PLC, (6) diseases that contraindicate anterior surgery.

Character of the U-cage

The U-cage is a rectangular standalone device made of titanium alloy (Ti6Al4V). Like cylinder cage, it is a hollow device in which cancellous bone could be implanted into. The dorsal wall prevents the bone implants dropping into spinal canal, which facilitates the nonstructural bone grafting around the cage. The whole thickness of the cage is 0.6 cm, which had relatively small bulk compared with cylinder cage [Figure 1]. Thus, more vertebral body could be preserved during decompression. Two screws fix into the adjacent endplates which reduce the risk of migration. To adapt to the variability of vertebral body, cages with different heights and widths are designed. Because it is a nonexpensible device, the proper size should be chosen before insertion. Otherwise, the device may destroy the adjacent endplates and increases the risk of subsidence if it is too large, or lead to loss of kyphosis correction during the surgery if it is too small.

Operative procedure

All patients were placed right-side down to avoid retracting the liver and injuring the inferior vena cava. A retroperitoneal approach was used. The affected vertebra and two neighboring vertebrae were carefully exposed, and the segmental vessels of these three vertebrae were subsequently ligated. The intervertebral disk and cartilage above and below the injury level were removed while preserving the bony endplate. A slot on the posterior third of the vertebral body was made with an osteotome and hammer to decompress the spinal canal and create a space to place the U-cage, which eliminated the need to perform corpectomy [Figure 2]. A special distractor was used for reduction, and a gauge for measuring the length between the cephalad and caudal endplates was used to choose an appropriately sized U-cage. Cancellous bone harvested from the fractured vertebral body or resected ribs was packed inside the device. After confirming appropriate cage placement, two 3.5 mm cortical screws were fixed into the endplates to prevent further displacement and subsidence of the cage. Cancellous bone also filled into the space of the two intervertebral spaces and in front of the U-cage. Allogeneic cancellous bone was also applied if there was not enough bone for implantation. The low-profile anterior

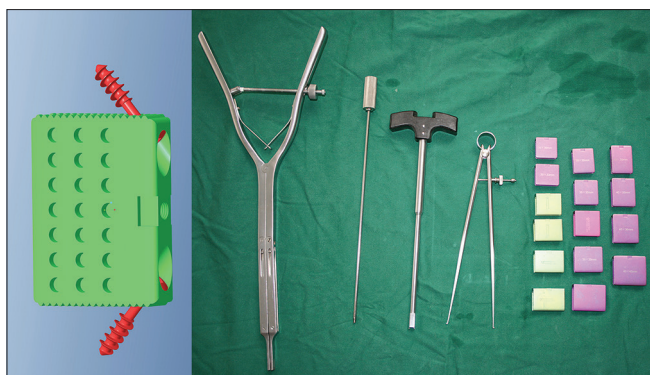

Figure 1: Photograph showing different sizes of U-cage for reconstructing fractured vertebral bodies along with instrumentation

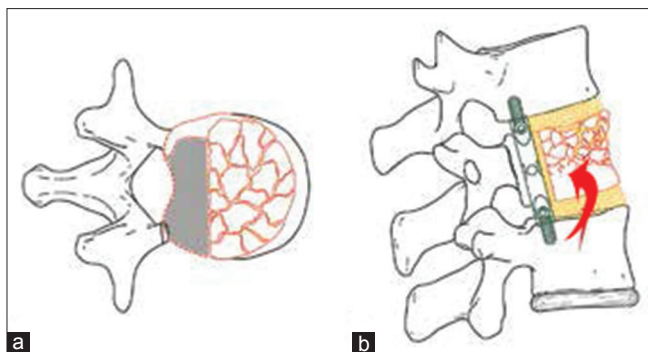


Figure 2: Schematic diagram showing the surgical techniques of decompression and reconstruction using the U-cage. The posterior part of the fractured vertebral body was resected for decompression and U-cage insertion (a - shadows). Most of the anterior and middle vertebral column was preserved (b - arrow)

D-Rod system (Independent R and D, manufactured by Double Engine Medical Material Ltd., Xiamen, Fujian, P.R. China)¹³ was then applied for further stabilization. Intraoperative radiographs were obtained to ensure the satisfactory position of the entire implant. Finally, a drain was placed, and the muscle, fascia, and skin were closed in standard fashion.

Patients completed a questionnaire on demographics, pain, function, use of analgesics, and employment status. The duration of operation, intraoperative blood loss, and intra- and postoperative complications were recorded in the patient's chart. A visual analog scale (VAS, 0–100) that evaluated pain was administered pre- and postoperatively and at the final followup. The Oswestry Disability Index (ODI) was used to evaluate disability level 6, 12, and 24 months after surgery. The ASIA scale was reevaluated postoperatively and at the final followup.

Radiological evaluation

Radiological evaluations including local kyphosis angle (LKA) and the height of vertebral body (one level above the fractured vertebrae to one level below) were measured before and after the surgery, and loss of correction was calculated at the final followup. The vertebral height was measured to evaluate cage subsidence. X-rays were taken at 3, 6, and 24 months, and fusion grade of burst vertebral body was assessed by the method of Bridwell *et al.*,¹⁴ which had four grades of fusion: Grade I was fused with remodeling and trabeculae; Grade II was not fully remodeling but had no lucencies; Grade III had clear lucencies in the fused vertebral body, whereas Grade IV was not fused and had implant bone resorption and collapse. CT scans were performed to further define fusion effectiveness. Any potential complications related to U-cage and D-Rod system placement were also evaluated. Spinal cord decompression was assessed by calculating the

anteroposterior canal stenosis index (CSI) according to the method described by Shi *et al.*,¹⁵ and neural structure recovery was assessed by signal changes on MRI scans. All radiological evaluations were conducted by a trained orthopedics resident.

Statistical analysis

Differences were assessed for VAS and ODI scores, as well as vertebral height and LKA correction. Repeated measurement analysis was applied if the data did not satisfy the sphericity hypothesis, and Bonferroni corrections were used to compare data collected at different time points. Statistical significance was set at $P < 0.05$. SPSS version 16.0 (SPSS, Inc., Chicago, IL, USA) software was used for statistical analysis.

RESULTS

Finally, a total of 120 patients met the inclusion criteria and were followed for 24 months. Seven patients were lost to followup. One patient moved to other province and had difficulty to get back for examination. One patient had heart attack and refused to continue followup at 10 months after surgery. One patient with L2 burst fracture fell from a high place and caused another T12 burst fracture at 12 months followup. He was excluded from the research as multiple level fracture. There were 66 males and 54 females. The average age was 37.8 ± 10.8 years old. The mean surgery time was 122.8 ± 12.6 min, and mean blood loss was 734.5 ± 100.2 ml.

Clinical evaluation

The mean preoperative, postoperative, and 24-month followup VAS values (mean \pm standard deviation) were 78.7 ± 9.9 , 56.5 ± 11.7 , and 9.4 ± 8.9 , respectively, which showed a continuing decline ($P < 0.01$). The mean ODI score was 42.9 ± 18.9 when assessed 6 months after surgery. It steadily decreased to 30.6 ± 21.3 and 23.2 ± 16.7 at 12 and 24 months after surgery, respectively ($P < 0.01$). At the time of admission, 27 patients had complete paraplegia (ASIA A), and the remaining 93 patients had incomplete neurological deficits (ASIA B: 23 patients, ASIA C: 39 patients, and ASIA D: 31 patients). At the end of followup, only ten patients with ASIA A still showed complete paraplegia. Other patients gained at least 1 level of ASIA grade improvement. About 41.7% of patients (50/120) were neurologically intact 2 years after surgery [Table 1].

Radiological evaluation

The mean LKA was $19.2 \pm 13.4^\circ$ preoperatively and corrected to $2.2 \pm 11.4^\circ$ postoperatively, with a mean correction of 17° ($P < 0.01$). It was $2.5 \pm 11.8^\circ$ at final followup, which corresponded to a 0.3° loss of

correction ($P > 0.05$). The average height from one level above the fractured vertebrae and below was 85.1 ± 8.4 mm, 100.2 ± 8.4 mm, and 99.8 ± 8.2 mm for preoperative, postoperative, and final followup measurements, respectively. The average height loss was 0.4 ± 0.5 mm. Height was significantly recovered immediately after surgery ($P < 0.01$) and slightly reduced at the followup ($P > 0.05$)

About 83.3% (100/120) patients had achieved Grade I and II fusion at the 3-month followup, which increased to 98.3% (with 110 achieving Grade I fusion) at the 6-month followup. At the end of the followup, 119 patients had Grade I fusion, and the other one patient achieved Grade II fusion. No Grade III or IV fusion was observed during the followup period [Table 2]. CT scan also demonstrated the consistency of bone density and the continuity of the bone trabeculae in and around the cage at the implant-endplate surface and the fractured vertebral body. Canal stenosis was successfully alleviated. The average CSI increased from 39% to 99% after surgery. MRI showed no signs of spinal cord edema or hematoma [Figure 3].

Complications

Device-related complications were not observed at the end of the followup period. One patient developed a superficial postoperative wound infection and was treated by drainage and antibiotics. Another patient developed deep venous thrombosis and received thrombolytic therapy to release the pain in her left leg. No obvious subsidence or displacement of the cage was observed.

DISCUSSION

The current study demonstrated satisfactory results of selective corpectomy when treating lumbar burst fractures. Compared to the subtotal corpectomy, the decompression

effectiveness was same while the fusion effectiveness improved. Subsidence rate also decreased with early stage fusion. The LKA was significantly corrected from $19.2 \pm 13.4^\circ$ preoperatively to $2.2 \pm 11.4^\circ$ postoperatively, with average of 17° correction, which was similar to previous reports (average correction angle ranged from 5.4° to 20.7°).^{2,16,17} Although the basic procedure of selective corpectomy was similar as previous subtotal corpectomy, the section of vertebral body in selective corpectomy was smaller. Only one-third part of posterior vertebral body was destroyed during the anterior decompression procedure, which may lead to different treatment effect of anterior surgery.

The previous study has proved the biomechanical stability of the U-cage.¹¹ After the U-cage reconstruction, the burst vertebral body was found to be equivalent to intact bone in all directions except for left rotation. All 6 specimens could withstand the 200 cyclic tests in all directions, and no subsidence or loosening of the device was detected. Average peak load for the instrumented specimens was 4137.5 N.

In the current study, burst level fusion reached 83.3% at 3 months after surgery and 98.3% at 6 months, which is suggestive of early and excellent fusion. According to the previous anterior surgery study,^{13,18} the average fusion time was about 4.5 months. However, they have not clearly mentioned the exact fusion rate during their followup period which made it hard to compare with our results. We believe that the selective corpectomy was an advantage to burst level fusion. First, it provided a better biomechanical stability for bone fusion than subtotal corpectomy. Burst level stability is one of the predominant influences for effective fusion.¹⁹ Apart from stable fixation, the corpectomy extent also influences its biomechanical stability. In the study of Schmoelz *et al.*,²⁰ partial corpectomy achieved better biomechanical stability compared to the complete corpectomy, which could explain current results. As more vertebral body was reserved, a more stable environment for bone fusion was achieved in the selective corpectomy, which may lead to the better fusion effect. Second, the selective corpectomy provided more bone structure and blood supply for fusion. Those saved burst vertebral body could act as an autograft with endogenous blood supply, which promotes a better and faster vertebral body healing. In the meantime, as bone defect became smaller with selective corpectomy, less healing time was needed, which has been proved by the previous research.²¹

The gate-like rectangular cage used in the selective corpectomy is also beneficial to fusion. Previous studies have shown the average subsidence was 4–10 mm,^{4,5} whereas in our study, the subsidence was <1 mm. Compared to the round titanium cage, it allowed not only

Table 1: The American Spinal Injury Association grade

Preoperative	Number of case	Final followup				
		A	B	C	D	E
A	27	10	12	3	2	-
B	23	-	-	10	13	-
C	39	-	-	-	31	8
D	31	-	-	-	-	31
E	0	-	-	-	-	-
Total	120	10	12	13	46	39

Table 2: The fusion grade evaluated by X-ray in 3, 6, and 12 months

Followup/fusion grade	I	II	III	IV	Fusion rate (I + II) (%)
3 months	63	37	20	0	83.3
6 months	110	8	2	0	98.3
12 months	119	1	0	0	100

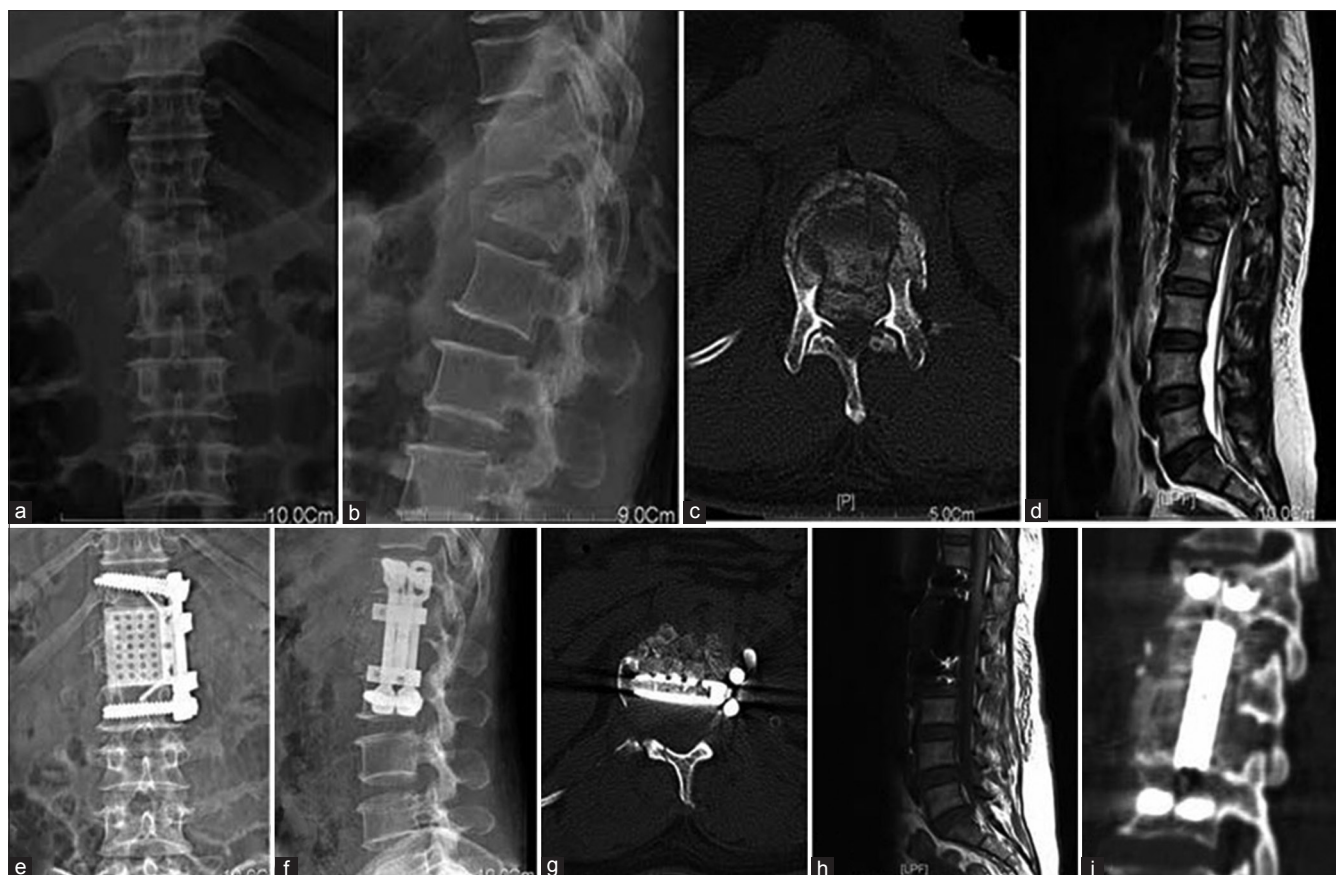

Figure 3: X-ray of dorsolumbar spine anteroposterior (a) and lateral (b) views showing an L1 burst fracture and kyphosis (c) Axial CT scan showing retropulsed fragment of L1 burst fracture (d) T2W mid sagittal MRI of dorsolumbar spine showing L1 burst fracture and spinal canal compression (e and f) X-ray anteroposterior and lateral views showing cage and implant *in situ* (g) Axial CT scan showing decompression and implant *in situ* (h) T1W mid sagittal MRI showing decompression (i) Reconstructed CT image at burst level showing adjacent vertebral bodies, cage and implant

bone implant inside the cage but also in front of the cage. In the current study, the amount of bone implantation in the burst vertebral body and adjacent disc spaces was larger. This was considered to be safe as the gate-like design could help avoid grafted bone dropping into spinal canal. Solid fusion was supposed to occur both inside and outside the rectangular cage, which would provide better fusion effect observed in the selective corpectomy.

Early fusion has been proved to reduce cage subsidence in selective corpectomy in the current study. A previous study has confirmed that successful bony fusion could achieve near physiologic stress distribution pattern in the lumbar interbody fusion,⁹ and we hypothesize that bony fusion also affects the load transfer between cage and endplate. The fused vertebral body may become dominant in sharing axial loads again at an early stage and reducing the cage-endplate contact stress, which leads to the lower subsidence rate in the current study. The cage design may be another reason to explain lower subsidence rate.²² Recently, rectangular footplate designed cage has been observed to have more subsidence resistance,^{23,24} and biomechanical studies have confirmed that peripheral part of endplate could afford

more load compression than central.^{24,25} Similar to these researches, the rectangular cage applied in the study also rested more on the stronger peripheral area, which could be another reason for a less subsidence rate.

Besides better fusion effect and less subsidence rate, selective corpectomy, and rectangular cage reconstruction can achieve satisfactory decompression and kyphosis correction. By conducting selective corpectomy, the operation time was saved, and neurological recovery was similar as traditional subtotal corpectomy. This indicates that the extent of corpectomy has no relationship with decompression effect. By resecting posterior one-third part of the vertebral body, the surgeons could gain enough space for removing the compressed bone fragments and in the meantime, minimizing the trauma during operation. The kyphosis was corrected and maintained in the last followup, which has further verified the effectiveness of rectangular cage reconstruction. As subsidence rate decreased, it could better maintain the deformity correction.

Although the selective corpectomy may have some advantage than subtotal corpectomy, we noticed that it

Liang, *et al.*: Selective corpectomy and rectangular cage reconstruction to treat thoracolumbar burst fracture

could only be used in treating burst fractures. Diseases such as spinal tumors or tuberculosis were not suitable for selective corpectomy, as preservation of the vertebral body may facilitate disease recurrence. Thus, compared to the subtotal corpectomy, its applicability is less.

CONCLUSIONS

Selective corpectomy and rectangular cage reconstruction may be a good option for treating lumbar burst fracture as it could improve effective fusion and decrease cage subsidence rate.

Financial support and sponsorship

This study was supported by military grant (12Z23).

Conflicts of interest

There are no conflicts of interest.

REFERENCES

1. Yang X, Song Y, Liu L, Liu H, Zeng J, Pei F. Anterior reconstruction with nano-hydroxyapatite/polyamide-66 cage after thoracic and lumbar corpectomy. *Orthopedics* 2012;35:e66-73.
2. Suzuki T, Abe E, Miyakoshi N, Murai H, Kobayashi T, Abe T, *et al.* Anterior decompression and shortening reconstruction with a titanium mesh cage through a posterior approach alone for the treatment of lumbar burst fractures. *Asian Spine J* 2012;6:123-30.
3. Oskouian RJ Jr., Shaffrey CI, Whitehill R, Sansur CA, Pouratian N, Kanter AS, *et al.* Anterior stabilization of three-column thoracolumbar spinal trauma. *J Neurosurg Spine* 2006;5:18-25.
4. Dvorak MF, Kwon BK, Fisher CG, Eiserloh HL 3rd, Boyd M, Wing PC. Effectiveness of titanium mesh cylindrical cages in anterior column reconstruction after thoracic and lumbar vertebral body resection. *Spine (Phila Pa 1976)* 2003;28:902-8.
5. Lee GJ, Lee JK, Hur H, Jang JW, Kim TS, Kim SH. Comparison of clinical and radiologic results between expandable cages and titanium mesh cages for thoracolumbar burst fracture. *J Korean Neurosurg Soc* 2014;55:142-7.
6. Chen Y, Chen D, Guo Y, Wang X, Lu X, He Z, *et al.* Subsidence of titanium mesh cage: A study based on 300 cases. *J Spinal Disord Tech* 2008;21:489-92.
7. Tosun B, Erdemir C, Yonga O, Selek O. Surgical treatment of thoracolumbar tuberculosis: A retrospective analysis of autogenous grafting versus expandable cages. *Eur Spine J* 2014;23:2299-306.
8. Tokuhashi Y, Ajiro Y, Umezawa N. Subsidence of metal interbody cage after posterior lumbar interbody fusion with pedicle screw fixation. *Orthopedics* 2009;32. pii: Orthosupersite.com/view.asp?rID=38061.
9. Kumar N, Judith MR, Kumar A, Mishra V, Robert MC. Analysis of stress distribution in lumbar interbody fusion. *Spine (Phila Pa 1976)* 2005;30:1731-5.
10. Klezl Z, Bagley CA, Bookland MJ, Wolinsky JP, Rezek Z, Gokaslan ZL. Harms titanium mesh cage fracture. *Eur Spine J* 2007;16 Suppl 3:306-10.
11. Liang B, Ding Z, Liu T, Kang L, Zai W, Sha M, *et al.* Design and biomechanical properties of a new reconstruction device for treating thoracolumbar burst fractures. *Orthopedics* 2012;35:e1785-91.
12. Rihn JA, Anderson DT, Harris E, Lawrence J, Jonsson H, Wilsey J, *et al.* A review of the TLICS system: A novel, user-friendly thoracolumbar trauma classification system. *Acta Orthop* 2008;79:461-6.
13. Huang ZY, Ding ZQ, Liu HY, Fang J, Liu H, Sha M. Anterior D-rod and titanium mesh fixation for acute mid-lumbar burst fracture with incomplete neurologic deficits: A prospective study of 56 consecutive patients. *Indian J Orthop* 2015;49:471-7.
14. Bridwell KH, Lenke LG, McEnery KW, Baldus C, Blanke K. Anterior fresh frozen structural allografts in the thoracic and lumbar spine. Do they work if combined with posterior fusion and instrumentation in adult patients with kyphosis or anterior column defects? *Spine (Phila Pa 1976)* 1995;20:1410-8.
15. Shi R, Liu H, Zhao X, Liu X, Gong Q, Li T, *et al.* Anterior single segmental decompression and fixation for Denis B type thoracolumbar burst fracture with neurological deficiency: Thirty-four cases with average twenty six month followup. *Spine (Phila Pa 1976)* 2011;36:E598-605.
16. Zahra B, Jodoin A, Maurais G, Parent S, Mac-Thiong JM. Treatment of thoracolumbar burst fractures by means of anterior fusion and cage. *J Spinal Disord Tech* 2012;25:30-7.
17. Xu JG, Zeng BF, Zhou W, Kong WQ, Fu YS, Zhao BZ, *et al.* Anterior Z-plate and titanic mesh fixation for acute burst thoracolumbar fracture. *Spine (Phila Pa 1976)* 2011;36:E498-504.
18. Tang J, Liu Y, Hu Y, Cao Z, Lu X, Lin B. Anterior decompression with single segmental spinal interbody fusion for Denis type B thoracolumbar burst fracture: A midterm followup study. *Int Orthop* 2013;37:2205-9.
19. Schnake KJ, Stavridis SI, Krampe S, Kandziora F. Additional anterior plating enhances fusion in anteroposteriorly stabilized thoracolumbar fractures. *Injury* 2014;45:792-8.
20. Schmoelz W, Schaser KD, Knop C, Blauth M, Disch AC. Extent of corpectomy determines primary stability following isolated anterior reconstruction in a thoracolumbar fracture model. *Clin Biomech (Bristol, Avon)* 2010;25:16-20.
21. Wlodarski KH, Galus R. Histological aspects of bone fracture healing. *Ortop Traumatol Rehabil* 2005;7:351-60.
22. Tan JS, Bailey CS, Dvorak MF, Fisher CG, Oxland TR. Interbody device shape and size are important to strengthen the vertebra-implant interface. *Spine (Phila Pa 1976)* 2005;30:638-44.
23. Pekmezci M, McDonald E, Kennedy A, Dedini R, McClellan T, Ames C, *et al.* Can a novel rectangular footplate provide higher resistance to subsidence than circular footplates? An *ex vivo* biomechanical study. *Spine (Phila Pa 1976)* 2012;37:E1177-81.
24. Deukmedjian AR, Manwaring J, Le TV, Turner AW, Uribe JS. Corpectomy cage subsidence with rectangular versus round endcaps. *J Clin Neurosci* 2014;21:1632-6.
25. Lowe TG, Hashim S, Wilson LA, O'Brien MF, Smith DA, Diekmann MJ, *et al.* A biomechanical study of regional endplate strength and cage morphology as it relates to structural interbody support. *Spine (Phila Pa 1976)* 2004;29:2389-94.