

# Minimally invasive surgery under fluoro-navigation for anterior pelvic ring fractures

Kai-Hua Zhou, Cong-Feng Luo, Nong Chen, Cheng-Fang Hu, Fu-Gen Pan

## ABSTRACT

**Background:** The incidence of pelvic fractures in trauma patients is reported to be 3–8.2%, with roughly half of these fractures being caused by high energy injuries with a potential for catastrophic hemorrhage and death. Indications for internal fixation of anterior pelvic ring are controversial. Because of fears of disturbing the pelvic hematoma and causing additional hemorrhage, open reduction and internal fixation of pelvic ring disruption is routinely delayed. In contrast to conventional surgery, percutaneous screw fixation is gaining popularity in the treatment of pelvic and acetabular fractures mainly because of minimal soft tissue damage, less operative blood loss, early surgical intervention and comfortable mobilization of the patient. Fluoro-navigation is a new surgical technique in orthopedic trauma surgery. This study is to investigate clinical results of fluoro-navigation surgery in anterior pelvic ring fractures.

**Materials and Methods:** From January 2006 to October 2011, 23 patients with anterior pelvic ring fractures were treated with percutaneous cannulated screw under fluoro-navigation. There were 14 men and 9 women, with a mean age of 40.1 years (range 25–55). According to the AO and Orthopedic Trauma Association classification, there were seven A 2.1, two A 2.2, one A 2.3, six B 1.2, one B 2.1: 1, one B 2.2, one C 1.2, two C 1.3 and two C 2.3 types of fractures. Amongst these patients, 13 had posterior pelvic ring injuries, 8 had other injuries including urethral, lumbar vertebrae fractures and femoral fractures. All patients were operated when their general condition stabilized after emergency management. The mean time from injury to percutaneous screw fixation of the anterior pelvic ring fracture was 12 days (3–15 days). All the anterior ring fractures were fixed with cannulated screws by two senior surgeons. They were familiar with the navigation system and had gained much experience in the computer-assisted percutaneous placement of screws.

**Results:** A total of 32 screws were inserted, including 19 in the pubic ramis and 13 in the anterior acetabular columns. The average surgical time was 23.3 min/screw. The average time of X-ray exposure was  $19.1 \pm 2.5$  s/screw. The virtual images of fluoro-navigation were compared with real-time X-rays during and after the surgery. Compared to the final position of the screw, the average deviated distance was 3.11 mm and the average trajectory difference was  $2.81^\circ$ . Blood loss during the operation was minimal (22.3 ml/screw). One screw (3.1%) deviated out of the fracture site during the operation. No superficial or deep infection occurred. No patient sustained recognized neurologic, vascular, or urologic injury as a result of the percutaneous screw fixation. All fractures united at the last followup.

**Conclusions:** Fluoro-navigation technique could become a safe, accurate, and fairly quick method for the treatment of anterior pelvic ring fractures. Standardization of the operative procedure and training are mandatory for the success of this procedure.

**Key words:** Anterior pelvic ring fractures, fluoro-navigation, minimally invasive surgery

**MeSH terms:** Pelvis, minimally invasive. fluoroscopy, acetabulum

Department of Orthopedics, Qingpu Branch of Zhongshan Hospital, Fudan University, Shanghai 201700, China

**Address for correspondence:** Prof. Cong-Feng Luo, Department of Orthopedics, Shanghai Sixth People's Hospital, Shanghai Jiao Tong University, School of Medicine, Shanghai 200233, China. E-mail: 1983216145@sohu.com

Access this article online	
<b>Quick Response Code:</b> 	<b>Website:</b> <a href="http://www.ijoonline.com">www.ijoonline.com</a>
	<b>DOI:</b> 10.4103/0019-5413.181791

## INTRODUCTION

The incidence of pelvic fractures in trauma patients is reported to be 3–8.2%, with roughly half of these fractures being caused by high energy injuries with

This is an open access article distributed under the terms of the Creative Commons Attribution-NonCommercial-ShareAlike 3.0 License, which allows others to remix, tweak, and build upon the work non-commercially, as long as the author is credited and the new creations are licensed under the identical terms.

**For reprints contact:** [reprints@medknow.com](mailto:reprints@medknow.com)

**How to cite this article:** Zhou KH, Luo CF, Chen N, Hu CF, Pan FG. Minimally invasive surgery under fluoro-navigation for anterior pelvic ring fractures. *Indian J Orthop* 2016;50:250-5.

a potential for catastrophic hemorrhage and death.<sup>1,2</sup> The anterior pelvic ring is an important structure of the pelvis. Internal fixation of the anterior ring can stabilize the pelvic ring that in turn can reduce the failure of fixation of the posterior ring and enhance early mobility and weight bearing.<sup>3</sup> However, indications for internal fixation of anterior pelvic ring are controversial. Because of fears of disturbing the pelvic hematoma and causing additional hemorrhage, open reduction and internal fixation of pelvic ring disruption is routinely delayed.<sup>4</sup> In contrast to conventional surgery, percutaneous screw fixation is gaining popularity in the treatment of pelvic and acetabular fractures mainly because of minimal soft tissue damage, less operative blood loss, early surgical intervention and comfortable mobilization of the patient.<sup>4-6</sup>

To achieve good accuracy and avoid neural or vascular injury, C-arm fluoroscopy is used more frequently during surgery with percutaneous screws. However, conventional fluoroscopy generally provides only one image at a time, thus to check the guide wire or screw, There is undue prolongation of surgical time and radiation exposure time for the patient and the surgical team.

We report an alternative type of surgery under fluoro-navigation. We use patients' image data to provide real-time guidance in multiple image planes during the surgery. We want to investigate clinical results of fluoro-navigated surgery in anterior pelvic ring fractures.

## MATERIALS AND METHODS

From January 2006 to October 2011, 23 patients with anterior pelvic ring fractures were operated under fluoro-navigation system at our center. Patients were eligible for inclusion in this study if they had nondisplaced or a minimally displaced acetabular fracture or displaced acetabular fractures that could be reduced with closed reduction. There were 14 men and 9 women, with a mean age of 40.1 years (range 25–55). According to the AO and Orthopedic Trauma Association classification, there were seven A 2.1, two A 2.2, one A 2.3, six B 1.2, one B 2.1: 1, one B 2.2, one C 1.2, two C 1.3 and two C 2.3 types of fractures. Amongst these patients, 13 had posterior pelvic ring injuries, 8 had other injuries including urethral, lumbar vertebrae fractures and femoral fractures. All patients were operated when their general condition stabilized after emergency management. The mean time from injury to percutaneous screw fixation of the anterior pelvic ring fracture was 12 days (3–15 days). All the anterior ring fractures were fixed with cannulated screws by two senior surgeons. They were familiar with the navigation system and had gained much experience in the computer-assisted percutaneous placement of

screws. General patient data, including preinjury status, were recorded at admission.

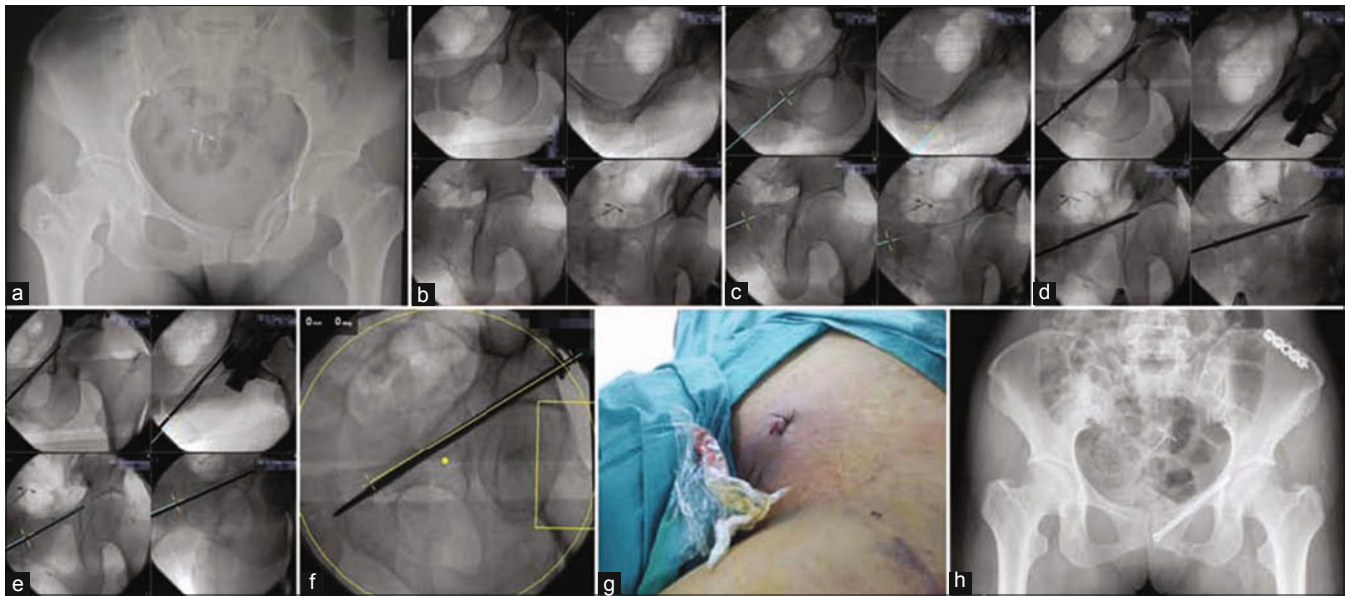
All patients underwent preoperative anteroposterior (AP) radiographs and computed tomography (CT) scan of the pelvis. Preoperative planning was conducted according to the fracture type and soft tissue condition, including: (1) Surgical position (2) procedures for reduction and fixation (3) equipment position (system platform, C-arm and site of patient's tracker), which are important for a successful navigational operation.

Under general anesthesia, the patient was placed supine or prone on a radiolucent table. For displaced pelvic ring fracture, reduction was first performed via manipulation of the injured limb. Reduction was judged by fluoroscopy. If reduction was adequate, fixation was performed with percutaneous cannulated screws under fluoro-navigation.

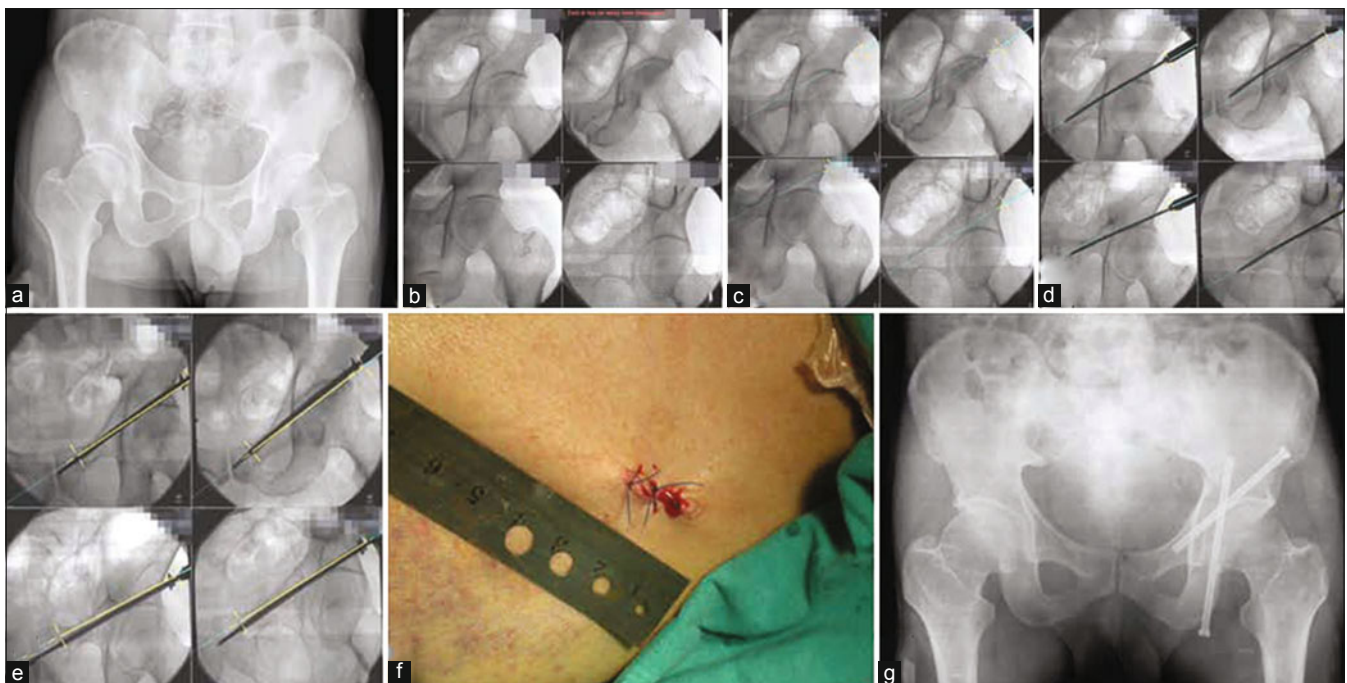
The fluoroscopy-based Navigation System II (Stryker, Freiburg, Germany) consists of a system platform, a C-arm fluoroscope adapted for use with a navigation system, and equipment for optoelectronic position detection called tracker. The system platform with an infrared camera was used for tracking and positioning the fluoroscopy.

At first, the patient tracker was installed on the patient's pelvic crest. Another tracker was installed on the drill sleeve and validated by the navigation system. Calibrate cage was mounted on the C-arm for validation. Then we collected AP, inlet, outlet, Judet view images for the surgery. We transferred and stored the images on the computer platform. Patient images could be selected during surgery. Up to four images could be used simultaneously for navigation. The skin was stabbed, and the drill sleeve was then inserted into the bone surface close to the area of interest. Multiplanar images were available then. The multiplanar images were dynamically altered correspondingly according to the alteration of the drill sleeve. The extending green dotted line was the virtual of the screwing trajectory. The guide pin was then inserted into the drill sleeve once the screw trajectory matched the preoperative surgical plan. Its position was judged by the C-arm. The length of the guide pin was then measured, and a Stryker 6.5 mm half-threaded cannulated screw was inserted. Finally, the screw was examined by fluoroscopy again, and we used the virtual of the screwing trajectory to evaluate the accuracy [Figures 1 and 2].

We divided the fractures into two subtypes: (1) The fractures of the anterior column of the acetabulum and superior pubic ramus for the antegrade screws; (2) the fractures of the inferior pubic ramus for the retrograde screws. In the antegrade screw groups, the entry points were



**Figure 1:** Anteroposterior radiograph of pelvis in a 32-year-old male showing a left fracture of the inferior pubic rami (a) pelvic anteroposterior, inlet, outlet, Judet views were obtained and displayed on a computer screen simultaneously (b) the real time spatial position of the guide sleeve was presented on four fluoroscopic projections. The extending blue dotted line was the virtual trajectory of the screw (c) A retrograde cannulated screw was inserted (d) Finally the screw was examined by fluoroscopy again and we used the virtual trajectory to evaluate the accuracy (e and f) The incision was about 20 mm (g) Postoperation X-ray (h)



**Figure 2:** Anteroposterior radiograph of a 43-year-old male with a left fracture of the anterior column of the acetabulum (a) pelvic anteroposterior, inlet, outlet, Judet views were obtained and displayed on a computer screen simultaneously (b), the real time spatial position of the guide sleeve was presented on four fluoroscopic projections. The extending blue dotted line was the virtual of the screwing trajectory (c and d). An antegrade cannulated screw was inserted (e). The incision was about 20 mm (f). Postoperation X-ray (g)

determined by a line drawn between the tip of the greater trochanter and the thick part of the iliac crest (usually about 4–5 cm back from the anterior-superior iliac spine). In the retrograde screw group, the entry point was against the ipsilateral pubic tubercle and directed laterally above the acetabulum.

We recorded the surgical time, including calibration and validation of the surgical tool, image collection, and screw insertion.

The SPSS 11.5 (SPSS Inc., Chicago, IL, USA) program was used for statistical analysis.



## RESULTS

A total of 32 screws were inserted, including 19 in the pubic ramus and 13 in the anterior acetabular columns. The average surgical time was 23.3 min/screw and the average time of X-ray exposure was  $19.1 \pm 2.5$  s/screw. The virtual images of fluoro-navigation were compared with real-time X-rays during and after surgery. Because this surgery was minimally invasive, bleeding was minimal (22.3 ml/screw). One screw (3.1%) deviated out of the fracture site during the operation. No superficial or deep infection occurred. There was no evidence of secondary fragment displacement or screw back out. No patient sustained recognized neurologic, vascular or urologic injury as a result of the percutaneous screw. The surgical details are shown in Figure 3.

Fluoroscopic verification after surgery showed that the wire tip average error was 3.11 mm (range 1.0–4.5 mm) and the average trajectory difference was  $2.81^\circ$  (range  $1.4^\circ$ – $3.5^\circ$ ).

Five patients were lost to followup. In rest of the patients, the mean duration of followup was 16.6 months. All the fractures showed union at the last followup. One year after surgery, each patient was evaluated with the Short Musculoskeletal Function Assessment Questionnaire (SMFA). Mean scores were 64.26 (49.26–82.35) points for dysfunction index and 65.83 (47.92–100) points for annoyance index.

## DISCUSSION

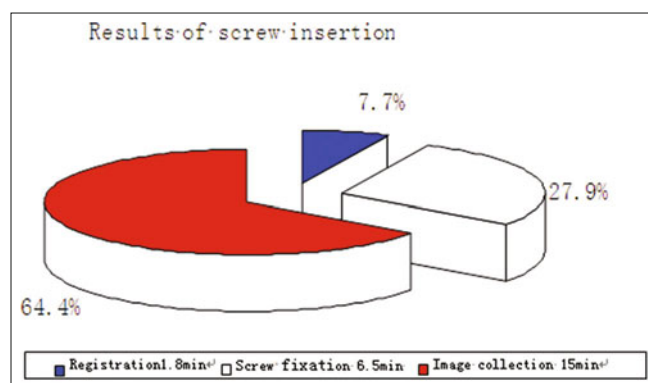
Recent researches in anatomy and biomechanics show that incomplete pelvic mechanics may cause an instability of the pelvis. About 30% of the load of the upper body is transferred to the hips through the anterior pelvic ring.<sup>7</sup> In order to improve stability and prognosis for this area, the anterior pelvic ring must be repaired in the most effective way possible.<sup>8</sup>

For inferior pubic ramus fractures, a Pfannenstiel incision can expose the fractures. For the anterior column of the

acetabulum and superior pubic ramus fractures, we used the long ilio-inguinal incision previously but now we mostly use the Stoppa's approach. The modified Stoppa's approach allows for exposure of most (79%) of the inner true bony pelvis including the entire pelvic brim and 80% of the quadrilateral surface.<sup>9</sup> The Stoppa's approach is much safer and smaller exposure than ilioinguinal approach. But all the traditional techniques of open reduction and internal fixation required extensive surgical exposure of the deep structures of the pelvis, which can hamper wound healing, damage major vessels or nerves and increases the incidence of infection up to 25%.<sup>10,11</sup> Studies show that the lateral femoral cutaneous nerve injury is nearly 30% and 50% in these patients.<sup>12</sup> Most of these complications are related to surgical exposure. Therefore, less invasive alternatives are needed.

Closed reduction with percutaneous fixation of nondisplaced or minimally displaced fractures of the anterior pelvic ring is gaining popularity in recent years. It can stabilize the pelvis, reduce exposure-related hazards and decrease soft tissue disruption. Because of the complex three-dimensional (3D) of the pelvis and the close proximity to neurovascular structures, the percutaneous screw fixation is demanding and requires the surgeon to have detailed anatomic knowledge and extensive surgical experience. In addition, the patient and the operating room team are exposed to high levels of fluoroscopic times.<sup>13,14</sup> Augmenting visualization of the anatomic site, navigation surgery may be valuable in this special clinical situation. Navigation surgery aims to replay surgical action performed with different instruments on a computer monitor in real time.<sup>15</sup> Roberts first used this technique in neurosurgery in 1986.<sup>16</sup> Now it is widely used in orthopedic operations.

There are four major navigation systems: (1) Image-free navigation. (2) CT-based surgical navigation.<sup>17</sup> (3) Two-dimensional (2D) fluoroscopy-based surgical navigation. (4) 3D fluoroscopy-based surgical navigation. The image-free navigation is mostly used in the joint arthroplasty. CT-based surgical navigation needs CT images preoperatively. But when we transfer the patients to the operation bed, it can cause the fracture to displace and CT-images can undergo distortion. A cadaveric study shows that 3D fluoro-navigation shows the highest accuracy rate in the position of the screw, but the fluoroscopic time was longer in 3D fluoroscopic navigation than in 2D fluoroscopic navigation.<sup>18</sup> Ochs *et al.* compared 2D with 3D fluoroscopy-based surgical navigation. They concluded that the accuracy of percutaneous periacetabular screw placement in artificial pelvis models and human cadaver specimen is similar, especially for the anterior column screws. 3D fluoroscopy navigation led to significantly longer total procedure and fluoroscopic times, and the



**Figure 3:** Average time per screw during steps of navigation surgery

applied radiation dose was significantly higher.<sup>19</sup> And for most hospitals, the cost of the 3D fluoroscopy navigation is too high. So on an overall consideration, among these four systems, we think the 2D fluoro-navigation is the most suitable technique in the anterior pelvic ring fractures for most hospitals.

During navigated operations, it is possible to supervise several reference images simultaneously using virtual images without any X-ray exposure. We did not take other images during surgery. With the navigation technique in our surgery, the average surgical time was 23.3 min/screw and the average time of X-ray exposure was  $19.1 \pm 2.5$  s/screw. The results compared well with the above mentioned series and were superior to that of conventional fluoroscopy methods with a mean fluoroscopic time of 141 s and a mean operation time of 69 min, which indicated lower radiation exposure and shorter operation time using computer-assisted surgery.<sup>6</sup> Bjorn's research also showed that for screw placement, the fluoroscopic time and the radiation dose were significantly lower in the navigation surgeries than in the conventional operation.<sup>19</sup> The incision was about 20 mm. It was much smaller than the length of incision made for open reduction using the Stoppa approach or the ilioinguinal approach. Bleeding was minimal (22.3 ml/screw). One screw (3.1%) deviated out of the fracture site during the operation. The accuracy of screw position was much higher than that in the Bojorn's study.<sup>19</sup> No superficial or deep infection occurred. No evidence was noted of secondary fragment displacement or screw back out. No patient sustained recognized neurologic, vascular or urologic injury as a result of percutaneous screw. This showed that the fluoro-navigation technique was a safe and accurate method. With the aid of the navigation, young surgeons can shorten their learning curve for pelvic surgery.

Patients with anterior pelvic ring fractures may also have other injuries like those of the posterior pelvic ring or other long bone fractures. In our research, 13 of 23 patients (56.5%) had posterior pelvic ring fractures, and 8 (34.8%) had multi-trauma. Minimally invasive surgery under fluoro-navigation addresses the shortcomings of traditional surgery. Without the need for preoperative images, the patient does not require position changes and several operations can be completed at one time so as to reduce the whole operation time and improve functional recovery.

The advantages of fluoro-navigation surgery are many but caution is required. First, training is required for correct use of the technique. Surgeons are better of using this system on plastic bones or in a cadaver to be familiar with the concepts of fluoro-navigation. An experienced fluoroscopy technician

who is familiar with percutaneous screw techniques and fluoroscopic navigation also facilitates the successful applications of this technique. Second, fluoro-navigation technique has a learning curve and team cooperation. We spent much more time to insert screws at first because the fluoro-navigation need several preparatory step, including placement of the system platform, a C-arm fluoroscope, trackers, calibration of tracking devices, and acquisition of initial pelvic images. In our research, 64.4% of the surgery time was involved with these issues. Now we could save about half time to insert one screw. We have defined a standard operation protocol. To ensure the quality of the surgery, we may take more images than necessary at first while fewer images are required after mastery. Now the system's preparatory time could decrease to less than 10 min. Third, patients with acetabular fractures sometimes can have apparent intestinal pneumatosis, which seriously affects the quality of the acquired images, so we should give the patients intestinal preparation. Fourth, as the patient tracker is the only way the infrared camera can track acetabular fractures this device should be fixed stably to the iliac crest and remains in its position through out the operation. Unnoticed manipulations of the tracker can lead to complete shift of the images. Thus, any doubts about the consistency of the tracker position at any time must be verified immediately. Fifth, due to plenty of muscles around the hip and the tendency of the long guide wire to bend, obviously, the use of a navigated rigid drill sleeve can prevent the extra osseous guide wire bending by soft tissues and reduce the deviation at the starting point and thus is safer and more accurate. Sixth, the cost of the navigation system is higher than traditional surgery. But studies had confirmed that fluoroscopy time and surgical time were significantly shorter than that conventional surgery.

Although trauma navigation surgery for orthopedic trauma is still at the clinical research stage, we recommend that nondisplaced or minimally displaced fractures of the anterior pelvic ring can be easily fixed with minimally invasive surgery under fluoro-navigation. Our study lacked a control group so we cannot directly compare the clinical results with the conventional percutaneous screw fixation technique. But we compared it with the results of Lin YC *et al.*<sup>6</sup> And we found obvious superiority in the fluoro-navigation technique. Good screw position judged from postoperative X-ray and the deviated distances and angles could justify that the screw placement accuracy of fluoro-navigation technique did seem to be similar or even higher. Using fluoro-navigation technique could become a safe, accurate, and fairly quick method for the treatment of anterior pelvic ring fractures.

In the future, widespread, integrated use of fluoro-navigation offers huge potential to improve patient care. The resulting

computer-assisted orthopedic surgery tools will effectively plug treatment loop holes in orthopedic surgical practice.

### Financial support and sponsorship

Nil.

### Conflicts of interest

No funding was received to support this study, and the authors report no conflict of interest.

### REFERENCES

1. Pohlemann T, Gänsslen A, Schellwald O, Culemann U, Tscherne H. Outcome after pelvic ring injuries. *Injury* 1996;27 Suppl 2:B31-8.
2. Wong JM, Bucknill A. Fractures of the pelvic ring. *Injury* 2013;12:pil: S0020-138300556-1.
3. Simonian PT, Routt ML Jr, Harrington RM, Tencer AF. Internal fixation of the unstable anterior pelvic ring: A biomechanical comparison of standard plating techniques and the retrograde medullary superior pubic ramus screw. *J Orthop Trauma* 1994;8:476-82.
4. Routt ML Jr, Kregor PJ, Simonian PT, Mayo KA. Early results of percutaneous iliosacral screws placed with the patient in the supine position. *J Orthop Trauma* 1995;9:207-14.
5. Hong G, Cong-Feng L, Cheng-Fang H, Chang-Qing Z, Bing-Fang Z. Percutaneous screw fixation of acetabular fractures with 2D fluoroscopy-based computerized navigation. *Arch Orthop Trauma Surg* 2010;130:1177-83.
6. Lin YC, Chen CH, Huang HT, Chen JC, Huang PJ, Hung SH, *et al.* Percutaneous antegrade screwing for anterior column fracture of acetabulum with fluoroscopic-based computerized navigation. *Arch Orthop Trauma Surg* 2008;128:223-6.
7. Keating JF, Werier J, Blachut P, Broekhuysen H, Meek RN, O'Brien PJ. Early fixation of the vertically unstable pelvis: The role of iliosacral screw fixation of the posterior lesion. *J Orthop Trauma* 1999;13:107-13.
8. Matta JM, Tornetta P 3<sup>rd</sup>. Internal fixation of unstable pelvic ring injuries. *Clin Orthop Relat Res* 1996;8:129-40.
9. Bible JE, Choksi AA, Kadakia RJ, Evans JM, Mir HR. Quantification of bony pelvic exposure through the modified Stoppa approach. *J Orthop Trauma* 2014;28:320-3.
10. Kellam JF, McMurtry RY, Paley D, Tile M. The unstable pelvic fracture. Operative treatment. *Orthop Clin North Am* 1987;18:25-41.
11. Routt ML Jr, Simonian PT, Swiontkowski MF. Stabilization of pelvic ring disruptions. *Orthop Clin North Am* 1997;28:369-88.
12. Leighton RK, Waddell JP. Techniques for reduction and posterior fixation through the anterior approach. *Clin Orthop Relat Res* 1996;8:115-20.
13. Hinsche AF, Giannoudis PV, Smith RM. Fluoroscopy-based multiplanar image guidance for insertion of sacroiliac screws. *Clin Orthop Relat Res* 2002;2:135-44.
14. Norris BL, Hahn DH, Bosse MJ, Kellam JF, Sims SH. Intraoperative fluoroscopy to evaluate fracture reduction and hardware placement during acetabular surgery. *J Orthop Trauma* 1999;13:414-7.
15. Nolte LP, Beutler T. Basic principles of CAOS. *Injury* 2004;35 Suppl 1:S-A6-16.
16. Tian ZM. Clinical evaluation of neuronavigation and frameless stereotaxy in minimally invasive neurosurgery. *Chin Med J* 2001;81:1028-9.
17. Nolte LP, Visarius H, Arm E, Langlotz F, Schwarzenbach O, Zamorano L. Computer-aided fixation of spinal implants. *J Image Guid Surg* 1995;1:88-93.
18. Xu P, Wang H, Liu ZY, Mu WD, Xu SH, Wang LB, *et al.* An evaluation of three-dimensional image-guided technologies in percutaneous pelvic and acetabular lag screw placement. *J Surg Res* 2013;185:338-46.
19. Ochs BG, Gonser C, Shiozawa T, Badke A, Weise K, Rolauffs B, *et al.* Computer-assisted periacetabular screw placement: Comparison of different fluoroscopy-based navigation procedures with conventional technique. *Injury* 2010;41:1297-305.

### Staying in touch with the journal

#### 1) Table of Contents (TOC) email alert

Receive an email alert containing the TOC when a new complete issue of the journal is made available online. To register for TOC alerts go to [www.ijoonline.com/signup.asp](http://www.ijoonline.com/signup.asp).

#### 2) RSS feeds

Really Simple Syndication (RSS) helps you to get alerts on new publication right on your desktop without going to the journal's website. You need a software (e.g. RSSReader, Feed Demon, FeedReader, My Yahoo!, NewsGator and NewzCrawler) to get advantage of this tool. RSS feeds can also be read through Firefox or Microsoft Outlook 2007. Once any of these small (and mostly free) software is installed, add [www.ijoonline.com/rssfeed.asp](http://www.ijoonline.com/rssfeed.asp) as one of the feeds.