

# Results of a modified posterolateral approach for the isolated posterolateral tibial plateau fracture

Guan-Yi Liu, Bai-Ping Xiao, Cong-Feng Luo<sup>1</sup>, Yun-Qiang Zhuang, Rong-Ming Xu, Wei-Hu Ma

## ABSTRACT

**Background:** There are few posterolateral approaches that do not require the common peroneal nerve (CPN) dissection. With the nerve exposure, it would pose a great challenge and sometimes iatrogenic damage over the surgical course. The purpose was to present a case series of patients with posterolateral tibial plateau fractures treated by direct exposure and plate fixation through a modified posterolateral approach without exposing the common peroneal nerve (CPN).

**Materials and Methods:** 9 consecutive cases of isolated posterior fractures of the posterolateral tibial plateau were operated by open reduction and plate fixation through the modified posterolateral approach without exposing the CPN between June 2009 and January 2012. Articular reduction quality was assessment according to the immediate postoperative radiographs. At 24 month followup, all patients had radiographs and were asked to complete a validated outcome measure and the modified Hospital for Special Surgery (HSS) Knee Scale.

**Results:** All patients were followedup, with a mean period of 29 months (range 25–40 months). Bony union was achieved in all patients. In six cases, the reduction was graded as best and in three cases the reduction was graded as middle according to the immediate postoperative radiographs by the rank order system. The average range of motion arc was 127° (range 110°–134°) and the mean postoperative HSS was 93 (range 85–97) at 24 months followup. None of the patients sustained neurovascular complication.

**Conclusions:** The modified posterolateral approach through a long skin incision without exposing the CPN could help to expand the surgical options for an optimal treatment of this kind of fracture, and plating of posterolateral tibial plateau fractures would result in restoration and maintenance of alignment. This approach demands precise knowledge of the anatomic structures of this region.

**Key words:** Knee, tibial plateau fracture, posterolateral approach

**MeSH terms:** Tibial fractures, fracture fixation, knee joint

## INTRODUCTION

The posterolateral tibial plateau fracture is an uncommon injury. The fracture line of a posterolateral tibial plateau fracture usually appears in the coronal plane, making it difficult to identify using plain anteroposterior (AP) radiographs of the knee.<sup>1</sup> As computed tomography (CT) is commonly used in the

diagnosis and evaluation of intraarticular fractures, this kind of fracture has been found with increasing frequency. The pattern of this fracture is from a combination of valgus and axial compression forces with knee in flexion, resulting in a fracture line primarily and mainly of the posterior aspect and lateral condyle continuously in the coronal plane.<sup>2,3</sup>

Carlson<sup>4,5</sup> described dual posterolateral and posteromedial curvilinear S-shaped approaches separately for posterior bicondylar tibial plateau fractures in 1998 and 2005. During the exposure, the common peroneal nerve (CPN) needed to be identified at the posterior aspect of the biceps femoris muscle and protected carefully. Several approaches have been described for the posterolateral tibial plateau with authors deliberating over the merits of each.<sup>4-10</sup> There are few posterolateral approaches that do not require the CPN dissection.<sup>4-10</sup> With the nerve exposure, it would pose a great challenge and damage sometimes inevitably appeared over the surgical course.<sup>8</sup> This article introduces a modified posterolateral approach through a long skin incision without exposing the CPN for open reduction and buttress plate fixation under direct visualization.

Departments of Orthopaedic Surgery, Ningbo 6<sup>th</sup> Hospital, Ningbo, Zhejiang 315040, <sup>1</sup>Shanghai Sixth People's Hospital, Jiao Tong University School of Medicine, Shanghai, People's Republic of China

**Address for correspondence:** Dr. Yun-qiang Zhuang, 1059, Zhongshan East Road, Department of Orthopaedic Surgery, Ningbo 6<sup>th</sup> Hospital, Ningbo, Zhejiang 315040, People's Republic of China. E-mail: 18906628697@163.com

Access this article online	
Quick Response Code:	Website: <a href="http://www.ijoonline.com">www.ijoonline.com</a>
	DOI: 10.4103/0019-5413.177578

## MATERIALS AND METHODS

Nine patients with isolated posterolateral tibial plateau fractures, operated by open reduction and plate fixation through the posterolateral approach between June 2009 and January 2012 were included in the study. There were five females and four males, with an average age of 47 years (range 40–58 years). All had closed fractures. After institutional board approval, the patients were enrolled prospectively [Table 1]. All cases were assessed preoperatively and postoperatively by X-ray radiographs, CT scans, three-dimensional reconstructions and magnetic resonance imaging [Figure 1]. Eight cases had lateral meniscus injury. Anterior cruciate ligament avulsion was found in two cases and medial collateral ligament injury was found in four cases. All meniscus and ligament injuries were not serious and did not need operative repair.

### Operative procedure

The operation is performed with the patient in the prone position on a radiolucent table, under tourniquet. The knee is held slightly flexed by a bump under the ankle and kept in flexion. A 7–8 cm long skin incision is made straight down, about 1.5 cm medial to the medial border of the fibular head, starting at 1 cm below the popliteal crease. The subcutaneous tissue and popliteal fascia are incised by sharp dissection. The CPN is beneath medial margin of the biceps femoris, between the tendon of biceps and the lateral head of the gastrocnemius muscle. The CPN sloped close to the fibula and then surrounded the neck of the fibula. As the long skin incision is 1.5 cm medial to the medial border of the fibular head, our approach does not require CPN dissection [Figure 2]. The lateral gastrocnemius muscle is retracted from its lateral border to the medial side. Then, popliteal vascular bundle and the tibial nerve are retracted and protected medially and the soleus muscle is divided from its posterior attachment of the proximal posterolateral aspect the proximal tibia. The medial retractors have to be placed with caution to avoid shearing injuries to these vascular bundles. The distal dissection should be restricted to no more than 5 cm below the articular level, as the anterior tibial artery (ATA)

courses through the interosseous membrane at 4.6 cm distal to the lateral tibial plateau and 3.5 cm distal to the fibula head.<sup>11</sup> If further distal exposure is required for placement of a plate, the ATA needs to be freed and carefully protected. The interosseous membrane can be opened from its fibula insertion and this allows ATA movement. The popliteus muscle is identified and the inferior lateral genicular artery passing on the muscle surface is ligated. The popliteal muscle is bluntly prepared completely for a better exposure of the posterolateral aspect of the proximal tibia. The posterior ligamento-capsular complex is opened transversely and the meniscus is elevated and the fracture pattern is examined.

Fractures can be reduced absolutely anatomically under direct vision with the help of a periosteal elevator or an osteotome. All cases need bone graft substitute (Osteonics, Wright) as the diameter of the metaphyseal defects is always >1 cm. Six cases are fixed with Meta plate (Johnson and Johnson, America) and three cases with precontoured buttress 2.7 mm volar distal radius locking plate system (Synthes, Switzerland) [Figure 1B]. The stability of the knee joint is assessed at the end of the operation and no significant ligamentous rupture is identified. The wound is closed in layers.

### Postoperative management

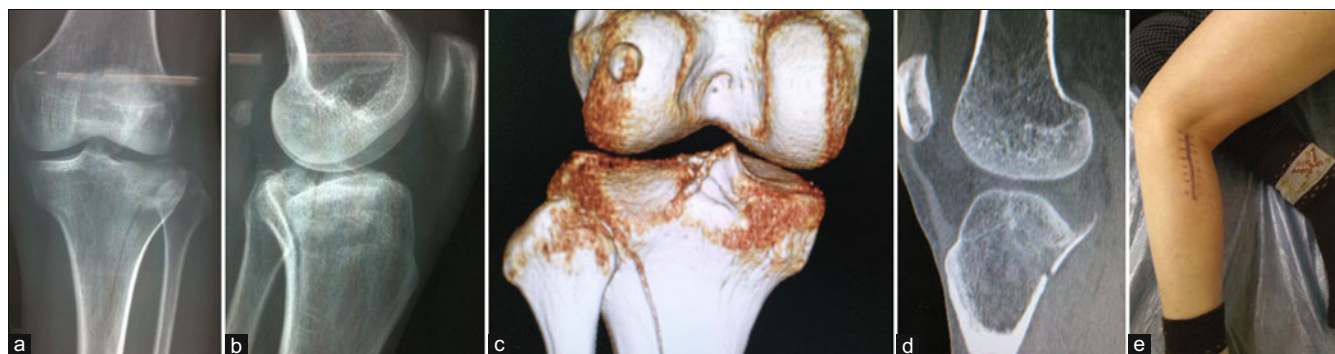The knee was elevated on a pillow for the first 3 days to allow tissue healing and for relief of the pain. The knee range of motion was allowed between 0–70° for the first 4 postoperative weeks. Then the patient was advised to increase his range of motion about 30° per week until full range was regained. Partial weight bearing began at the sixth postoperative week. Full weight bearing was delayed until the fracture was healed and callus appeared on radiographs. All discharged patients were followed up every 4 or 5 weeks for the first 4 months. Postoperatively, AP X-rays of the knee were taken in the immediate postoperative period, every 4 or 5 weeks until bony union occurred and then 2 years after the index operation.

Articular reduction quality was assessed according to the immediate postoperative radiographs by the rank-order

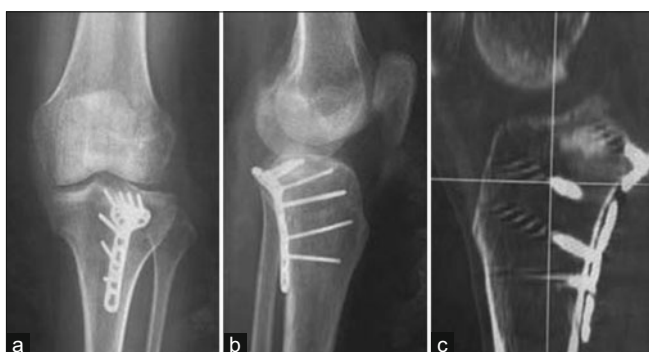**Table 1: Patient demographics, fracture classification and treatment**

No.	Sex	Age (years)	Classification AO/OTA	Approach	Internal fixation	Bone graft
1	Female	52	41-B3	Posterolateral approach	Volar distal radius locking plate system	Osteonics, wright
2	Male	40	41-B3	Posterolateral approach	Meta plate	Osteonics, wright
3	Male	43	41-B3	Posterolateral approach	Volar distal radius locking plate system	Osteonics, wright
4	Female	48	41-B3	Posterolateral approach	Meta plate	Osteonics, wright
5	Female	41	41-B3	Posterolateral approach	Meta plate	Osteonics, wright
6	Male	50	41-B3	Posterolateral approach	Volar distal radius locking plate system	Osteonics, wright
7	Female	46	41-B3	Posterolateral approach	Meta plate	Osteonics, wright
8	Male	58	41-B3	Posterolateral approach	Meta plate	Osteonics, wright
9	Female	42	41-B3	Posterolateral approach	Meta plate	Osteonics, wright

OTA=Orthopaedic Trauma Association



**Figure 1A:** A 52 year old female (case 1) injured in a car accident (a and b) Anteroposterior and lateral radiographs showing the posterolateral tibial plateau fracture (c and d) three dimensional reconstruction and sagittal computed tomography (CT) scanning showing the posterolateral depression fracture (e) Clinical photograph showing incision of the modified posterolateral approach




**Figure 1B:** Postoperative 4 months followup of anteroposterior (a) Lateral X-ray films (b) and sagittal CT scan (c) showing that a 2.7 mm volar distal radius locking plate was used after bone substitute insertion to buttress the fracture

system of DeCoster *et al.*,<sup>12</sup> as follows: Postoperative radiographs were stripped of identifying information and reviewed by three independent orthopedic surgeons. The surgeons placed the radiographs in an order of three grades from best (perfect, anatomic reduction), middle (imperfect, <2 mm step-off), to worst articular reduction (poor, 2 mm step-off). At 24-month followup, all patients had radiographs and were asked to complete the modified Hospital for Special Surgery (HSS) Knee Scale [Figure 1C].

## RESULTS

The mean time from injury to surgery was 5 (range 3–8 days) days. All patients were followed up, with a mean period of 29 (range 25–40 months) months. The mean duration of hospital stay was 12 (range 8–16 days) days.

Bony union was observed in all the patients. The mean time to achieve union was 12 weeks (range 10–16 weeks) after the surgery. In six cases, the reduction was graded as best and in three cases, the reduction was graded as middle according to the immediate postoperative radiographs by the rank order system. Radiographic obvious loss (>2 mm



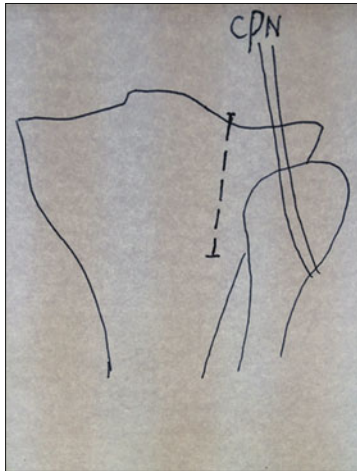
**Figure 1C:** (a and b) Clinical photographs showing flexion and extension function of this case 24 months after the operation

step-off) of intraarticular reduction was not noticed at 24-month followup. Although there were two cases with anterior cruciate ligament avulsion and four cases with medial collateral ligament injury, no symptoms of knee instability or pain were found in all cases. Internal fixation failure or breakage was not found in all patients.

At 24 months followup, the average range of motion arc was 127° (range 110°–134°). All patients have normal knee extension, but compared with the contralateral leg, only three patients have flexion lag of 15°–20°. The mean postoperative HSS at 24 month followup was 93 (range 85–97) [Table 2]. All the patients' gaits were normal without deformities. There were no complications at 24 months.

## DISCUSSION

The posterior parts of the plateau are generally unsatisfactorily dealt with by the well established medial and lateral standard access strategies.<sup>4,5,13</sup> Multiple authors recommend that tibial plateau fractures involving the posteromedial region should be treated using posteromedial approaches.<sup>14,15</sup> Posterolateral tibial plateau fractures are uncommon.<sup>16–18</sup> Solomon *et al.*,<sup>7</sup> (2010) described a posterolateral transfibular neck approach to the proximal tibia. However, this approach may increase the risk of injury to the CPN. Another shortcoming of this procedure is that the fibular neck needs to be fixed after the fixation of the tibial plateau. Yu *et al.*,<sup>8</sup> (2010) used the lateral approach with partial or full heads of the fibula



**Figure 2:** Line diagrams showing the incision of the modified posterolateral approach and its relationship to the common peroneal nerve (CPN)

**Table 2: Results**

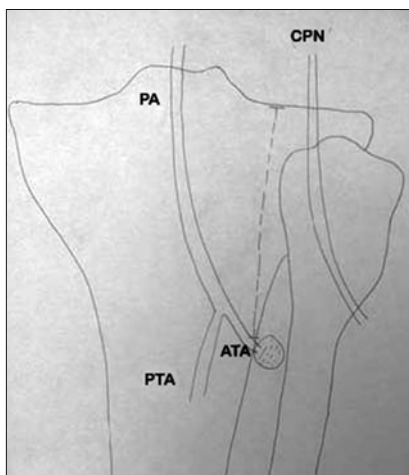
Case number	Followup (months)	Time of fracture healing (weeks)	Operative reduction	Range of motion (24-month followup)	HSS
1	26	12	Best	0-130°	96
2	25	10	Middle	0-134°	85
3	32	11	Best	0-130°	97
4	40	16	Best	0-125°	90
5	27	13	Middle	0-110°	94
6	26	12	Best	0-134°	93
7	28	12	Best	0-120°	96
8	30	14	Middle	0-129°	87
9	29	12	Best	0-120°	96

removed to expose the posterolateral aspect of the tibial plateau in six cases. A disadvantage of this technique is that the release of the posterolateral corner is a traumatic procedure.

Frosch *et al.*<sup>9</sup> (2010) presented a surgical approach with the patient in a lateral position. In this approach, a lateral arthrotomy for visualizing the joint surface and a posterolateral approach for the fracture reduction and plate fixation are both achieved through one posterolateral skin incision. It may be very helpful when the fractures are more complex and involve the lateral or anterolateral parts of the tibia plateau. However, when the fracture is limited to isolated posterolateral tibial plateau, the lateral arthrotomy for visualizing the joint surface may be not necessary. Sassoon *et al.*,<sup>19</sup> (2014) presented a novel technique that posterior impaction of the lateral tibial plateau could be reliably reduced and stabilized with the use of an intraosseous fibular allograft through a anterolateral approach. In instances in which posterolateral cortical shearing is noted, fixation of the cortex with buttress plates through a posterolateral approach may be necessary.

Tao *et al.*,<sup>10</sup> (2008) recently introduced a modified L-shaped incision to expose the posterior aspect of the lateral plateau through the intervals among the medial gastrocnemius, lateral gastrocnemius, popliteus and soleus. The lateral head of the gastrocnemius was retracted laterally which is different from our technique. We retracted the lateral gastrocnemius muscle from its lateral border to the medial side. Furthermore, instead of the L-shaped incision used by Tao *et al.*,<sup>10</sup> (2008) we used the long line incision on the posterolateral aspect of the knee. Carlson<sup>4,5</sup> (1998 and 2005) introduced dual posteromedial and posterolateral curvilinear S-shaped approaches separately for posterior bicondylar tibial plateau fractures. The posterolateral fractures were exposed by retracting the lateral gastrocnemius medially. Our approach presented here is similar with the Carlson's posterolateral approach, but different in a linear skin incision and the procedure of dealing with the CPN.<sup>4,5</sup> A curvilinear S-shaped incision was placed posterolaterally over the biceps femoris muscle, and the CPN was isolated and protected to the lateral side in the Carlson's approach. The CPN slopes close to the fibula and then surrounds the neck of the fibula. The CPN slopes at a mean angle of 14.7° toward the axis of fibula.<sup>20</sup> The point at which the CPN wound around the fibular neck is on average 42.2 mm from articular line.<sup>20</sup> As the skin incision was 1.5 cm medial to the medial border of the fibular head, starting at 1 cm below the popliteal crease, which was more medial and lower than the Carlson's incision,<sup>4</sup> our technique did not require CPN dissection.

We used a modified posterolateral approach that was presented here and achieved adequate exposures both of the lateral and posterior aspect via the intervals among lateral gastrocnemius, soleus and CPN without any procedures of osteotomy and nerve dissection. However, the posterolateral exposure cannot be extended distally. Ebraheim *et al.*,<sup>21</sup> (1998) reported a cadaver study that the interosseous foramen where the ATA coursed through the interosseous membrane was located 68.4 ± 5.0 mm below the lateral knee joint space. Heidari *et al.*,<sup>11</sup> (2013) recently in a cadaver study measured the perpendicular distance from the lateral joint line to the interosseous foramen. The ATA coursed through the interosseous membrane at 46.3 ± 9.0 mm (range 27–62 mm) distal to the lateral tibial plateau. They concluded that the distal limit of this dissection could be as little as 27 mm distal to the lateral tibial plateau. Dissection in this region should be carried out with caution. Sun *et al.*,<sup>20</sup> (2013) also performed an anatomical study and found the mean distance between the opening of the interosseous membrane and articular surface was 48.78 mm (range 45.86–51.36 mm) [Figure 3]. We prefer to restrict the distal dissection to no more than



**Figure 3:** A line diagram showing the posterior aspect of the proximal tibia. The anterior tibial artery coursed through the interosseous foramen at 46–48 mm distal to the lateral tibial plateau, as shown by the black dotted line. PA: Popliteal artery; PTA: Posterior tibial artery; ATA: Anterior tibial artery; CPN: Common peroneal nerve

5 cm below the articular level. However, according to morphological studies for the posterolateral fracture of tibial plateau,<sup>22,23</sup> the cortical split length on the coronal plane of the posterolateral fracture is sometimes more than 30 mm from the articular rim to the distal tip. We also treated two the posterolateral fractures with long fracture line [Figure 3]. Thus, implantation of a plate often needs to go beyond the level of the opening of interosseous membrane and cross deep toward the ATA. If the placement of a long posterior plate is necessary, the ATA needs to be freed and carefully protected. The interosseous membrane may be opened from its fibula insertion, and this allows ATA movement.<sup>20,23</sup> Another problem of the posterolateral approach is the difficulty in the secondary plate removal after fracture healing.<sup>24</sup> Huang and Chang<sup>24</sup> (2012) and Luo *et al.*<sup>25</sup> (2010) thus prefer to expose the posterolateral plateau by an extensile posteromedial reverse L-shaped skin incision and fix the fracture by an oblique placed plate in buttress fashion.

The anatomic reduction of the fracture, bone grafting and internal fixation can be performed under direct visualization from the dorsal side in the posterolateral approach. For isolated posterolateral tibial plateau fractures, a buttress plate affords optimal biomechanical fixation. By using an artificial bone fracture model, Zhang *et al.*,<sup>22</sup> (2012) compared the biomechanical characteristics of four different types of internal fixation to stabilize the posterolateral shearing tibial plateau fracture and confirmed that the posterolateral buttress plate is biomechanically the strongest fixation for posterolateral shearing tibial plateau fracture. The direct posterolateral plate could be used as a buttress and plays an important role in maintaining the reduction of the posterolateral fragment, which could also support

the articular surface. Anterior plate fixation was not strong enough to resist axial loading and the use of screws from anterior to posterior was at high risk of failure.<sup>3</sup>

There were some limitations of this study. The sample size ( $n = 9$ ) is small. The followup is also not long enough to address posttraumatic arthritis. Cadaveric studies that look at the locations of the CPN and these vessels and try to quantify the applicability of the modified posterolateral approach would also be beneficial.

## CONCLUSIONS

The modified posterolateral approach through a long skin incision without exposing the CPN could help to expand the surgical options for an optimal treatment of this kind of fracture and plating of posterolateral tibial plateau fractures would result in restoration and maintenance of alignment. This approach demands precise knowledge of the anatomic structures of this region.

## REFERENCES

1. Waldrop JJ, Macey TI, Trettin JC, Bourgeois WR, Hughston JC. Fractures of the posterolateral tibial plateau. *Am J Sports Med* 1988;16:492-8.
2. Kennedy JC, Bailey WH. Experimental tibial-plateau fractures. Studies of the mechanism and a classification. *J Bone Joint Surg Am* 1968;50:1522-34.
3. Papagelopoulos PJ, Partsinevelos AA, Themistocleous GS, Mavrogenis AF, Korres DS, Soucacos PN. Complications after tibia plateau fracture surgery. *Injury* 2006;37:475-84.
4. Carlson DA. Bicondylar fracture of the posterior aspect of the tibial plateau. A case report and a modified operative approach. *J Bone Joint Surg Am* 1998;80:1049-52.
5. Carlson DA. Posterior bicondylar tibial plateau fractures. *J Orthop Trauma* 2005;19:73-8.
6. Lobenhoffer P, Gerich T, Bertram T, Lattermann C, Pohlemann T, Tschernke H. Treatment of posterior tibial plateau fractures via posteromedial and posterolateral exposures. *Unfallchirurg* 1997;100:957-67.
7. Solomon LB, Stevenson AW, Baird RP, Pohl AP. Posterolateral transfibular approach to tibial plateau fractures: Technique, results, and rationale. *J Orthop Trauma* 2010;24:505-14.
8. Yu B, Han K, Zhan C, Zhang C, Ma H, Su J. Fibular head osteotomy: A new approach for the treatment of lateral or posterolateral tibial plateau fractures. *Knee* 2010;17:313-8.
9. Frosch KH, Balcarek P, Walde T, Stürmer KM. A new posterolateral approach without fibula osteotomy for the treatment of tibial plateau fractures. *J Orthop Trauma* 2010;24:515-20.
10. Tao J, Hang DH, Wang QG, Gao W, Zhu LB, Wu XF, *et al.* The posterolateral shearing tibial plateau fracture: Treatment and results via a modified posterolateral approach. *Knee* 2008;15:473-9.
11. Heidari N, Lidder S, Grechenig W, Tesch NP, Weinberg AM. The risk of injury to the anterior tibial artery in the posterolateral approach to the tibia plateau: A cadaver study. *J Orthop Trauma* 2013;27:221-5.

12. DeCoster TA, Willis MC, Marsh JL, Williams TM, Nepola JV, Dirschl DR, *et al.* Rank order analysis of tibial plafond fractures: Does injury or reduction predict outcome? *Foot Ankle Int* 1999;20:44-9.
13. Connolly JF. The posterior shearing tibial plateau fracture: Treatment and results via a posterior approach. *J Orthop Trauma* 2005;19:508.
14. Fakler JK, Ryzewicz M, Hartshorn C, Morgan SJ, Stahel PF, Smith WR. Optimizing the management of Moore type I postero-medial split fracture dislocations of the tibial head: Description of the Lobenhoffer approach. *J Orthop Trauma* 2007;21:330-6.
15. Bhattacharyya T, McCarty LP 3<sup>rd</sup>, Harris MB, Morrison SM, Wixted JJ, Vrahas MS, *et al.* The posterior shearing tibial plateau fracture: Treatment and results via a posterior approach. *J Orthop Trauma* 2005;19:305-10.
16. Cole PA, Bhandari M. What's new in orthopaedic trauma. *J Bone Jt Surg Am* 2006;88:2545-61.
17. Moore TM. Fracture – Dislocation of the knee. *Clin Orthop Relat Res* 1981;156:128-40.
18. Schatzker J, Tile M. *The Rational of Operative Fracture Care*. 3<sup>rd</sup> ed. Springer-Verlag; 2005.
19. Sassoon AA, Torchia ME, Cross WW, Cass JR, Sems SA. Fibular shaft allograft support of posterior joint depression in tibial plateau fractures. *J Orthop Trauma* 2014;28:e169-75.
20. Sun H, Luo CF, Yang G, Shi HP, Zeng BF. Anatomical evaluation of the modified posterolateral approach for posterolateral tibial plateau fracture. *Eur J Orthop Surg Traumatol* 2013;23:809-18.
21. Ebraheim NA, Lu J, Hao Y, Biyani A, Yeasting RA. Anterior tibial artery and its actual projection on the lateral aspect of the tibia: A cadaveric study. *Surg Radiol Anat* 1998;20:259-62.
22. Zhang W, Luo CF, Putnis S, Sun H, Zeng ZM, Zeng BF. Biomechanical analysis of four different fixations for the posterolateral shearing tibial plateau fracture. *Knee* 2012;19:94-8.
23. Chang SM, Zheng HP, Li HF, Jia YW, Huang YG, Wang X, *et al.* Treatment of isolated posterior coronal fracture of the lateral tibial plateau through posterolateral approach for direct exposure and buttress plate fixation. *Arch Orthop Trauma Surg* 2009;129:955-62.
24. Huang YG, Chang SM. The posterolateral approach for plating tibial plateau fractures: Problems in secondary hardware removal. *Arch Orthop Trauma Surg* 2012;132:733-4.
25. Luo CF, Sun H, Zhang B, Zeng BF. Three-column fixation for complex tibial plateau fractures. *J Orthop Trauma* 2010;24:683-92.

**How to cite this article:** Liu GY, Xiao BP, Luo CF, Zhuang YQ, Xu RM, Ma WH. Results of a modified posterolateral approach for the isolated posterolateral tibial plateau fracture. *Indian J Orthop* 2016;50:117-22.

**Source of Support:** Nil, **Conflict of Interest:** None.

### Author Help: Online submission of the manuscripts

Articles can be submitted online from <http://www.journalonweb.com>. For online submission, the articles should be prepared in two files (first page file and article file). Images should be submitted separately.

1) **First Page File:**

Prepare the title page, covering letter, acknowledgement etc. using a word processor program. All information related to your identity should be included here. Use text/rtf/doc/pdf files. Do not zip the files.

2) **Article File:**

The main text of the article, beginning with the Abstract to References (including tables) should be in this file. Do not include any information (such as acknowledgement, your names in page headers etc.) in this file. Use text/rtf/doc/pdf files. Do not zip the files. Limit the file size to 1 MB. Do not incorporate images in the file. If file size is large, graphs can be submitted separately as images, without their being incorporated in the article file. This will reduce the size of the file.

3) **Images:**

Submit good quality color images. Each image should be less than 4096 kb (4 MB) in size. The size of the image can be reduced by decreasing the actual height and width of the images (keep up to about 6 inches and up to about 1800 x 1200 pixels). JPEG is the most suitable file format. The image quality should be good enough to judge the scientific value of the image. For the purpose of printing, always retain a good quality, high resolution image. This high resolution image should be sent to the editorial office at the time of sending a revised article.

4) **Legends:**

Legends for the figures/images should be included at the end of the article file.