

Research Note

Endoparasites found in European brown hares (*Lepus europaeus*) hunted in Macedonia, Greece

A. DIAKOU^{1*}, C. SOKOS², E. PAPAPOULOS¹

¹Laboratory of Parasitology and Parasitic Diseases, School of Veterinary Medicine, Faculty of Life Sciences, Aristotle University of Thessaloniki, 54124 Thessaloniki, Greece, E-mail: diakou@vet.auth.gr, eliaspap@vet.auth.gr;

²Research Division, Hunting Federation of Macedonia and Thrace, Ethnikis Antistasis 173-175, GR-55134 Thessaloniki, Greece, E-mail: thiramatologos@hotmail.com

Summary

The European brown hare (*Lepus europaeus*) is widespread throughout Europe with population declines in some countries. Parasites can be one of the natural regulative factors of hare population. The information about the prevalence of endoparasites of European hares in Southern Europe is limited while relevant data from Greece are lacking. Gastrointestinal tracts of 84 *Lepus europaeus*, hunted in Macedonia, Greece, were examined for endoparasites. Sixty two (73.8 %) of the animals were parasitized by one or multiple parasitic species. *Eimeria* spp. was found in 54 (64.28 %) of the gastrointestinal tracts, *Trichostrongylus retortaeformis* in 42 (50 %), *Trichuris leporis* in 18 (21.42 %), *Dicrocoelium dentriticum* in 8 (9.52 %), *Passalurus ambiguus* in 4 (4.76 %) and *Protostrongylus* spp. in 2 (1.22 %). Moreover, *Linguatula serrata* larvae were found in 16 (19.04 %) animals and *Dirofilaria scapiceps* in one. Mixed infections were significantly more common than single infections. Although the parasites found do not represent a threat for other animal species, under certain conditions, they may play an important role in the health status of hares.

Keywords: endoparasites; helminths; protozoa; Greece; *Lepus europaeus*

Introduction

European brown hare (*Lepus europaeus* Pallas 1778) is a common wild animal in Greece, distributed over all parts of the continental country, and most of the islands (Thomaides *et al.*, 2011), representing an important species for hunting economy (Sokos *et al.*, 2003). Brown hare's population densities seem to be low in certain areas of Greece (Sfougaris *et al.*, 1999), while in general, they have not been evaluated (Legakis & Maragou, 2009). Although it is classified by the IUCN as a "least concerned" species, the

populations of *L. europaeus* have been experiencing declines in many areas across its geographic range in Europe. In some European countries (Norway, Germany, Austria and Switzerland), population declines have resulted in country-specific Red Listing as "near threatened" or "threatened" (Smith & Johnston, 2008), while in others, hares are legally hunted.

The primary cause of this population decline is anthropogenic, and it is considered to be due to the intensification of agriculture (Smith *et al.*, 2005). Infectious diseases such as European brown hare syndrome (EBHS), pasteurellosis, yersiniosis and tularaemia represent an additional threat to *L. europaeus* (Lamarque *et al.*, 1996). Parasites can also be one of the natural regulative factors of hare population (Newey *et al.*, 2004; Alzaga *et al.*, 2008).

The information about the species and prevalence of endoparasites of European hares in Southern Europe is limited, while relevant data from Greece are lacking. Since brown hare is an important wildlife species in Greece, the purpose of this study was a first approach in investigating the endoparasites of *L. europaeus* in areas of Macedonia, Northern Greece, in order to evaluate the parasitic fauna in relation to i) the hare's health status, and ii) its importance to other wild or domestic animals.

Materials and methods

Digestive tracts of 84 *L. europaeus* were provided by hunters, active in the area of Macedonia, Greece. The animals were shot in different locations, including forested and plain environments, during the hare hunting period (September to December) of the years 2011–2013. The digestive tract was removed from the dead animals and kept initially in isothermal boxes with ice packs and subsequently at 4 °C until examination.

Each digestive tract was dissected and examined for the




Fig. 1. Posterior end of a male *Trichostrongylus retortaeformis*, found in *Lepus europaeus*, illustrating bursa copulatrix (a) and copulatory spicules (b)

presence of parasites initially by naked eye. Subsequently, the stomach, and parts of the small and large intestine were washed with tap water in glass containers, and the sediment was examined under the optical stereoscope. The parasites found were isolated and preserved in glycerin in alcohol 180° (1:17 v/v) (Haralabidis & Diakou, 2001). The identification of the parasites was based on morphological criteria (Yamaguti, 1961).

Faecal samples were collected from the rectum, and examined by standard parasitological methods, i.e. zinc sulphate flotation, Telemann sedimentation and Ziehl-Neelsen stained smears, for the detection of *Cryptosporidium* oocysts, as described before, with minor modifications (MAFF, 1986; Thienpont *et al.*, 1986; Henriksen & Pohlenz, 1981). In brief, for the zinc sulphate flotation method, approximately 1 g of faecal material was diluted

with tap water and passed through a sieve (No 150) into a centrifuge tube. The tube was centrifuged at 200 ×g for 3 min, the supernatant fluid was discharged down to approximately 1 cm above the sediment and zinc sulphate (ZnSO₄·7H₂O) solution 33.2 % (w/v) was added to the sediment. After thorough dilution of the sediment, zinc sulphate solution was added to just over the top of the tube and a cover slip was placed on the top of the tube. After centrifugation at 150 ×g for 1 min, the cover slip was carefully removed and placed on a microscope slide. For the Telemann sedimentation method, approximately 1 g of the fecal material was diluted in HCl 16 %, passed through a sieve (No 150) into a centrifuge tube, 5 ml ether was added, and the content of the tube was homogenized by vigorous shaking. After centrifugation at 200 ×g for 3 min, all the phases of the centrifuged material, except the sedi-

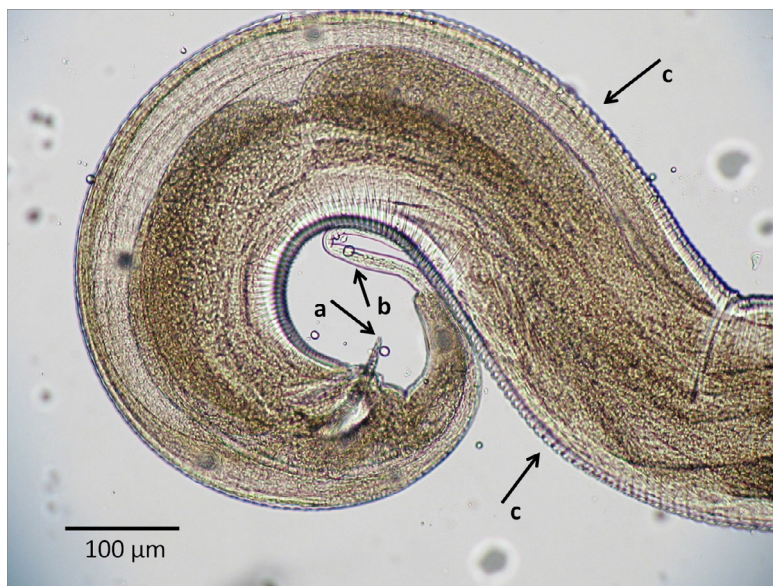


Fig. 2. Posterior end of a male *Passalurus ambiguus*, found in *Lepus europaeus*, illustrating copulatory spicules (a), finely-pointed tail (b) and striated cuticle (c)

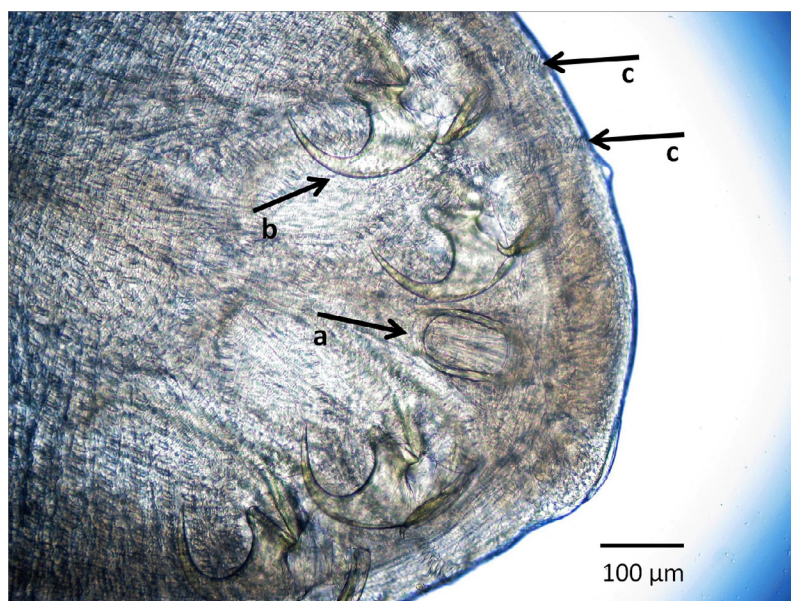


Fig. 3. *Linguatula serrata* nymph, found in *Lepus europaeus*, illustrating mouth opening (a), hooks (b), and cuticular spines (c)

ment were discharged. Drops of the sediment were placed on a microscope slide and covered with a cover slip. All the preparations were examined under the optical microscope at 100×, 400× and 1000× magnification. Comparison between single and mixed infections was performed by one-sample t-test ($p < 0.05$).

Results

Parasites were found in 62 (73.8 %) of the 84 gastrointestinal tracts examined. The most prevalent nematode was *Trichostrongylus retortaeformis* in 42 (50 %) animals (Fig. 1), followed by *Trichuris leporis* found 18 (21.42 %) animals and *Passalurus ambiguus* in 4 (4.76 %) (Fig. 2). Regarding the faecal examination, the coccidian *Eimeria* spp. was found in 54 (64.28 %) of the faecal samples, first

stage larvae (L1) of the nematode *Protostrongylus* spp. were found in 2 (1.22 %) and eggs of the trematode *Dicrocoelium dentriticum* were found in 8 (9.52 %) faecal samples.

Linguatula serrata larvae (Fig. 3) were a parallel finding on the serosa of 16 (19.04 %) of the gastrointestinal tracts. In addition, a female *Dirofilaria scapiceps* (Fig. 4) was found incidentally on the intestines of one animal (Table 1). Finally, no *Cryptosporidium* oocysts were found in the stained faecal smears.

Mixed infections (Fig. 5) were significantly more common than single infections ($p < 0.05$) and were noted in 38 of the 62 infected animals. In particular, 2 parasitic species were found in 10 (11.9 %) animals, 3 in 16 (19.04 %), 4 in 10 (11.9 %) and 5 in 2 (2.38 %) animals.

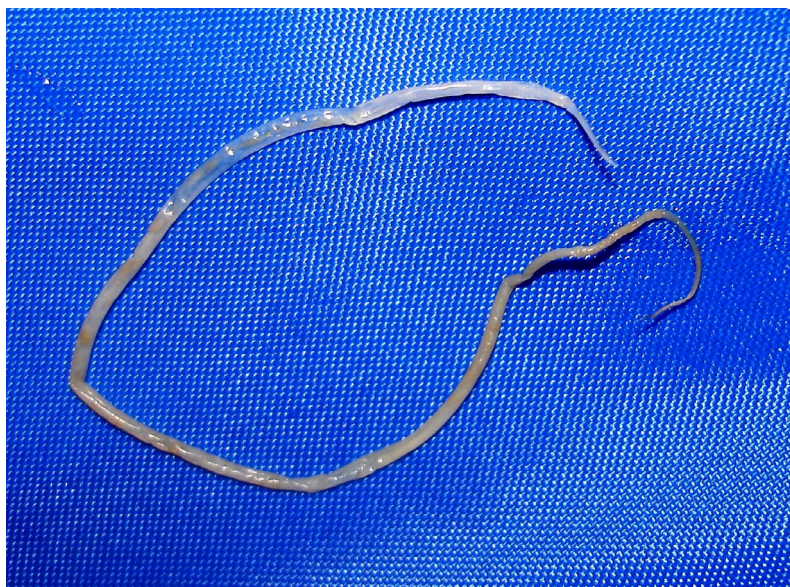


Fig. 4. The filarial nematode *Dirofilaria scapiceps* (85 mm long), found in *Lepus europaeus*

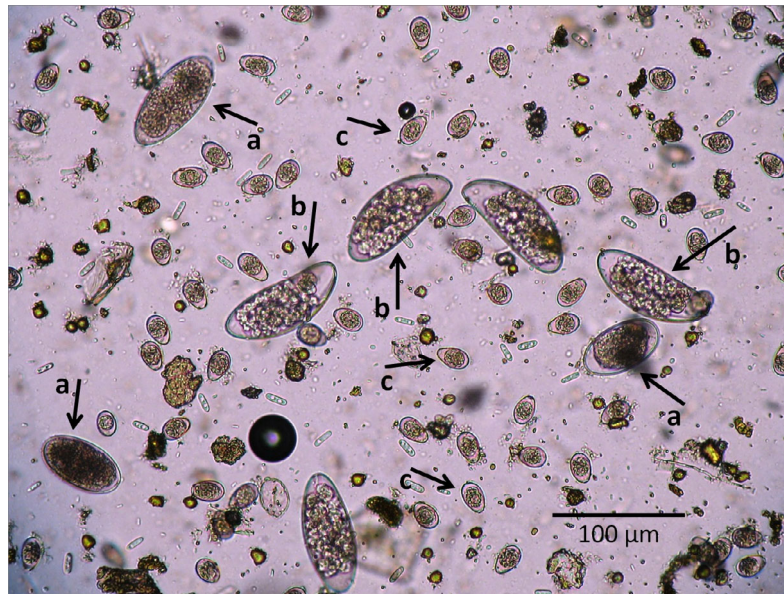


Fig. 5. Nematode eggs (a: *Trichostrongylus* sp., b: *Passalurus ambiguus*) and *Eimeria* oocysts (c) found in faeces of *Lepus europaeus*, by zinc sulphate flotation (mixed infection)

Discussion

Parasitic infections are an expected feature among free-ranging and wild animals. Their impact on the health status of the host is closely related to environmental parameters such as weather conditions, food supply, population density, other pathogens etc. It has been noted that in brown hares, parasitic infections, both of the lungs and intestines, influenced the health status and decreased the body weight of the animals (Chroust *et al.*, 2012) and that mixed infections often lead to enhancement of these adverse effects of the parasites (Lukešová *et al.*, 2012).

Only a few studies of the endoparasites of European hares have been conducted in Southern Europe (Bordes *et al.*, 2007; Alzaga *et al.*, 2009). The information regarding the parasitofauna of brown hares in South – Eastern Europe is even poorer. This is the first report of endoparasites of *L. europaeus* in Greece.

The percentage of hares that bear one or more parasitic species in the present study was high (73.8 %). The most prevalent parasites found were *Eimeria* spp. (64.28 %). In

23 (28 %) cases of positive samples the parasites were particularly abundant i.e. >100 oocysts/ field of view in 100× magnification. Coccidian infection can be very prevalent, reaching in some populations 60 – 100 % of the animals (Wibbelt & Frölich, 2005). Various species of *Eimeria* have been reported in hares, with some of the most prevalent being *E. europea*, *E. hungarica*, *E. robertsoni*, *E. semisculpta*, *E. septentrionalis*, *E. stefanskii*, *E. townsendii* and *E. leporis*, often connected with severe catarrhal enteritis, gaseous distension of the gut and even intussusception (Boch & Schneidawind, 1988; McCulloch *et al.*, 2004). These reports indicate that hares are vulnerable to coccidian infections. Young or naive adult animals are particularly sensitive and severe infections, in combination with conditions such as cold weather or food shortage can be fatal (Wibbelt & Frölich, 2005). In the Czech Republic coccidia were responsible for approximately 62 % of the total parasitic infections leading to death in brown hares (Sterba, 1982).

Trichostrongylus retortaeformis is a very common nematode in the small intestine of brown hares. The prevalence of this parasite in the present study was high (50 %), although even higher percentages have been recorded in central Europe in the past, reaching 85 % in Austria and 86 % in the Czech Republic, as referred in Chroust *et al.* (2012). However, a relatively low prevalence i.e. 6.76 % was recorded in Slovakia (Dubinský *et al.*, 2010). Severe infections by this parasite can result in chronic enteritis, with hyperaemia, petechiae and epithelial erosions (Chroust *et al.*, 2012). In the present research, no visible lesions of the intestinal mucosa were observed, even in animals with high parasite abundance.

The whipworm *Trichuris leporis* is found in the caecum and large intestine of brown hares. A review of the literature reveals confusion about the species of the genus *Trichuris* identified in *L. europaeus* (Baker, 2008). Although

Table 1. Prevalence of parasitic infections in hares (*Lepus europaeus*) in Macedonia, Greece, found by inspection of the stomach and intestines and by faecal examination

Parasite	n (%) of positive animals
<i>Eimeria</i> spp. ^a	54 (64.28)
<i>Dicrocoelium dentriticum</i> ^a	8 (9.52)
<i>Trichostrongylus retortaeformis</i>	42 (50)
<i>Trichuris leporis</i>	18 (21.42)
<i>Passalurus ambiguus</i>	4 (4.76)
<i>Protostrongylus</i> spp. ^a	2 (2.38)
<i>Linguatula serrata</i>	16 (19.04)

^a faecal examination

two species, i.e. *T. leporis* and *T. sylvilagi* have been reported from lagomorphs all over the world, Kutzer (1978) concludes that *T. sylvilagi*, Tiner 1950, is a synonym of *T. leporis*, Zeder 1803. *Trichuris* spp. produces toxic metabolites that are responsible for necrotic lesions of the gut wall (Wibbelt & Frölich, 2005). The prevalence of this parasite in the present study was 21.42 %, while it has been reported in higher percentages in central and northern Europe in the past (Sebek, 1969; Irvin, 1970; Dubinský *et al.*, 2010).

Larvae (L1) of the lung nematode *Protostrongylus* sp. were found in the faeces of two (2.38 %) animals. Since detection of this infection was made only by faecal examination, species identification was not possible. However, *Protostrongylus pulmonalis* (syn. *commutatus*) is the species identified in brown hares (Boch & Schneidawind, 1988; Costantini *et al.*, 1990; Chroust *et al.*, 2012). The prevalence of infection reported in previous surveys varies widely between 0 % and 60 % in different populations (Boch & Schneidawind, 1988; Frölich *et al.*, 2003; Chroust *et al.*, 2012). Severe cases of lungworm infection comprise dyspnoea and nasal discharge due to catarrhal pneumonia and pleuritis (Kötsche & Gottschalk, 1990). Kutzer and Frey (1976) reported adverse effects of this parasite on the body condition and general health of hares. They also observed that mortality rate due to bacterial infections is twofold higher in hares affected by this lungworm than in non-parasitised hares. In contrast, Laakkonen (2006) reported that the condition and weight of Finnish hares did not show any significant association with the intensity of lungworm infection.

Passalurus ambiguus is an oxyurid pinworm, specific to lagomorphs. The adult worm lives in the cecum or anterior colon and usually is clinically insignificant (McClure, 2011). According to Chroust *et al.* (2012) this parasite is rarely reported in brown hares and with a low prevalence (<1 %). However, *P. ambiguus* was found in 12.16 % of the hares in Slovakia (Dubinský *et al.*, 2010) and in 4 (4.76 %) of the hares in the present study. In one of these animals, the eggs of the parasite were not detected in the faecal examination, because, as found in the microscopic study of the parasites isolated from the intestine, they were immature.

European brown hares may be infected with the lancet fluke *Dicrocoelium dendriticum* in areas with sheep at pasture (Chroust *et al.*, 2012). In the present study, eggs of this trematode were found in 8 (9.52 %) of the animals by faecal examination (sedimentation method). *Dicrocoelium dendriticum* in Greece is a common parasite in small ruminants. According to Theodoropoulos *et al.* (2002), *D. dendriticum* fluke's contribution to marketable organ condemnation in abattoir is 26 %. Infection of hares with *D. dendriticum* is usually subclinical, but sometimes is associated with hyperplastic lesions of the hepatic bile ducts (Wibbelt & Frölich, 2005).

Cryptosporidium spp. is a protozoan parasite, occasionally causing zoonotic gastroenteritis (cryptosporidiosis). It has been found in a great range of animal species. To the best

of the authors' knowledge, there is no report of *Cryptosporidium* infection in *L. europaeus* in international literature. Similarly, in the present study, no *Cryptosporidium* oocysts were found in the hares examined (Ziehl-Neelsen stained faecal smears).

The pentastomid *Linguatula serrata* has been reported in *L. europaeus* among other animals (Christoffersen & De Assis, 2013). Herbivores serve as intermediate host of the parasite while carnivores are the final host, bearing the adult parasite in the nasal cavities. Larvae of this parasite were found on the serosa of the intestines in 18 (21.42 %) animals examined in the present study. This prevalence would probably be higher if the whole peritoneal cavity of the animals had been examined. *L. serrata* infection is very common in Greece, at least in the Northern part of the country, where sheep, goats and carnivores are often found infected (Diakou, unpublished data).

An adult female filariid nematode was incidentally found on the intestines of one hare, presumably originating from some other part of the animal's body. According to the literature, *Dirofilaria scapiceps* is specific to lagomorphs, parasitizing between the synovial sheath and tendons (Bartlett, 1984).

Mortality of European brown hares can be ascribed to several factors. In an analysis of the cause of death of 2269 wild brown hares in the Czech Republic, parasitic infections came first, together with dietary factors (Sterba, 1982). Some environmental conditions, like rain and humidity, favor the spread of endoparasites by increasing the persistence of infective stages in the environment (Stromberg, 1997) while others such as low temperatures contribute to the pathogenicity of parasites like *T. gondii* (Jokelainen *et al.*, 2011). In the present study, there was no occasion to assess the general health status of the animals, as they were all killed by hunters and only the gastrointestinal tract was presented to the Laboratory. However, two of the animals with particularly high abundance of parasites and mixed infection (5 species), were of poor body condition, according to the information given by the hunters. This observation is in accordance with the conclusion stated by Chroust (1984), that coccidia in combination with lung and digestive tract nematodes, can be a major regulatory factor of the hare population.

The results of the present, preliminary study indicate that hares share species of endoparasites, such as *D. dendriticum* and *L. serrata* with other animal species, and thus may represent a reservoir of these parasites in nature. Moreover, the parasites found, under certain conditions, may play an important role in the health status of hares in Macedonia, Northern Greece. Therefore, a more detailed study is planned in order to evaluate how parasitic burden and pathogenesis influence the fitness of hares and its population dynamics, longitudinally.

Acknowledgements

The authors would like to thank Ms. Androniki Tamvaki, Ecological modeling, Department of Marine Sciences,

University of the Aegean, Greece for the statistical analysis of the data, and Ms. Anne Beavan for improving the English language of the article.

References

- ALZAGA, V., TIZZANI, P., ACEVEDO, P., RUIZ-FONS, F., VICENTE, J., GORTAZAR, C. (2009): Deviance partitioning of host factors affecting parasitization in the European brown hare (*Lepus europaeus*). *Naturwissenschaften*, 96(10): 1157 – 1168. DOI: 10.1007/s00114-009-0577-y
- ALZAGA, V., VICENTE, J., VILLANUA, D., ACEVEDO, P., CASAS, F., GORTAZAR, C. (2008): Body condition and parasite intensity correlates with escape capacity in Iberian hares (*Lepus granatensis*). *Behav. Ecol. Sociobiol.*, 62 (5): 769 – 775. DOI: 10.1007/s00265-007-0502-3
- BAKER, D. G. (2008): Flynn's Parasites of Laboratory Animals *Blackwell Publishing Professional, Iowa USA*, 472.
- BARTLETT, C. M. (1984): Pathology and epizootiology of *Diriofilaria scapiceps* (Leidy, 1886) (Nematoda: Filarioidea) in *Sylvilagus floridanus* (J.A. Allen) and *Lepus americanus* erxleben. *J. Wildl. Dis.*, 20(3): 197 – 206
- BOCH, J. SCHNEIDAWIND, H. (1988). *Krankheiten des jagdbaren Wildes*, Verlag Paul Parey.
- BORDES, F., LANGAND, J., FELIU, C. MORAND, S. (2007): Helminth communities of an introduced hare (*Lepus granatensis*) and a native hare (*Lepus europaeus*) in southern France. *J. Wildl. Dis.*, 43(4): 747 – 751
- CHRISTOFFERSEN, M. L. DE ASSIS, J. E. (2013): A systematic monograph of the Recent Pentastomida, with a compilation of their hosts. *Zool. Meded.*, 29(iii): 1 – 206
- CHROUST, K. (1984): Dynamics of coccidial infection of free-living and cage-reared European hares. *Acta Vet. Brno*, 53: 175 – 182
- CHROUST, K., VODNANSKY, M. J., P. (2012): Parasite load of European brown hares in Austria. *Vet. Med. (Praha)*, 57(10): 551 – 558
- COSTANTINI, R., MANFREDI, M. T., IORI, A. PACETTI, A. (1990): *Protostrongylus pulmonalis* from hares (*Lepus europaeus*) in Italy. *Parassitologia*, 32(3): 353 – 357
- DUBINSKÝ, P., VASILKOVÁ, Z., HURNÍKOVÁ, Z., MITERÁKOVÁ, M., SLAMEČKA, J. JURČÍK, R. (2010): Parasitic infections of the European brown hare (*Lepus europaeus* Pallas, 1778) in south-western Slovakia. *Helminthologia*, 47(4): 219 – 225. DOI: 10.2478/s11687-010-0034-7
- FRÖLICH, K., WISSER, J., SCHMÜSER, H., FEHLBERG, U., NEUBAUER, H., GRUNOW, R., NIKOLAOU, K., PRIEMER, J., THIEDE, S., STREICH, W. J. SPECK, S. (2003): Epizootiologic and ecologic investigations of European brown hares (*Lepus europaeus*) in selected populations from Schleswig-Holstein, Germany. *J. Wildl. Dis.*, 39(4): 751 – 761
- HARALABIDIS, S. DIAKOU, A. (2001). *Diagnosis of Parasitic Diseases*, Thessaloniki, University Studio Press.
- HENRIKSEN, S. A. POHLENZ, J. F. L. (1981): Staining of Cryptosporidia by a modified Ziehl-Neelsen technique. *Acta Vet. Scand.*, 22: 594 – 596
- IRVIN, A. D. (1970): Gastrointestinal parasites of British hares (*Lepus europaeus* and *Lepus timidus*). *J. Zool.*, 162: 544 – 546
- JOKELAINEN, P., ISOMURSU, M., NÄREAHO, A. OKSANEN, A. (2011): Natural *Toxoplasma gondii* infections in European brown hares and mountain hares in Finland: proportional mortality rate, antibody prevalence, and genetic characterization. *J. Wildl. Dis.*, 47(1): 154 – 163
- KÖTSCHKE, W., GOTTSCHALK, C. (1990). *Krankheiten der Kaninchen und Hasen. (Diseases of rabbits and hares)*, Fischer, Jena.
- KUTZER, E. (1978): Notes to the hare-whipworm *Trichuris leporis* (Zeder, 1803) (author's translation). *Z. Parasitenkd.*, 56(1): 69 – 72
- KUTZER, E. FREY, H. (1976): Parasites of brown hares (*Lepus europaeus*) in Austria (in German). *Berl. Munch. Tierarztl. Wochenschr.*, 89: 480 – 483
- LAAKKONEN, J. N. T., HILTUNEN, M., KAUKHALA K., NIKANDER, S., SOVERI, T. (2006): Effects of *Protostrongylus* sp. and *Pneumocystis* sp. on the pulmonary tissue and the condition of mountain and brown hares from Finland. *J. Wildl. Dis.*, 42(4): 780 – 787
- LAMARQUE, F., BARRAT, J. MOUTOU, F. (1996): Principal diagnoses for determining causes of mortality in the European brown hare (*Lepus europaeus*) found dead in France between 1986 and 1994. *Gibier Faune Sauvage*, 13(1): 53 – 72
- LEGAKIS, A. MARAGOU, P. (2009). *The Red Data Book of Threatened Animals of Greece*. Hellenic Zoological Society.
- LUKEŠOVÁ, D., LANGROVÁ, I., VADLEJCH, J., JANKOVSKÁ, I., HLAVA, J., VÁLEK, P. ČADKOVÁ, Z. (2012): Endoparasites in European hares (*Lepus europaeus*) under game-keeping conditions in the Czech Republic. *Helminthologia*, 49(3): 159 – 163. DOI:10.2478/s11687-012-0032-z
- MAFF (1986). *Manual of Veterinary Parasitological Laboratory Techniques*.
- MCCLURE, D. (2011): Parasitic Diseases of Rabbits. In: *The Merck Veterinary Manual Online*. Retrieved February 8, 2014, from http://www.merckmanuals.com/vet/exotic_and_laboratory_animals/rabbits/parasitic_diseases_of_rabbits.html.
- MCCULLOCH, C. R., PROSL, H. SCHMIDT, P. A. S. (2004): A spontaneous and fatal jejunal intussusception in a European brown hare associated with *Eimeria leporis*. *J. Vet. Med. B Infect. Dis. Vet. Public Health*, 51: 470 – 472
- NEWWEY, S., THIRGOOD, S. J. HUDSON, P. J. (2004): Do parasite burdens in spring influence condition and fecundity of female mountain hares *Lepus timidus*? *Wildlife Biol.*, 10(3): 171 – 176
- SEBEK, J. (1969): Parasitic infections in hares from Nový Prerov near Breclav (in Czech). *Veterinarství*, 19: 353 – 354
- SFOUGARIS, A., PAPAGEORGIOU, N., GIANNAKOPOULOS, A. H., G. (1999): Distribution, populations and habitat of the European hare (*Lepus europaeus*) in Central and Western Greece. In THOMAIDIS, C., KYPRIDEMOS, N. (Eds) *Proceedings of the 24th Congress of International Union of Game Biologists, Sept. 20 – 24, 1999*. Thessaloniki, Greece, pp. 423 – 430
- SMITH, A. T. JOHNSTON, C. H. (2008). *Lepus europaeus*. In: *IUCN 2010. IUCN Red List of Threatened Species*.

- SMITH, R. K., JENNINGS, N. V. HARRIS, S. (2005): A quantitative analysis of the abundance and demography of European hares *Lepus europaeus* in relation to habitat type, intensity of agriculture and climate. *Mamm. Rev.*, 35(1): 1 – 24. DOI: 10.1111/j.1365-2907.2005.00057.x
- SOKOS, C. K., SKORDAS, K. E. BIRTSAS, P. K. (2003): Valuation of hunting and management of brown hare (*Lepus europaeus*) in rangelands. In *Proceedings of 3rd Pan-Hellenic Rangelands Conference. Hellenic Rangelands and Pasture Society, 4 – 6 September 2002*, Karpenissi, Greece. Retrieved from <http://www.panida.gr/site/wp-content/uploads/2003-harehunters.pdf> (In Greek)
- STERBA, F. (1982): Main mortal causes in the European brown hare in 1975 – 1979. *Folia Venat.*, 12: 239 – 260 (In Czech)
- STROMBERG, B. E. (1997): Environmental factors influencing transmission. *Vet. Parasitol.*, 72(3 – 4): 247 – 264. DOI: 10.1016/S0304-4017(97)00100-3
- THEODOROPOULOS, G., THEODOROPOULOU, E., PETRAKOS, G., KANTZOURA, V. KOSTOPOULOS, J. (2002): Abattoir condemnation due to parasitic infections and its economic implications in the region of Trikala, Greece. *J. Vet. Med. B Infect. Dis. Vet. Public Health*, 49(6): 281 – 284. DOI: 10.1046/j.1439-0450.2002.00563.x
- THIENPONT, D., ROCHETTE, F. VANPARIJS, O. F. J. (1986): *Diagnosing helminthiasis by coprological examination*, Beerse (Belgium): Janssen Research Foundation.
- WIBBELT, G. FRÖLICH, K. (2005): Infectious Diseases in European Brown Hare (*Lepus europaeus*). *Wildl. Biol. Pract.*, 1(1): 86 – 93. DOI: 10.2461/wbp.2005.1.11
- YAMAGUTI, S. (1961). *Systema Helminthum. Vol. III. The nematodes of vertebrates*, New York & London: Interscience Publishers Inc.

RECEIVED JUNE 4, 2014

ACCEPTED JULY 15, 2014