

“Benign” myoclonic epilepsy of infancy as the initial presentation of glucose transporter-1 deficiency

Nicolas Gaspard¹, Arvid Suls^{2,3,4}, Catheline Vilain⁵, Peter De Jonghe^{2,3,4,6}, Patrick Van Bogaert¹

¹ Department of Pediatric Neurology, ULB-Erasme Hospital, Brussels

² Neurogenetics Group, VIB Department of Molecular Genetics, Antwerp

³ Laboratory of Neurogenetics, Institute Born-Bunge, Antwerp

⁴ University of Antwerp, Antwerp

⁵ Department of Medical Genetics, ULB-Erasme Hospital, Brussels

⁶ Division of Neurology, University Hospital Antwerp, Antwerp, Belgium

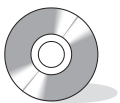Received March 17, 2011; Accepted June 1, 2011

ABSTRACT – We report the case of a young boy carrying a *de novo* missense mutation (c.1199G>T; p.R400L) in the *SLC2A1* gene who presented initially with benign myoclonic epilepsy of infancy. Eventually, he had a poor outcome with refractory generalised tonic-clonic, myoclonic and absence seizures, ataxia, significant mental impairment and slowing of head growth. He responded poorly to ketogenic diet. This case extends the phenotype of GLUT1-related syndromes and also sheds light on the genetic basis of myoclonic epilepsies of infancy suggesting that variable outcome may depend on genetic factors. [Published with video sequences]

Key words: SLC2A1, De Vivo syndrome, seizure, children, myoclonus, myoclonic epilepsy of infancy

Of the idiopathic generalised epilepsy (IGE) syndromes, the earliest onset is that of benign myoclonic epilepsy of infancy (MEI) (Auvin *et al.*, 2006; Dravet and Bureau, 2005; Lin *et al.*, 1998). The genetic basis of MEI is unknown. Its prognosis is usually good, with spontaneous seizure remission and normal cognitive outcome (Auvin *et al.*, 2006; Dravet and Bureau, 2005; Lin *et al.*, 1998). However, recent retrospective series suggest that up to 30% of affected children develop either other seizure types or cognitive or

learning impairment as they grow older (Mangano *et al.*, 2005). This prompted the ILAE Classification Core Group to remove the word “benign” from the name of this syndrome (Engel, 2006). Mutations in the *SLC2A1* gene are associated with a spectrum of neurological disorders, including IGE syndromes such as early-onset, juvenile or adult-onset absence epilepsy (Mullen *et al.*, 2010). Here we describe the case of a young boy who presented with typical MEI but had a poor evolution



Correspondence:

N. Gaspard
Department of Pediatric Neurology,
ULB-Hôpital Erasme,
808 Route de Lennik, 1070 Brussels,
Belgium
<ngaspard@ulb.ac.be>

with refractory generalised seizures and psychomotor impairment. Genetic studies revealed a *de novo* missense mutation in the *SLC2A1* gene.

Case study

This boy was first evaluated at six months of age because of a recent occurrence of jerks. He had no significant personal or familial history and normal development milestones. Physical and neurological examinations were normal, with a head circumference of 44 cm (percentile 50). Video-electroencephalographic (EEG) recording disclosed a normal background and occurrence of spontaneous myoclonic jerks, synchronous with generalised spike-and-wave discharges (*figure 1*, see *video sequence*). No reflex myoclonus could be elicited. He was treated with valproate, which led to complete seizure control with a follow-up of one year. Based on the electroclinical presentation and on the response to valproate, we made an initial diagnosis of benign MEI. However, at 18 months, he started to have recurring myoclonic seizures, *de novo* generalised tonic-clonic and absence seizures (*figure 2*) which required the addition of lamotrigine and topiramate, without satisfactory control. In addition, developmental delay as well as ataxia of gait and recession of head growth appeared, with a head circumference of 50 cm (percentile 10) at the age of four years. A lumbar puncture was then performed, showing mild hypoglycorrhachia (CSF glucose level of 39 mg/dL with a blood glucose

level of 84 mg/dL) and a presumptive diagnosis of GLUT1 deficiency syndrome (GLUT1-DS) was made. A three-month ketogenic diet (4:1) program failed to reduce seizures despite good compliance.

Sequence analysis of the *SLC2A1* gene, performed by direct sequencing according to procedures described elsewhere, revealed the presence of a heterozygous missense mutation (c.1199G>T; p.R400L) which was not observed in his parents or 275 ethnically matched control individuals (Suls *et al.*, 2009).

Discussion

Since its description in 1981, more than 150 patients with MEI have been reported (Auvin *et al.*, 2006; Dravet and Bureau, 2005; Lin *et al.*, 1998). Criteria for diagnosis proposed by Dravet *et al.* (Dravet and Bureau, 2005) are: (1) the occurrence, usually between four months and three years, of brief myoclonic seizures (which can be spontaneous and/or reflex) in an otherwise normal infant, (2) EEG showing normal background, rare interictal spike-waves enhanced by drowsiness and slow sleep which may be evoked by intermittent photic stimulation, and generalised spike-waves, polyspikes and/or polyspike-waves during myoclonic seizures, and (3) good response to valproate. Our patient thus fulfilled all the above criteria at the time of presentation. Since the earliest description of the syndrome, it was stressed that prognosis was usually good. Seizures typically abate with time, antiepileptic treatment may be stopped and most children have a normal

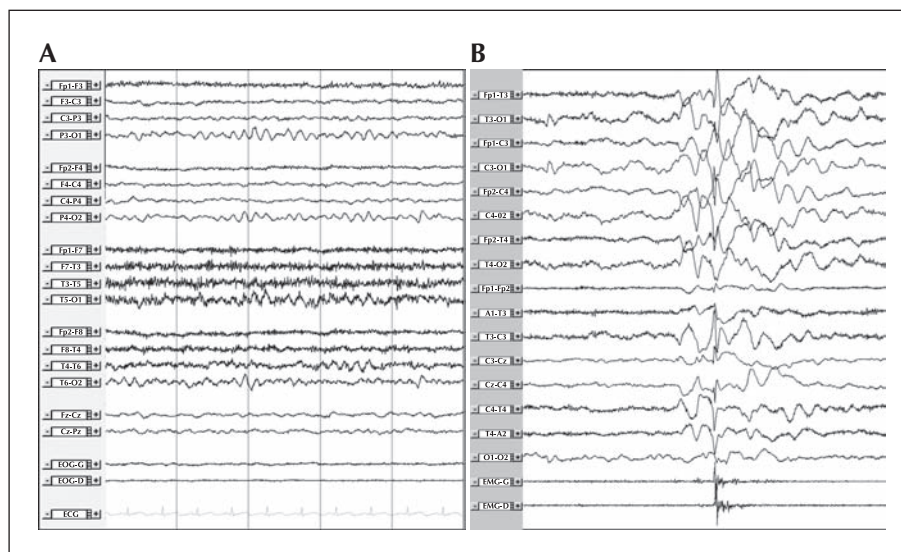


Figure 1. Sample of interictal (A) and ictal (B) EEG recordings at six months of age. Bipolar longitudinal montage with midline electrodes was used in (A) and bipolar longitudinal (rows 1-8) and transversal montage (rows 9-16) used in (B); time scale is 1 second per time division and 300 μ V per cm. **A** The interictal recording shows a normal background with a 6-Hz posterior dominant rhythm. **B** The ictal recording shows a myoclonic seizure; a generalised spike-and-wave discharge closely followed by a burst of EMG activity (myoclonus) (refer to *video sequence*).

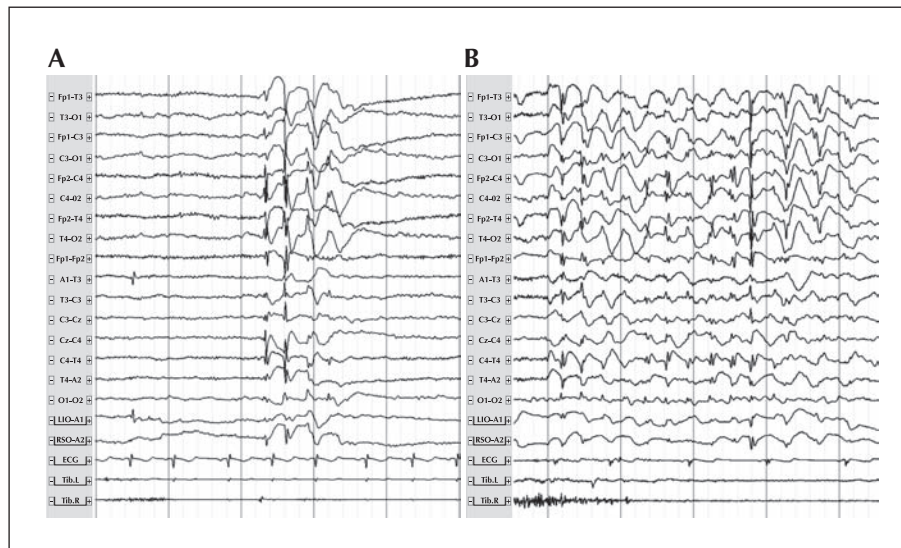


Figure 2. Sample of interictal (**A**) and ictal (**B**) EEG recordings at six years of age. Bipolar longitudinal (rows 1-8) and transversal montage (rows 9-16) in (**B**); time scale is 1 second per time division and sensitivity 300 μV per cm. **A**) The interictal recording shows a burst of 3-Hz generalised spike-and-wave discharges. **B**) The ictal recording shows an absence seizure with a 3-Hz generalised spike-and-wave.

development. Although myoclonic seizures gradually disappear in most children, a significant minority present other seizure types at a later age, including generalised tonic-clonic and early-onset absence seizures (Caraballo *et al.*, 2011; Dravet and Bureau, 2005). Evolution to typical juvenile myoclonic epilepsy has also been reported (Auvin *et al.*, 2006). Psychological outcome is also favourable for most children achieving normal IQ. Again, however, 20% show a significant cognitive or learning impairment (Mangano *et al.*, 2005). These differences in outcome might be related to a delay in treatment onset and seizure control, inappropriate educational attitudes or to side effects of treatment, as suggested by various authors. Our findings, however, offer another explanation. Indeed, we suggest that some cases initially presenting as benign MEI but with atypical evolution, including early-onset absence seizures, pharmacoresistance and cognitive impairment, might be attributed to a GLUT1 glucose transporter deficiency due to a mutation in the *SLC2A1* gene. Typical manifestations of the GLUT1-DS, or DeVivo syndrome, include developmental delay, ataxia, hypotonia and acquired microcephaly in association with a reduced CSF glucose concentration. Infantile seizures are frequent and of various types: generalised tonic and/or clonic, absence, myoclonic, atstatic and partial seizures (Leary *et al.*, 2003). In addition, some *SLC2A1* mutations result in milder phenotypes associated with a wide range of epilepsies, including early-onset, juvenile and adult-onset absence epilepsy (Mullen *et al.*, 2010; Suls *et al.*, 2009), myoclonic absence epilepsy and other classic IGE syndromes. Despite a less severe course than the

classic phenotype, ataxia and cognitive impairment may occur, as was the case in our patient. Ketogenic diet is considered as the treatment of choice for GLUT1-DS, with a positive effect being expected on seizures and other features of the disease, such as paroxysmal movement disorders or cognitive impairment. However, some children, including our patient, do not show any benefit from the diet (Leen *et al.*, 2010).

The missense mutation we identified (c.1199G>T) is predicted to lead to a single amino acid arginine-to-leucine substitution (p.R400L). Although we did not perform functional analysis, evidence from the literature supports the pathological nature of the mutation. The highly conserved arginine residue involved is predicted to be required for substrate affinity of the transporter (Salas-Burgos *et al.*, 2004) and substitution of the corresponding arginine to lysine in GLUT4, a paralogue of GLUT1, has been shown to abolish transport activity *in vitro* (Schurmann *et al.*, 1997). In addition, the mutation was not found in the parents of our patient or control individuals.

Very little is known of the genetics of MEI. Autosomal recessive inheritance has been reported in one family with linkage to chromosome 16p13.3 (Zara and De Falco, 2005) and a family history of febrile seizures or idiopathic epilepsy syndrome is reported in some sporadic cases (Auvin *et al.*, 2006; Dravet and Bureau, 2005; Lin *et al.*, 1998). However, no genetic defect has been reported so far. Our findings, thus, for the first time, shed light on the genetic basis of atypical cases of MEI and may offer an explanation for its variable outcome. We suggest that MEI is a heterogeneous

syndrome, from both clinical and genetic perspectives, with multiple different molecular substrates. We propose that other cases with an atypical or poor outcome, including the occurrence of seizure types other than myoclonic seizures, poor seizure control and abnormal development, might be linked to *SLC2A1* mutations. For these cases, the adjective “benign” should indeed be dropped. The genetic basis and the role of the *SLC2A1* gene in the typical benign cases, as well as the role of yet undiscovered genes, remain to be solved. □

Disclosure.

Dr. Suls is a postdoctoral researcher of the National Fund for Scientific Research of Flanders (FWO).

Prof. Dr. De Jonghe has received speaker honoraria from Biocodex; has received funding for travel from UCB and Biocodex; serves on the editorial board of *Acta Neurologica Belgica*; and receives/has received research support from the National Fund for Scientific Research of Flanders (FWO), Methusalem excellence grant of the Flemish Government, The University of Antwerp, and The Belgian Science and Policy Office.

Legend for video sequence

Excerpt of video-EEG recording demonstrating a myoclonic seizure.

Key words for video research on www.epilepticdisorders.com

Etiology: GLUT-1 deficiency

Phenomenology: myoclonic seizure, generalized, absence (dialeptic) seizure

Localization: —

Syndrome: myoclonic epilepsy in infancy

References

- Auvin S, Pandit F, De Bellecize J, *et al.* Benign myoclonic epilepsy in infants: electroclinical features and long-term follow-up of 34 patients. *Epilepsia* 2006; 47: 387-93.
- Caraballo RH, Darra F, Fontana E, Garcia R, Monese E, Dalla Bernardina B. Absence seizures in the first 3 years of life: an electroclinical study of 46 cases. *Epilepsia* 2011; 52: 393-400.
- Dravet C, Bureau M. Benign myoclonic epilepsy in infancy. *Adv Neurol* 2005; 95: 127-37.
- Engel J Jr. Report of the ILAE classification core group. *Epilepsia* 2006; 47: 1558-68.
- Leary LD, Wang D, Nordli DR Jr, Engelstad K, De Vivo DC. Seizure characterization and electroencephalographic features in Glut-1 deficiency syndrome. *Epilepsia* 2003; 44: 701-7.
- Leen WG, Klepper J, Verbeek MM, *et al.* Glucose transporter-1 deficiency syndrome: the expanding clinical and genetic spectrum of a treatable disorder. *Brain* 2010; 133: 655-70.
- Lin Y, Itomi K, Takada H, *et al.* Benign myoclonic epilepsy in infants: video-EEG features and long-term follow-up. *Neuropediatrics* 1998; 29: 268-71.
- Mangano S, Fontana A, Cusumano L. Benign myoclonic epilepsy in infancy: neuropsychological and behavioural outcome. *Brain Dev* 2005; 27: 218-23.
- Mullen SA, Suls A, De Jonghe P, Berkovic SF, Scheffer IE. Absence epilepsies with widely variable onset are a key feature of familial GLUT1 deficiency. *Neurology* 2010; 75: 432-40.
- Salas-Burgos A, Iserovich P, Zuniga F, Vera JC, Fischbarg J. Predicting the three-dimensional structure of the human facilitative glucose transporter glut1 by a novel evolutionary homology strategy: insights on the molecular mechanism of substrate migration, and binding sites for glucose and inhibitory molecules. *Biophys J* 2004; 87: 2990-9.
- Schurmann A, Doege H, Ohnimus H, Monser V, Buchs A, Joost HG. Role of conserved arginine and glutamate residues on the cytosolic surface of glucose transporters for transporter function. *Biochemistry* 1997; 36: 12897-902.
- Suls A, Mullen SA, Weber YG, *et al.* Early-onset absence epilepsy caused by mutations in the glucose transporter GLUT1. *Ann Neurol* 2009; 66: 415-9.
- Zara F, De Falco FA. Autosomal recessive benign myoclonic epilepsy of infancy. *Adv Neurol* 2005; 95: 139-45.