



Benign Papillary Breast Mass Lesions: Favorable Outcomes with Surgical Excision or Imaging Surveillance

Gillian Kuehner, MD¹, Jeanne Darbinian, MS, MPH², Laurel Habel, PhD², Karen Axelsson, MD³, Sherry Butler, MD⁴, Sharon Chang, MD⁵, Rhona Chen, MD⁶, and Lou Fehrenbacher, MD⁷

¹Department of Surgery, The Permanente Medical Group, Vallejo, CA; ²Division of Research, Kaiser Permanente Northern California, Oakland, CA; ³Department of Pathology, The Permanente Medical Group, Oakland, CA; ⁴Department of Radiology, The Permanente Medical Group, South San Francisco, CA; ⁵Department of Surgery, The Permanente Medical Group, Fremont, CA; ⁶Department of Surgery, The Permanente Medical Group, South San Francisco, CA; ⁷Kaiser Permanente Oncology Clinical Trials Northern California, Vallejo, CA

ABSTRACT

Background. There is no consensus regarding the management of benign papillary breast lesions diagnosed on image-guided core needle biopsy (IGCNB).

Methods. This is a retrospective review of 407 patients within Kaiser Permanente Northern California diagnosed between 2012 and 2013. The study focused on patients presenting with a mass lesion and who were diagnosed with a benign papillary breast lesion (BPBL) on IGCNB. Patients who did not have surgical excision of the IGCNB papilloma were followed for at least 2 years.

Results. A total of 327 patients (80%) underwent surgical excision, 61 patients (15%) had follow-up imaging, and 19 patients (5%) had no surgery or imaging. Overall among women with surgical excision, 9.5% had a high-risk lesion, 3.4% had in situ cancer, and 2.4% had invasive cancer. An upgrade to an in situ cancer or invasive cancer was more common among women with a lesion greater than 1 cm, a palpable breast mass, age > 50 years, or if the lesion was > 5 cm from the nipple. No cancers were diagnosed in 61 women followed by imaging surveillance.

Conclusions. This is the largest, single-cohort study of benign papillary mass lesions diagnosed on IGCNB. On surgical excision, the overall rate of upgrade to in situ cancer and invasive cancer was low, and almost all cancers diagnosed had favorable features. Because no cancers were

found in women who were followed by imaging, we conclude that outcomes for BPBL diagnosed on IGCNB are favorable whether surgical excision or surveillance is the treatment choice.

Image-guided core needle biopsy (IGCNB) is the “gold standard” for diagnosing breast abnormalities. However, making a definitive diagnosis of a breast lesion based on a core needle sample can be challenging. This is particularly true for breast papillary lesions, which cover a spectrum of disease, including benign papillomas, papillomas with atypia, papillary carcinoma in situ, encapsulated papillary cancers, and invasive papillary carcinoma. Distinguishing between these diagnoses is difficult because of subtle differences that define each category. Core needle biopsies can have inherent sampling issues, especially if the architecture of the lesion cannot be determined due to a fragmented or small specimen. Until relatively recently, studies proposed that all benign papillary breast lesions (BPBLs) on IGCNB be surgically excised for definitive diagnosis.^{1–8}

The first study challenging this recommendation was published in 2011 by Chang et al.⁹ The authors prospectively looked at patients diagnosed by 11-gauge, vacuum-assisted, needle biopsy (VAB) who then went on to surgical excision. They found a zero percent upgrade to malignancy rate. However, with only 49 patients in the study, it was difficult to apply these results broadly. This trial led to further studies, suggesting that after a core needle biopsy, either a VAB or surgical excision were reasonable alternatives to confirm a benign diagnosis, whereas some studies concluded that benign papillary

lesions diagnosed on core biopsy could be safely followed with imaging surveillance.^{10–20} To better define outcomes, investigators started to look for other clinical or imaging characteristics that could predict a benign result. Older age, larger size of the papillary lesion, distance of the papillary lesion from the nipple, or a combination of these variables, including radiology-pathology correlation, were all factors identified as potential predictors of outcome.^{12,21–30}

In contrast, one recent study was unable to find any clinical predictors of upgrade, although the authors noted that BPBLs are rarely upstaged to malignancy.³¹

Overall, there are multiple drawbacks to these studies: they grouped together patients with different imaging characteristics, gathered data over an extended time, had very small patient populations, many patients were lost to follow-up, or included only patients seen at an academic or referral center. Importantly, there is no description of the type of malignancies diagnosed.

Clearly there is a need for more robust data concerning BPBLs diagnosed on IGCNB, which is applicable to the general population, describes the absolute risk of cancer with immediate surgical excision, identifies variables commonly seen with upgrade, and gives a full understanding of the stage and associated prognosis of these cancers. This information is essential for informed, shared decision making between providers and patients when weighing the risks and benefits of immediate surgical excision versus imaging surveillance.

METHODS

Setting

This study was conducted within the membership of Kaiser Permanente Northern California (KPNC), a pre-paid integrated health care system with more than 4.1 million members. The membership is racially and ethnically diverse and demographically similar to the underlying population, except at the extremes of income.³² The KPNC Institutional Review Board approved this study with waiver of consent.

Study Eligibility

Potential subjects were identified by the Breast Cancer Tracking System (BCTS), a management program designed to improve the quality of breast care for KPNC members. We identified a preliminary cohort of women who underwent IGCNB from 2012 to 2013 after a breast imaging study was assigned an alert code of BIRADS 4 or 5, and the pathology report indicated that the lesion was benign. To limit variables, we chose to focus on BPBLs presenting as a solid mass lesion on imaging. We excluded

patients with papillomatosis, papillomas found incidentally, papillomas described as focal, minute, diminutive, or microscopic, as well as papillomas found on final pathology report when the target lesion was described as microcalcifications. Women had to be 18 years or older and have no history of an atypical or high-risk lesion, no prior history of breast cancer, and no known genetic mutation placing them at elevated risk for developing breast cancer.

Current Practice at KPNC

KPNC guidelines recommend screening mammography every 1–2 years. IGCNB is used as the initial diagnostic approach for all breast lesions. Ultrasound and stereotactic biopsies are performed either by a breast imaging specialist or a general radiologist. A metallic clip is placed at the biopsy site and post-procedure imaging is done to confirm accurate placement in the target lesion. Hematoxylin and eosin-stained slides of the IGCNB specimen are read by general pathologists. Generally, a recommendation is made to send patients with a benign papillary lesion to a surgeon for consultation, specifically to consider excisional biopsy.

Data Collection

Data were obtained from electronic clinical and administrative databases, including pathology reports linked to the IGCNB procedure and any subsequent surgical excision, radiology reports for the initial and follow-up breast imaging studies, and patient demographic and clinical characteristics, including age, race/ethnicity, height, weight, comorbid conditions, past medical and health plan enrollment history, and deaths during the study period. Women were designated as being in the surgical excision group if the intent was surgical excision at the time of surgical consultation. All patients, except one, underwent surgical excision of the lesion within 6 months of the initial IGCNB, and all patients had no additional imaging before surgical excision. The remainder of the patients were placed in the imaging surveillance category. Since there is no standard protocol for imaging surveillance after IGCNB showing BPBL, this recommendation is left to the discretion of the radiologist and/or consulting surgeon. A follow-up of 2 years was considered sufficient to confirm the lesion was benign.^{33,34}

We calculated the Deyo version of the Charlson comorbidity index using a 1-year pre-IGCNB capture of diagnosis and procedure codes linked to inpatient and outpatient encounters. Body mass index (BMI) was computed from height and weight measurements obtained closest to the index IGCNB.

Chart review was conducted by the study's investigators, which included three surgeons, one radiologist, and

one pathologist, using a structured data collection tool. Clinical, imaging, and pathologic characteristics required review of the patient’s Electronic Medical Record (EMR).

After initial chart review, additional exclusions were made according to the study criteria (Fig. 1). If there was more than one lesion per woman, the lesion with a final diagnosis of highest risk was selected.

The outcomes of upgrade to high-risk lesion (defined as atypical lobular hyperplasia, atypical ductal hyperplasia, papilloma with atypia, or lobular carcinoma in situ), in situ cancer, or invasive cancer were determined from chart review of relevant pathology and radiology reports, as well as abstraction from the patient’s EMR. Specific cancer characteristics were obtained from chart review and extracted

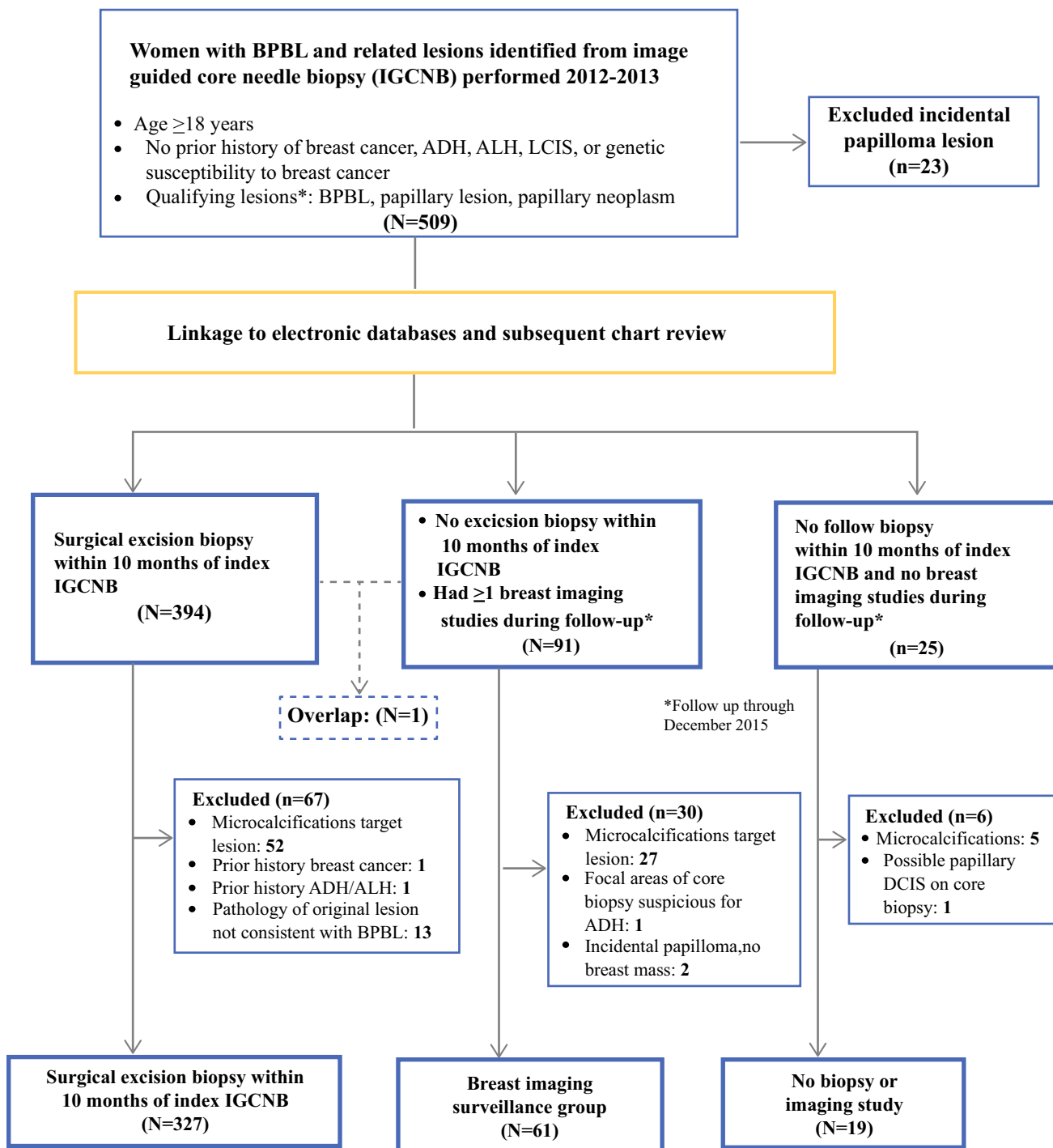


FIG. 1 Case flow diagram for benign solid papillary breast lesions

from the KPNC Cancer Registry, with excellent concordance between the two sources.

Statistical Analysis

Bivariate analysis compared demographic, clinical, and radiologic characteristics between the groups, using Chi square and Fischer exact tests for categorical variables, and *t* tests, ANOVA, and nonparametric tests (Wilcoxon two-sample and Kruskal–Wallis) for continuous variables. For women who underwent surgical excision, row percentage and 95% confidence intervals were computed for demographic and clinical characteristics by outcome (i.e., benign, high-risk, in situ cancer, or invasive cancer).

RESULTS

The final analytic cohort consisted of 407 patients, of which 327 (80%) had surgical excision, 61 (15%) had imaging surveillance, and 19 (5%) had no surgery or radiologic follow-up during the study period (Fig. 1). Subjects with and without surgical excision generally had similar age, BMI, racial/ethnic distribution, preexisting comorbid condition score, breast density, and lesion location (Table 1). However, surgical excision was statistically significantly more common among women with lesions larger than 1.5 cm ($p = 0.02$) and if the IGCNB had an aggregate volume < 1.5 cm ($p = 0.008$). Nineteen women did not undergo surgical excision or imaging surveillance (not shown). Compared with subjects in the two main study groups, these women had similar age, BMI, Charlson comorbidity index scores, breast density, and lesion location.

Of the 327 women who underwent surgical excision, 99% were performed within 6 months. Results of surgical excision showed that 9.5% had a high-risk lesion (ADH 4.9%, ALH 1.2%, LCIS 0.9%, and papilloma with atypia 2.5%), 3.4% had ductal carcinoma in situ (DCIS), and 2.4% had an invasive cancer (Table 2). An upgrade to an in situ or invasive cancer was more common among women with a lesion greater than one centimeter, a palpable breast mass, age greater than 50 years, or if the lesion was greater than 5 cm from the nipple, and less common among women with nipple discharge.

Most of the women diagnosed with invasive cancer on immediate surgical excision had early stage, low to intermediate grade, estrogen receptor (ER)-positive, node-negative tumors (Table 3). The one patient with an advanced stage at surgical excision had an 8-cm, palpable lesion with radiology-pathology discordance, and had not sought medical care for 10 years. Although considered an outlier, for completeness, this case was included in the

analysis. Women with a diagnosis of noninvasive cancer uniformly had low- or intermediate-grade lesions, and all but one patient was ER-positive.

If a woman did not undergo surgical excision, she was categorized into the imaging surveillance group. Of these patients, 70% ($n = 43$) were recommended to have increased imaging frequency—annually (10 patients), every 6 months (32 patients), or in 2 months (1 patient)—whereas 30% of patients ($n = 18$) were recommended to return to routine screening and/or imaging interval was not specified. Overall, regardless of recommendation, the first imaging exam for 49% of patients ($n = 30$) was within 7 months of IGCNB, 20% of patients ($n = 12$) had their first imaging exam 7–13 months from IGCNB, 20% of patients ($n = 12$) had their first imaging exam > 13 –24 months from IGCNB, and 11% ($n = 7$) of patients had their first imaging > 24 months after IGCNB.

Four of the 61 women in the imaging surveillance group eventually had surgical excision of the index lesion, and no cancers were found. One lesion was upgraded to high-risk (ADH). Women in this group were followed for at least 2 years and follow-up ended because of death ($n = 1$), disenrollment from the health plan ($n = 2$), or end of the study ($n = 58$).

DISCUSSION

This is the largest, published, cohort study describing outcomes of surgical excision versus imaging surveillance for women with a solid breast lesion on imaging and a benign papillary lesion on IGCNB. Importantly, this is the first study to characterize the cancer outcomes by stage and prognostic factors.

Overall there was a low rate of upgrade to invasive cancer (2.4%) or noninvasive cancer (3.4%) with immediate surgical excision. Furthermore, the cancers identified had favorable characteristics; almost all women had T1a or T1b, low- to intermediate-grade, ER-positive, node-negative tumors. Similarly, women with a diagnosis of noninvasive cancer uniformly had low- to intermediate-grade lesions, and all but one patient was ER-positive. No cancers were diagnosed in women who did not undergo immediate surgical excision, and these patients were followed for at least 2 years.

Many previous studies recommended surgical excision for all papillary lesions.^{1–8,21} However, with using a VAB, it was believed that accuracy of diagnosis was improved, and women could be offered imaging surveillance after benign VAB.^{9–11,13–15,18,24} In our study, a larger core needle sample, as measured by aggregate volume of tissue removed with IGCNB, did not suggest a benign result on surgical excision. However, there was a statistically

TABLE 1 Characteristics at time of image-guided core needle biopsy (IGCNB) of women undergoing excision versus imaging surveillance

Characteristic ^a	Total (n = 388)	Study group		P value ^c
		Surgical excision (n = 327)	Imaging surveillance (n = 61)	
Age (year)				0.27
< 50	117 (30.1)	104 (31.8)	13 (21.3)	
50–70	228 (58.8)	187 (57.2)	41 (67.2)	
> 70	43 (11.1)	36 (11.0)	7 (11.5)	
Race/ethnicity				0.14
Non-hispanic white	183 (47.2)	154 (47.1)	29 (47.5)	
Black/African American	52 (13.4)	40 (12.2)	12 (19.7)	
Asian/Pacific Islander	97 (25.0)	88 (26.9)	9 (14.8)	
Hispanic	46 (11.9)	36 (11.0)	10 (16.4)	
Other ^b	10 (2.6)	9 (2.8)	1 (1.6)	
BMI (kg/m ²)				0.70
16.6–24.9	120 (30.9)	104 (31.8)	16 (26.2)	
25.0–29.9	136 (35.1)	113 (34.6)	23 (37.7)	
≥ 30.0	132 (34.0)	110 (33.6)	22 (36.1)	
Charlson comorbidity score				0.26
0	280 (72.2)	241 (73.7)	39 (63.9)	
1	56 (14.4)	45 (13.8)	11 (18.0)	
2 +	52 (13.4)	41 (12.5)	11 (18.0)	
Breast density				0.73
Fatty	24 (6.2)	21 (6.4)	3 (4.9)	
Scattered fibroglandular	166 (42.8)	136 (41.6)	30 (49.2)	
Heterogeneously dense	145 (37.4)	125 (38.2)	20 (32.8)	
Extremely dense	28 (7.2)	25 (7.7)	3 (4.9)	
Not noted	25 (6.4)	20 (6.1)	5 (8.2)	
Lesion size (cm)				0.02
0.1–1.0	233 (60.1)	186 (56.9)	47 (77.1)	
1.1–1.5	61 (15.7)	54 (16.5)	7 (11.5)	
≥ 1.6	83 (21.4)	77 (23.6)	6 (9.8)	
Unknown	11 (2.8)	10 (3.1)	1 (1.6)	
Distance of lesion from nipple (cm)				0.25
Retroareolar	95 (24.5)	80 (24.5)	15 (24.6)	
0.1–2.0	93 (24.0)	76 (23.2)	17 (27.9)	
2.1–4.9	98 (25.3)	89 (27.2)	9 (14.8)	
≥ 5.0	73 (18.8)	58 (17.7)	15 (24.6)	
Unknown	29 (7.5)	24 (7.3)	5 (8.2)	
Aggregate volume of tissue removed (cm)				0.008
0.1–0.9	74 (19.1)	68 (20.8)	6 (9.8)	
1.0–1.5	187 (48.2)	162 (49.5)	25 (41.0)	
1.6–2.0	71 (18.3)	58 (17.7)	13 (21.3)	
≥ 2.1	50 (12.9)	34 (10.4)	16 (26.2)	
Unknown	5 (1.5)	5 (1.5)	1 (1.6)	
Palpable breast mass	99 (25.5)	81 (24.8)	18 (29.5)	0.43
Nipple discharge	69 (17.8)	57 (17.4)	12 (19.7)	0.72

^aN and column percentages are shown under each heading^bIncludes Native American, mixed, and unknown race/ethnicity^cFrom two-sided Fisher exact test

TABLE 2 Surgical excision: demographic and clinical characteristics at image guided core needle biopsy by final lesion diagnosis

	Total cases (n)	Final diagnosis of index lesion								
		Invasive cancer 2.4% (0.8-4.1)			DCIS ^c 3.4% (1.4-5.3)		High risk ^d 9.5% (6.3-12.7)		No upgrade 84.7% (80.8-88.6)	
Characteristic ^a	327	8	11	31	277	Row N	Row %	95% CI	Row %	95% CI
Age (year)										
< 50	104	0	–	1.9	0.0–4.6	6.7	1.9–11.6	91.3	85.9–96.8	
50–70	187	2.7	1.0–6.5	4.3	1.4–7.2	12.3	7.6–17.0	79.7	73.9–85.5	
> 70	36	2.8	0.0–8.2	2.8	0.0–8.2	2.8	0.0–8.2	91.7	72.6–100.0	
Race/ethnicity										
Non-hispanic white	154	3.9	0.8–7.0	3.3	0.4–6.1	9.1	4.5–13.7	83.8	77.9–89.6	
Black/African American	40	2.5	0.0–7.4	7.5	0.0–15.7	5.0	0.0–11.8	85.0	73.9–96.1	
Asian/Pacific Islander	88	1.1	0.0–3.4	3.4	0.0–7.2	14.8	7.3–22.2	80.7	72.4–89.0	
Hispanic	36	0	–	0	–	2.8	0.0–8.2	97.2	91.8–100.0	
Other ^b	9	0	–	0	–	11.1	0.0–31.8	88.9	68.3–100.0	
BMI (kg/m ²)										
16.6–24.9	104	1.9	0.0–4.6	3.8	0.1–7.6	7.7	2.5–12.8	86.5	79.9–93.1	
25.0–29.9	113	1.8	0.0–4.2	4.4	0.6–8.2	10.6	4.9–16.3	83.2	76.3–90.1	
≥ 30.0	110	3.6	0.1–7.2	1.8	0.0–4.3	10.0	4.4–15.6	84.5	77.8–91.3	
Charlson comorbidity score										
0	241	2.1	0.3–3.9	1.7	0.0–3.3	10.1	6.2–13.8	86.3	81.9–90.7	
1	45	0	–	6.7	0.0–14.0	8.9	0.5–12.2	84.4	73.8–95.1	
2 +	41	7.3	0.0–15.3	9.8	0.6–18.9	7.3	0.0–15.3	75.6	62.4–88.8	
Breast density										
Fatty	21	0	–	4.8	0.0–13.9	9.5	0.0–22.1	85.7	70.7–100.0	
Scattered fibroglandular	136	1.6	0.0–3.8	2.9	0.1–5.8	12.5	6.9–18.1	81.6	75.1–88.2	
Heterogeneously dense	125	1.6	0.0–3.8	4.0	0.5–7.5	5.6	1.5–9.7	88.8	83.2–94.4	
Extremely dense	25	4.0	0.0–11.7	0	–	12.0	0.0–24.8	84.0	69.6–98.4	
Not noted	20	5.0	0.0–14.6	5.0	0.0–14.6	10.0	0.0–23.2	80.0	62.4–97.6	
Lesion size (cm)										
0.1–1.0	186	0.5	0.0–1.6	1.6	0.0–3.4	7.5	3.7–11.3	90.3	86.1–94.6	
1.1–1.5	54	3.7	0.0–8.8	1.9	0.0–5.5	14.8	5.3–24.3	79.6	68.8–90.4	
1.6–2.0	37	5.4	0.0–12.7	10.8	0.8–20.9	5.4	0.0–12.7	78.4	65.0–91.7	
≥ 2.1	40	7.5	0.0–15.7	5.0	0.0–11.8	12.5	2.2–22.8	75.0	61.5–88.5	
Unknown	10	0	–	10.0	0.0–28.7	20.0	0.0–44.9	70.0	41.4–98.6	
Distance of lesion from nipple (cm)										
Retroareolar	80	1.3	0.0–3.7	2.5	0.0–5.9	8.8	2.5–15.0	87.5	80.2–94.8	
0.1–2.0	76	2.6	0.0–6.3	2.6	0.0–6.3	3.9	0.0–8.3	90.8	84.3–97.3	
2.1–4.9	89	1.1	0.0–3.3	1.1	0.0–3.3	7.9	2.2–13.5	89.9	83.6–96.2	
≥ 5.0	58	6.9	0.3–13.5	8.6	1.4–15.9	20.7	10.2–31.2	63.8	51.4–76.2	
Unknown	24	0	–	4.2	0.0–12.2	5.7	0.0–19.4	87.5	74.2–100.0	
Aggregate volume of tissue removed (cm)										
0.1–0.9	68	1.5	0.0–4.4	2.9	0.0–7.0	11.8	4.1–19.5	83.8	75.0–92.6	
1.0–1.5	162	1.9	0.0–3.9	4.3	1.2–7.5	8.6	4.3–13.0	85.2	79.7–90.7	
1.6–2.0	58	6.9	0.3–13.5	1.7	0.0–5.1	5.2	0.0–10.9	86.2	77.3–95.1	
≥ 2.1	34	0	–	0	–	11.8	0.9–22.7	88.2	77.3–99.1	
Unknown	5	0	–	20.0	0.0–55.2	40.0	0.0–83.2	40.0	0.0–83.2	
Palpable breast mass	81	4.9	0.2–9.7	6.2	0.9–11.4	7.4	1.7–13.1	81.5	73.0–90.0	
Nipple discharge	57	0	–	1.8	0.0–5.2	7.0	0.4–13.7	91.2	83.8–98.6	

^aRow % and 95% CI unless otherwise specified^bIncludes Native American, mixed, and unknown race/ethnicity^cDuctal carcinoma in situ^dHigh risk includes atypical ductal hyperplasia (ADH), atypical lobular hyperplasia (ALH), lobular carcinoma in situ (LCIS), and papilloma with atypia

TABLE 3 Characteristics of in situ or invasive breast cancer found on surgical excision

Pathology	Diagnosis	Grade	T-stage	N-stage	ER	PR	HER-2	
Non-invasive	DCIS	1	Tis	NX	POS	POS		
	DCIS	1	Tis	NX	POS	POS		
	DCIS	1	Tis	NX	POS	POS		
	DCIS	2	Tis	NX	POS	POS		
	DCIS	2	Tis	NX	POS	POS		
	DCIS	2	Tis	NX	POS	POS		
	DCIS	2	Tis	NX	POS	UNK		
	Papillary CA	1	Tis	N0	POS	POS		
	Papillary CA	2	Tis	NX	POS	POS		
	Papillary CA	UNK	Tis	N0	NEG	TND		
	Papillary CA	UNK	Tis	NX	POS	POS	NEG	
	Invasive	Invasive Papillary CA	1	T1mi	N0	POS	NEG	NEG
		Invasive Papillary CA	1	T1a	N0	POS	POS	NEG
Invasive breast CA		1	T1a	N0	POS	POS	NEG	
Invasive breast CA		1	T1a	N0	NEG	NEG	NEG	
Invasive breast CA		2	T1a	N0	POS	POS	NEG	
Invasive Papillary CA		1	T1b	N0	POS	POS	NEG	
Invasive breast CA		2	T1b	N0	POS	POS	NEG	
Invasive breast CA		2	T3	N0	POS	NEG	NEG	

significant smaller aggregate volume of tissue among women in the surgical excision group compared with the imaging surveillance group, which may have influenced this result. We looked at additional patient, imaging, and pathologic factors relative to outcomes. In agreement with recent studies, we found that age older than 50 years, a lesion > 1 cm, a more peripherally located lesion, or a palpable lesion were all more common in women who had invasive or noninvasive cancer on surgical excision compared with women without an upgrade.^{21,22,25,26,28,29} Nipple discharge was more commonly seen in women whose lesion was not upgraded on excision, a finding that has not been previously identified. As with other studies, a very small percentage of women undergoing imaging surveillance had a subsequent unfavorable outcome, with only 1 of 61 diagnosed with ADH during the 2-year follow-up period.^{24,30}

Due to differences in their relative clinical importance and management, results are reported separately for cancer and high-risk lesions. KPNC participated in both the NSABP-P1 and STAR trials showing that women with high-risk lesions who take tamoxifen or raloxifene can decrease their breast cancer risk by 50%, without any survival benefit.³⁵ However, of the 19 women in our cohort upgraded to a high-risk lesion on surgical excision, only 2 patients opted for chemoprevention. Furthermore, despite an automatic change in the patient's health prompt to annual mammography, less than half of these patients increased their breast cancer screening frequency. In our

cohort, the theoretical benefit of diagnosing a high-risk lesion did not translate into a significant difference in clinical management.

Our study is limited by the fact that it is retrospective, with a potential for bias between the subset of women who had imaging surveillance and those who underwent surgical excision, as evidenced by the fact that women who underwent surgical excision were statistically more likely to have larger lesions and smaller aggregate volume of tissue removed in the IGCNB. We also chose to focus on women with a solid mass lesion on imaging, which limits the broader applicability of these results to all benign papillary breast lesions, particularly lesions presenting as microcalcifications. The strengths of the study are that data were collected over a relatively short period of time (2 years), included a large sample size from a diverse population, and had excellent follow-up. Despite having a large cohort, some of our estimates are imprecise because of small numbers. There is an imbalance between the number of patients in the comparison groups; only 16% (61 patients) of the cohort had imaging surveillance compared with 84% (327 patients) who underwent surgical excision (Table 1). Although the confidence intervals are wide for the surgical excision group (Table 2), we were able to demonstrate characteristics more frequently in women harboring a cancer. Our results are consistent with findings from other studies showing certain variables (patient age, size of lesion, distance from the nipple, and a palpable mass) are more common in women whose lesions are upgraded to a malignancy with surgical excision.

Overall, this study adds important data to the growing body of literature suggesting that a conservative approach is reasonable in the management of a BPBLs diagnosed on IGCNB. One of the crucial elements for fully informed, shared decision making is understanding both the likelihood and prognosis of an outcome. If most patients end up having a benign lesion and/or high-risk lesion that will not significantly change their clinical management or impact their long-term survival, this needs to be weighed against the time, expense, potential for complications, and anxiety associated with a recommendation for surgical excision. While this study identifies variables that are more commonly seen in women upgraded to malignancy, it is important to recognize that almost all patients with a malignancy, whether invasive or noninvasive, have an excellent prognosis at time of diagnosis.

In summary, overall outcomes for BPBLs diagnosed on IGCNB are favorable whether immediate surgical excision or imaging surveillance is the final treatment choice.

ACKNOWLEDGMENT This study was supported by a grant from the Kaiser Permanente Northern California Community Benefit Program.

REFERENCES

1. Fu CY, Chen TW, Hong ZJ, et al. Papillary breast lesions diagnosed by core biopsy require complete excision. *Eur J Surg Oncol.* 2012;38:1029–35.
2. Boin DP, Baez JJ, Guajardo MP, et al. Breast papillary lesions: an analysis of 70 cases. *Ecancermedalscience.* 2014;8:461.
3. Wang H, Tsang P, D'Cruz C, Clarke K. Follow-up of breast papillary lesion on core needle biopsy: experience in African-American population. *Diagn Pathol.* 2014;9:86.
4. Glenn ME, Throckmorton AD, Thomison JB, Bienkowski RS. Papillomas of the breast 15 mm or smaller: 4-year experience in a community-based dedicated breast imaging clinic. *Ann Surg Oncol* 2015;22:1133-9.
5. Rozentsvayg E, Carver K, Borkar S, et al. Surgical excision of benign papillomas diagnosed with core biopsy: a community hospital approach. *Radiol Res Pract.* 2011;2011:679864.
6. Shouhed D, Amersi FF, Spurrier R, et al. Intraductal papillary lesions of the breast: clinical and pathological correlation. *Am Surg.* 2012;78(10):1161–5.
7. Al Hassan T, Delli Fraine P, El-Khoury M, et al. Accuracy of percutaneous core needle biopsy in diagnosing papillary breast lesions and potential impact of sonographic features on their management. *J Clin Ultrasound.* 2013;41:1–9.
8. Gilani S, Tashjian R, Kowalski P. Histological evaluation of papillary lesions of the breast from needle biopsy to the excised specimen: a single-institutional experience. *Pathologica.* 2013;105(2):51–5.
9. Chang JM, Han W, Moon WK, et al. Papillary lesions initially diagnosed at ultrasound-guided vacuum-assisted breast biopsy: rate of malignancy based on subsequent surgical excision. *Ann Surg Oncol.* 2011;18:2506–14.
10. Shamonki J, Chung A, Huynh KT, et al. Management of papillary lesions of the breast: can larger core needle biopsy samples identify patients who may avoid surgical excision? *Ann Surg Oncol.* 2013;20:4137–44.
11. Wyss P, Varga Z, Rossle M, Rageth CJ. Papillary lesions of the breast: outcomes of 156 patients managed without excisional biopsy. *Breast J.* 2014;20:394–401.
12. Holley SO, Appleton CM, Farria DM, et al. Pathologic outcomes of nonmalignant papillary breast lesions diagnosed at imaging-guided core needle biopsy. *Radiology.* 2012;265(2):379–84.
13. Yamaguchi R, Tanaka M, Tse GM, et al. Management of breast papillary lesions diagnosed in ultrasound-guided vacuum-assisted and core needle biopsies. *Histopathology.* 2015;66:565–76.
14. Seely JM, Verma R, Kielar A, et al. Benign papillomas of the breast diagnosed on large-gauge vacuum biopsy compared with 14 gauge core needle biopsy: do they require surgical excision? *Breast J.* 2017;23:146–53.
15. Hawley JR, Lawther H, Erdal BS, et al. Outcomes of benign breast papillomas diagnosed at image-guided vacuum-assisted core needle biopsy. *Clin Imaging.* 2015;39:576–81.
16. Maxwell AJ, Mataka G, Pearson JM. Benign papilloma diagnosed on image-guided 14 G core biopsy of the breast: effect of lesion type on likelihood of malignancy at excision. *Clin Radiol* 2013;68:383–7.
17. Bianchi S, Bendinelli B, Saladino V, et al. Non-malignant breast papillary lesions—b3 diagnosed on ultrasound-guided 14-gauge needle core biopsy: analysis of 114 cases from a single institution and review of the literature. *Pathol Oncol Res.* 2015;21:535–6.
18. Kibil W, Hodorowicz-Zaniewska D, Popiela TJ, Kulig J. Vacuum-assisted core biopsy in diagnosis and treatment of intraductal papillomas. *Clin Breast Cancer.* 2013;13:129–32.
19. Bennett LE, Ghate SV, Bentley R, Baker JA. Is surgical excision of core biopsy proven benign papillomas of the breast necessary? *Acad Radiol.* 2010;17:553–7.
20. Wiratkapun C, Keeratitragoon T, Lertsithichai P, Chanplakorn N. Upgrading rate of papillary breast lesions diagnosed by core-needle biopsy. *Diagn Interv Radiol.* 2013;19:371–6.
21. Rizzo M, Linebarger J, Lowe MC, et al. Management of papillary breast lesions diagnosed on core-needle biopsy: clinical pathologic and radiologic analysis of 276 cases with surgical follow-up. *J Am Coll Surg.* 2012;214:280–7.
22. Ko D, Kang E, Park SY, et al. The management strategy of benign solitary intraductal papilloma on breast core biopsy. *Clin Breast Cancer.* 2017;17:367–72.
23. Swapp RE, Glazebrook KN, Jones KN, et al. Management of benign intraductal solitary papilloma diagnosed on core needle biopsy. *Ann Surg Oncol.* 2013;20:1900–5.
24. Mosier AD, Keylock J, Smith DV. Benign papillomas diagnosed on large-gauge vacuum-assisted core needle biopsy which span < 1.5 cm do not need surgical excision. *Breast J.* 2013;19:611–7.
25. Choi SH, Jo S, Kim DH, et al. Clinical and imaging characteristics of papillary neoplasms of the breast associated with malignancy: a retrospective cohort study. *Ultrasound Med Biol.* 2014;40:2599–608.
26. Nakhli F, Ahmadiyah N, Lester S, et al. Papilloma on core biopsy: excision vs. observation. *Ann Surg Oncol.* 2015;22:1479–82.
27. Wen X, Cheng W. Nonmalignant breast papillary lesions at core-needle biopsy: a meta-analysis of underestimation and influencing factors. *Ann Surg Oncol.* 2013;20:94–101.
28. Youk JH, Kim E-K, Kwak JY, et al. Benign papilloma without atypia diagnosed at US-guided 14-gauge core-needle biopsy: clinical and US features predictive of upgrade to malignancy. *Radiology.* 2011;258(1):81–8.
29. McGhan LI, Pockkaj BA, Wasif N, et al. Papillary lesions on core biopsy: excisional biopsy for all patients? *Am Surg.* 2013;79:1238–42.
30. Nayak A, Carkaci S, Gilcrease MZ, et al. Benign papillomas without atypia diagnosed on core needle biopsy: experience from

- a single institution and proposed criteria for excision. *Clin Breast Cancer*. 2013;13:439–49.
31. Tatarian T, Sokas C, Rufail M, et al. Intraductal papilloma with benign pathology on breast core biopsy: to excise or not? *Ann Surg Oncol*. 2016;23:2501–7.
 32. Gordon NP. Similarity of the adult Kaiser Permanente membership of Northern California to the insured and general population in Northern California: statistics from the 2011–2012 California Health Interview Survey. Kaiser Permanente Division of Research, Oakland CA. 2015. http://divisionofresearch.kaiserpermanente.org/projects/memberhealthsurvey/SiteCollectionDocuments/chis_non_kp_2011.pdf.
 33. American College of Radiology. BI-RADS ATLAS-Breast ultrasound. 5th ed. Virginia: American College of Radiology; 2013. p. 121–32.
 34. Lee KA, Talati N, Oudsema R, et al. BI-RADS 3: current and future use of probably benign. *Curr Radiol Rep*. 2018;6:5.
 35. Vogel VG. The NSABP Study of Tamoxifen and Raloxifene (STAR) trial. *Expert Rev Anticancer Ther*. 2009;9:51–60.

Publisher's Note Springer Nature remains neutral with regard to jurisdictional claims in published maps and institutional affiliations.