

RESEARCH

Open Access



# Predictors of subclinical shoulder joint affection in patients with rheumatoid arthritis by ultrasonography

Samah M. Alian<sup>1\*</sup> , Elsayed A. Elsiad<sup>1</sup>, Alzahraa E. Elsayed<sup>2</sup> and Mohamed A. Hammad<sup>1</sup>

## Abstract

**Background:** To assess subclinical involvement of shoulder joints in patients with rheumatoid arthritis (RA) by using musculoskeletal ultrasound (MSUS) and detect their predictors.

**Results:** We found 75% of the patients have subclinical ultrasound changes in their shoulder joints where 65% of the patient's shoulders are affected. About 57.5% of the shoulder joints showed peri-articular structural changes by ultrasound, while the articular changes were 36.9% with the most frequent one being supraspinatus tendinopathy (43.12%) followed by subacromial-subdeltoid bursitis [total (31.87%), effusion (16.87%), and synovial hypertrophy (15%)], supraspinatus tendon partial tear (30.62%), and long head of biceps tenosynovitis (effusion only) (28.75%), while the least frequencies were glenohumeral joint erosion (11.25%) and synovitis (12.5%). Older age and longer disease duration were significant predictors for the peri-articular changes with  $p$  value  $< 0.5$ , while high disease activity, seropositive rheumatoid factor, and long disease duration were significant predictors for the articular changes with  $p$  value  $< 0.5$ .

**Conclusion:** Although shoulders were clinically silent in RA patients, we found a high percentage of subclinical abnormalities detected by MSUS, which were more predominant in the peri-articular structures. MSUS is a simple and non-invasive technique that can be used to detect RA shoulder subclinical affection.

**Keywords:** Subclinical arthritis, MSUS, Shoulder, Rheumatoid arthritis

## Background

Rheumatoid arthritis (RA) is a progressive inflammatory autoimmune disease with articular and systemic effects. The exact cause is unknown, but genetic and environmental factors are contributory. Although some patients have mild self-limited disease, many experience joint destruction, severe physical disability, and multiple comorbidities [1]. RA involves the shoulder and is usually manifested by tenderness, pain, and limitation of movement, but few percent of RA patients have clinically detectable tenderness and swelling [2]. Considering the importance of early treatment in RA patients before the

damage occurrence, musculoskeletal ultrasonography (MSUS) has an important role in detecting abnormalities in rheumatoid shoulder to achieve low disease status and eventually remission. It is proven to be a valid tool in the assessment of inflammatory arthritis, including RA and more sensitive than clinical examination in such joints [3].

## Methods

### Patients

This study was carried out in Rheumatology and Rehabilitation Departments, Faculty of Medicine, Zagazig University Hospitals, on 80 patients (58 females and 22 males) with RA diagnosed according to 2010 American College of Rheumatology/European League Against Rheumatism (ACR/EULAR) classification criteria for RA [4].

\* Correspondence: [dr\\_r18@yahoo.com](mailto:dr_r18@yahoo.com)

<sup>1</sup>Rheumatology and Rehabilitation Department, Faculty of Medicine, Zagazig University, Zagazig, Egypt

Full list of author information is available at the end of the article

Written informed consent was obtained from patients for their study participation. The study was approved by the local ethical committee of Zagazig University Hospitals.

#### Exclusion criteria

Patients with other inflammatory autoimmune diseases, clinically evident shoulder affection (by history and clinical shoulder examination), and history of shoulder surgery, trauma, infection, fracture, or malignancy were excluded from the study

#### Type of study: observational cross-sectional study

##### Data collection

All patients were subjected to full history taking, clinical examination, and especially full shoulder joint examination with special tests for shoulder joint and laboratory investigations including complete blood count, erythrocyte sedimentation rate (ESR) [5], C reactive protein (CRP), rheumatoid factor (RF), and anti-cyclic citrullinated peptide (anti-CCP) antibodies [6]. RA disease activity was evaluated by 28-joint count disease activity score (DAS-28 score) [7].

##### Shoulder examination

Inspection for swelling or deformity, palpation for tenderness and warmth, range of motion both active and passive, and special tests for shoulder joint peri-articular structure affection such as Neer's test for impingement syndrome, Hawkin's test for supraspinatous tendinitis, drop arm test for rotator cuff tear, lift-off test for subscapularis tendon tear, empty can test for supraspinatous tendon tear, and Speed's and Yergason's tests for long head of biceps tenosynovitis were done.

##### Ultrasonography

MSUS was done to all patients at the musculoskeletal unit of the department by one rheumatologist trained in MSUS who was blind to the clinical and laboratory data of the patients. Ultrasound was done by both (gray scale and power Doppler) using high frequency superficial ultrasound probe by Hitachi Aloka F37 ultrasound device with a linear probe frequency (10–18) MHz transducer. MSUS (patient position and standard scans) are done according to the European League Against Rheumatism (EULAR) guidelines for MSUS examination [8]. The following anatomical areas were scanned in both shoulder joints (right and left): glenohumeral joint, acromioclavicular joint, biceps tendon, subacromial subdeltoid (SASD) bursa, and rotator cuff tendons (supraspinatus, subscapularis, infraspinatus, and teres minor). Structural pathology is defined according to the outcome measures in rheumatology clinical trials (OMERACT) definitions of pathology in MSUS [9], in which:

*Synovial hypertrophy (synovitis)* is defined as abnormal hypoechoic (relative to subdermal fat, but sometimes may be isoechoic or hyperechoic) intraarticular tissue that is nondisplaceable and poorly compressible and which may exhibit Doppler signal.

*Synovial effusion* is defined as abnormal hypoechoic or anechoic (relative to subdermal fat, but sometimes may be isoechoic or hyperechoic) intraarticular material that is displaceable and compressible, but does not exhibit Doppler signal.

*Tenosynovitis* is defined as hypoechoic or anechoic thickened tissue with or without fluid within the tendon sheath, which is seen in 2 perpendicular planes and which may exhibit Doppler signal.

*Erosion* is defined as an intraarticular discontinuity of the bone surface that is visible in 2 perpendicular planes.

*Osteophyte* is defined as linear bony outcropping adjacent to the joint.

*Bursitis* is defined as an increase of hypoechoic fluid and/or tissue depending on its nature within the bursa and may show Doppler signals

*Tendinopathy* is thickened/thinned and heterogenous, with loss of the normal fibrillar echopattern (architectural distortion)

*Tendon tear* is defined as hypoechoic area within the tendon at both planes at the articular/bursal surface or intrasubstance.

#### Statistical analysis

All data were collected, tabulated, and statistically analyzed using SPSS 20.0 for windows (SPSS Inc., Chicago, IL, USA). Quantitative data were expressed as the mean  $\pm$  SD and qualitative data were expressed as absolute frequencies (number) and relative frequencies (percentage). Student's *t* test was used to compare between two groups of normally distributed variables. Mann-Whitney test was used to compare between two groups of non-parametric variables. Percent of categorical variables was compared using chi-square test or Fisher's exact test when appropriate. Multiple regression was used for detecting predicting factors for a dependant variable on several independent variables. All tests were two-sided. *p* value  $< 0.05$  was considered statistically significant (S);  $\geq 0.05$  was considered statistically insignificant (NS).

#### Results

The demographic data of RA patients is shown in (Table 1). Frequency of subclinical MSUS lesions in RA patients and their shoulder joints are presented in Table 2. The total MSUS lesions were present in 75% of RA patients, articular lesions were present in 52.5%, and peri-articular were present in 68.8%, while the total MSUS lesions were present in 65% of RA shoulders, articular lesions were present in

**Table 1** Demographic data of RA patients

Items		RA patients (n = 80) No. (%)
Age (years)	Mean ± SD	43.0 ± 13.1
	Range	20–70
Sex	Female, N (%)	58 (72.5%)
	Male, N (%)	22 (27.5%)
Occupation	Not working, N (%)	14 (17.5%)
	Working, N (%)	66 (82.5%)
Disease duration	Mean ± SD	3.45 ± 1.6
	Range	1–7
Smoking	No, N (%)	(100%)
	Yes, N (%)	0

36.9%, and peri-articular were present in 57.5% of shoulders (not all 60 patients affected had bilateral shoulder lesions but only 44 (73.3) had bilateral and 16 (26.6) had unilateral affection so the total shoulder joint affections are not double the number of total patients affected). The frequency of subclinical MSUS lesion sub-types in RA shoulder joints is seen in Fig. 1 with the most frequent lesion being supraspinatus tendinopathy (43.12%) followed by SASDs bursitis [total (31.87%), effusion (16.87%), and synovial hypertrophy (15%)], and then the supraspinatus tendon partial tear (30.62%) and long head of biceps tenosynovitis (effusion only not synovial hypertrophy) (28.75%), while the subscapularis tendinopathy was 14.37% and subscapularis tendon partial tear was 9.37%. The articular changes of the shoulder joint were in the following order: acromioclavicular joint synovitis (26.87%), acromioclavicular joint osteophyte (23.75%), glenohumeral joint synovitis (12.5%) [total (12.5%), effusion (7.5%), synovial hypertrophy (5%)], and glenohumeral joint erosion (11.25%) (Figs. 2, 3, and 4).

The association between peri-articular and articular subclinical MSUS shoulder joint lesions in RA patients and their disease characteristics are shown in Tables 3 and 4. There was a significant association between peri-articular subclinical US lesions and both older age and longer disease duration and comorbidity (Table 3). Also, there was a significant association between articular

subclinical MSUS lesions and positive RF, DAS-28 score, and disease duration (Table 5).

The significant predictors for both peri-articular and articular subclinical shoulder joint changes by MSUS in RA patients are shown in Table 5 where older age and longer disease duration were significant predictors for peri-articular changes, while RF positive, longer disease duration, and higher DAS-28 scores (moderate and severe activity) were significant predictors for articular changes.

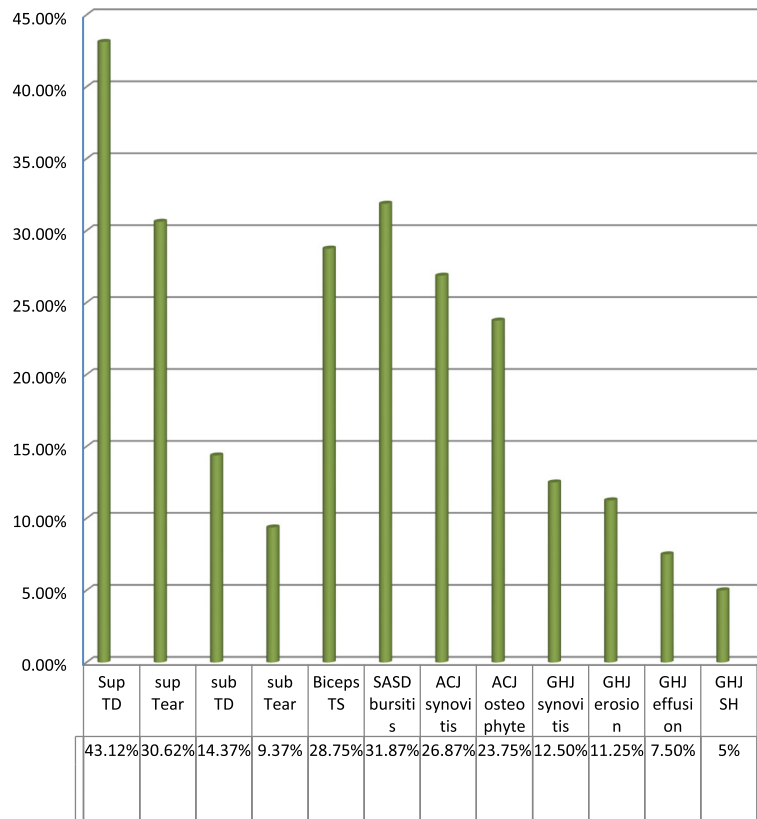
## Discussion

MSUS is a widely accepted imaging technique in both clinical practice and in rheumatology research to visualize joints and soft tissues. This procedure has several benefits such as the absence of side effects, speed of realization, sensitivity for detecting erosions, and availability in a routine practice [10]. The objectives of our study were to assess the prevalence and types of subclinical MSUS lesions of both shoulder joints in RA patients and their predictors. We found that more than half of the patients (75%) have subclinical MSUS changes in their clinically silent (inactive) shoulder joints where 65% of the patient's shoulders are affected, and this is higher than the recently reported data in a study of healthy subjects done by Iganocci et al. [11] in which the MSUS changes were present in 28.9% of the normal shoulders. At the same time, we agree with the study done by Naranjo et al. [12] in which they found that the total MSUS changes in 67 painless RA shoulders were 52%.

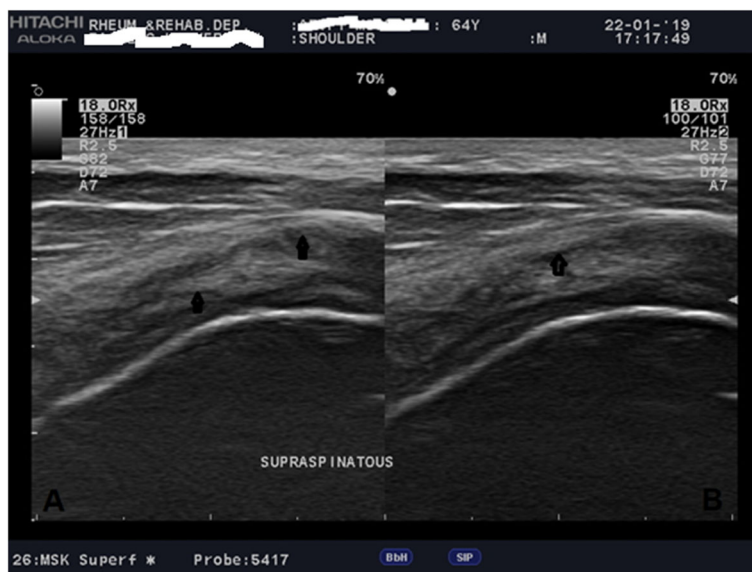
The most frequent MSUS changes of the shoulder joint in our RA population were in the peri-articular structures and not in the articular one. Our study goes in agreement with many studies done on both painless and painful RA shoulders as regards the higher percentage of the peri-articular changes. We found that supraspinatus tendinopathy was the most frequent MSUS change which was present in 43.12% of our patient's shoulders and also subscapularis tendinopathy was present in 14.37%. This percentage is higher than the average percent present in the normal population in Iganocci et al.'s study [11], in which the supraspinatus tendinopathy percentage was 20.6%, but we agree in this high percentage with a study done by Fuda et al. [13] on 40 RA patients in which the rotator cuff tendinopathy

**Table 2** Frequency of subclinical MSUS lesions in RA patients and their shoulder joints

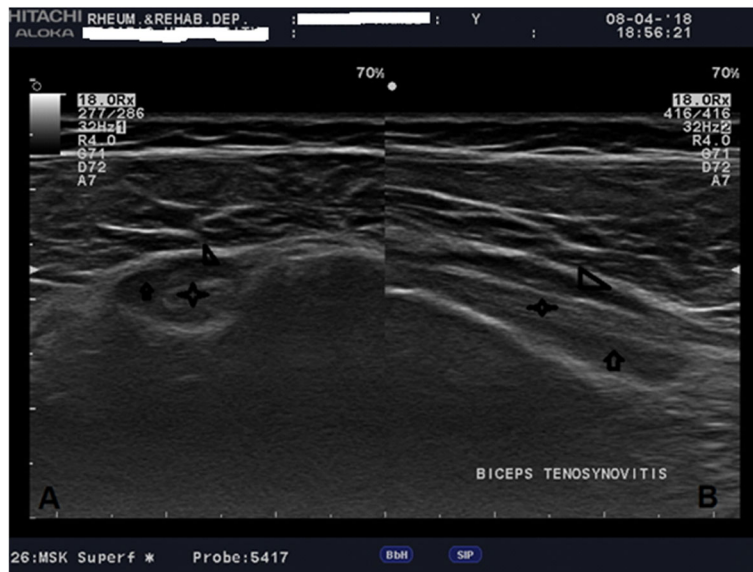Subclinical ultrasound shoulder lesions	RA patients (80) No. (%)	Subclinical ultrasound shoulder lesions	RA shoulder joints (160) No. (%)
Total lesions	60 (75.0)	Total lesions	104(65.0)
Articular lesions	42 (52.5)	Articular lesions	59(36.9)
Peri-articular lesions	55 (68.8)	Peri-articular lesions	92(57.5)
Unilateral lesions	16 (26.6)	Right shoulder lesions	54(51.9)
Bilateral lesions	44 (73.3)	Left shoulder lesions	50(48.0)



**Fig. 1** Bar chart showing the peri-articular and articular subclinical ultrasonography subtype changes in RA shoulder joints. Articular lesions are ACJ synovitis, ACJ osteophyte, GHJ synovitis (GHJ, SH, and GHJ effusion), and GHJ erosion), while peri-articular lesions are Sup TD, Sup tear, Sub TD, Sub tear, biceps TS, and SASD bursitis; Sup TD, supraspinatous tendinopathy; sup, supraspinatous; sub TD, subscapularis tendinopathy; sub, subscapularis; TS, tenosynovitis; SASD, subacromial subdeltoid; ACJ, acromioclavicular joint; GHJ, glenohumeral joint; SH, synovial hypertrophy



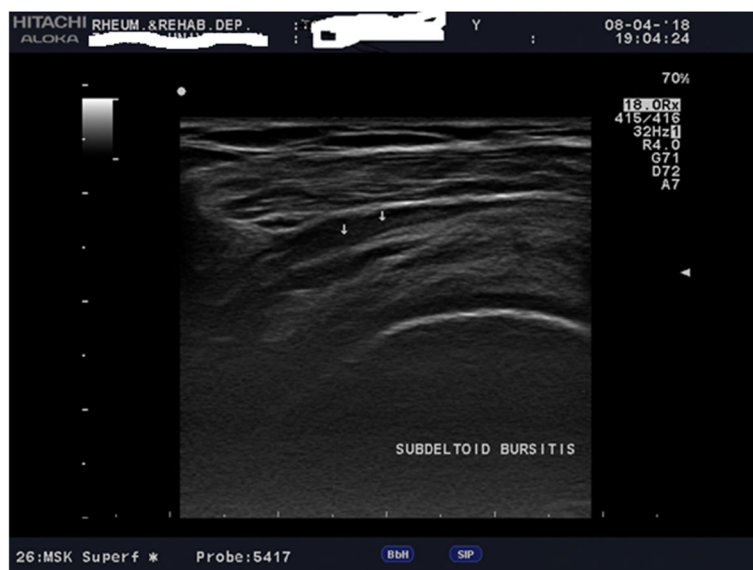**Fig. 2** Left supraspinatus tendinopathy. **a** Longitudinal view. **b** Transverse view of the left supraspinatus tendon of the left shoulder joint. Arrows showed architectural distortion with loss of the normal fibrillar echopattern



**Fig. 3** Right biceptal tenosynovitis. **a** Longitudinal view. **b** Transverse view of the right long head of biceps tendon of the right shoulder joint. Asterisks showed the tendon fibers, arrows showed synovial hypertrophy, and arrow heads showed effusion around the tendon inside its synovial sheath

was present in 45% of the shoulders, although this study was done on active painful shoulders only. As regards the SASD bursitis, we found that 31.78% of our patient’s shoulders showed SASD bursitis with 16.87% effusion and 15% synovial hypertrophy, and also this is higher than the percentage of SASD bursitis present in the normal population in Iganocci et al.’s study [11], in which they found that SASD bursitis effusion was present in 11.3% and synovial hypertrophy was present in 2.1%. But

also, we still agree regarding the findings with many studies like the study done by Elbinoune et al. [14] in which they evaluated 37 RA patients with painful and painless shoulder joints and found that SASD bursitis was present in 37.8% of the patient’s shoulders; another study agreed with us which was done by Stegbauer et al. [10] on painful shoulders in 99 RA patients, and they found that SASD bursitis was present in (35%) of the shoulders; also another study on painful shoulders in 44



**Fig. 4** Left subdeltoid bursitis. Longitudinal view of the left rotator cuff of the left shoulder joint. arrows showed hypoechoic area inside the subdeltoid bursa (synovial hypertrophy)

**Table 3** Association between peri-articular subclinical ultrasound shoulder joint lesions in RA patients and their demographic, clinical and treatment parameters

Rheumatoid patients		RA patients (80)		$\chi^2$	<i>p</i>
		With periarticular lesions, <i>N</i> (%)	Without peri-articular lesions, <i>N</i> (%)		
Sex	Female	41 (70.7)	17 (29.3)	58	0.54
	Male	14 (63.6)	8 (36.4)		
Occupation	Non manual worker	8	6	14	0.3
	Manual worker	47	16	66	
Co-morbidity	Yes	14 (93.3)	1 (6.7)	15	0.04*
	No	41 (63.1)	24 (36.9)	65	
RF	+ ve	45 (72.5)	17 (27.5)	62	0.27
	- ve	10 (55.5)	8 (44.5)	18	
Anti-CCP	+ ve	36 (70.5)	15 (29.5)	51	0.82
	- ve	19 (65.5)	10 (34.5)	29	
NSAID	Yes	28 (68.3)	13 (31.7)	41	0.9
	No	27 (69.2)	12 (30.8)	39	
Steroid	Yes	51 (69)	23 (31)	74	0.73
	No	4 (66.6)	2 (33.4)	6	
Age (years)	Mean $\pm$ SD	49 $\pm$ 9	29 $\pm$ 8.5	U	0.001*
ESR	Mean $\pm$ SD	36 $\pm$ 23	34 $\pm$ 17	U	0.95
Disease duration (years)	Mean $\pm$ SD	4 $\pm$ 1.5	2.2 $\pm$ 1.2	U	0.001*
CRP	Mean $\pm$ SD	7.6 $\pm$ 4.2	7.8 $\pm$ 3.6	U	0.6
DAS-28	Mild	4 (40)	6 (60)	10	0.054
	Moderate	44 (75.8)	14 (24.2)	58	
	Severe	7 (58.4)	5 (41.6)	12	

ESR erythrocyte sedimentation rate, CRP C-reactive protein, RF rheumatoid factor, anti-CCP anti-cyclic citrullinated peptide antibodies, DAS-28 score 28-joint count disease activity score, NSAID non-steroidal anti-inflammatory drugs, U Mann-Whitney test,  $\chi^2$  chi-square test

\*Added values are significant at  $p < 0.05$

RA patients done by Mohamed et al. [15] in which they found that SASD bursitis was present in 43.75% of shoulder joints. The smallest percent of SASD bursitis effusion was present in a study done by Kim et al. [16] on 30 RA patients with 25 non-painful shoulders and 35 painful shoulders and was present in 4% and 14.3%, respectively, and this discrepancy in SASD bursitis percentage may be due to a large number of patients in our study with higher percentage of comorbidities (63.7%) mainly diabetes mellitus which may cause peri-articular shoulder changes. As regards the rotator cuff tears, we found in our population a relatively higher percentage of partial thickness tear in supraspinatus tendon (30.7%), while subscapularis tendon partial thickness tear was 9.6%. Also, these results were still higher than the normal values in Iganocci's et al.'s [11] study in which the supraspinatus tendon partial tear was 7.9% in young age and 8.3% in old age, but also our results are in agreement with Ruta et al.'s [17] study in which the rotator cuff partial tear percentage was 35% and also Alasaarela and Alasaarela's [18] study in which the supraspinatus tendon changes were present in 33% of painful shoulders.

On the other hand, our percentage of partial rotator cuff tear was higher than the other studies like Kim et al. [16] which was 20% in subscapularis tendon and 16% in supraspinatus tendon in both painful and non-painful shoulders. Also, in Stegbauer et al.'s [10] study, it was 15% in painful shoulders, and in Sakellariou et al.'s [14] study, it was 11% in both tender and non-tender joints. We can explain our high percent of rotator cuff tears by that our patients had a large number of manual workers (farmers) which may cause traumatic tears and also the high frequency probe (18 MHz) of the apparatus we used.

As regards the long head of biceps tenosynovitis, our patients showed 28.75% effusion in bicipital sheath. Like the previous findings, this was higher than the normal percentage present in Iganocci et al.'s [11] study in which the long head of biceps tenosynovitis (effusion) was 16.5%, and we agreed in this finding with a study that was done by Kim et al. [16] in which the biceps tendon effusion was present in 36% of non-painful shoulder joints; also in a study done by Stegbauer et al. [10], the biceps tenosynovitis was seen in 35% of painful shoulders, in Coari et al.'s [19] study, the percentage of biceps

**Table 4** Association between articular subclinical ultrasound shoulder joint lesions in RA patients and their demographic, clinical, and treatment parameters

Rheumatoid patients		RA patients (80)		$\chi^2$	<i>p</i>
		With articular lesions, No (%)	Without articular lesions, No (%)		
Sex	Female	28 (48.3)	30 (51.7)	58	0.22
	Male	14 (63.6)	8 (36.4)		
Occupation	Non-manual worker	8	6	14	0.7
	Manual worker	34	32	66	
Co-morbidity	Yes	9 (60)	6 (40)	15	0.71
	No	33 (50.7)	32 (49.3)	65	
RF	+ ve	41 (66.2)	21 (33.8)	62	0.0002*
	- ve	1 (5.5)	17 (94.5)	18	
Anticcp	+ ve	31 (60.7)	20 (39.3)	51	0.08
	- ve	11 (38)	18 (62)	29	
NSAID	Yes	20 (49)	21 (51)	41	0.5
	No	22 (56.4)	17 (43.6)	39	
Steroid	Yes	39 (52.7)	35 (47.3)	74	0.76
	No	3 (50)	3 (50)	6	
Age (years)	Mean $\pm$ SD	42. $\pm$ 10	43.8 $\pm$ 16	U	0.6
ESR	Mean $\pm$ SD	38 $\pm$ 26	33 $\pm$ 16	U	0.6
Disease duration (years)	Mean $\pm$ SD	4 $\pm$ 1.5	2.8 $\pm$ 1.6	U	0.001*
CRP	Mean $\pm$ SD	8.3 $\pm$ 4.5	7 $\pm$ 3.4	U	0.25
DAS-28	Mild	1 (10)	9 (90)	10	0.0006*
	Moderate	30 (51.7)	28 (48.3)	58	
	Severe	11 (91.6)	1 (8.4)	12	

ESR erythrocyte sedimentation rate, CRP C-reactive protein, RF rheumatoid factor, anti-CCP anti-cyclic citrullinated peptide antibodies, DAS-28 score 28-joint count disease activity score, NSAID non-steroidal anti-inflammatory drugs, U Mann-Whitney test;  $\chi^2$  chi-square test

\*Added values are significant at  $p < 0.05$

effusion was 32.2%, and in Ruta et al. [17], it was 23.3% of painful shoulders, while it was lower than our result in Naranjo et al.'s [12] study in which it was 9% in painless shoulders. Other studies showed a higher percentage of biceps tenosynovitis in their population as in the

study done by Sanja and Mirjana [20] in which it was 81.8% and in Fuda et al. [13] which was 52.5%; and in the study of Alasaarela and Alasaarela [18], the percentage was 57%, and this higher percent may be due to that their findings were done on painful shoulders.

**Table 5** Logistic regression for predicting variables for both articular and peri-articular subclinical US shoulder joint changes in RA patients

Variables	P(sig)	Lower limit of 95%CI	Odds ratio	Upper limit of 95%CI
<i>Articular</i>				
RF positive	0.006*	3.6	84.58	1994
Duration	0.018*	1.1	1.9	3.1
DAS28 mild	0.038*	1.16	14.5	181
DAS28 moderate				
DAS28 severe				
<i>Peri-Articular</i>				
Duration (years)	0.004*	1.4	4	10
Comorbidity	0.07	0.85	7.8	72
Age	0.0001*	1.1	1.3	1.5

CI confidence interval subclinical shoulder affection, RF rheumatoid factor, DAS28 28-joint count disease activity score

\*Added values are significant at  $p < 0.05$

In general, we have a lower percentage of articular MSUS changes in our study, and this may be due to that we study subclinical shoulders and not clinically active joints and our population has relatively smaller disease duration in comparison to other studies.

We found that synovitis in acromioclavicular joint was 26.87%, while the glenohumeral joint synovitis was 12.5% [7.5% effusion and 5% synovial hypertrophy]; also we found that the percentage of degenerative osteophytes in acromioclavicular joint was 23.75%, while the percentage of erosion in glenohumeral joint was 12.5%. These findings are still slightly higher than the normal percent present in healthy subjects in the study done by Iganocci et al. [11], in which the acromioclavicular joint effusion was 25.7% and the acromioclavicular joint osteophyte was 23.7%, while glenohumeral joint effusion was 2.6%, (glenohumeral joint and acromioclavicular joint) synovial hypertrophy was zero, and glenohumeral joint erosion was also zero. These findings are in agreement with the studies done on both painless and painful shoulders like Naranjo et al.'s [12] study, in which the glenohumeral joint effusion was 12% and glenohumeral joint erosion was 16% in painless joints; also Kim et al.'s [16] study found glenohumeral joint erosion in 8% and glenohumeral joint effusion in 20% of painless shoulders, while Sakellariou et al.'s [21] study found that glenohumeral joint involvement was present in 14%, humeral head erosion in 25%, and acromioclavicular joint synovitis in 26.87% of both painful and painless shoulders, while studies done on painful shoulders only showed higher percentage than ours; like in Fuda et al.'s [13] study, they found glenohumeral joint synovitis in 45% and glenohumeral joint erosion in 52.5%, and in Mohammed et al.'s [15] study, the glenohumeral joint synovitis was present in 93.7% and erosions in 29.2% of the patient's shoulders. When we studied the association between subclinical MSUS changes and the patient's characteristics, we found that the peri-articular changes were statistically significantly associated with older age, increased comorbidities present in RA patients, and longer disease durations, but comorbidities are not significant as a predictor for these changes, while the factors associated with and predicted for articular changes were high disease activity, long disease duration, and seropositive RF. We agree in these findings with the following studies done on the clinically affected shoulders in RA patients. In a study on shoulder joints in 37 RA patients by Elbinoune et al. [14], they found that the MSUS changes in shoulder joints were associated with advanced age and found that MSUS inflammatory findings in anterior recess of glenohumeral joint were linked to a higher level of rheumatoid factor and the SASDs bursitis was not associated nor with a high disease activity, nor with elevated ESR or CRP. Also, a study by Sakellariou et al. [21] found that patients with MSUS

inflammatory involvement had longer median disease duration, RF positive, higher disease activity, and higher acute phase reactants. A study also done by Fuda et al. [13] found a significant relation between MSUS-detected erosion in RA patients and disease duration and RF level as the erosion is a destructive process, and this may explain the cause of a small number of erosion in our study as our patients have relatively small disease duration.

## Conclusion

Although clinically silent shoulders in RA patients, we found a high percentage of subclinical abnormalities detected by MSUS examination. These changes were more predominant in the peri-articular structure of the shoulder joints than in the articular structure with confirmation of the finding of power Doppler as an indicator of active joint inflammation as we did not find any power Doppler activity in our population. Older age and longer disease duration were significant predictors for the peri-articular changes while high disease activity, seropositive RF, and longer disease duration were significant predictors for the articular changes. So clinical examination of RA shoulders is not conclusive in all patients and MSUS is a simple and non-invasive technique which can be used to detect subclinical affection in those patients. From the results of our present study, we can recommend to do routine regular ultrasonography examination of both shoulder joints in all patients with RA even if asymptomatic as this will help in early detection of the changes, to alarm the patients with RA about the importance of early treatment to prevent further complications and to achieve remission.

The limitation of our study is the small number and absence of a comparison control group so further studies on larger cohort of RA patients with longer disease duration and variable risk factors compared to apparently healthy people to show more structure damaging subclinical ultrasonography changes in both shoulder joints and to show the effect of subclinical shoulder lesions on functional impairment and quality of life in RA patients. It should be noted that articular changes could be a predisposing factor for the development of peri-articular changes as they definitely cause disordered biomechanics of the shoulder joint complex.

## Abbreviations

RA: Rheumatoid arthritis; MSUS: Musculoskeletal ultrasonography; ACR/EULAR: American College of Rheumatology/European League Against Rheumatism; ESR: Erythrocyte sedimentation rate; CRP: C-reactive protein; RF: Rheumatoid factor; anti-CCP: Anti-cyclic citrullinated peptide antibodies; DAS-28 score: 28-joint count disease activity score; EULAR: European League Against Rheumatism; SASD: Subacromial subdeltoid; OMERACT: Outcome measures in rheumatology clinical trials

## Acknowledgements

No specific acknowledgements.



**Authors' contributions**

SA contributed to the conception and design of the work, interpretation of the data, and revision of the work; had approved the submitted version (and any substantially modified version); and, finally, had agreed both to be personally accountable for her own contributions and to ensure that questions related to the accuracy or integrity of any part of the work, even ones in which she was not personally involved, are appropriately investigated, resolved, and the resolution documented in the literature. EE contributed to the conception and had revised it, AE contributed to the design of the work; the acquisition, analysis, and interpretation of data; and writing the work. MH contributed to the conception, design of the work, and the acquisition, analysis, interpretation of the data; revised it, and also had approved the submitted version. N.B: All authors have read and approved the final manuscript.

**Funding**

No funding for this article.

**Availability of data and materials**

Not applicable

**Ethics approval and consent to participate**

Written informed consent was obtained from patients for their study participation. The study was approved by the local ethical committee of Zagazig University Hospitals by the number (3930/13-8-2017).

**Consent for publication**

Written informed consent was obtained from patients for publication of this work.

**Competing interests**

No conflict of interest.

**Author details**

<sup>1</sup>Rheumatology and Rehabilitation Department, Faculty of Medicine, Zagazig University, Zagazig, Egypt. <sup>2</sup>Rheumatology and Rehabilitation Department, Belqas Hospital, Belqas, Egypt.

Received: 27 March 2020 Accepted: 5 May 2020

Published online: 09 June 2020

**References**

- Choy E (2012) Understanding the dynamics: pathways involved in the pathogenesis of rheumatoid arthritis. *Rheumatology (Oxford)* 51(Suppl 5): v3–v11
- Kanasawa T, Nishino J, Tohma S (2013) Analysis of the affected joints in rheumatoid arthritis patients in a large Japanese cohort. *Mod Rheumatol* 23: 44–49
- Smolen JS, Aletaha D, Bijlsma JW, Breedveld FC, Boumpas D, Burmester G et al (2010) Treating rheumatoid arthritis to target: recommendations of an international task force. *Ann Rheum Dis* 69(4):631–637
- Aletaha D, Neogi T, Silman AJ, Funovits J, Felson T, Bingham CO et al (2010) Rheumatoid arthritis classification criteria: an American College of Rheumatology/European League Against Rheumatism collaborative initiative. *Arthritis Rheum* 62(9):2569–2581
- Westergren A (1957) Diagnostic tests: the erythrocyte sedimentation rate range and limitations of the technique. *Inn Med Kinderheilkunde* 3:20–25
- Van Gaalen FA, Visser H, Huizinga TW (2005) A comparison of the diagnostic accuracy and prognostic value of the first and second anti-cyclic citrullinated peptides (CCP1 and CCP2) autoantibody tests for rheumatoid arthritis. *Ann Rheum Dis* 64:1510–1512
- Prevo ML, Hof Van't MA, Kuper HH, van MA L, van de LBA P, van PLCM R (1995) Modified disease activity scores that include twenty-eight-joint counts. Development and validation in a prospective longitudinal study of patients with rheumatoid arthritis. *Arthritis Rheum* 38(1):44–48
- Ingrid M, Janta I, Backhaus M, Ohrndorf S, Bong DA, Martinoli C et al (2017) The 2017 EULAR standardised procedures for ultrasound imaging in rheumatology. *Ann Rheum Dis* 0:1–6
- Richard J, Wakefield PV et al (2005) Musculoskeletal ultrasound including definitions for ultrasonographic pathology. *J Rheumatol* 32:2485–2487
- Johannes S, Christian L, Stefan M (2008) Sites of inflammation in painful rheumatoid shoulder assessed by musculoskeletal ultrasound and power Doppler sonography. *Rheumatol Int* 28:459–465
- Iagnocco A, Filippucci E, Sakellariou G, Ceccarelli F, Geso D, Carli L et al (2013) Ultrasound imaging for the rheumatologist XLIV. Ultrasound of the shoulder in healthy individuals. *Clin Exp Rheumatol* 31:165–171
- Naranjo A, Marrero-Pulido T, Ojeda S, Francisco F, Erausquin C, Rua-Figueroa I et al (2002) Abnormal sonographic findings in the non-painful arthritic shoulder. *Scand J Rheumatol* 31:17–21
- Fudaa AI, Ismail N, Galalb O (2015) Ultrasonographic findings of the shoulders in Egyptian patients with rheumatoid arthritis. *Egyptian Rheumatology & Rehabilitation* 44:17–23
- Elbinoune I, Amine B, Moudjibou W, Rkain H, Aktaou S, Hajjaj-Hassouni N (2016) Rheumatoid shoulder assessed by ultrasonography: prevalence of abnormalities and associated factors. *Pan African Medical Journal* 24:235
- Mohamed Moneer Rayan, Ahmed Mosallam Ebrahim, Ahmed Aly Abdelaziz and Saad Rizk Abdelwahed. Assessment of site of inflammation in painful Rheumatoid shoulder by musculoskeletal ultrasonography, power Doppler sonography and magnetic resonance imaging. *AAMJ*. 2012;10 N.2.
- Kim HA, Kim SH, Seo Y (2007) Ultrasonographic findings of the shoulder in patients with rheumatoid arthritis and comparison with physical examination. *J Koran Med Sci* 22:660–666
- Ruta S, Rosa J, Navarta D A, Saucedo C, Catoggio L and Soriano E. Ultrasound assessment of new onset bilateral painful shoulder in patients with polymyalgia rheumatica and rheumatoid arthritis 2012.
- Alasaarela EM, and Alasaarela EL Ultrasound evaluation of painful rheumatoid shoulders *J Rheumatol*. Sep 1994;21(9):1642-1648
- Coari G, Paoletti F, Iagnocco A (1999) Shoulder involvement in rheumatic diseases. Sonographic findings *J Rheumatol* 26:668–673
- Sanja MR, Mirjana ZS (2010) Ultrasonographic study of the painful shoulder in patients with rheumatoid arthritis and patients with degenerative shoulder disease. *Acta Rheumatol Port* 35(1):50–58
- Sakellariou G, Iagnocco A, Filippucci E (2013) Ultrasound imaging for the rheumatologist. Ultrasound of the shoulders of patients with rheumatoid arthritis *Clin Exp Rheumatol* 31:837–842

**Publisher's Note**

Springer Nature remains neutral with regard to jurisdictional claims in published maps and institutional affiliations.

**Submit your manuscript to a SpringerOpen® journal and benefit from:**

- Convenient online submission
- Rigorous peer review
- Open access: articles freely available online
- High visibility within the field
- Retaining the copyright to your article

Submit your next manuscript at ► [springeropen.com](https://www.springeropen.com)