

ORIGINAL ARTICLE

Open Access



# Evaluation of computed tomography (CT) findings in patients with symptomatic deviated nasal septum and their correlation with intraoperative findings

Ayaz Rehman<sup>1</sup>, Faiza Ashfah Deva<sup>1</sup>, Bashir Ahmad Malik<sup>1\*</sup> , Asif A. Wani<sup>1</sup> and Majid ul Islam Masoodi<sup>1</sup>

## Abstract

**Aim** To evaluate the computed tomography (CT) findings in patients having a symptomatic deviated nasal septum (DNS) and their comparison with intraoperative findings.

**Methods** Cross-sectional, observational study done in the department of ENT and HNS at a tertiary care center, over a period of 16 months. Patients presenting with nasal obstruction as the chief complaint and findings of deviated nasal septum on anterior rhinoscopy without clinical features of chronic rhinosinusitis (CRS) were included in the present study. All patients underwent CT scans of paranasal sinuses (PNS) as per the govt. scheme for approval of surgery. Surgery was planned as per the indication based on history, clinical examination, and non-contrast CT scan PNS findings. The average duration from CT scan to surgery was 4.5 weeks.

**Results** All 200 (100%) patients had DNS with inferior turbinate hypertrophy in 103 (52.5%), concha bullosa in 22 (11.0%), pneumatized superior turbinate in 6 (3.0%), and PMT (paradoxical middle turbinate) in 22 (11.0%). On comparing CT scan findings with intraoperative findings, it was found that maxillary sinus involvement had been seen in 28 (14.0%) patients on CT scan and only 8 (4.0%) patients intraoperatively. Similarly, CT scan involvement compared to and intraoperative involvement of anterior ethmoidal sinus was seen in 20 (10.0%) compared to 6 (3.0%) patients intraoperatively, posterior ethmoid in 12 (6.0%) compared to 3 (1.5%) frontal sinus in 4 (2.0%) compared to 1 (0.5%), sphenoid in 11 (5.5%) compared to 2 (1.0%), and osteomeatal complex (OMC) in 27 (13.5%) compared to 6 (3.0%) patients intraoperatively. Involvement of PMT, enlarged inferior, and concha bullosa was similar on CT scan and intraoperatively.

**Conclusion** From this study, we concluded that a preoperative CT scan is a poor tool in predicting sinus disease in patients without clinical features of sinus disease and has a limited role in patients with symptomatic DNS. Insurance companies and government agencies should review their policies of ordering CT scans for approving septal surgeries.

**Keywords** Deviated nasal septum (DNS), Nasal obstruction, NCCT nose and PNS, Septoplasty

## Background

The nasal septum is divided into bony, cartilaginous, and membranous parts. Most of the deviations are present in the cartilaginous part followed by bony septal deviations and bony cartilaginous junction. DNS is a nasal disorder, where the septum is deviated from its normal straight,

\*Correspondence:

Bashir Ahmad Malik  
drbasir.orthns18@gmail.com

<sup>1</sup> Department of ENT & HNS, SKIMS MCH, Bemina, Srinagar, India

symmetrical, and midline position. DNS approximately affects 80% of people, most of them unknowingly [1, 2]. Septal deflections can be developmental or secondary to trauma. Trauma during birth can cause septal deviations which are evident only later in life when there is a more active growth phase of puberty. In some cases, trauma occurs in childhood and can be easily overlooked until it increases with age and growth [3, 4]. Nasal obstruction is the most common symptom of DNS. Patients with unilateral septal deviations may complain of nasal obstruction on the contralateral side mostly due to inferior turbinate enlargement or hypertrophy of inferior turbinate (HIT) a phenomenon called paradoxical nasal obstruction. Therefore, turbinate reduction surgery is often done along with septoplasty procedures [5–9].

Anterior rhinoscopy allows visualization of the septum, inferior turbinate, and nasal valve area. Diagnostic nasal endoscopy allows detailed anatomy of the entire nasal cavity in most cases except when there is obstruction by impacted DNS, massive turbinate hypertrophy, large mass lesions in the nasal cavity, and apprehensive/uncooperative patients. Some authors promote physical examination as the gold standard for diagnosis of symptomatic DNS and that CT scan has a limited role in this patient population [10]. Non-contrast computed tomography (NCCT) is the preferred approach for assessing nose and paranasal sinus structure and inflammation [11]. A preoperative CT scan in symptomatic DNS patients can examine the nasal structure and identify ancillary sinonasal disorders. However this approach is more expensive, exposes patients to hazardous radiation, and may assess septal deviation differently than a dynamic 3-D physical assessment. It is therefore necessary to examine indications for its appropriate use before septoplasty [12]. When nasal endoscopy is limited by obstructive pathology or chronic rhinosinusitis, a preoperative CT is recommended. CT is not recommended for septoplasty candidate selection or insurance approval, according to the literature [10]. Furthermore, soft tissue thickenings on CT scans without symptoms of sinus disease are not an indication for sinus surgery and most of these patients have normal or near normal sinuses on endoscopic sinus surgery when surgery was done after a few weeks following the CT scan.

This study was done to assess the CT scan results in patients having symptomatic DNS and compare those findings with intraoperative findings.

## Methods

### Setting of study

This research has been performed in the Department of ENT and HNS, in a tertiary care hospital for a duration of 16 months from January 2022 to April 2023.

### Population

The population comprised of the patients attending the outpatient department of ENT and HNS.

### Sample size

The sample size consisted of 200 patients who were admitted to the ENT and HNS department and fulfilled the criteria for sample selection.

### Criteria for sample selection

#### Inclusion criteria

- A patient presenting with nasal obstruction and diagnosed with DNS on anterior rhinoscopy.

#### Exclusion criteria

- Acute or chronic rhinosinusitis with or without nasal polyposis.
- History of previous nasal surgery.
- Tumors involving the nose and PNS.

### Tools and techniques

Patients presenting with nasal obstruction and findings of DNS on anterior rhinoscopy, who satisfy the inclusion criteria, were in the research. Detailed history has been taken including history of the symptoms, their time duration, aggravating and relieving factors, allergic history, medication history, and history of past nasal surgery. ENT examination was done including a nasal examination. External nasal examination and nasal cavity assessment have been done. Anterior rhinoscopy and nasal endoscopic findings were recorded for each patient. NCCT of PNS was ordered for each patient. Coronal and axial sections with a slice thickness of 1 mm were done to evaluate each patient to look for any inflammatory changes within the nose and paranasal sinuses, OMC pathologies, and turbinate hypertrophy. Any anatomical variations like concha bullosa, uncinate process abnormalities, and other anatomical variations may cause or aggravate nasal obstruction. Based on history, examination, and CT scan findings, the surgery was planned accordingly. In addition to septoplasty and inferior turbinate reduction, many additional procedures were done based on CT scan findings. Intraoperative endoscopic findings like para nasal sinus mucosal thickenings, PMT, enlarged inferior turbinate, concha bullosa, and OMC pathologies were recorded. All the sinuses showing mucosal thickening or opacities on the preoperative CT scans were operated on and the findings were recorded on the basis of the presence or absence of mucosal

thickenings or polyposis. However, any secretions other than mucopurulent in the osteomeatal area and sinuses were considered to be a negative endoscopic finding.

**Statistical evaluation**

Spreadsheets were used to compile and input the data. Version 24.0 of SPSS's data editor was exported (SPSS Inc., Chicago, IL, USA). Frequency and percentage were used to summarize categorical variables. For each parameter of relevance, the McNamara chi-square test has been utilized for comparing CT results to intraoperative findings. A *p*-value <0.05 has been determined statistically significant and 2-tailed *p*-values have been presented. STATA version 15 was used for the statistical analysis.

**Results**

In our study, deviated nasal septum was present in all 200 (100%) patients. It was C-shaped on the right side in 68 (34%) patients, C-shaped left side in 74 (37%) patients, S-shaped DNS in 30 (15.0%) patients, and C/S-shaped DNS with spur was seen in 28 (14.0%) patients. Enlarged inferior turbinate had been seen in 103 (51.5%) patients, 32 (16.0%) patients on right side, 27 (13.5%) patients on left side, and 44 (22.0%) patients bilaterally. Concha bullosa or pneumatized middle turbinate was found in 11 (5.5%) patients on right side, 9 (4.5%) patients on the left side, and 2 (1.0%) patients bilaterally. PMT was seen in 10 (5.0%) patients on right side, 8 (4.0%) patients on left side, and 2 (1.0%) patients bilaterally. Pneumatized superior turbinate had been observed in 1 (0.5%) patient on right side, 2 (1.0%) patients on the left side, and 3 (1.5%) patients bilaterally. Osteomeatal complex was blocked in 27 (13.5%) patients, right side 7 (3.5%), left side 13 (6.5%), and bilateral 7 (3.5%) (Table 1).

Paranasal sinus mucosal thickening was seen in many patients. It was seen in maxillary sinus right side 7 (3.5%) patients, left side 14 (3.5%) patients, and bilateral 7 (3.5%) patients; anterior ethmoidal sinuses right 6 (3.0%), left 4 (2.0%), and bilateral 10 (5.0%); posterior ethmoidal sinuses right 4 (2.0%), left 3 (1.5%), and bilateral 5 (2.5%); sphenoidal sinus right 5 (2.5%), left 4 (2.0%), and bilateral 2 (1.0%); and frontal sinus right 2 (1.0%), left 1 (0.5%), and bilateral 1(0.5%). Agar nasi cell was seen in 27 (13.5%) patients, onodi cells 11 (6.5%) patients, haller cells in 14 (7.0%) patients, and pneumatized uncinata in 6 (3.0%) patients (Table 2).

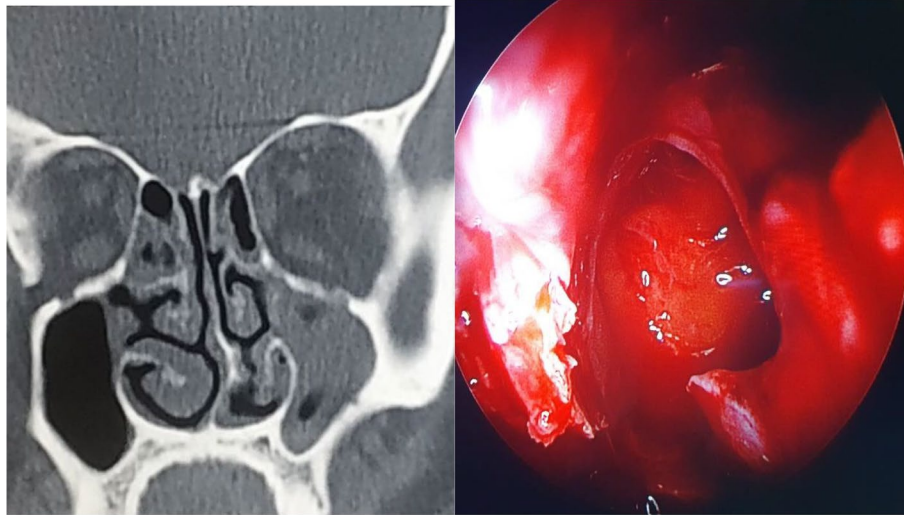
In this study, a comparison of NCCT findings and intraoperative findings was done. There was a time gap of 4.5 weeks on average between CT scan and surgery. Maxillary sinus mucosal thickening had been found in 28 (14.0%) patients on CT scan but only in 8 (4.0%) patients intraoperatively (Fig. 1). Anterior ethmoid sinus mucosal thickening had been found in 20 (10.0%) patients on CT

**Table 1** NCCT findings of study patients (n=200)

<b>Deviated nasal septum (DNS)</b>	Right (C-shaped)	68	34.0
	Left (C-shaped)	74	37.0
	S-shaped	30	15.0
	C/S shaped DNS with spur	28	14.0
<b>Enlarged inferior turbinate</b>	Right	32	16.0
	Left	27	13.5
	Bilateral	44	22.0
<b>Concha bullosa</b>	Right	11	5.5
	Left	9	4.5
	Bilateral	2	1.0
<b>Pneumatized superior turbinate</b>	Right	1	0.5
	Left	2	1.0
	Bilateral	3	1.5
<b>Paradoxical middle turbinate</b>	Right	10	5.0
	Left	8	4.0
	Bilateral	2	1.0
<b>Osteomeatal complex (OMC) blocked</b>	Right	7	3.5
	Left	13	6.5
	Bilateral	7	3.5

**Table 2** NCCT findings of study patients (n=200)

Findings	No. of patients	Percentage
<b>Maxillary sinus mucosal thickening</b>		
Right	7	3.5
Left	14	7.0
Bilateral	7	3.5
<b>Frontal sinus/recess mucosal thickening</b>		
Right	2	1.0
Left	1	0.5
Bilateral	1	0.5
<b>Anterior ethmoid sinus mucosal thickening</b>		
Right	6	3.0
Left	4	2.0
Bilateral	10	5.0
<b>Posterior ethmoid sinus mucosal thickening</b>		
Right	4	2.0
Left	3	1.5
Bilateral	5	2.5
<b>Sphenoid sinus mucosal thickening</b>		
Right	5	2.5
Left	4	2.0
Bilateral	2	1.0
<b>Agger nasi cell</b>	27	13.5
<b>Onodi cells</b>	11	5.5
<b>Haller cells</b>	14	7.0
<b>Pneumatized uncinata</b>	6	3.0



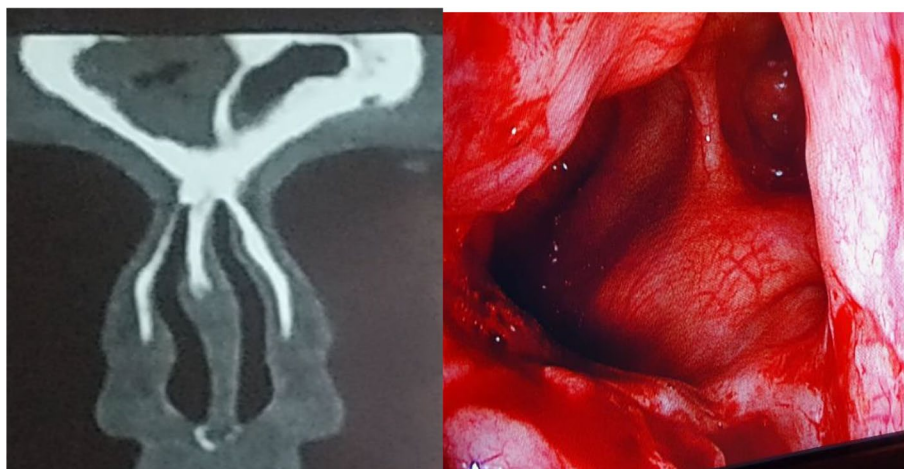
**Fig. 1** Preoperative CT scan and intraoperative endoscopic picture of left maxillary sinus. Left showing pre-operative CT scan with maxillary sinus opacity, on right side showing intraoperative endoscopic picture of the same patient after 4 weeks. Maxillary sinus is clear and disease-free intraoperatively

scan but only in 6 (3.0%) patients intraoperatively (Fig. 2). Posterior ethmoidal sinus mucosal thickening had been observed in 12 (6.0%) patients on CT scan but only in 3 (1.5%) patients intraoperatively. Sphenoid sinus mucosal thickening was found in 11 (5.5%) patients on CT scan but only in 2 (1.0%) patients intraoperatively. Frontal sinus mucosal thickening was seen in 4 (2.0%) patients on CT scan but only in 1 (0.5%) patient intraoperatively (Fig. 3). PMT had been found in 20 (10.0%) patients on CT scan and 20 (10.0%) patients intraoperatively. Enlarged inferior turbinate had been found in 103 (51.5%)

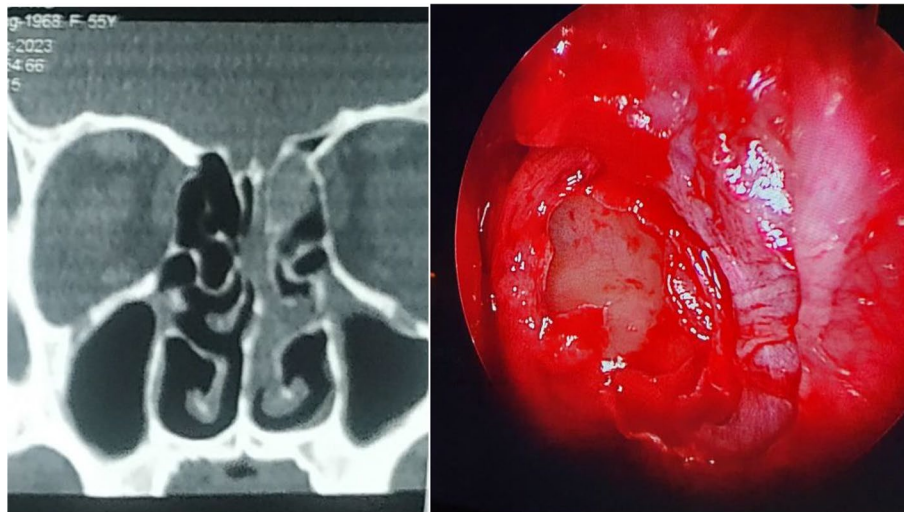
patients on CT scan and 103 (51.5%) patients intraoperatively. Pneumatized middle turbinate/concha bullosa had been observed in 22 patients on CT scan and 22 patients intraoperatively (Table 3).

### Discussion

Nasal obstruction is the frequent complaint in otolaryngology clinics and deviated nasal septum is the frequent isolated cause of nasal obstruction. Symptomatic DNS can be an isolated entity or it can be associated with other anatomical or pathological conditions causing or



**Fig. 2** Preoperative CT scan and intraoperative endoscopic picture of right frontal sinus. Left showing pre-operative CT scan with right frontal sinus opacity, on right side showing intraoperative endoscopic picture of the same patient after 3 weeks. Frontal sinus is clear and there was no pathology seen intraoperatively



**Fig. 3** Preoperative CT scan and intraoperative endoscopic picture of left anterior ethmoidal sinus. Left showing pre-operative CT scan with left anterior ethmoid sinus mucosal thickenings, on right side showing intraoperative endoscopic picture of the same patient after 5 weeks. Anterior ethmoids were clear intraoperatively

**Table 3** Comparison of NCCT and intraoperative endoscopic findings (n = 200)

	NCCT findings		Intraoperative findings	
	No	%age	No	%age
Maxillary sinus disease	28	14.0	8	4.0
Anterior ethmoid disease	20	10.0	6	3.0
Posterior ethmoid disease	12	6.0	3	1.5
Frontal sinus/recess disease	4	2.0	1	0.5
Sphenoid sinus disease	11	6.5	2	1.0
OMC blocked	27	13.5	6	3.0
Paradoxical middle turbinate	20	10.0	20	10.0
Enlarged inferior turbinate	103	51.5	103	51.5
Concha bullosa	22	11.0	22	11.0
Haller cell	27	13.5	27	13.5
Onodi cell	11	5.5	11	5.5
Agar nasi cell	14	7	14	7

aggravating obstructive symptoms. A decreased quality of life is an integral accompaniment of nasal blockade. Most of these patients with nasal obstruction secondary to deviated nasal septum need corrective surgery in the form of septoplasty with or without turbinate reduction. Some patients need additional procedures depending upon CT scans and/or other investigations. Septoplasty with or without inferior turbinate reduction improves nasal airway and therefore quality of life in these patients [13].

CT is the current imaging standard of choice in evaluating the nose and paranasal sinus pathology and

anatomy. It is currently the preferred tool to visualize anatomical borders and to detect pathology in the nose and paranasal system. The role of CT scan in the preoperative evaluation of symptomatic DNS is inconclusive in the literature. Some studies clearly demonstrate its role in symptomatic DNS [12, 14, 15] while others are against it [16–18]. This study was done to evaluate CT scan findings in symptomatic DNS patients and compare those findings with intraoperative endoscopic findings.

In this study, most of the patients were young with 130 (65%) patients between 20 and 30 years of age. The mean age in years was  $26.4 \pm 3.2$  years. The average time from CT scan to surgery was 4.2 weeks. Adeel et al. [19] in their study had a mean age of  $31.0 \pm 13.15$ . Similar research by Kanwar et al. [20] found that the majority of patients (33%) in their research were between the ages of 21 and 30. All patients present with nasal obstruction. Other symptoms present were headache, snoring, sneezing, nasal discharge, and nasal bleeding. Most common type of DNS was C-shaped present in 142 (72.0%) patients followed by S-shaped DNS in 30 (15.0%) and DNS with spur in 28 (14.0%) patients. According to Kanwar et al. [20], DNS was present on the right side of 43.9% of patients and on the left of 28.5% of patients. Rehman et al. [21] discovered left-sided DNS in 40.5% of patients and right-sided DNS in 59.4% of patients. In another study by Moorthy et al. [22], 90% of patients had C-shaped DNS, whereas 10% had S-shaped DNS.

Enlarged inferior turbinate was seen in 103 (51.5%) of our patients. Isolated right and left inferior turbinate enlargement was seen in 32 (16.0%) and 27 (13.5%) patients respectively while bilateral inferior turbinate

enlargement had been observed in 44 (22.0%) patients. Farhan et al. [23] in their study found inferior nasal turbinate hypertrophy in 99 of 130 (76.2%) patients; it was seen in 28 (21.5%) patients on the right side and 21 (16.2%) patients on the left side and 50 (38.5%) patients bilaterally. Enlarged inferior turbinate was seen by Chakraborty et al. [24] and Eylgor et al. [25] in 57.3% and 25.1% of patients respectively. Chavan et al. [26] found enlarged inferior turbinate in 66% of their study population.

Concha bullosa had been seen in 11 (5.5%) patients on the right side, 9 (4.5%) patients on the left side, and 2 (1.0%) patients bilaterally. PMT was seen in 10 (5.0%) patients on the right side, 8 (4.0%) patients on the left side, and 2 (1.0%) patients bilaterally. In a similar study by Chevan et al. [26] PMT had been observed in 1 (0.5%) patient on the right side, 2 (1.0%) patients on the left side, and 3 (1.5%) patients bilaterally. Farhan et al. [23] observed concha bullosa in 30% of patients, unilateral in 25.33%, and bilateral in 4.66% of patients. In another study by Wani et al. [27], concha bullosa was seen in 45 individuals (30%), unilaterally (U/L) in 38 patients (25.33%), and bilaterally (B/L) in 7 patients (4.66%). In their study, 14 (9.33%) individuals had a PMT curvature. Incidence of concha bullosa was reported by Lloyd [28] in 14% of patients, Mamatha et al. [29] in 15% of patients, Dua et al. [30] in 16% of patients, Berenholz [31] in 20% patients, Rajneesh et al. [32] in 32% patients, and Karatas et al. [33] in 35% patients. Dar et al. [15] in their study found bullous middle turbinate in 11.6% of patients, and PMT in 12 (10%) patients. Eylgor et al. [25] found PMT in 10.8% of patients.

Osteomeatal complex was blocked in 27 (13.5%) patients in our series; it was on the right side in 7 (3.5%), left side in 13 (6.5%), and bilateral in 7 (3.5%) patients. Dar et al. [15] had OMC blocked in 17 (14.2%) out of 120 patients. Chevan et al. [26] found blocked OMC in 60% of patients in their study.

Mucosal thickening of paranasal sinuses was seen in many sinuses on NCCT. Maxillary sinus in 28 (14%) patients was the most common sinus involved; anterior ethmoidal sinuses right 6 (3.0%), left 4 (2.0%), and bilateral 10 (5.0%); posterior ethmoidal sinuses right 4 (2.0%), left 3 (1.5%), and bilateral 5(2.5%); sphenoidal sinus right 5 (2.5%), left 4 (2.0%), and bilateral 2(1.0%); and frontal sinus right 2 (1.0%), left 1 (0.5%), and bilateral 1(0.5%). In the study by Dar et al. [15], 16 (13.3%) patients had mucosal thickening or disease of the maxillary sinus, compared to 8 (6.7%) for the anterior ethmoid sinus, 4 (3.3%) for the posterior ethmoid sinus, 2 (1.7%) for the sphenoid sinus, and 1 (0.8%) for the frontal sinus. In another study by Moheiby et al. [34], maxillary sinus was the most common sinus involved in their patients;

this was followed by ethmoidal sinus, frontal, and sphenoidal sinuses. In a study by Dar et al. [15], 16 patients (13.3%) had mucosal thickening or disease of the maxillary sinus, compared to 8 (6.7%) patients with anterior ethmoid sinus disease and 4 (3.3%) patients with posterior ethmoid sinus disease, 2 (1.7%) patients with sphenoid sinus disease, and 1 (0.8%) patient with frontal sinus disease.

In this study, agar nasi cell was seen in 27 (13.5%) patients, onodi cells 11 (6.5%) patients, haller cells in 14 (7.0%) patients, and pneumatized uncinata in 6 (3.0%) patients. Haller cells have been observed in 13 (8.6%) of the patients in research by Wani et al. [27] and abnormal agger nasi cells in 14 (9.33%) of their patients. Chevan et al. [20] in their series of 50 patients found ITH in 60%, and paradoxical MT in 16% concha bullosa in 44% of their patients. Dar et al. [15] in their study found onodi cells in 9 (7.5%) patients, haller cells in 10 (8.3%) patients, pneumatized uncinata in 4 (3.3%) patients, and agger nasi cells in 17 (14.2%) patients; OMC was blocked in 5.8% of their patients. In a similar study by Eylgor et al. [25] agger nasi cells were present in 16.1% of patients and haller cells in 9.3% of patients. In a different research, Chakraborty et al. [24] discovered that agger nasi cells were present in 26.8% of patients, PMT was in 14.63% of patients, and onodi cells were in 10.9% of patients.

A correlation of pathological findings between CT scans and intraoperative endoscopy in symptomatic DNS patients is sparse in literature unlike patients with chronic rhinosinusitis where excellent correlation has been found by many studies. Only a few studies were found on the subject. In this study, a comparison of NCCT findings and intraoperative findings was done. The maxillary sinus was the most frequent sinus involved. Maxillary sinus mucosal thickening had been seen in 28(14%) patients on CT scan but only in 8(4%) patients intraoperatively. Anterior ethmoid sinus mucosal thickening had been found in 20(10%) patients on CT scan but only in 6(3%) patients intraoperatively. Posterior ethmoidal sinus mucosal thickening had been observed in 12(6%) patients on CT scan but only in 3(1.5%) patients intraoperatively. Sphenoid sinus mucosal thickening had been found in 11 patients on CT scan but only in 2 patients intraoperatively. Frontal sinus mucosal thickening had been found in 4 patients on CT scan but only in 1 patient intraoperatively. PMT had been observed in 20 patients on CT scan and 20 patients intraoperatively. Enlarged inferior turbinate had been observed in 103 patients on CT scan and 103 patients intraoperatively. PMT/concha bullosa turbinate had been observed in 22 patients on CT scan and 22 patients intraoperatively. In related research by Dar et al. [15], mucosal thickening of the maxillary sinus had been observed in 16 (13.3%) patients, as well as

anterior and posterior ethmoid sinus disease in 8 (6.7%), sphenoid sinus disease in 2 (1.7%), and frontal sinus disease in 1 (0.8%) patients. In a research by Mohebbi et al. [34], bilateral maxillary sinusitis had been observed in 27% of patients while unilateral disease had been observed in 18.4%; likewise, unilateral frontal sinus involvement had been observed in 12.5% and bilaterally in 11.2%, unilateral sphenoidal sinus in 13% patients and bilateral sphenoidal sinusitis had been observed in 12.3%, bilateral ethmoidal sinusitis had been observed in 36.1%, and unilateral ethmoidal sinusitis had been found in 18.1% patients.

As shown in Table 3, there was an excellent association among preoperative CT scan and intraoperative endoscopic results in terms of anatomical variations, but there was a poor correlation between pathological CT findings like mucosal thickenings, OMC block, and intraoperative endoscopic findings. Therefore, any CT scan paranasal sinus mucosal thickenings that are not supported by clinical findings should not be made basis for additional procedures.

## Conclusion

From this study, we concluded that a preoperative CT scan is a poor tool for predicting sinus disease in patients without clinical features of sinus disease and has a limited role in patients with symptomatic DNS. Additional procedures were done on the basis of these incidental findings on CT. But intraoperatively, we find a poor correlation with most of these incidental pathological findings like mucosal thickenings and blocked OMC. Insurance companies and government agencies should review their policies of ordering CT scans for approving septal surgeries. Further soft tissue thickenings on CT scans without symptoms of sinus disease are not an indication for sinus surgery and most of these patients have normal or near normal sinuses on endoscopic sinus surgery when surgery was done after a few weeks following the CT scan. Further sinus mucosal thickening, or CRS, is a medical disease and surgical indications must be strong before considering the patient as a candidate for surgery.

## Acknowledgements

Acknowledgement sought.

## Authors' contributions

AR was major contributor in writing the manuscript. BAM is the corresponding author, and analyzed and compiled the patient data. AAW is senior author who did the surgeries and supervised the research. MIM contributes in diagnosis and patient data collection. FAD contributes in diagnosis and patient data collection.

## Funding

Nil.

## Availability of data and materials

The data sets used/analyzed during the current study are available from corresponding author on reasonable request.

## Declarations

### Ethics approval and consent to participate

Ethical clearance sought from the ethical committee of the institution named "Institutional Ethical Committee (IEC)" SKIMS-MC Srinagar Kashmir India. Reference number: IECSKIMSMC 2023/2501/301, Dated- 25/01/2023.

Written and informed consent to participate in the study was taken from each patient in common and understandable language I agree to participate in the study that my labs and medical data be used for medical research.

### Consent for publication

Not applicable.

### Competing interests

The authors declare that they have no competing interests.

Received: 19 July 2023 Accepted: 12 January 2024

Published online: 30 January 2024

## References

- Gray LP (1972) Early treatment of septal deformity and associated abnormalities. *Mod Nose Throat* 219–236
- Gray LP (1978) Deviated nasal septum. Incidence and etiology: annals of otology. *Rhinology Laryngology* 87(Suppl. 50):3–20
- Brain D (1992) The etiology of neonatal septal deviation. *Facial Plast Surg* 8(4):191–193
- Kent SE, Reid AP, Nairand ER, Brain DJ (1988) Neonatal septal deviations. *J Royal Soc Med* 81(3):123–135
- Egeli E, Demirci L, Yazycy B, Harputluoglu U (2004) Evaluation of the inferior turbinate in patients with deviated nasal septum by using computed tomography. *Laryngoscope* 114(1):113–117
- Akoglu E, Karazincir S, Balci A, Okuyucu S, Sumbas H, Dagli AS (2007) Evaluation of the turbinate hypertrophy by computed tomography in patients with deviated nasal septum. *Otolaryngol Head Neck Surg* 136(3):380–384
- Kim DH, Park HY, Kim HS, Kang SO, Park JS, Han NS et al (2008) Effect of septoplasty on inferior turbinate surgery. *Arch Otolaryngol Head Neck Surg* 134(4):419–423
- Jun BC, Kim SW, Kim SW, Cho JH, Park YJ, Yoon HR (2009) Is turbinate surgery necessary when performing a septoplasty? *Eur Arch Otorhinolaryngol* 266(7):975–980
- Orhan I, Aydin S, Ormeci T, Yilmaz F (2014) A radiological analysis of inferior turbinate in patients with deviated nasal septum by using computed tomography. *Am J Rhinol Allergy* 28(1):e68–72
- Wotman M, Kacker A (2016) What are the indications for the use of computed tomography before septoplasty? *Laryngoscope* 126(6):1268–1270. <https://doi.org/10.1002/lary.25815>
- Wuister AM, Goto NA, Oostveen EJ et al (2014) Nasal endoscopy is recommended for diagnosing adults with chronic rhinosinusitis. *Otolaryngol Head Neck Surg* 150:359–364
- Lebowitz RA, Suzanne K, Galli D, Holliday RA, Jacobs JB (2001) Nasal septal deviation: a comparison of clinical and radiological evaluation. *Oper Tech Otolaryngol Head Neck Surg* 12:104–106
- Han JK, Stringer SP, Rosenfeld RM et al (2015) Clinical consensus statement: septoplasty with or without inferior turbinate reduction. *Otolaryngology Head Neck Surg* 153(5):708–720
- Sedaghat AR, Kieff DA, Bergmark RW, Cunnane ME, Busaba NY (2015) Radiographic evaluation of nasal septal deviation from computed tomography correlates poorly with physical exam findings. *Int Forum Allergy Rhinol* 5:258–262
- Dar NH, Altaf S, Patigaroo SA et al (2022) Role of non-contrast computed tomography of nose and paranasal sinus in preoperative evaluation of patients with symptomatic deviated nasal septum. *Indian J Otolaryngol Head Neck Surg* 74(Suppl 2):1502–1509. <https://doi.org/10.1007/s12070-021-02636-3>

16. Lee DC, Shin JH, Kim SW et al (2013) Anatomical analysis of nasal obstruction; nasal cavity of patients complaining of stuff nose. *Laryngoscope* 123:1381–1384
17. Karatas D, Yuksel F, Senturk M, Dogan M (2013) The contribution of computed tomography to nasal septoplasty. *J Craniofac Surg* 24:1549–1551
18. AlQahtani AS, Dagriri RM, Shamakhi RE, Alrasheed AM, Etwadi AA, AlQahtani KA (2021) Determining the impact of pre-operative computed tomography scan in patients underwent septoplasty on the postoperative complications. *New Front Med Medical Res* 2:75–80. <https://doi.org/10.9734/bp/nfmmr/v2/2818F>
19. Adeel M, Rajput MSA, Akhter S, Ikram M, Arain A, Khattak YJ (2013) Anatomical variations of nose and para-nasal sinuses: CT scan review. *J Pak Med Assoc* 63(3):317–19
20. Kanwar SS, Mital M, Gupta PK, Saran S, Parashar N, Singh A (2017) Evaluation of paranasal sinus disease by computed tomography and its histopathological correlation. *J Oral Maxillofac Radiol* 5:46–52
21. Rehman A, Hamid S, Ahmad M, Rashid A (2012) A prospective study of nasal septal deformities in Kashmiri population attending tertiary care hospital. *Int J Otolaryngol Head Neck Surg* 1:77–84
22. Moorthy PNS, Kolloju S, Madhira S, Jowka AB (2014) Clinical study on deviated nasal septum and its associated pathology. *Int J Otolaryngol Head Neck Surg* 3:75–81
23. Farhan N, Naqvi S, Rasheed B et al (2020) Identification of significant anatomical variations in the nose and anterior skull base using computed tomography: a cross-sectional study. *Cureus* 12(6):e8449. <https://doi.org/10.7759/cureus.8449>
24. Chakraborty P, Jain RK (2016) Radiologic variations of nose and paranasal sinuses: a CT based study. *JMSCR* 04(5):10536–10541
25. Eylgor H, Kucuktepe U, Yilmaz MD, Osmar U, Durmus E, Erol B et al (2018) Is performing the paranasal sinus CT before the septal operation change the indication of surgery? *Eur J Rhinol Allergy* 1:43–46
26. Chavan A, Maran R, Meena K (2019) Diagnostic evaluation of chronic nasal obstruction based on nasal endoscopy and CT scan paranasal sinus. *Indian J Otolaryngol Head Neck Surg* 71(Suppl 3):1948–1952. <https://doi.org/10.1007/s12070-018-1376-6>. Epub 2018 May 5. PMID: 31763274; PMCID: PMC6848296
27. Wani AA, Kanotra S, Lateef M, Ahmad R, Qazi SM, Ahmad S (2009) CT scan evaluation of the anatomical variations of the ostiomeatal complex. *Ind J Otolaryngol Head Neck Surg* 61(3):163–168. <https://doi.org/10.1007/s12070-009-0059-8>
28. Lloyd GA (1990) CT of the paranasal sinuses: study of a coronal series in relation to endoscopic sinus surgery. *J Laryngol Otol* 104(6):477–481
29. Mamatha H, Shamasunder NM, Bharathi M, Prasanna L (2010) Variations of ostiomeatal complex and its applied anatomy: a CT scan study. *Indian J Sci Technol* 3:904–907
30. Dua K, Chopra H, Khurana AS, Munjal M (2005) CT scan variations in chronic sinusitis. *Ind J Radiol Imag* 15(3):315–320
31. Berenholz L, Kessler A, Lapinsky J, Segal S, Shlamkovitch N (2000) Nasal obstruction in the adult: is CT scan of the sinuses necessary? *Rhinology* 38(4):181–184
32. Rajneesh, Rahul S (2017) A radiological study of anatomical variations in ostiomeatal complex in patients with chronic rhinosinusitis. *Int J Otorhinolaryngol Head Neck Surg* 3(3):528–533
33. Karatas D, Yuksel F, Senturk M, Dogan M (2013) The contribution of computed tomography to nasal septoplasty. *J Craniofac Surg* 24:1549–1551
34. Mohebbi et al (2012) An epidemiologic study of factors associated with nasal septum deviation by computed tomography scan: a cross sectional study. *BMC Ear Nose Throat Disord* 12:15

## Publisher's Note

Springer Nature remains neutral with regard to jurisdictional claims in published maps and institutional affiliations.