

ORIGINAL RESEARCH

Open Access

# The “branching external jugular vein”: an unreported clinically significant anatomic variation



Mohamed Sameh Shalaby 

## Abstract

**Background:** The reported overall success rate for central venous catheter (CVC) insertion into the external jugular vein (EJV) is less than other central veins. A contributing factor for this might be the well-documented anatomical variations of the EJV. However, there are no reports correlating these anatomical variations with successful CVC insertion. Our aim was to evaluate the EJV anatomical variations and their clinical relevance.

**Results:** All CVCs inserted over the study period were prospectively recorded with emphasis on the times the EJV was accessed, operative difficulties and any anatomical variations with their influence on CVC insertion. Over 15 months, 36 CVCs were inserted, 17 (47%) into EJV. For EJV line insertions, age is 39 days–14 years, 9 into right EJV. Operative difficulty was encountered in 4 patients (24%) where the catheter was inserted into EJV but failed to thread into a satisfactory position. In all 4 patients, further dissection revealed EJV branching into a bigger anterior branch which follows the course of main EJV yet not leading to the right atrium (RA) and a smaller posterior branch leading to RA. Regarding the 4 cases of “the branching EJV”, age is 2–14 years, 3 males:1 female and 3 left:1 right EJV. The overall success rate for CVC insertion through the EJV in this study was 100% including the 4 cases with “the branching EJV”.

**Conclusions:** This is the first report describing “the branching EJV” and its clinical relevance to CVC insertion.

**Keywords:** External jugular, Anomaly, Anatomy, Branching, Vein, Central venous lines

## Background

Central venous catheters (CVCs) are commonly needed in intensive care, for parenteral nutrition, chemotherapy and following major surgeries [1]. Access particularly in children can be quite difficult and challenging owing to their small size [2]. The success of the procedure or occurrence of complications depends on several factors, such as the size of the patient, operator’s experience, previous cannulation and the presence of vascular anomalies [2].

Central venous access is usually accomplished through the internal jugular vein (IJV), external jugular vein

(EJV) or subclavian vein (SCV) via either percutaneous or cut down approach [3]. Variations in the venous vascular anatomy of the head and neck are well recognised [4] and can be of significant importance to decrease morbidities related to central venous access. Variations in the formation, course and termination of the EJV have been previously reported in the literature [4], yet there are no reports correlating these variations/anomalies and their clinical relevance in relation to CVC insertions. In 2013, the author has encountered difficulty inserting a CVC due to an unreported variation in the anatomy of the EJV where it branched into a bigger anterior branch not leading to the superior vena cava (SVC) and a smaller posterior branch leading to the SVC. The anterior branch followed the course of the main EJV unlike the posterior branch which was arising from the EJV at

Correspondence: [mshalaby@doctors.org.uk](mailto:mshalaby@doctors.org.uk)  
Department of Paediatric Surgery, Bristol Royal Hospital for Children, Bristol  
BS2 8BJ, UK

an acute angle above the clavicle. This made threading the catheter into the posterior branch quite challenging.

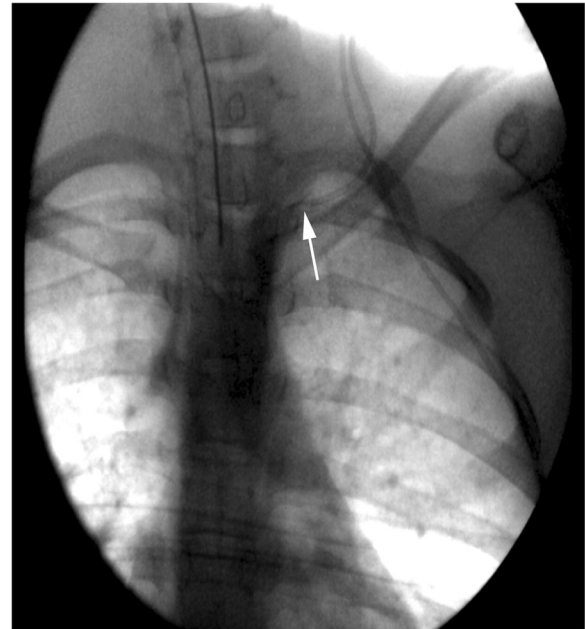
Since then, all CVCs inserted by the author have been prospectively recorded, especially in relation to EJV anatomy and its influence on the insertion of the CVCs. The aim of this work was to evaluate the anatomical variations in the EJV and their clinical relevance in relation to CVC insertion.

### Methods

All the CVC insertions performed by the author at the Royal Hospital for Sick Children, Glasgow, over the study period (February 2013–April 2014 inclusive) were prospectively recorded with special emphasis on the times the EJV was used. Recorded data included patient's demographics, the indication for CVC insertion, the vein used for central access, operative difficulties and any related anatomical variations with their influence on the CVC insertion. Collected data was analysed. No ethical approval was required for this study.

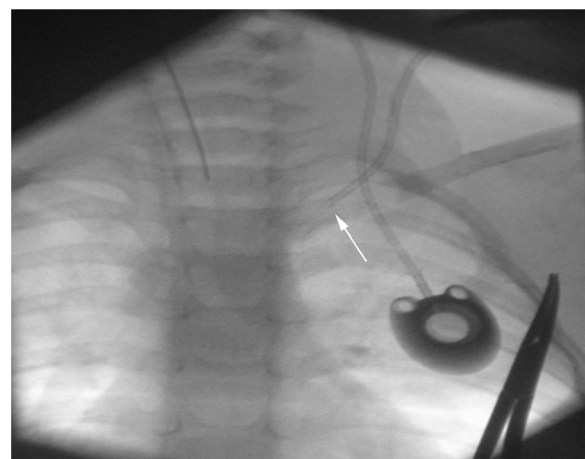
### Results

Over the 15-month study period, 36 CVCs were inserted, 17 (47%) were into the EJV. The choice of the vein to be used for CVC insertion depended on previous sites of cannulation and external visibility of the EJV. If the EJV had not been previously accessed and was externally visualised, then an open cut down approach over the vein 2 fingers breadth above the clavicle was utilised for insertion of the CVC. For the 17 EJV line insertions, the age ranged from 39 days to 14 years and 9 months. Nine lines were inserted into the right EJV and eight into the left EJV. The commonest indication for CVC insertion was malignancy in 59% of the cases. All CVCs were inserted under intra-operative fluoroscopic guidance. Operative difficulty was encountered in 4 patients (24%), all of whom the catheter was inserted easily into the EJV but failed to thread into a satisfactory position (superior vena cava/right atrium junction) despite manipulation of the head and the ipsilateral arm (Figs. 1 and 2). In all of the 4 patients, further dissection of the EJV inferiorly revealed branching of the EJV into a bigger anterior branch which follows the course of the main EJV (before it branches) and a smaller posterior branch arising above the clavicle at an acute angle. Further dissection at the site of the branching enabled passage of the catheter into the posterior branch in all the cases. Once the catheter was into the posterior branch of the EJV, it was threaded easily into a satisfactory position (superior vena cava/right atrium junction) (Fig. 3) in all the cases. Regarding the 4 cases of “the branching EJV”, the youngest patient was 2 years and 9 months old and the oldest was 14 years and 9 months. Three were males and one was a female. The used vein in three cases was the left EJV and in one the right EJV. In 2

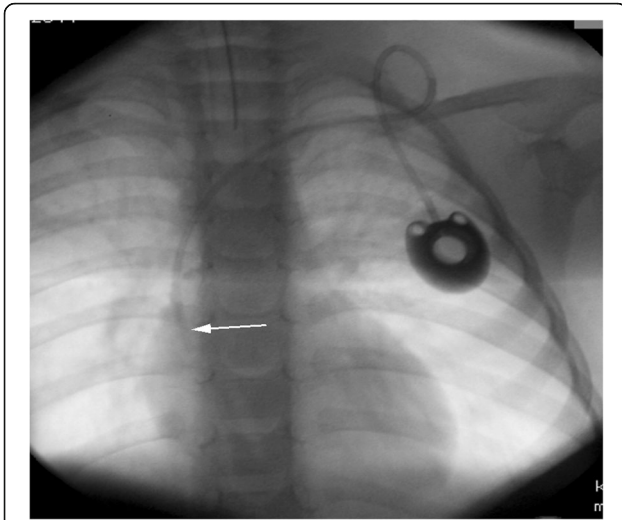


**Fig. 1** Patient 1 intra-operative fluoroscopic picture. CVC inserted into the anterior branch of the EJV which followed the same course of the main EJV (before branching) but failed to be threaded into the right atrium. The white arrow is pointing to the tip of the central venous line

cases, a port was inserted in patients with cystic fibrosis, and in the other 2 cases, a double-lumen tunnelled line was inserted for malignancy (neuroblastoma and lymphoma). The overall success rate for CVC insertion through the EJV in this study was 100% (17/17) including the 4 cases with “the branching EJV”.



**Fig. 2** Patient 2 intra-operative fluoroscopic picture. CVC inserted into the anterior branch of the EJV and failed to be threaded into the right atrium. The white arrow is pointing to the tip of the central venous line



**Fig. 3** Patient 2 intra-operative fluoroscopic picture. CVC inserted into the posterior branch of the EJV and was threaded easily towards the right atrium. The white arrow is pointing to the tip of the central venous line

## Discussion

Central venous catheterization is one of the most common procedures performed by physicians [5]. It allows intravenous infusion of TPN, chemotherapeutic agents and long-term antibiotics. It also facilitates blood withdrawal and haemodynamic monitoring [5]. The preferred initial access site for CVC insertion by most authors is the right IJV [6].

The majority of paediatric surgeons in the UK prefer the ultrasound-guided approach for insertion of CVCs, and this report is certainly not disputing that the ultrasound-guided approach is less invasive and should be the first option if the relevant experience is available. However nowadays, especially in children, there are more patients requiring multiple CVC insertions due to repeated complications such as catheter sepsis or malfunction and vein stenosis or thrombosis. It is therefore crucial to be aware of the various options for long-term central venous access [3]. The use of the EJV as an alternative route for central venous access is generally accepted both in adults [6, 7] and in children [8, 9]. The EJV is additionally used in patients undergoing transjugular liver biopsy [10].

Anatomically, the superficial temporal vein unites with the maxillary vein within the substance of the parotid gland to form the retromandibular vein which then divides into anterior and posterior branches. The facial vein joins the anterior branch to form the common facial vein which drains into the IJV. The posterior auricular vein unites with the posterior branch of the retromandibular vein to form the EJV. After its formation, the EJV runs vertically downwards in the superficial

fascia and crosses the sternomastoid muscle. It then pierces the deep cervical fascia just above the middle of the clavicle to drain into the SCV [4].

There have been a few reports illustrating variations in the formation or the termination of the EJV [4]. Vollala et al. reported variations in the formation of the EJV in 2 cadavers, one of whom the EJV was formed very low and in the other cadaver the EJV was formed by the union of the facial vein and an undivided retromandibular vein [11]. In 2 cadaveric studies examining the termination of the EJV, it was reported that the EJV mostly terminated in the jugulo-subclavian venous confluence (60% and 72%), followed by the SCV (36% and 26%), while rarely (4% and 2%) the EJV terminated into the IJV [12, 13]. There have been no reports on “the branching EJV” or its clinical relevance to CVC insertion. Similarly, there have been no reports in paediatric or adult patients correlating any variation in the anatomy of the EJV and its clinical relevance during CVC insertion.

The fact that “the branching EJV” has never been reported previously may be due to the preference of most surgeons and intensivists to use the percutaneous approach to the IJV, SCV or femoral vein using the Seldinger technique rather than the cut down technique on the EJV [9]. The percutaneous approach for the EJV has been described in children [8, 9] but is not yet popular among most paediatric surgeons. The preference of the author during the study period for insertion of CVCs in children, who are likely to need many central venous lines in the future, was to spare the IJV and the SCV if possible. Hence, for any child requiring CVC insertion, if the EJV is externally visualised and has not been previously accessed, then the open cut down approach through the EJV was the preferred technique. This has led to an increase in the number of procedures performed on the EJV (47% of the cases during the current study period). This together with awareness of the anatomical variations with the EJV led to recognition of “the branching EJV”.

In the current study, “the branching EJV” was noted in 24% of the cases with no predilection to the side of the vein, patient’s sex, age or clinical diagnosis. “The branching EJV” divided into a larger anterior branch that follows the course of the main EJV (before it branches) and a smaller posterior branch arising above the clavicle at an acute angle. This has led to the tendency of the CVC to follow the anterior rather than the posterior branch and hence the difficulty in placing the CVC in a satisfactory position. Figures 1 and 2 illustrate how the central line descended into the anterior branch, giving false impression that it is heading in the right direction. Various manoeuvres have been reported to be necessary for the successful insertion of CVCs into the EJV in 50% of the children [9]. These manoeuvres include careful twisting

of the head to the side of the vein and exerting downward traction on the ipsilateral arm and shoulder [9]. Although we appreciate the usefulness of these manoeuvres in the insertion of the EJV CVCs, yet in all the cases of “the branching EJV”, it was of no help as the catheter always threaded into the anterior branch that was not leading to the right atrium. The key for successful insertion in these cases is identifying the posterior branch of the EJV (that always arises above the clavicle at an acute angle) and manipulating the line so that it passes into the posterior rather than the anterior branch of the EJV. Once the central line is in the posterior branch, it follows its course easily into the right atrium.

The overall success rate of percutaneous CVC insertion in children via the EJV is suboptimal, with Humphrey et al. [14] reporting an overall success rate of 59% in children with visible EJV. Romão et al. [9] reported an improved success rate (78.8%) with body manoeuvres required in half of the successful children. The current study although small yet represents the highest reported success rate with CVC insertions through the EJV in children (100%). We believe that this is due to the use of the open cut down approach that allowed the identification of “the branching EJV”. It is obviously more difficult to identify “the branching EJV” and negotiate the catheter in the posterior branch using the percutaneous approach.

## Conclusion

This is the first report describing “the branching EJV” and its clinical relevance to CVC insertion. The EJV can be safely and efficiently used to acquire central venous access even in infants. When using the percutaneous approach to the EJV, if it failed to achieve satisfactory central venous access, then the open cut down approach over the EJV, identifying and dissecting “the branching EJV” followed by threading the CVC into the posterior branch, can significantly improve the success rate.

## Abbreviations

CVC: Central venous catheter; EJV: External jugular vein; RA: Right atrium; IJV: Internal jugular vein; SCV: Subclavian vein

## Acknowledgements

MSS would like to thank Ms May Al-Husseiny for proofreading the manuscript.

## Author's contributions

MSS is the corresponding and only author. Study design, manuscript writing, editing and review of the literature was done by MSS. The author(s) read and approved the final manuscript.

## Funding

This research received no specific grant from any funding agency in the public, commercial or not-for-profit sectors.

## Availability of data and materials

Not applicable.

## Ethics approval and consent to participate

Not required.

## Consent for publication

Not applicable.

## Competing interests

No competing interests.

Received: 12 August 2020 Accepted: 10 November 2020

Published online: 30 November 2020

## References

1. Wells JM, Arul S. Venous access in children. *Surgery*. 2010;28:377–81.
2. Grebenik CR, Boyce A, Sinclair ME, et al. NICE guidelines for central venous catheterization in children. Is the evidence base sufficient? *Br J Anaesth*. 2004;92:827–30.
3. Juno RJ, Knott AW, Racadio J, et al. Reoperative venous access. *Semin Pediatr Surg*. 2003;12:132–9.
4. Shenoy V, Saraswathi P, Raghunath G, et al. Double external jugular vein and other rare venous variations of the head and neck. *Singapore Med J*. 2012;53:e251.
5. Rajaram SS, Dellinger RP. Positioning for central venous access. *Semin Anaesth*. 2005;24:211–3.
6. Cho SK, Shin SW, Do YS, et al. Use of the right external jugular vein as the preferred access site when the right internal jugular vein is not usable. *J Vasc Interv Radiol*. 2006;17:823–9.
7. Costantino TG, Kirtz JF, Satz WA. Ultrasound-guided peripheral venous access vs. the external jugular vein as the initial approach to the patient with difficult vascular access. *J Emerg Med*. 2010;39:462–7.
8. Cruzeiro PCF, Camargos PAM, Tatsuo ES, et al. Percutaneous central venous catheterization through the external jugular vein in children: is inserting the guide wire into the superior vena cava essential for successful catheterization? *J Pediatr Surg*. 2012;47:1742–7.
9. Romão RLP, Valinetti E, Tannuri ACA, et al. Percutaneous central venous catheterization through the external jugular vein in children: improved success rate with body maneuvers and fluoroscopy assistance. *J Pediatr Surg*. 2008;43:1280–3.
10. Vadgaonkar R, Rai R, Ranade AV, et al. An anomalous left external jugular vein draining into right subclavian vein. *Bratisl Lek Listy*. 2008;109:461–2.
11. Vollala VR, Bolla SR, Pamidi N. Important vascular anomalies of face and neck – a cadaveric study with clinical implications. *Firat Tip Dergisi*. 2008;13:123–6.
12. Deslaugiers B, Vaysse P, Combes JM, et al. Contribution to the study of the tributaries and the termination of the external jugular vein. *Surg Radiol Anat*. 1994;16:173–7.
13. Kopuz C, Akan H. The importance of the angulation and termination of external jugular vein in central venous catheterization in newborn. *Okajimas Folia Anat Jpn*. 1996;73:155–9.
14. Humphrey MJ, Blitt CD. Central venous access in children via the external jugular vein. *Anesthesiology*. 1982;57:50–1.

## Publisher's Note

Springer Nature remains neutral with regard to jurisdictional claims in published maps and institutional affiliations.