

ORIGINAL RESEARCH

Open Access



# Laparoscopic two-port pre-tied peritoneal dialysis catheter insertion in children: a simple modification

Nasir Bustangi<sup>1</sup> and Mohammad Gharieb Khirallah<sup>2\*</sup>

## Abstract

**Background:** Different laparoscopic approaches for insertion of a peritoneal dialysis catheter (PDC) have been adopted. Most of these techniques require 2–3 ports. One port laparoscopic technique for PDC placement was introduced by some authors to minimize potential complications. The main drawback of these techniques was the inadequate position of catheter tip and hence affecting its efficacy.

The purpose of this study is to evaluate a simple modified laparoscopic technique during insertion of PDC.

**Results:** The mean age of these patients was  $6 \pm 4.1$  years. There were 11 females. The mean body weight was  $13 \pm 3.3$  kg. The mean operative time was 35.5 min. No operative complications occurred. Two cases had catheter obstruction. Wound infection developed in three cases. Mean follow-up period was  $11 \pm 5.3$  months

**Conclusions:** Laparoscopic insertion of PDC in children suffering end-stage renal disease using a pre-tied catheter tip with V-loc/STRATAFIX<sup>®</sup> size 3/0 suture and two-port-only technique was associated with shorter operative time and longer life of catheter without migration or catheter malfunction.

**Keywords:** Peritoneal, Dialysis, Laparoscopic, Catheters, Children

## Background

Since it has been introduced in 1959, peritoneal dialysis (PD) gained a lot of acceptance because it is utilized as a home therapy, affording greater patient autonomy and quality of life than in-center hemodialysis [1, 2].

There are no randomized controlled trials comparing the two modalities; however, PD may be favored in patients with vascular access failure, intolerance to hemodialysis, congestive heart failure, long distance from dialysis center, and peripheral vascular disease and bleeding diathesis. PD may also be preferred by patients with the possibility of renal transplantation soon, needle anxiety, and active lifestyle [3].

Over the last years, laparoscopic insertion of peritoneal dialysis catheter (PDC) in children gained popularity.

However, it is not free of challenges as some series described a high rate of complications approaching about 70% of cases. Laparoscopic insertion of PDC has many advantages, as a thorough exploration of the peritoneal cavity, optimal catheter tip position, and associated with lower incidence of adhesive complications [4].

Laparoscopic insertion of PDC was first described in the early 1990s, and the safety and feasibility of various laparoscopic insertion techniques in both adults and children have been documented in many case reports, retrospective reviews, and comparative studies [5–8].

The aim of this study is to evaluate a novel simple modified laparoscopic approach using two ports for PDC placement.

## Methods

This study is a retrospective file review. The records of all cases referred from pediatric nephrology unit to pediatric surgery unit for PDC insertion in the period

\* Correspondence: [Mohamed.khirallah@med.tanta.edu.eg](mailto:Mohamed.khirallah@med.tanta.edu.eg)

<sup>2</sup>Department of Pediatric Surgery, Tanta University, El Geish street, Tanta, Egypt

Full list of author information is available at the end of the article

from 2017 to 2019 were reviewed. The files of patients who had laparoscopic insertion of PDC were retrieved. Special charts were designed to retrieve the following data from the records: safety and feasibility of technique, operative time, any accidental iatrogenic injuries during procedure, durability of catheter function, and any post-operative complications.

Exclusion criteria were patient in the neonatal period, PDC inserted by conventional open method, cases with previous abdominal operation, obese children that may have redundant omentum that may obstruct tube, patients with hemodynamic instability, and patients with severe respiratory or cardiac comorbidity.

## Results

The retrospective study included 17 children with end-stage renal disease who had laparoscopic insertion of PDC. There were 11 females and 6 males. The mean body weight was  $13 \pm 3.3$  kg. The mean age of patients was  $6 \pm 4.1$  years (Table 1).

### Operative technique

PD Tenckhoff straight catheter with two cuffs was used in all patients. Under general anesthesia, the patient was placed in a supine position; trans-umbilical open technique was used to insert the first 5 mm optic port. This was followed up by the creation of pneumoperitoneum. Hand tying V-loc/STRATAFIX<sup>®</sup> size 3/0 suture over the catheter tip was performed on a table (Fig. 1).

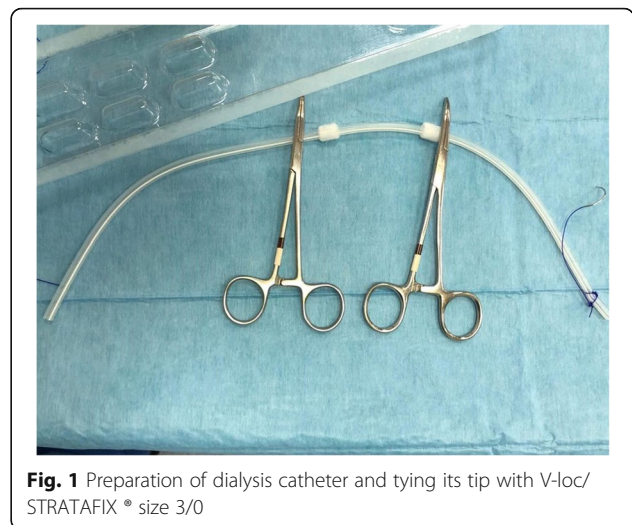
Another 5 mm port was inserted in midclavicular line at the level of umbilicus. Small incision left to the umbilicus to enter the catheter was carried out (Fig. 2).

The prepared suture was held by small mosquito forceps near to the needle, and then introduced carefully under vision through lift small incision (Fig. 3). A grasper forceps was used from the right port to pull the suture with the catheter gently. Then, the catheter tip was fixed and sutured to the peritoneal reflection of Douglas pouch in girls and in the rectovesical space in boys with blocked fashion (Fig. 4).

The catheter tip placement and the positioning of the first cuff were adequately placed, narrowing with suture around the first cuff and then subcutaneous tunneling to get the catheter out (Fig. 2). Testing of the catheter was done and we properly secured closure of all the openings.

**Table 1** Preoperative and demographic data

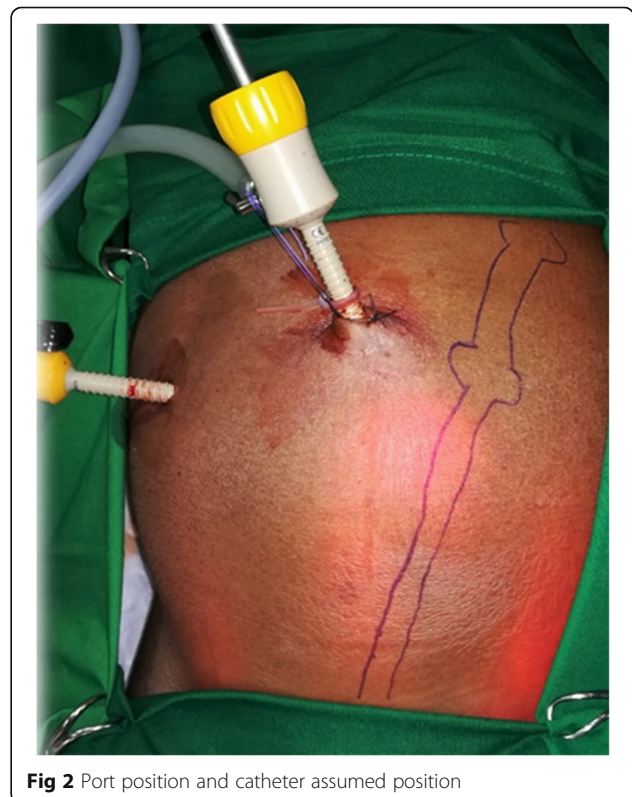Variables	
<b>Preoperative data</b>	
Age (mean in years $\pm$ SD)	$6 \pm 4.1$
Sex (male/female)	6/11
Body weight (mean in Kg $\pm$ SD)	$13 \pm 3.3$



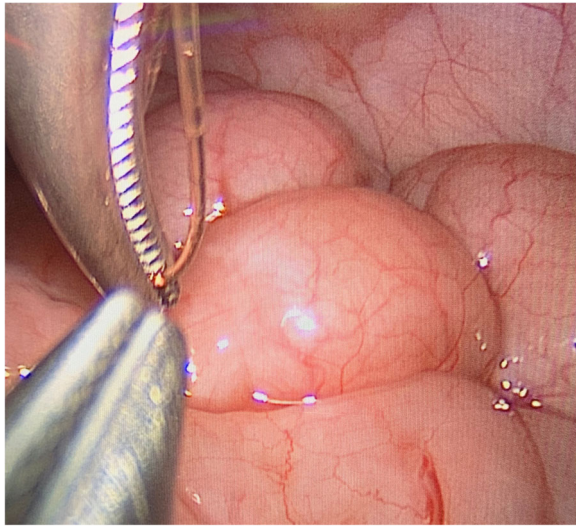
**Fig. 1** Preparation of dialysis catheter and tying its tip with V-loc/STRATAFIX<sup>®</sup> size 3/0

### Operative and post-operative (Table 2)

The procedure was completed in all cases without the need for conventional technique. No cases had omentectomy. The mean operative time was  $35 \pm 10.5$  min. No injury of any peritoneal organs occurred. Wound infection developed in three cases. These children responded to local antibiotics dressings. Obstruction of catheter occurred in 2 cases and a redo was decided by laparoscopy. In the first case, obstruction was due to wrapping of the fallopian tube around the catheter (Fig. 5).



**Fig 2** Port position and catheter assumed position



**Fig. 3** Introduction of catheter tip into peritoneal cavity

In the second case, obstruction was due to fibrinous debris. Repositioning of the tip was just enough to overcome the obstruction. No cases had peritonitis. The mean period of follow-up of these catheters was  $11 \pm 5.3$  months.

Two weeks after the procedure, PD starts.

## Discussion

Different techniques for laparoscopic placement of PDC have been described. Most of these techniques have equal or fewer perioperative complications when compared to conventional placement techniques. On the other hand, laparoscopic approaches had the benefits of

easier method, shorter hospital stay, and earlier use of dialysis [9, 10].

One of the most important advantages of laparoscopy in these cases is to reduce the incidence of catheter dysfunction. This may happen due to compartmentalization from adhesions, catheter tip migration into the upper abdomen, and omental wrapping or entrapment following conventional surgery [11].

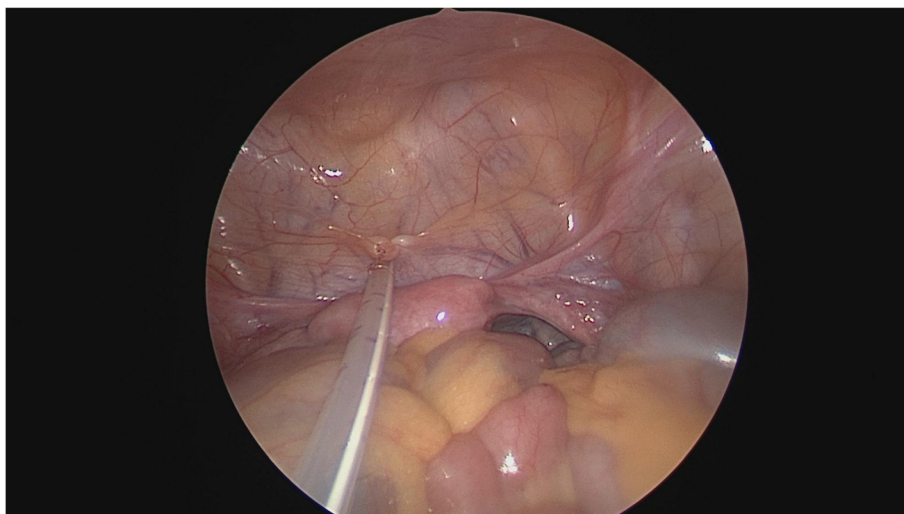
In the current study, the mean operative time was  $35 \pm 10.5$  min. The preparation of catheter with V-loc/STRATAFIX™ effectively helped reducing the operative time.

Copeland and his team demonstrated that operative time in their laparoscopic group was  $47 \pm 16.8$  min. They used conventional three-port technique [12].

In order to decrease the incidence of catheter dysfunction, many surgical techniques are utilized; these include omentopexy, omentectomy, rectus sheet tunneling, and suture fixation [13–16].

In this study, we performed suture fixation in all cases. Although omental adhesion to PDC is an important cause of obstruction and failure in about 26 to 36% of cases in some literature [17, 18], recent researches are not strong enough to recommend this step as mandatory.

Lack of evidence of omentectomy among surgeons made worldwide controversy [14, 19]. Omentectomy was not performed in any child. The authors believe that omentum, especially in young children, is not well developed and on the other hand if peritonitis should occur due to catheter position, it may help in localizing the infection. Catheter dysfunction due to obstruction occurred only 11.7% in all cases. However, the causes of obstruction were either wrapping of the fallopian tube or fibrinous debris.



**Fig. 4** Fixation of catheter tip at pelvis of child

**Table 2** Operative and postoperative data

Variable	
<b>Operative</b>	
Operative time (mean in min ± SD)	35 ± 10.5
Bleeding	No cases
Visceral injury	No cases
<b>Early postoperative complications</b>	
Leak	No cases
Malfunction	2 cases
Wound infection	3 cases
Peritonitis	No cases
<b>Late postoperative complication</b>	
<b>Catheter tip migration</b>	No cases
<b>Port site hernia</b>	No cases
<b>Development of inguinal or other abdominal wall defects hernia</b>	No cases
<b>Follow-up periods (mean in months ± SD)</b>	11 ± 5.3 months

In this study, we added vancomycin to cephalosporin as chemoprophylaxis against post-operative peritonitis, based on the current clinical practice guidelines from the International Society of Peritoneal Dialysis [20].

One of the most common causes of PDC malfunction is migration. It is important to secure the catheter tip in position with sutures. In the attempt of Copeland and his team to avoid tip malposition or migration, they performed a suprapubic incision down to the subcutaneous tissue and used facial closure device to place the suture around the tip of the catheter securing and directing it into pelvis. They also recommended the use of nonabsorbable suture material to prolong catheter duration in us [12].

Also, Waston and his team had found during their study that only one case had long-term tip migration

from 19 patients in whom catheter was secured by suture in pelvis [21].

In the same context, Soontrapornchia and his colleagues documented long duration before catheter migration if it was secured in the pelvis, but this fixation had no role on its survival [22].

In the current study, no cases were reported to have migration of the tip away from its fixing point. This was mainly owing to the pre-tied tip which was secured at the pelvis of the child.

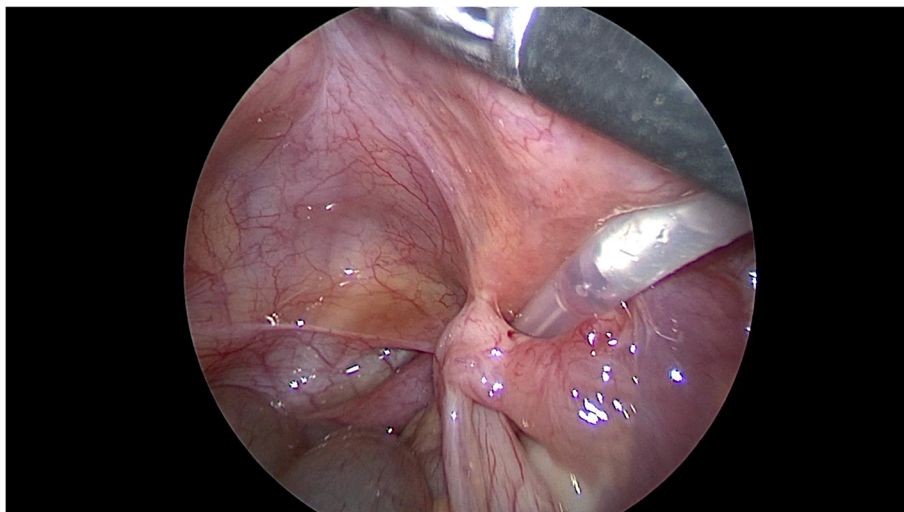
Wong reported two cases out of thirty-three cases in his cohort that had abnormal position of the tip of catheter. They assumed that the cause was abnormal torque at the cuff at facial defect. To overcome this trouble, they made purse string suture securing catheter cuff [23].

In addition to securing catheter deep in pelvis, the authors documented the feasibility of using only two-port technique instead of conventional three-port technique.

The authors believed that one of the main limitations of their study is that it was a retrospective study. Also, the limitation to the number of cases and the absence of control groups made some limitations to the study.

## Conclusion

Laparoscopic insertion of PDC in children suffering end-stage renal disease using a pre-tied catheter tip with V-loc/STRATAFIX<sup>®</sup> size 3/0 suture and two-port-only technique was associated with shorter operative time and longer life of catheter without migration or catheter malfunction. A prospective randomized control study is required to standardize this technique to conventional laparoscopic approach.



**Fig. 5** Wrapping of tube by right fallopian tube

**Abbreviations**

PD: Peritoneal dialysis; PDC: Peritoneal dialysis catheter

**Acknowledgements**

None

**Authors' contributions**

All authors contributed equally in the writing of this manuscript. M KH contributed specifically in patients' selection, partitioning, and operative technique. NB participated mainly in the study designing, and the operative technique. All authors have read and approved the manuscript and ensure that this is the case.

**Funding**

None

**Availability of data and materials**

The datasets used and/or analyzed during the current study are available from the corresponding author on reasonable request.

**Ethics approval and consent to participate**

Approval was obtained from the Research Ethics Committee at our faculty of medicine with approval code 2977/12/14. Parents of each patient were informed about all the steps in the procedure.

A written consent was obtained from the study participants.

**Consent for publication**

Agree to consent for publication

**Competing interests**

None.

**Author details**

<sup>1</sup>Division of Pediatric Surgery, King Abdul-Aziz University Hospital, Jeddah, Saudi Arabia. <sup>2</sup>Department of Pediatric Surgery, Tanta University, El Geish street, Tanta, Egypt.

Received: 2 June 2020 Accepted: 1 September 2020

Published online: 05 November 2020

**References**

- Maxwell MH, Rockney RE, Kleeman CR, Twiss MR. Peritoneal dialysis. Technique and applications. *J Am Med Assoc.* 1959;170:917–24.
- Juergensen E, Wuertth D, Finkelstein SH, Juergensen PH, Bekui A, Finkelstein FO. Hemodialysis and peritoneal dialysis: patients' assessment of their satisfaction with therapy and the impact of the therapy on their lives. *Clin J Am Soc Nephrol.* 2006;1:1191–6.
- Shetty AOG. Peritoneal dialysis: its indications and contraindications. *Dialysis Transplant.* 2000;29:71–7.
- Hauch AT, Lundberg PW, Paramesh AS. Laparoscopic techniques enable peritoneal dialysis in the difficult abdomen. *JSLs.* 2014;18(4):e2014.002334.
- Tenckhoff H, Schechter H. A bacteriologically safe peritoneal access device. *Trans Am Soc Artif Intern Organs.* 1968;14:181–7.
- Maya ID. Ultrasound/fluoroscopy-assisted placement of peritoneal dialysis catheters. *Semin Dial.* 2007;20:611–5.
- Brewer TE, Caldwell FT, Patterson RM, Flanigan WJ. Indwelling peritoneal (Tenckhoff) dialysis catheter. Experience with 24 patients. *JAMA.* 1972;219:1011–5.
- Ash SR. Placement of the Tenckhoff peritoneal dialysis catheter under peritoneoscopic visualization. *Dialysis Transplant.* 1981;10:82–6.
- Lu CT, Watson DJ, Elias TJ, Faull RJ, Clarkson AR, Bannister KM. Laparoscopic placement of peritoneal dialysis catheters: 7 years' experience. *ANZ J Surg.* 2003;73:109.
- Dalgic A, Ersoy E, Anderson M, Lewis J, Engin A, D'Alessandro AM. A novel minimally invasive technique for insertion of peritoneal dialysis catheter. *Surg Laparosc Endosc Percutan Tech.* 2002;12:252–4.
- Bannister KM, Watson DJ, Pearce T, Paterson D. Clinical and cost benefits of laparoscopic Tenckhoff catheter insertion for continuous ambulatory peritoneal dialysis. *Kidney Int.* 1997;51:1328.
- Copeland DR, Blaszkak RT, Tolleson JS, Saad DF, Jackson RJ, Smith SD, Kokoska ER. Laparoscopic Tenckhoff catheter placement in children using

- securing suture in pelvis: comparison to an open approach. *J Pediatr Surg.* 2008;43:2256–9.
- McIntosh G, Hurst PA, Young AE. The 'omental hitch' for the prevention of obstruction to peritoneal dialysis catheters. *Br J Surg.* 1985;72:880.
- Phan J, Stanford S, Zaritsky JJ, DeUgarte DA. Risk factors for morbidity and mortality in pediatric patients with peritoneal dialysis catheters. *J Pediatr Surg.* 2013;48:197–202.
- Attaluri V, Lebeis C, Brethauer S, Rosenblatt S. Advanced laparoscopic techniques significantly improve function of peritoneal dialysis catheters. *J Am Coll Surg.* 2010;211:699–704.
- Ko J, Ra W, Bae T, Lee T, Kim HH, Han HS. Two-port laparoscopic placement of a peritoneal dialysis catheter with abdominal wall fixation. *Surg Today.* 2009;39:356–8.
- Ladd AP, Breckler FD, Novotny NM. Impact of primary omentectomy on longevity of peritoneal dialysis catheters in children. *Am J Surg.* 2011;201(3):401–4.
- Esposito F, Di Serafino M, Ambrosio C, et al. Chronic peritoneal dialysis in children: the role of ultrasound in the diagnosis of peritoneal catheter obstruction. *J Ultrasound.* 2016;19:191–6.
- Lemoine C, Keswani M, Superina R. Factors associated with early peritoneal dialysis catheter malfunction. *J Pediatr Surg.* 2019;54:1069–75.
- Figueiredo A, Goh BL, Jenkins S, Johnson DW, Mactier R, Ramalakshmi S, Shrestha B, Struijk D, Wilkie M. Clinical practice guidelines for peritoneal access. *Perit Dial Int.* 2010;30:424–9.
- Watson DJ, Paterson D, Bannister K. Secure placement of peritoneal dialysis catheters using a laparoscopic technique. *Surg Laparosc Endosc.* 1996;6(1):35–7.
- Soontrapornchai P, Simapatanapong T. Comparison of open and laparoscopic secure placement of peritoneal dialysis catheters. *Surg Endosc.* 2005;19(1):137–9.
- Wong YS, Pang KKY, Ma ALT, Tong PC, Tam YH. A standardized technique of laparoscopic placement of peritoneal dialysis catheter with omentectomy and closure of patent processus vaginalis: a 3-in-1 minimally invasive surgical approach. *J Pediatr Surg.* 2019; in press. <https://doi.org/10.1016/j.jpedsurg.2019.09.033>.

**Publisher's Note**

Springer Nature remains neutral with regard to jurisdictional claims in published maps and institutional affiliations.

**Submit your manuscript to a SpringerOpen® journal and benefit from:**

- Convenient online submission
- Rigorous peer review
- Open access: articles freely available online
- High visibility within the field
- Retaining the copyright to your article

Submit your next manuscript at ► [springeropen.com](https://www.springeropen.com)