

RESEARCH

Open Access



Vertebroplasty in geriatric patients with osteoporotic vertebral fractures: single-center cohort study at a level 1 center for spinal surgery

Mohammed Banat* , Gregor Bara, Abdallah Salemdawod, Shaleen Rana, Motaz Hamed, Jasmin Scorzin and Hartmut Vatter

Abstract

Study design: Retrospective single-center cohort study.

Background: The spine is the most common anatomic site for osteoporotic fractures. Osteoporotic vertebral fractures play an increasingly important role in geriatric patients and percutaneous vertebroplasty (PVP) constitutes a common treatment option. The aim of this study was to evaluate the safety and efficacy of PVP in geriatric patients with cardiovascular comorbidities at our center.

Methods: In this retrospective single-center study, 49 patients aged ≥ 65 with a total of 88 vertebral fractures underwent vertebroplasty. MRI and CT scans of the spine were performed in all patients prior to surgery. All patients were evaluated 4 weeks after surgery as part of their clinical follow-up. VAS scores were recorded before and after the operation. Postoperative complications within 30 days of the initial surgery were analyzed.

Results: The mean age of patients was 77 years (± 6.4). Of the 49 patients, 39 (80%) were female, and 36 (76%) had cardiovascular comorbidities. The most frequent postoperative complications were cement leakage with no new neurological postoperative deficits (14.3%). The in-hospital mortality rate was 1 out of 49 patients (2%). VAS scores revealed an overall pain reduction of $> 97\%$. None of the following affected patient safety: ASA, BMI, duration of surgery, or the level or localization of vertebroplasty.

Conclusions: Our data demonstrate that vertebroplasty was a feasible and effective treatment for pain reduction in geriatric patients with osteoporotic fractures despite cardiovascular comorbidities.

Level of evidence: 3.

Keywords: Osteoporotic vertebral fracture, Geriatric patients, Vertebroplasty complication, Cardiovascular comorbidities

Background

The spine is the most common anatomic site for osteoporotic fractures. The incidence of osteoporotic vertebral compression fractures in the aging population is increasing worldwide and becoming a major healthcare issue [1, 2]. Unlike peripheral fractures, osteoporotic vertebral fractures (OVF) often cause nonspecific symptoms and the risk of further fractures increases by a factor of up

*Correspondence: mohammed.banat@ukbonn.de

Department of Neurosurgery, University Hospital Bonn, Venusberg-Campus 1, Building 81, 53127 Bonn, Germany

to 7.3 [3–5]. Symptomatic OVF were previously treated conservatively to reduce pain through immobilization [6]. Now, however, percutaneous vertebroplasty (PVP) is widely used as a minimally invasive procedure to treat pain from vertebral fractures with different pathologies—osteoporotic, traumatic, or neoplastic [7–11]. Many studies [12, 13] have addressed the indications for PVP, its success, and its complications, but rarely within the geriatric subgroup and considering other factors such as cardiovascular comorbidities.

The aim of this study was to evaluate the safety and efficacy of PVP in geriatric patients with cardiovascular comorbidities at our center.

Methods

Patient selection and inclusion criteria

In this retrospective single-center cohort study, we analyzed data on all patients with OVF aged ≥ 65 years who were surgically treated with PVP at our spine center between January 2017 and December 2020. Patients' clinical information was registered and documented, including age, sex, BMI, duration of surgery, ASA score, fracture location, number of fractured vertebrae, kyphosis angle, history of cardiovascular comorbidities, surgery-related complications, and in-hospital complications.

The inclusion criteria were subacute osteoporotic fracture. The indication for PVP was increasing treatment-refractory pain after osteoporotic fracture. The diagnosis of OVF was performed according to the Osteoporosis International algorithm (2020) [14]. Radiological imaging [15] of the spine was undertaken before surgery with CT and MRI with short tau inversion recovery (STIR) sequences for edema at the vertebra (Fig. 1).

Postoperative surgery-related and in-hospital complications were defined as any adverse events occurring within 30 days of the initial surgery.

Patients underwent standardized preoperative clinical, MRI, and CT examinations. VAS scores and the kyphosis angle were recorded both pre- and post-operatively. A CT scan was routinely performed after the PVP surgery. Clinical follow-up examinations were undertaken 1 month after surgery. For more comprehensive clinical and radiological data, we evaluated the EQ-5D, a measure of health-related quality of life from the EuroQol Group, and the compression index of fractured vertebra (using the Orbis® OpenMed health information system) [16, 17].

Patients with tumor fractures, other pathologies such as traumatic fractures, and acute OVF less than 3 weeks old were excluded; we also excluded all patients whose history of comorbidities was unknown.

Sugita et al. [18] described a prognostic classification system for osteoporotic vertebral fractures with 5 subtypes. Our cohort with fracture subtypes 2–4 was treated with PVP, and patients with subtype 5 were treated with augmented dorsal fixation with screws and dorsal decompression because of spinal stenosis and a high kyphosis angle.

The study was approved by the local ethics committee of our institution (reference no. 067/21). Patient approval to publish data is not required, because these data are collected as standard in our clinic, and therefore consent for retrospective data is not necessary. This retrospective data analysis complies with the applicable local and international guidelines for data protection and carrying out scientific studies. This manuscript does not contain any patient-sensitive data or images that require approval for publication.

This cohort study has been reported in line with the PROCESS Guideline [19].

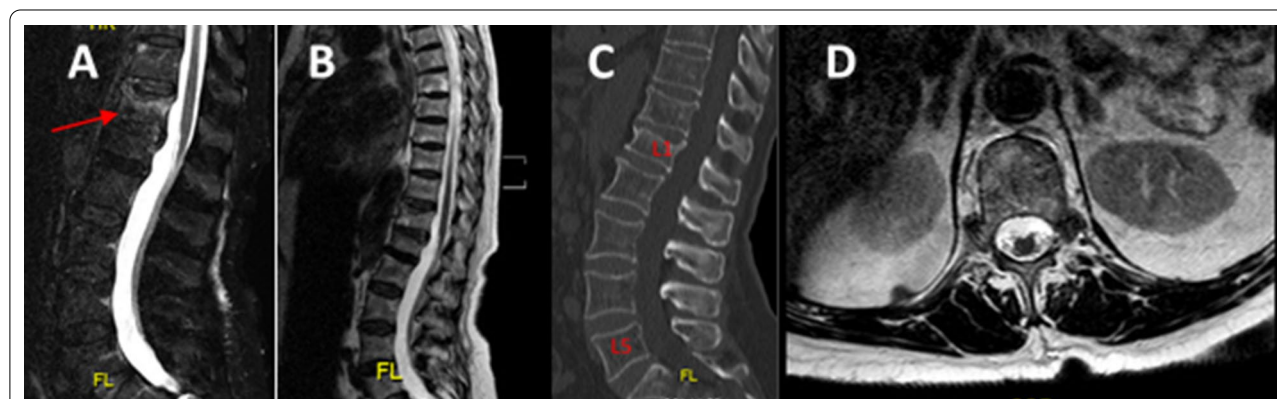


Fig. 1 Indication for surgery. 79 y/o female with osteoporotic L1 vertebral fracture. **A** MRI STIR sagittal sequence, **B** T2-sagittal sequence, **C** CT scan, and **D** axial sequence of L1 without spinal stenosis

Surgical procedure

The surgical procedure generally involved anesthesia, and all the procedures followed the same process. Patients were placed in a prone position. We routinely used a radiolucent table with a gel mattress. A posterior surgical approach was taken at the level of the segments to be operated on. Prior to the skull incision, an X-ray was performed to verify the region of interest by 2D fluoroscopy. Jamshidi needles for later cement application were inserted by using the fluoroscopy in anterior posterior and lateral projections. After the pedicle was perforated, a contrast medium was injected to confirm that the pedicle had not been breached and to verify the correct localization of the Jamshidi needles. Finally, the cement was applied (bi-pedicular approach). The volume of cement injected was usually around 1.5–2 mL/side, but this was not mandatory. To eliminate as much as possible bias due to the skill or experience of the surgeon, operations were performed by only three neurosurgeons in our department.

Postoperative management

Patients received early postoperative mobilization with physiotherapy. A postoperative CT scan was conducted on the day of surgery [20].

Statistics

All data were analyzed using IBM® SPSS® Statistics V22.0 (IBM, Chicago, Illinois, USA). Quantitative, normally distributed data are presented as mean values \pm standard deviation (SD), while non-parametric data are summarized by median values [first quartile–third quartile]. In the case of categorical variables, data are given as numbers and percentages. After normality testing via the Shapiro–Wilk test, continuous normally distributed data were compared using t-tests, while the Mann–Whitney U test was used for non-parametric data. Nominal data were tested between groups using Fisher's exact test and in case of multinomial data with a Chi-square test. Correlation analysis was carried out using Spearman's correlation coefficient. The Wilcoxon test was used to compare VAS profiles. *p* values < 0.05 were considered statistically significant.

Results

Patient characteristics

A total of 49 patients aged ≥ 65 years with a total of 88 osteoporotic vertebral fractures were surgically treated with PVP at our center. Table 1 shows the baseline data.

Table 1 Baseline data

Total (n = 49)	No. patients	Percentage
Gender		
Female	39	79.5
Male	10	20.5
ASA		
ASA ₁₋₂	18	36.7
ASA ₃₋₄	31	63.3
BMI, kg/m ² [IQR]	28 [25–29]	
Age, yrs. (mean \pm SD)	77 \pm 6.4	
Duration of operation in minutes [IQR]	45.0 [32.0–65.5]	
Cardiovascular comorbidities	36	73.5%
Kyphosis angle (degrees) [IQR]		
Pre PVP	12.9 [12–16]	
After PVP	11.2 [10.2–13.7]	
VAS [IQR]		
Pre-surgery	8 [7–10]	
Directly after surgery	4 [3–5]	
4 weeks later	4 [3, 4]	
Surgical complications	7	
Neurological deficit	0	0
Cement leakage	7	14.2
PE	1	2
Vertebroplasty localization		
Thoracic	18	36.7
Lumbar	25	51.0
Thoracic and lumbar	6	12.3
Vertebroplasty level		
1 level	31	63
2 levels	11	22
3 levels and more	7	15
In-hospital complications		
Pneumonia	1	2
UTI	3	6
Mortality	1	2
Length of stay in days [IQR]	9 [6–12]	

ASA American Society of Anesthesiology, BMI body mass index, IQR interquartile range, PE pulmonary embolism, PVP percutaneous vertebroplasty, SD standard deviation, UTI urinary tract infection, VAS Visual Analog Scale for pain, yrs years

Postoperative complications

The most relevant postoperative complication was cement extravasation (intra- or para-spinal) with no new neurological postoperative deficits, which occurred in seven out of 49 patients (14%) (Fig. 2). There was one case of pulmonary cement embolism (2%).

Further postoperative in-hospital adverse events consisted of urinary tract infections (6%) and pneumonia (2%). One patient died 2 days after the operation due to

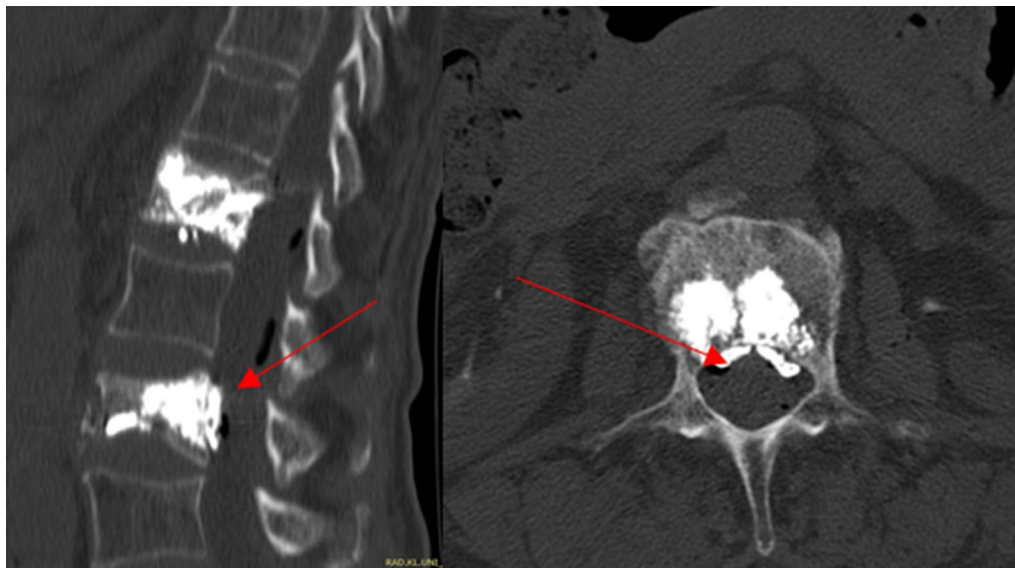


Fig. 2 Postoperative CT scan showing complications consisting of cement extravasation (intraspinal) without neurological deficit

a myocardial infarction with cardiopulmonary resuscitation (Table 1).

Patient-related factors influencing postoperative complications

Influence of clinical admission status

Patients suffering from postoperative complications following PVP exhibited similar values for ASA, BMI, and age; there were no significant variations. Female patients exhibited postoperative complications significantly more often than males: while 7 out of 27 female patients suffered from adverse postoperative events, there were no complications in the male group (Table 2).

Influence of patients' comorbidities, duration of surgery, level/localization of OVF, and length of stay

Patients with arterial hypertension, coronary artery disease, atrial fibrillation, diabetes mellitus, or a history of pulmonary embolism or deep vein thrombosis were not significantly affected by postoperative complications (Table 2). Furthermore, patients with more than one OVF (Fig. 3) did not exhibit elevated levels or localization of postoperative complications compared to patients with a single OVF ($p = 0.834$) (Table 2). There was no significant difference in the duration of surgery, or length of stay.

Effect of VAS score, EQ-5D, kyphosis angle, and compression index

The patients in our group recorded a significant improvement of at least 97% in their VAS scores, and this improvement was maintained at the 4 weeks clinical

follow-up; additionally, the patients reported a better quality of life. Seven patients were lost to follow-up.

A moderate kyphosis angle reduction of at least one degree was also seen in the post-surgery CT scans. After vertebroplasty, the compression index improved by 3–10% (Fig. 4).

Discussion

Osteoporosis is one of the most common diseases in geriatric patients and the number of osteoporotic vertebral fractures is increasing [4, 5]. This fact confronts the treating surgeons with a medical and moral question as to how far vertebroplasty can be offered as a treatment option [6, 7]. Two studies with randomized controlled trials compared the pain-relief benefit of PVP and non-surgical management. These two studies, by Buchbinder et al. [12] and Kallmes et al. [13], came to opposing conclusions—Buchbinder found no benefit of PVP, whereas Kallmes described a trend toward a higher rate of clinically meaningful improvement in pain after PVP.

This study evaluates the usefulness of vertebroplasty in geriatric patients and in this cohort focuses specifically on postoperative complications and the influence of comorbidities on these complications.

Cement leakage is known to be the most common complication following PVP and has been reported in about 30% to 65% of patients with osteoporotic vertebral fractures [21, 22]. This finding has important clinical implications. Despite generally showing no clinical symptoms, there seems to be a considerable incidence of cement extravasation that can occasionally result

Table 2 Patient-related factors influencing complications after PV

Total (n = 49)	No postoperative complications	Postoperative complications	p value
No. of patients	42	7	
Age, yrs. (mean ± SD)	77 ± 6.1	79 ± 8.2	0.376
Gender			0.179
Female	32 (76.2%)	7 (100%)	
Male	10 (23.8%)	0 (0.0%)	
BMI, kg/m ²			
Median [IQR]	28 [25–29]	28 [25–29]	0.818
ASA score			
Median [IQR]	3 [2, 3]	3 [2, 3]	0.590
VAS, median [IQR]			
Pre-surgery	8 [7–9]	10 [9, 10]	0.073
Directly after surgery	4 [3–5]	5 [3–6]	0.239
4 weeks later	4 [3, 4]	4 [3–5]	0.486
Vertebroplasty level			
1 level	29 (69.1%)	2 (28.6%)	0.834
2 level	9 (21.4%)	2 (28.6%)	
3 levels and more	4 (9.5%)	3 (42.8%)	
Surgery duration in minutes [IQR]	44 [32–65]	66 [31–85]	0.166
Comorbidities			
Arterial hypertension	14 (33.3%)	3 (42.9%)	0.681
Coronary artery disease	15 (35.7%)	4 (57.1%)	0.407
Atrial fibrillation	16 (38.1%)	5 (71.4%)	0.122
Diabetes mellitus	8 (19.0%)	0 (0%)	0.581
History of PE/DVT/COPD	0 (0%)	0 (0%)	1.000
Vertebroplasty localization			
Thoracic	(38.0%)	2 (28.6%)	0.173
Lumbar	22 (52.4%)	3 (42.8%)	0.233
Thoracic and lumbar	4 (9.6%)	2 (28.6%)	0.456
Kyphosis angle pre-surgery [IQR]	12.9 [12.0–15.6]	12.1 [11.1–16.9]	0.466
Kyphosis angle post-surgery [IQR]	11.4 [10.2–13.4]	10.5 [9.1–15.1]	0.864
Length of stay in days [IQR]	6 [6.0–13.3]	9.5 [5–11]	0.223
Mortality	1 (2%)	0	1.000

ASA American Society of Anesthesiology, BMI body mass index, COPD chronic obstructive pulmonary disease, DVT deep vein thrombosis, IQR interquartile range, PE pulmonary embolism, Pts. patients, PVP percutaneous vertebroplasty, SD standard deviation, w/o without, yrs. years

p ≤ 0.05

in severe complications. Chew et al. reported rates of severe complications ranging from 2% to 11.5% resulting from cement leakage [23]. Cement leakage or extravasation is defined as the presence of extra-vertebral cement. Cement can leak into the spinal canal, the neural foramina, or another location in the body, leading to neurological complications such as paraplegia or root compression [24], and can also leak into the pulmonary arteries, causing a pulmonary embolism [25, 26]. We found reports in the literature of these complications ranging from 9% to 59.6% [21, 25, 27, 28]. At 14%, the cement leakage rates in our study are at the lower end of the reported rates. The rate of cement

leakage and the low prevalence of clinically significant symptoms or complications in our series are probably due to technical and organizational reasons at our center. On the technical side, we injected a high-viscosity cement and applied as much cement volume as bone and resistance allowed. On the organizational side, we believe that, in addition to strict selection of suitable patients, the standardized approach to vertebroplasty by our experienced neurosurgeon is significant. Varied results are reported in the literature on the influence of the volume of cement injected on the clinical outcome. In the majority of these studies, the volume of cement is not demonstrably related to the quality of

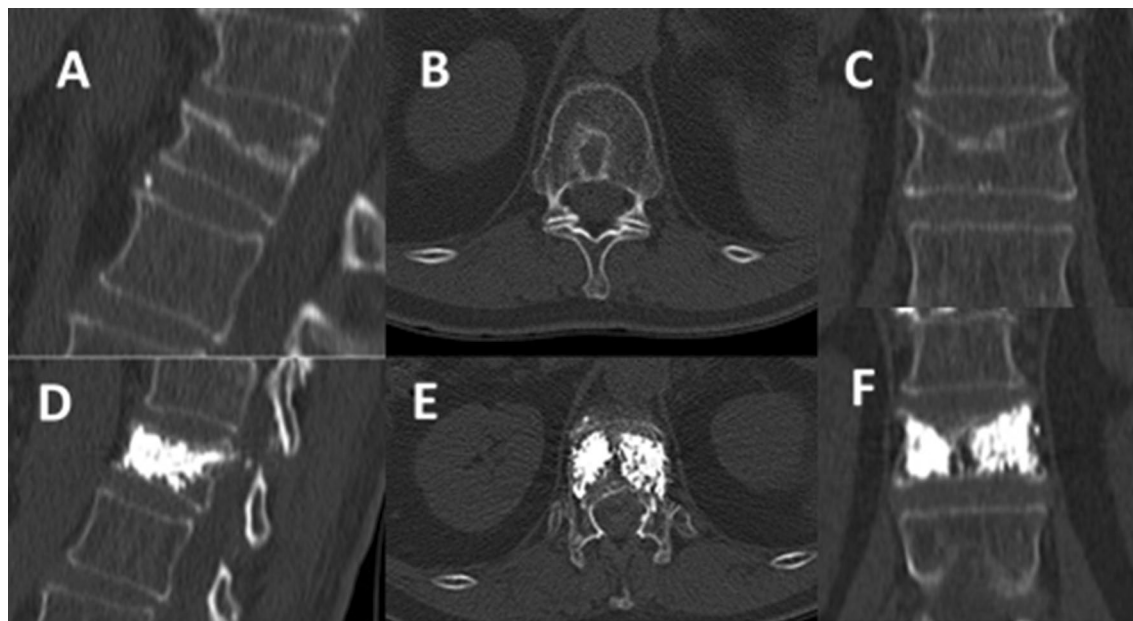


Fig. 3 Vertebroplasty of thoracic vertebral fracture (T12), OF type 1. **A–C** CT scan before surgery (sagittal, axial and coronal), **D–F** after surgery

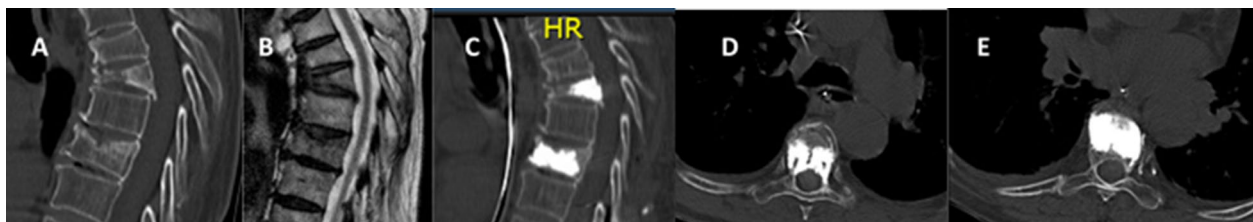

Fig. 4 **A, B** Sagittal CT and MRI of osteoporotic thoracic vertebral fractures (T4 and T6); T4: OF type 3, T6: OF type 2. **C–E** CT scan (sagittal and axial) after PVP of both vertebral fractures without complications

postoperative pain reduction, but to an increase in the rate of complications [29].

Several studies with different patient cohorts reported on the benefits of PVP in relation to VAS scores after surgery with low complication rates. Although these studies differed in their structure, including both prospective and retrospective cohorts, their results were along the lines of our data [30–34]. The change of kyphosis angle and the height of the affected vertebral body (compression index) did not appear to have brought about a significant improvement in clinical symptoms [35]. An injection of <4 mL per vertebral body was sufficient in our patients. Taking into account the result of other studies mentioned above and the clinically high reduction of pain in our study, the authors consider a low volume of cement to be both safe and effective.

Given the high correlation between age, sex, and the distribution of OVE, it is not surprising that there are a number of studies which express the view that OVF are

restricted to the female sex [1, 2, 36]. This was reflected in our cohort, which also had a higher mean age than usually described in the literature [33, 37]. We believe that our relatively low complication rates, despite our higher age range, suggest that it is possible to offer vertebroplasty for appropriate indications without increased risk, even at a more advanced age.

Except for sex, we found no factors that specifically correlated with the occurrence of postoperative complications—not even weight or cardiovascular comorbidities.

Our recommendation meets the criteria for a level of evidence 3, based on the Oxford Centre for Evidence-Based Medicine 2011 Levels of Evidence.

Limitations

We were able to achieve an acceptable degree of kyphosis angle correction, although we cannot judge on the basis of the short-term follow-up and the small patient cohort to what extent this had an influence on the overall result.

This represents one of the main limitations of this retrospective study.

Conclusions

Our data demonstrate that vertebroplasty was a feasible and effective treatment for pain reduction in geriatric patients with osteoporotic fractures despite cardiovascular comorbidities. This treatment option offered rapid and significant pain reduction, with a reasonable level of risk.

Abbreviations

ASA: America Society of Anesthesiology; BMI: Body mass index; CT: Computer tomogram; MRI: Magnetic resonance imaging; OV: Osteoporotic vertebral fracture; PVP: Percutaneous vertebroplasty; SD: Standard deviation; STIR: Short tau inversion recovery; VAS: Visual Analog Scale for pain; y/o: Years old.

Acknowledgements

None.

Study design

Retrospective clinical cohort study. The investigation was approved by the local ethics committee (protocol no 067/21).

Author contributions

MB: conceived, designed and performed the study; first draft of the manuscript and illustrations; analysis and interpretation of data. GB, SR, MH, JS: critical review of the manuscript. AS: statistical analysis. HV: critical review of the manuscript; analysis and interpretation of data, supervision of study. The final manuscript was critically reviewed and approved by all authors. All authors read and approved the final manuscript.

Funding

No funding was received for this research. This research did not receive any specific grant from funding agencies in the public, commercial, or not-for-profit sectors.

Availability of data and materials

All data generated or analyzed during this study are included in this published article.

Declarations

Ethics approval and consent to participate

All procedures were performed in accordance with the ethical standards of the institutional and national research committee (Ethics committee of the Rheinische Friedrich Wilhelms University Bonn) and with the 1964 Helsinki declaration and its later amendments or comparable ethical standards.

Consent for publication

The Corresponding Author transfers to the journal the non-exclusive publication rights and he warrants that his contribution is original and that he has full power to make this grant. The author signs for and accepts responsibility for releasing this material on behalf of any and all co-authors. This transfer of publication rights covers the non-exclusive right to reproduce and distribute the article, including reprints, translations, photographic reproductions, microform, electronic form (offline, online) or any other reproductions of similar.

Competing interests

The authors have no relevant financial or non-financial interests to disclose. Mohammed Banat, Gregor Bara, Abdallah Salemdawod, Motaz Hamed, Shaleen Rana, Jasmin Scorzin, and Hartmut Vatter declare that they have no conflict of interest. The authors alone are responsible for the content and writing of this work.

Received: 6 January 2022 Accepted: 9 September 2022
Published online: 24 September 2022

References

- Chapman J, Smith JS, Kopjar B, Vaccaro AR, Arnold P, Shaffrey CI, et al. The AOSpine North America Geriatric Odontoid Fracture Mortality Study: a retrospective review of mortality outcomes for operative versus nonoperative treatment of 322 patients with long-term follow-up. *Spine*. 2013;38(13):1098–104.
- O'Neill TW, Cockerill W, Matthis C, Raspe HH, Lunt M, Cooper C, et al. Back pain, disability, and radiographic vertebral fracture in European women: a prospective study. *Osteoporos Int*. 2004;15(9):760–5.
- Bartl R, Bartl C, Mutschler W. Diagnosis and therapy of osteoporosis. Strategy for effective treatment after fragility fractures. *Unfallchirurg*. 2003;106(7):526–41.
- Oberender P, Zerth J. Disease management from the economic point of view. *Zeitschrift für ärztliche Fortbildung und Qualitätssicherung*. 2003;97(3):189–94.
- Fassbender WJ, Stumpf UC. DVO guideline 2006. What changes have there been in the diagnosis, prevention and treatment of osteoporosis? *Z Rheumatol*. 2006;65(5):364–6.
- Felder-Puig R, Piso B, Guba B, Gartlehner G. Kyphoplasty and vertebroplasty for the management of osteoporotic vertebral compression fractures: a systematic review. *Der Orthopade*. 2009;38(7):606–15.
- Kotwica Z, Saracen A. Early and long-term outcomes of vertebroplasty for single osteoporotic fractures. *Neurol Neurochir Pol*. 2011;45(5):431–5.
- Saracen A, Kotwica Z. Treatment of multiple osteoporotic vertebral compression fractures by percutaneous cement augmentation. *Int Orthop*. 2014;38(11):2309–12.
- Hao J, Hu Z. Percutaneous cement vertebroplasty in the treatment of symptomatic vertebral hemangiomas. *Pain Physician*. 2012;15(1):43–9.
- Corcos G, Dbjay J, Mastier C, Leon S, Auperin A, De Baere T, et al. Cement leakage in percutaneous vertebroplasty for spinal metastases: a retrospective evaluation of incidence and risk factors. *Spine*. 2014;39(5):E332–8.
- Hussain A, Erdek M. Vertebroplasty augmentation procedures: examining the controversy. *Pain Physician*. 2013;16(5):E483–90.
- Buchbinder R, Osborne RH, Ebeling PR, Wark JD, Mitchell P, Wriedt C, et al. A randomized trial of vertebroplasty for painful osteoporotic vertebral fractures. *N Engl J Med*. 2009;361(6):557–68.
- Kallmes DF, Comstock BA, Heagerty PJ, Turner JA, Wilson DJ, Diamond TH, et al. A randomized trial of vertebroplasty for osteoporotic spinal fractures. *N Engl J Med*. 2009;361(6):569–79.
- Kanis JA, Harvey NC, McCloskey E, Bruyere O, Veronese N, Lorentzon M, et al. Algorithm for the management of patients at low, high and very high risk of osteoporotic fractures. *Osteoporos Int*. 2020;31(1):1–12.
- Langdon J, Way A, Heaton S, Bernard J, Molloy S. Vertebral compression fractures—new clinical signs to aid diagnosis. *Ann R Coll Surg Engl*. 2010;92(2):163–6.
- Rabin R, de Charro F. EQ-5D: a measure of health status from the EuroQol Group. *Ann Med*. 2001;33(5):337–43.
- In: Szende A, Janssen B, Cabases J, editors. *Self-Reported Population Health: An International Perspective based on EQ-5D*. Dordrecht (NL) 2014.
- Sugita M, Watanabe N, Mikami Y, Hase H, Kubo T. Classification of vertebral compression fractures in the osteoporotic spine. *J Spinal Disord Tech*. 2005;18(4):376–81.
- Agha RA, Fowler AJ, Rajmohan S, Barai I, Orgill DP, PROCESS Group. Preferred reporting of case series in surgery; the PROCESS guidelines. *Int J Surg*. 2016;36(Pt A):319–23.
- Tome-Bermejo F, Pinera AR, Duran-Alvarez C, Roman BL, Mahillo I, Alvarez L, et al. Identification of risk factors for the occurrence of cement leakage during percutaneous vertebroplasty for painful osteoporotic or malignant vertebral fracture. *Spine*. 2014;39(11):E693–700.
- Schmidt R, Cakir B, Mattes T, Wegener M, Puhl W, Richter M. Cement leakage during vertebroplasty: an underestimated problem? *Eur Spine J*. 2005;14(5):466–73.

22. Muijs SP, Nieuwenhuijse MJ, Van Erkel AR, Dijkstra PD. Percutaneous vertebroplasty for the treatment of osteoporotic vertebral compression fractures: evaluation after 36 months. *J Bone Jt Surg Br Vol.* 2009;91(3):379–84.
23. Chew C, Craig L, Edwards R, Moss J, O'Dwyer PJ. Safety and efficacy of percutaneous vertebroplasty in malignancy: a systematic review. *Clin Radiol.* 2011;66(1):63–72.
24. Patel AA, Vaccaro AR, Martyak GG, Harrop JS, Albert TJ, Ludwig SC, et al. Neurologic deficit following percutaneous vertebral stabilization. *Spine.* 2007;32(16):1728–34.
25. Kim YJ, Lee JW, Park KW, Yeom JS, Jeong HS, Park JM, et al. Pulmonary cement embolism after percutaneous vertebroplasty in osteoporotic vertebral compression fractures: incidence, characteristics, and risk factors. *Radiology.* 2009;251(1):250–9.
26. Krueger A, Bliemel C, Zettl R, Ruchholtz S. Management of pulmonary cement embolism after percutaneous vertebroplasty and kyphoplasty: a systematic review of the literature. *Eur Spine J.* 2009;18(9):1257–65.
27. Hulme PA, Krebs J, Ferguson SJ, Berlemann U. Vertebroplasty and kyphoplasty: a systematic review of 69 clinical studies. *Spine.* 2006;31(17):1983–2001.
28. Pitton MB, Herber S, Koch U, Oberholzer K, Drees P, Duber C. CT-guided vertebroplasty: analysis of technical results, extraosseous cement leakages, and complications in 500 procedures. *Eur Radiol.* 2008;18(11):2568–78.
29. Voormolen MH, Lohle PN, Lampmann LE, van den Wildenberg W, Juttman JR, Diekerhof CH, et al. Prospective clinical follow-up after percutaneous vertebroplasty in patients with painful osteoporotic vertebral compression fractures. *J Vasc Interv Radiol.* 2006;17(8):1313–20.
30. Baerlocher MO, Munk PL, Radvany MG, Murphy TP, Murphy KJ. Vertebroplasty, research design, and critical analysis. *J Vasc Interv Radiol.* 2009;20(10):1277–8.
31. Chen L, Black C, Hirsch JA, Beall D, Munk P, Murphy K. Vertebroplasty trials: the medium is the message. *J Vasc Interv Radiol.* 2014;25(2):323–5.
32. Firanesco CE, de Vries J, Lodder P, Venmans A, Schoemaker MC, Smeets AJ, et al. Vertebroplasty versus sham procedure for painful acute osteoporotic vertebral compression fractures (VERTOS IV): randomised sham controlled clinical trial. *BMJ.* 2018;361: k1551.
33. Leali PT, Solla F, Maestretti G, Balsano M, Doria C. Safety and efficacy of vertebroplasty in the treatment of osteoporotic vertebral compression fractures: a prospective multicenter international randomized controlled study. *Clin Cases Miner Bone Metab.* 2016;13(3):234–6.
34. Yang EZ, Xu JG, Huang GZ, Xiao WZ, Liu XK, Zeng BF, et al. Percutaneous vertebroplasty versus conservative treatment in aged patients with acute osteoporotic vertebral compression fractures: a prospective randomized controlled clinical study. *Spine.* 2016;41(8):653–60.
35. Jha RM, Yoo AJ, Hirsch AE, Growney M, Hirsch JA. Predictors of successful palliation of compression fractures with vertebral augmentation: single-center experience of 525 cases. *J Vasc Interv Radiol.* 2009;20(6):760–8.
36. Melton LJ 3rd, Chrischilles EA, Cooper C, Lane AW, Riggs BL. Perspective How many women have osteoporosis? *J Bone Miner Res.* 1992;7(9):1005–10.
37. Fan W, Qiao T, You Y, Zhang J, Gao J. Perioperative prevalence of deep vein thrombosis in patients with percutaneous kyphoplasty: a retrospective study with routine ultrasonography. *Medicine.* 2020;99(10): e19402.

Publisher's Note

Springer Nature remains neutral with regard to jurisdictional claims in published maps and institutional affiliations.

Submit your manuscript to a SpringerOpen[®] journal and benefit from:

- Convenient online submission
- Rigorous peer review
- Open access: articles freely available online
- High visibility within the field
- Retaining the copyright to your article

Submit your next manuscript at ► [springeropen.com](https://www.springeropen.com)
