

CASE REPORT

Open Access



Coronavirus disease 2019-associated nephropathy in an African American patient: a case report and review of the literature

Vijaypal S. Dhillon^{1*} , Ahmad Alkashash² and Karolina Viquez-Beita³

Abstract

Background Acute kidney injury is now recognized as a common complication of coronavirus disease 2019, affecting up to 46% of patients, with acute tubular injury as the most common etiology. Recently, we have seen an increase in cases of collapsing glomerulonephritis in patients with coronavirus disease 2019, also known as coronavirus disease 2019-associated nephropathy. It has been noted to be seen with a higher incidence in African American patients who are carriers of the *APOL1* variant allele.

Case presentation A 47-year-old African American male with a past medical history of asthma presented to the emergency department with complaints of intermittent chest pain, shortness of breath, and worsening confusion. On admission, he was found to be hemodynamically stable, but labs were significant for elevated creatinine and blood urea nitrogen, signifying acute kidney injury. He was admitted and taken for emergent dialysis. During his hospitalization, he was found to be positive for coronavirus disease 2019. Renal biopsy was done, which showed collapsing glomerulopathy, and the patient continues to require outpatient dialysis after discharge.

Conclusion Collapsing glomerulonephritis has emerged as a complication in patients with coronavirus disease 2019. This condition should be particularly suspected in African American patients who present with acute kidney injury, nephrotic-range proteinuria, and who are positive for coronavirus disease 2019. Current treatment options are limited to supportive treatment and renal replacement therapy. More clinical cases and trials are needed to better understand and improve therapeutic outcomes in these patients.

Keywords COVID, COVID-19, COVAN, Collapsing glomerulopathy, Critical care, ICU, Acute kidney injury, Acute renal failure

Background

Acute kidney injury (AKI) is now recognized as a common complication of the coronavirus-19 (COVID-19), affecting up to 46% [1] of patients with acute tubular

injury as the most common injury. In recent years we have seen an increase in cases of collapsing glomerulonephritis, also known as COVID-19-associated nephropathy (COVAN), with a higher incidence in the African American population, specifically those carrying the *APOL1* allele [2, 3]. It is theorized that COVID-19 triggers an inflammatory cascade that may affect the *APOL1* variant gene, causing glomerular impairment. The disease may range from mild progressive kidney disease to acute renal failure. Currently, the mainstay of treatment involves supportive measures and renal replacement therapy. The authors present a case in which COVAN

*Correspondence:

Vijaypal S. Dhillon
vdhillon@iu.edu

¹ Internal Medicine, Indiana University School of Medicine Muncie, Muncie, USA

² Department of Pathology, Indiana University, Indianapolis, USA

³ Hospitalist Department, IU Health Ball Memorial, Muncie, USA



© The Author(s) 2023. **Open Access** This article is licensed under a Creative Commons Attribution 4.0 International License, which permits use, sharing, adaptation, distribution and reproduction in any medium or format, as long as you give appropriate credit to the original author(s) and the source, provide a link to the Creative Commons licence, and indicate if changes were made. The images or other third party material in this article are included in the article's Creative Commons licence, unless indicated otherwise in a credit line to the material. If material is not included in the article's Creative Commons licence and your intended use is not permitted by statutory regulation or exceeds the permitted use, you will need to obtain permission directly from the copyright holder. To view a copy of this licence, visit <http://creativecommons.org/licenses/by/4.0/>. The Creative Commons Public Domain Dedication waiver (<http://creativecommons.org/publicdomain/zero/1.0/>) applies to the data made available in this article, unless otherwise stated in a credit line to the data.

occurred in an African American male who continues to require long-term renal replacement therapy.

Case presentation

A 47-year-old African American male with a past medical history of asthma presented to the emergency department with complaints of intermittent chest pain, shortness of breath, and worsening confusion. The patient was afebrile. In the emergency department, vitals showed an oxygen saturation of 96% on room air, a heart rate of 122 beats per minute, and a respiratory rate of 22 breaths per minute. On physical examination, the patient appeared ill and drowsy. While able to answer questions, he required repeated arousing as he was somnolent. Lungs were clear on auscultation, and no murmur was appreciated. The abdomen was soft and non-tender. He denied any history of alcohol, tobacco, or illicit drug abuse. There was no family history of confusion, dementia, or kidney disease. However, he reported exposure to COVID-19 in the past week.

While hemodynamically stable on admission, labs were remarkable for acute kidney injury with a serum creatinine of 31 mg/dL (normal 0.7–1.3 mg/dL), blood urea nitrogen (BUN) of 210 mg/dL (normal 6–24 mg/dL), potassium level of 7.6 mmol/L (normal 3.6–5.2 mmol/L), and a calcium level of 21.5 mg/dL (normal 8.6–10.3 mg/dL). Urinalysis showed significant proteinuria with levels equal to or greater than 500 mg/dL, white blood cells (WBC) of 21–50/hpf, and red blood cells of 6–10/hpf. Urine studies were done, which showed a urine protein level of 8700 mg/dL. Urine protein electrophoresis was interpreted as a glomerular pattern with no monoclonal bands seen, often seen in nephrotic and nephritic syndromes. A serology panel was sent, and antineutrophil cytoplasmic antibody (ANCA), antinuclear antibodies (ANA), human immunodeficiency virus (HIV), and hepatitis panel were negative. Electrocardiogram (ECG) showed normal sinus rhythm with peaked T waves.

Further workup showed patient positive for COVID-19 by antigen test. As a result of the patient's labs and condition, he was admitted and taken for emergent dialysis. A renal biopsy was performed, and light microscopy showed collapse of basement membranes in some glomeruli, along with severe tubular atrophy, interstitial fibrosis, and dilated tubules filled with hyaline and protein casts. Direct immunofluorescence did not show evidence of immune complex disease. Electron microscopy showed widespread effacement of foot processes, which correlated with proteinuria. These findings correlated with collapsing glomerulopathy (Figs. 1, 2). Computed tomography (CT) of the head and brain magnetic resonance imaging (MRI) scans

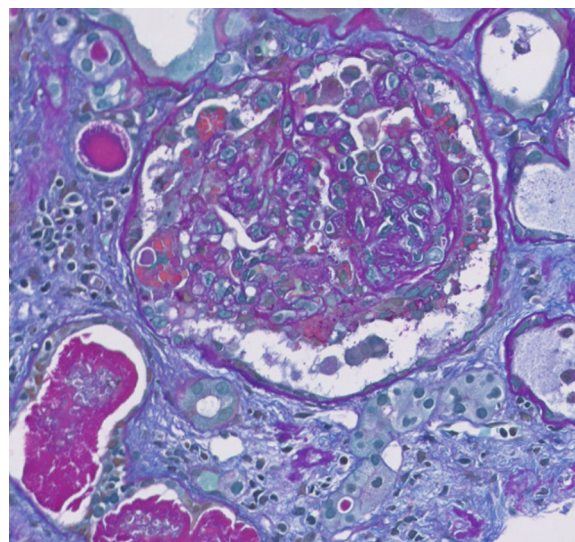


Fig. 1 Allochrome: glomerulus with collapsing features; including collapse of basement membranes with segmental accentuation and overlying hyaline droplet filled epithelial cells. Active cellular crescents, however, are not seen. Mesangial matrix is mildly expanded. In addition, dilate tubules filled with hyaline and protein casts, loss of brush borders, and intraluminal cellular and granular debris are also seen

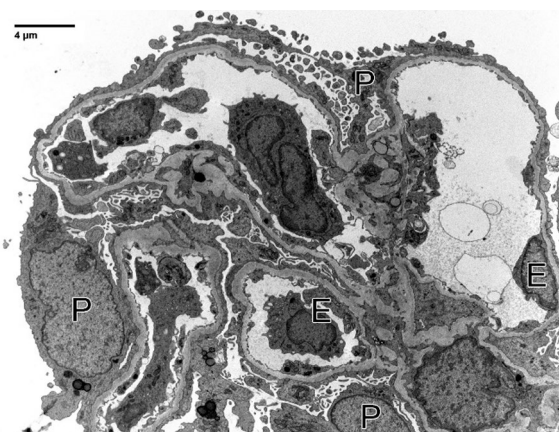


Fig. 2 Electron microscopy: one non-obliterated glomerulus was subjected to ultrastructural examination, with good tissue preservation. Podocytes display widespread effacement of foot processes, which correlates to proteinuria. Glomerular basement membranes are uniformly contoured except for a few segments with mild corrugation (mean glomerular basement membranes thickness, 303 ± 48 nm). Electron dense deposits were not seen

were done, which did not show any acute findings. After dialysis, his encephalopathy showed significant improvement. He was more awake, more alert, and able to have extended conversations. Unfortunately, his kidney function did not improve, and he continues to require outpatient hemodialysis after discharge.

Understandably, this has frustrated him, however, he has been compliant with follow-ups and dialysis appointments.

Discussion

While cases of COVID-19 initially presented with severe respiratory distress syndrome, after vaccinations and the introduction of variants, the number of patients that are developing severe pulmonary disease has decreased, however, we have seen other complications such as renal impairment [1].

Focal segmental glomerulosclerosis is a major cause of end-stage renal disease. It can present with several variants, including collapsing, tip, cellular, perihilar, and not otherwise specified [4]. The collapsing variant of focal segmental glomerulosclerosis is described as segmental and global collapse of the glomerular capillaries, marked hypertrophy, and hyperplasia of the podocytes. It is a severe form with high risk of progression to irreversible kidney failure [5]. It was first described in patients with HIV infection [4], known as HIV-associated nephropathy (HIVAN). However, since the use and introduction of antiretroviral therapy, the incidence of HIVAN has decreased significantly. Collapsing glomerulopathy has also been associated with other viral infections, drugs, and ischemia [2, 5]. While other viral infections such as cytomegalovirus and Epstein–Barr virus have been associated with collapsing glomerulopathy, in recent years we have noticed an increased incidence of COVID-19-associated glomerulopathy, also known as COVAN. This pathology has been reported by several authors, and interestingly, all the affected patients are of African American descent with the *APOLI* high-risk genotype [2, 3, 5–15].

Currently, the pathology is not well understood. As high-risk patients with the *APOLI* genotype appear to be more affected, some authors believe COVAN parallels the development of HIVAN in patients with HIV. In HIVAN, it is believed that HIV causes a “second-hit” in patients with the *APOLI* genotype [2]. The infection, or inciting event, triggers an inflammatory response that activates the interferon–chemokine pathway. This in turn affects the *APOLI* variant gene, causing glomerular impairment. It is believed that COVID-19 triggers a similar inflammatory response and this is why patients with the *APOLI* genotype are more prone to developing COVAN. The theory is supported by immunostaining of COVAN biopsies increasing the expression of phosphor-STAT3, which is activated by interleukin-6 [2, 7–9].

Another mechanism of injury that has been proposed is direct viral deposition in the glomerular membrane. This theory is controversial, given that viral particles are not present in some of the COVAN kidney biopsies [9].

Clinically, the patient presented with renal dysfunction and nephrotic range proteinuria with minimal respiratory symptoms. In several COVAN case reports, the outcome involves renal replacement therapy. The treatment for COVID-19 has been mainly directed toward acute respiratory failure, with medications such as dexamethasone, remdesivir, baricitnib, and tocilizumab often indicated on the basis of oxygenation levels [16]. When patients present with COVAN but without hypoxemia, treatment is mainly supportive. Our case report and others raise the question of whether initiating these therapies in patients with COVAN will change the course of kidney failure and possibly prevent the need for long-term renal replacement therapies.

Conclusions

COVAN has emerged as a complication in patients with COVID-19. This condition should be particularly suspected in patients of African American descent who present with COVID-19, acute kidney injury, and nephrotic-range proteinuria. *APOLI* variant carriers are at a higher risk of developing COVAN. More clinical trials are needed, especially in carriers of *APOLI*, to better understand the pathophysiology behind this disease and improve therapeutic options for these patients.

Acknowledgements

Not applicable.

Author contributions

Authors VSD and KV-B contributed to writing the article. AA read the pathological slides of the kidney and was a key contributor to writing the article. All authors read and approved the final manuscript.

Funding

All sources of funding for the researched report should be declared. The role of funding body in the design of the study, collection, analysis, and interpretation of data and in the writing of the manuscript should be declared.

Availability of data and materials

The datasets during and/or analyzed during the current study are available from the corresponding author on reasonable request.

Declarations

Ethics approval and consent to participate

All procedures performed in studies involving human participants were in accordance with the ethical standards of the institutional and national research committee and with the 1964 Helsinki declaration and its later amendments or comparable ethical standards. Informed consent was obtained from the individual participating in this case report.

Consent for publication

Written informed consent was obtained from the patient for publication of this case report and any accompanying images. A copy of the written consent is available for review by the Editor-in-Chief of this journal.

Competing interests

The authors declare that they have no competing interests.

Received: 14 September 2022 Accepted: 14 March 2023

Published online: 07 April 2023

References

- Chan L, Chaudhary K, Saha A, Chauhan K, Vaid A, Zhao S, Paranjpe I, Somani S, Richter F, Miotto R, Lala A, Kia A, Timsina P, Li L, Freeman R, Chen R, Narula J, Just AC, Horowitz C, Fayad Z, et al. AKI in hospitalized patients with COVID-19. *J Am Soc Nephrol*. 2021;32(1):151–60. <https://doi.org/10.1681/ASN.2020050615>.
- Velez JCQ, Caza T, Larsen CP. COVAN is the new HIVAN: the re-emergence of collapsing glomerulopathy with COVID-19. *Nat Rev Nephrol*. 2020;16(10):565–7. <https://doi.org/10.1038/s41581-020-0332-3>.
- Wu H, Larsen CP, Hernandez-Arroyo CF, Mohamed MMB, Caza T, Sharshir M, Chughtai A, Xie L, Gimenez JM, Sandow TA, Lusco MA, Yang H, Acheampong E, Rosales IA, Colvin RB, Fogo AB, Velez JCQ. AKI and collapsing glomerulopathy associated with COVID-19 and *APOL1* high-risk genotype. *J Am Soc Nephrol*. 2020;31(8):1688–95. <https://doi.org/10.1681/ASN.2020050558>.
- D'Agati VD, Fogo AB, Bruijn JA, Jennette JC. Pathologic classification of focal segmental glomerulosclerosis: a working proposal. *Am J Kidney Dis*. 2004;43(2):368–82. <https://doi.org/10.1053/j.ajkd.2003.10.024>.
- Muehlig AK, Gies S, Huber TB, Braun F. Collapsing focal segmental glomerulosclerosis in viral infections. *Front Immunol*. 2022;12:800074. <https://doi.org/10.3389/fimmu.2021.800074>.
- Mohamed MMB, Lukitsch I, Torres-Ortiz AE, Walker JB, Varghese V, Hernandez-Arroyo CF, Alqudsi M, LeDoux JR, Velez JCQ. Acute kidney injury associated with coronavirus disease 2019 in urban New Orleans. *Kidney*. 2020;1(7):614–22. <https://doi.org/10.34067/KID.0002652020>.
- Meliambro K, Li X, Salem F, Yi Z, Sun Z, Chan L, Chung M, Chancay J, Vy HMT, Nadkarni G, Wong JS, Fu J, Lee K, Zhang W, He JC, Campbell KN. Molecular analysis of the kidney from a patient with COVID-19-associated collapsing glomerulopathy. *Kidney Med*. 2021;3(4):653–8. <https://doi.org/10.1016/j.xkme.2021.02.012>.
- Legrand M, Bell S, Forni L, Joannidis M, Koyner JL, Liu K, Cantaluppi V. Pathophysiology of COVID-19-associated acute kidney injury. *Nat Rev Nephrol*. 2021;17(11):751–64. <https://doi.org/10.1038/s41581-021-00452-0>.
- Su H, Yang M, Wan C, Yi LX, Tang F, Zhu HY, Yi F, Yang HC, Fogo AB, Nie X, Zhang C. Renal histopathological analysis of 26 postmortem findings of patients with COVID-19 in China. *Kidney Int*. 2020;98(1):219–27. <https://doi.org/10.1016/j.kint.2020.04.003>.
- Larsen CP, Bourne TD, Wilson JD, Saqqa O, Sharshir MA. Collapsing glomerulopathy in a patient with COVID-19. *Kidney Int Rep*. 2020;5(6):935–9. <https://doi.org/10.1016/j.ekir.2020.04.002>.
- Kissling S, Rotman S, Gerber C, Halfon M, Lamoth F, Comte D, Lhopitalier L, Sadallah S, Fakhouri F. Collapsing glomerulopathy in a COVID-19 patient. *Kidney Int*. 2020;98(1):228–31. <https://doi.org/10.1016/j.kint.2020.04.006>.
- Sharma Y, Nasr SH, Larsen CP, Kemper A, Ormsby AH, Williamson SR. COVID-19-associated collapsing focal segmental glomerulosclerosis: a report of 2 cases. *Kidney Med*. 2020;2(4):493–7. <https://doi.org/10.1016/j.xkme.2020.05.005>.
- Shetty AA, Tawhari I, Safar-Boueri L, Seif N, Alahmadi A, Gargiulo R, Aggarwal V, Usman I, Kisselev S, Gharavi AG, Kanwar Y, Quaggin SE. COVID-19-associated glomerular disease. *J Am Soc Nephrol*. 2021;32(1):33–40. <https://doi.org/10.1681/ASN.2020060804>.
- Nasr SH, Kopp JB. COVID-19-associated collapsing glomerulopathy: an emerging entity. *Kidney Int Rep*. 2020;5(6):759–61. <https://doi.org/10.1016/j.ekir.2020.04.030>.
- Kudose S, Santoriello D, Bomback AS, Sekulic M, Batal I, Stokes MB, Ghavami IA, Kim JS, Marasa M, Xu K, Peleg Y, Barasch J, Canetta P, Rasouly HM, Gharavi AG, Markowitz GS, D'Agati VD. Longitudinal outcomes of COVID-19-associated collapsing glomerulopathy and other podocytopathies. *J Am Soc Nephrol*. 2021;32(11):2958–69. <https://doi.org/10.1681/ASN.2021070931>.
- Asselah T, Durantel D, Pasmant E, Lau G, Schinazi RF. COVID-19: discovery, diagnostics and drug development. *J Hepatol*. 2021;74(1):168–84. <https://doi.org/10.1016/j.jhep.2020.09.031>.

Publisher's Note

Springer Nature remains neutral with regard to jurisdictional claims in published maps and institutional affiliations.

Ready to submit your research? Choose BMC and benefit from:

- fast, convenient online submission
- thorough peer review by experienced researchers in your field
- rapid publication on acceptance
- support for research data, including large and complex data types
- gold Open Access which fosters wider collaboration and increased citations
- maximum visibility for your research: over 100M website views per year

At BMC, research is always in progress.

Learn more biomedcentral.com/submissions

