

ORIGINAL ARTICLE

Open Access



# Value of point-of-care ultrasonography compared with computed tomography scan in detecting potential life-threatening conditions in blunt chest trauma patients

Amirhosein Jahanshir<sup>1</sup>, Shida Mohajer Moghari<sup>2</sup>, Ayat Ahmadi<sup>3</sup>, Pejman Z. Moghadam<sup>4</sup> and Maryam Bahreini<sup>5\*</sup> 

## Abstract

**Background:** Ultrasonography is a suitable modality that can potentially improve patient care, saving time and lives.

**Purpose:** This article has evaluated the caveats and pitfalls of point-of-care ultrasonography in the diagnosis of pneumothorax, hemothorax and contusion.

**Materials and methods:** This prospective study was performed in 157 patients with blunt chest trauma in 3 university hospitals. Ultrasonography was performed by 2 board-certified emergency medicine specialists and an emergency medicine resident PGY-3 after passing the training process successfully.

**Results:** The false-negative cases were not significantly correlated with accompanying traumatic injuries. Lung ultrasonography accompanied by chest physical examination show accuracy 91.8. Point-of-care ultrasonography (PoCUS) showed sensitivity 75.0%, specificity 100%, positive-predictive value (PPV) of 100% and a negative-predictive value (NPV) of 94.9% for the diagnosis of pneumothorax. For hemothorax, bedside PoCUS had a sensitivity of 45.4%, specificity of 100%, PPV of 100% and NPV of 91.8%. PoCUS was assessed 58.1% sensitive and 100% specific for detecting lung contusion with positive-predictive value (PPV) of 100% and a negative-predictive value (NPV) of 86.3%. Performing US resulted in no false-positive cases.

**Conclusions:** Point-of-care ultrasonography was highly sensitive to detect pneumothorax and can be beneficial for the disposition of stable patients and to detect PTX in unstable patients before transferring to the operating room. It is also moderately appropriate for the diagnosis of hemothorax and lung contusion compared to the gold standard, CT scan. It is essential to consider the false-negative and false-positive instances of lung ultrasound in various situations to enhance management and disposition of blunt thoracic injuries.

**Keywords:** Chest injury, Computed tomography, Emergency, Hemothorax, Lung injury, Pneumothorax, Predictive value of tests, Ultrasonography

## Introduction

### Background

Thoracic injuries account for 20 to 25% of the trauma mortality which can be preventable by timely diagnosis. Despite of undesirable low sensitivity, chest X-ray (CXR) has remained one of the adjuncts for evaluation of chest trauma. Bedside ultrasonography (US) has an important

\*Correspondence: bahreiniMaryam@gmail.com; m-bahreini@tums.ac.ir  
<sup>5</sup> Department of Emergency Medicine, Sina Trauma and Surgery Research Center, Sina Hospital, Tehran University of Medical Sciences, Tehran, Iran  
Full list of author information is available at the end of the article

role in primary and advanced trauma life support (ATLS) due to higher sensitivity and specificity to detect of pneumothorax (PTX) and hemothorax (HTX) [1–3]. However, lung contusion, a common injury in 30–75% of blunt chest trauma, may remain undiagnosed by radiography or ultrasonography depending on the extent and intensity [4]. Besides, computed tomography (CT) scan is the standard modality for the assessment of lung parenchymal injuries. Yet it is time-consuming, expensive and there are concerns about radiation exposure and patient hemodynamic instability during transfer [1]. In this context, multiple trauma patients often undergo CT scan in trauma centers; however, the presence of clinical injuries that require emergent operative management in unstable patients such as brain lateralizing signs, necessitates the use of extended focused assessment with sonography in trauma (eFAST) bedside exam and bypassing torso CT scan. This may also remain true for the stable and selective population of patients with high risk mechanism of injury to reduce the risk of radiation. Based on the possibility of diagnosing potential life-threatening conditions in traumatic injuries by US, revising the Advanced Trauma Life Support (ATLS) guidelines have been proposed to incorporate eFAST in the work-up of high-energy trauma patients [5].

### Goals of investigation

Ultrasound may be overused without sufficient applicability in some situations. As the published papers were unable to find a unified answer for this issue, we discuss pitfalls and caveats to point-of-care lung ultrasound in various traumatic chest injuries, analyze false-negative and false-positive cases and highlight the growing topic of the point-of-care ultrasound (PoCUS) despite its common diagnostic limitations. Moreover, the diagnostic accuracy of ultrasonography was estimated in the detection of pneumothorax, hemothorax and contusion simultaneously in comparison with the gold standard, CT-scan.

### Materials and methods

#### Selection of participants

Patients with blunt chest trauma were included if they were 18 years or older with acute chest trauma defined as the isolated blunt trauma to the chest or back and also multiple trauma patients involving chest trauma. All chest trauma patients were recruited in the study including unconscious or apneic patients, or individuals with open chest injuries. All participants consented to enter the study.

Patient with old chest trauma, past history of lung fibrosis or if they were not planned or assented to CT

scan (except for clinically unstable patients who underwent chest tube insertion) were excluded.

#### Study design and setting

This longitudinal study was performed on 157 patients with blunt chest trauma in 3 university hospitals including a level I and 2 level II trauma centers with approximately 2200–3850 trauma patients per year. Bedside chest ultrasonography was performed by 2 board-certified emergency medicine specialists, certified from the Board Committee of Emergency Medicine of the country, and an emergency medicine resident PGY-3 (SM), in the third year of the residency program. The PGY-3 emergency medicine resident required to perform 50 successful ultrasound scans in this field prior to this study. These operators were blinded to the findings brought up by chest exam and radiography and were not involved in patient management. Patients were included by convenience sampling in the operators' clinical shifts 24/7 in the emergency department.

#### Interventions

As a common practice, the patients underwent the standard of care according to the ATLS guideline. Standard chest physical exam was performed routinely and documented consisting of tachypnea, abrasion or laceration, emphysema, rib tenderness or crepitation, hypotension, oxygen desaturation, stridor and other factors discussed in Table 1. Then, chest US was performed prior to imaging. Trauma patients commonly underwent supine CXR although in selected stable patients with definite intact spine, upright films might have been ordered up to the clinician's judgement and patient's condition. Chest X-ray was planned except for patients who were suspected for tension pneumothorax or massive hemothorax by physical exam and bedside ultrasonography. If rush of air or 100 ml of blood was detected during tube thoracotomy, the diagnosis became confirmed. These patients might undergo CT scan for further trauma evaluation if they became clinically and vitally stable; otherwise, because of the definite diagnosis, they were included in the study without CT scan. CTs were homogeneous by the technique applied and performed using 16-slice multidetector CT scanner (Philips Brilliance, Emotion, and Ingenuity) with slice width of 3 mm. Board-certified emergency physicians, who were blinded to the study, interpreted them.

Based on the discretion of the treating physician including clinical judgement in conjunction with the NEXUS chest trauma criteria, stable patients underwent chest computed tomography within 6 h of their trauma. As standard management in our setting, the time elapsed from the chest physical exam and CXR to chest

**Table 1 The diagnostic findings applied to assess traumatic chest injuries in physical exam and ultrasonography**

Assessment	Definition	Simple pneumothorax	Tension pneumothorax	Hemothorax	Massive hemothorax	Pulmonary contusion
Findings of physical examination						
Inspection	Chest expansion	NI-↓	↓	↓	↓	NI
	Trachea	NI	Deviated	NI	Deviated	NI
	Jugular vein pressure	NI	↑	NI	↓	NI
Percussion	The sound of striking 2 fingers on inter-costal spaces	NI-hyperresonance	Hyperresonance	NI-dull	Dull	NI
Auscultation	To hear both sides comparatively and note sounds' quality	↓	NI-dull	NI-↓	↓	NI-crackles
Findings of ultrasonography						
Pleural sliding	The shimmering movement of parietal pleura during inspiration	Lost in injured zone	Lost	NI	May be NI	Maybe falsely ↓
Seashore sign	Normal lung M-mode of sandy appearance above and parallel lines below	Lost in injured zone	Lost	NI	May be NI	May be NI
Barcode/stratosphere sign	Abnormal M-mode showing multiple parallel lines	+ in injured zone	+	-	-	May be falsely +
Lung point	The interface of normal lung and pneumothorax area in B-M mode	May be +	Often -	-	-	-
Sinusoid sign	The sinusoidal movement of the collapsed lung in the pleural fluid	-	-	+	+	-
V-line	Echogenic vertebral line with posterior shadow due to the transmission of ultrasound waves through the pleural fluid	-	-	May be +	+	-
B-lines/comet tails	Vertical echogenic artifact lines from the pleura to the screen edge, if multiple, resulting from alveolo-interstitial syndrome (rocket sign)	Lost	Lost	NI	May be NI	↑
Peripheral parenchymal lesions	Lung hepatization with subpleural hypoechoic foci and pleural line gap	-	-	-	-	+

CT was not more than 90 min. The chest trauma injuries were confirmed either by CT scan or by performing an emergent thoracostomy [6]. In our trauma centers, CT scan is frequently used and accessible 24/7. Generally, nearly asymptomatic patients with isolated occult PTX, small amount unilateral pneumothorax, hemothorax or

contusion were observed to discharge without intervention according to our ED management protocols.

**PoCUS protocol**

PoCUS was performed by Medison 8 (SONOACE), SonoSite Edge II and Samsung UGEO HM70A and

**Table 2 The diagnostic criteria of chest X-ray, US and CT scan to determine lung injuries in our settings**

Diagnostic criteria		PTX	HTX	Contusion
Chest X-ray		A thin dense line as the visceral pleural edge separating from the parietal pleura, the distance between the 2 pleurae is radiolucent usually accumulating in the periphery and sometimes deep lucent lateral costophrenic angle	In the presence of sufficient amount of blood, the involved hemithorax is hazy. If upright film is performed, the costophrenic sulcus become blunted.	Alveolar infiltration, irregular patchy consolidation that usually evolve within the first 6 h
US		Absence of lung sliding and the presence of stratosphere sign and the absence of B lines with or without "lung point"	Dependent collection above diaphragm with or without the sinusoidal movement of collapsed lung in inspiration in the B and M mode scan, the presence of V line	Three B lines in at least 2 zone scans, alveolo-interstitial syndrome (AIS), peripheral parenchymal lesions (PPL) and punctiform hyperechoic lesions without respiratory alterations
CT scan		In the pulmonary window, the existence of air in pleural space that may collapse the adjacent lung	Blood in the pleural space with Hounsfield Unit of about 45–65 in the mediastinal window	An interstitial or alveolar lung injury, usually focal and non-segmental peripheral opacification in lung parenchyma in lower lobes

PTX pneumothorax, HTX hemothorax, US ultrasonography, CT computed tomography

3–8 MHz and 7–15 MHz transducers. Each lung was scanned at least in 4 spaces for the evidence of pneumothorax, hemothorax and lung contusion by B and M modes: the probe was placed in the 2nd to 4th intercostal spaces in midclavicular and parasternal lines and the 6th or 7th intercostal space in the mid-axillary line in the supine position.

Subsequently, the low-frequency probe was positioned in the 5th to 6th right anterior to mid-axillary region and 7th to 8th left mid to posterior axillary region to find hemothorax as part of the eFAST exam [7]. Each bedside scan was performed routinely in 3–5 min.

The detailed diagnostic findings of chest traumatic injuries including simple and tension PTX, simple and massive HTX and pulmonary contusion determined by ultrasonography and physical exam are presented in Table 1. Table 2 demonstrates how we conducted our study using CXR, ultrasonography (US) and CT scan for traumatic lung injuries.

### Outcomes

This study aimed to widely assess the thoracic injuries by point-of-care ultrasonography in the emergency department compared to the computed tomography findings and interpreted false-positive and negative results.

A questionnaire was designed containing demographic data such as age, gender, trauma mechanism and detailed information on physical exam, ultrasonography and CT scan to detect thoracic injuries. As different scales are available to score injury severity with various accuracies and no definitive superiority, we report injuries according to the injury severity scale (ISS) [8, 9].

### Analysis

Data were analyzed by SPSS, version 22.0. Chicago, IL, USA. Sensitivity, specificity, positive-predictive value (PPV) and negative-predictive value (NPV) of different diagnostic modalities were assessed. Besides, univariate regression analysis was performed to assess single factors that are correlated with false-negative results including some related injuries or multisystem injuries. The type-I error 0.05 was considered significant and the confidence intervals (CI 95%) were reported. Sample size calculation met 80% power for 95% sensitivity. False-negative episodes were analyzed with regard to the results of physical examination, CT scan and outcome details to assess whether they were clinically significant or not. In this context, false-negative cases are categorized by findings such as occult PTX, subcutaneous emphysema, which was analyzed in these cases as a confounder to ultrasound results, and also the clinical decision for placing tube thoracostomy.

### Ethical considerations

The protocol of study has been reviewed and approved by the University of Medical Sciences Institutional Review Board and the ethical committee. All procedures were in accordance with the ethical standards of the institutional and national research committee and with the 1964 Helsinki declaration and its later ethical standards. Informed consent was obtained from the conscious participants and the relatives of critically ill patients.

### Results

#### Characteristics of study subjects

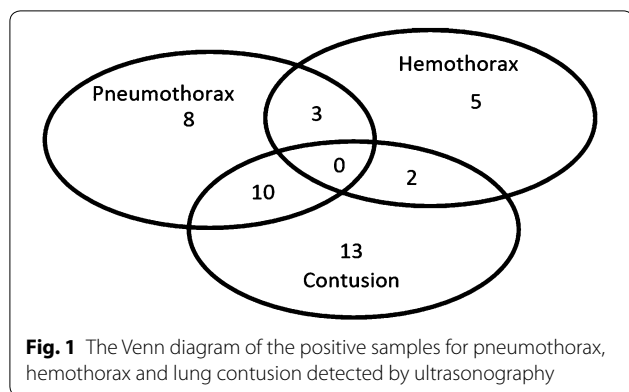
In this study, of 160 patients, 157 agents with blunt chest trauma were enrolled after obtaining informed consent, of which 134 (85.4%) were men. Three patients were excluded, 1 was underaged and 2 were not willing to undergo the study. The mean age was 38.3 (SD: 18.57) years. Motor vehicle collision ( $n=42$ , 26.8%) and falling ( $n=43$ , 27.4%) were the most common injury mechanisms. Among all patients, 94 (59.87%) cases had injury severity score 10–50 while 19 (12.10%) cases had ISS more than 50. Furthermore, 56 (35.6%) of patients had pneumothorax ( $n=21$ , 13.3%), hemothorax ( $n=10$ , 6.3%) or contusion ( $n=25$ , 15.9%). The Venn diagram of samples of different diagnoses by PoCUS is presented in Fig. 1.

#### Main results

The sensitivity, specificity, PPV, NPV and accuracy of point-of-care ultrasonography for the diagnosis of blunt pneumothorax, hemothorax and pulmonary contusion are shown in Table 3. The US results for pneumothorax was 75.0% (CI 55.1–89.0), while it was 45.4% (CI 24.4–67.8) and 58.1% (CI 42.1–73.3) for hemothorax and pulmonary contusion, respectively. Performing US resulted in no false-positive cases (specificity=100%), but when it was combined with physical examination, 9 cases were falsely diagnosed as positive (negative false-positive rate=9.2%). Rib fracture was present in 25 patients (15.9%). Three patients (1.9%) were intubated as a result of other traumatic injuries. None needed resuscitative or urgent thoracotomy.

#### Description of false-negative cases

To elucidate why US missed PTX in 7 cases, false-negative results were reviewed. Of 157 enrolled participants, 28 (17.83%) patients had pneumothorax in CT scan. Seven patients were not diagnosed by US of whom, 3 patients had concomitant subcutaneous emphysema and another 2 had occult PTX ( $P=0.000$ ). Regarding false-negative patient outcomes, 2 (of 7 false-negative results) were discharged with follow-up, 5 patients including



those with subcutaneous emphysema required tube thoracotomy and 4 out of those 5 patients were suspected to have pneumothorax on physical exam. Ultrasound was not helpful to diagnose hemothorax in 12 out of 21 CT confirmed patients. Besides, CT scan confirmed lung contusion in 43 patients but 18 cases were not diagnosed by bedside ultrasonography of whom, 8 individuals had definite concomitant pneumothorax. There were too few false-negative cases to quantitatively appraise its correlated determinant factors in univariable and multivariable (logistic regression) analysis. However, occult

pneumothorax and also the presence of concomitant hemothorax or lung contusion were more frequently seen among false-negative results than the state of clinical instability or the presence of multisystem injuries. Overall, 2 patients were not cooperative to undergo lung US and CT scan and were excluded. Only 3 patients acquired Glasgow Coma Scale under 9.

Furthermore, the diagnostic performance of ultrasound alone and positive physical exam in conjunction with ultrasound was assessed in comparison with CT scan and exhibited in Table 3.

There was no false-positive case in our study for traumatic lung injuries. The possible causes for false results of ultrasonography are shown in Table 4.

**Discussion**

The concrete indications for chest imaging have not yet been well established. There are some exclusion criteria for reducing CXR requests [10]. Here, we discussed the accuracy of chest PoCUS to delineate its uses in various settings to detect traumatic lung injuries simultaneously which is less discussed in previous studies. Furthermore, the false-negative results are discussed to ascertain the ambiguous situations when decision-making is critical to determine patient disposition in obviously stable or severely unstable patients.

**Table 3 Sensitivity, specificity, PPV, NPV and the accuracy and point-of-care ultrasound in the diagnosis of blunt chest injuries**

Type of injury	Diagnostic tool	Analysis	Point estimate	95% CI <sup>a</sup>
Pneumothorax	Sonography	Sensitivity, %	75.0	55.1–89.0
		Specificity, %	100	97.2–100
		PPV%	100	83.9–100
		NPV%	94.9	89.7–97.9
		Accuracy%	95.5	91.0–98.2
Hemothorax	Sonography	Sensitivity, %	45.4	24.4–67.8
		Specificity, %	100	97.3–100
		PPV%	100	69.2–100
		NPV%	91.8	86.2–95.7
		Accuracy%	92.4	87.0–96.0
Contusion	Sonography	Sensitivity, %	58.1	42.1–73.3
		Specificity, %	100	96.8–100
		PPV%	100	86.3–100
		NPV%	86.3	79.3–91.7
		Accuracy%	88.5	82.5–93.1
Pneumothorax, hemothorax and contusion	Physical exam and sonography	Sensitivity, %	91.5	81.3–97.2
		Specificity, %	90.8	83.3–95.7
		PPV	85.7	74.6–93.3
		NPV	94.7	88.0–98.3
		Accuracy	91.8	85.5–95.0

<sup>a</sup> Binomial exact calculation

**Table 4 Possible suggested causes for false-positive and negative results of bedside ultrasonography for the diagnosis of traumatic chest injuries**

Traumatic chest injury	Missed diagnoses	Causes
Pneumothorax	False positive	Achalasia Pleural adhesions Phrenic nerve palsy Pulmonary fibrosis Pulmonary atelectasis Cardiopulmonary arrest Congestive heart failure Right main bronchus intubation Subcutaneous chest emphysema Acute respiratory distress syndrome Significant concomitant lung contusion Bullous emphysema/pulmonary blebs Chronic obstructive pulmonary disease High positive end expiratory pressure-ventilated patients
	False negative	Lung remained in contact with the chest wall despite PTX Operator, machine or transducer conditions Cardiac movement with left lung sliding Subcutaneous chest emphysema Occult small pneumothorax
Hemothorax	False positive	Pleural effusion differential diagnoses
	False negative	Minimal amount hemothorax Subcutaneous emphysema
Lung contusion	False positive	Pulmonary fibrosis Cardiogenic pulmonary edema Acute respiratory distress syndrome
	False negative	Subcutaneous emphysema Inaccessible to ultrasound (retrosternal, paravertebral, etc.)

PTX pneumothorax

**Analysis of false-negative results and other shortcomings of lung US**

**Pneumothorax**

In this study, US sensitivity was lower though closely consistent with other studies suggesting that point-of-care ultrasonography is an acceptable modality to detect pneumothorax. Hyancinthe et al. retrospectively assessed the diagnostic accuracy of US and reported that it can detect PTX and contusion although it was not superior to CXR and chest exam [11]. Furthermore, a review article evaluated US sensitivity in blunt trauma patients and concluded that US is a sensitive screening test to assess PTX [12]. Ianniello et al. estimated the accuracy of US as the first diagnostic modality in major chest trauma patients and found a sensitivity, specificity, PPV and NPV of 77%, 99.8%, 98.5% and 97%, respectively [13]. Lichtenstein et al. showed that the absence of pleural sliding alone has the highest sensitivity (100%) and the presence of lung point provide 100% specificity to detect

pneumothorax although Markota has recognized the false-positive absence of pleural sliding due to high positive end expiratory airway pressure [14, 15].

Although the presence of subcutaneous emphysema can be a clue to suspect PTX, it is known to be disruptive to lung ultrasound, scattering US signals [16]. Occult PTX, defined as a very small PTX that can only be found by CT scan, may not be clinically significant [17]. It is not thoroughly evident whether ultrasonography may miss clinically unimportant pneumothorax. However, there are some data to suggest that ultrasound does not miss clinically important PTX [18].

Several studies have discussed the pitfalls of chest sonography to discover pneumothorax. Some researchers described cases with clinically significant pneumothorax who were not diagnosed by chest ultrasonography due to the uneven distribution of pneumothorax in the pleural cavity with pulmonary adhesions to the chest wall with or without lung contusion. Moreover, “double lung point

sign” as reported, may under or overestimate the PTX size by ultrasonography [4, 7, 19]. The extent of PTX was estimated by Blaivas et al. assessing the pleural sliding in several intercostal spaces and identified fair correlation with CT scan findings. They also evaluated pleural sliding by standard scan areas of “Power Doppler” to detect the fine pleural shimmering that may be difficult to detect due to resolution limitations [20, 21]. Some suggested differential diagnoses of dyspnea account for the most false-positive pneumothoraces in intensive care units including lung cancer, significant pulmonary infiltration or contusion, pleural or pulmonary adhesions and thoracic surgery, and in other settings such as achalasia [7, 22], many of which are grouped in Table 4.

### **Hemothorax**

US has provided high specificity despite lower sensitivity in our study compared with other studies in the assessment of hemothorax that can be due to small insignificant amounts of HTX. In this context, Hyacinthe et al. reported that missed hemothoraces can be due to minimal amounts of blood or those located posteriorly. They mentioned two missed cases suffering from concomitant subcutaneous emphysema and thus reported a modest accuracy for US to assess hemothorax, nearly similar to CXR [11]. Chest X-ray has been known to have low sensitivity in clinically significant injuries [23]. Besides, hemothorax can be falsely recognized in cases of pleural effusion of other causes. However, ultrasonography has shown appropriate sensitivity (92%) and specificity (100%) in the evaluation of hemothorax in trauma patients by Brooks et al. [24]. Also, Atkinson showed that US has sensitivity 92–100% and specificity 100% to detect hemothorax in intensive care settings [25]. Table 4 shows the possible suggested causes of false US results.

### **Pulmonary contusion**

The sensitivity of PoCUS was rather low in our study that may be caused by the inclusion of other lung injuries simultaneously. Leblanc D et al. showed that PoCUS can predict acute respiratory distress syndrome by detecting lung contusion in the first 72 h after trauma (receiving operator characteristic curve – area under the curve = 0.78 [95% CI 0.64–0.92]). The extent of contusion diagnosed by US had fair correlation with the corresponding clinical findings [26]. Trying to find various signs of lung contusion can improve the US diagnostic sensitivity. Some researchers reported high accuracy of the US in detecting alveolo-interstitial syndrome (AIS) (95.4%), although the diagnostic accuracy was estimated to be 65.9% in peripheral parenchymal lesions (PPL) [27]. Moreover, Helmy et al. assessed lung contusion by US to have 97.5% sensitivity, 90% specificity, PPV 97.5% and

NPV 90% detecting AIS and PPL images [4]. Lung contusion may be falsely diagnosed in patients with acute respiratory distress syndrome (ARDS) and cardiogenic pulmonary edema by ultrasonography. In other words, ultrasonography may not be decisive to definitely distinguish pulmonary contusion and ARDS as contusion may be a predisposing factor and a severity determinant for acute respiratory distress syndrome and further complications [28–31]. The mechanism, severity and the time elapsed from the injury may be clinically helpful [32]. Further studies can address this issue as the current evidence require larger sample sizes [33]. Contusion can be falsely interpreted in the presence of a large PTX due to the presence of a collapsed lung. In addition, the falsely missed lung injuries did not correlate with concomitant systemic injuries in poly-trauma patients if it serves as a distracting factor for the US operator and this issue was consistent with our findings. Also, subcutaneous emphysema and injury in zones not accessible by US may lead to underdiagnose contusion [11]. Soldati et al. reported two patients with documented pulmonary fibrosis among the missed lung contusions in ultrasonography [27].

Overall, considering several criteria for the detection of pneumothorax increase the accuracy of ultrasonography rather than each, including pleural sliding, seashore sign, and normal A and B lines. It seems that the false-negative results of ultrasonography for the diagnosis of traumatic pneumothorax can be compensated by the findings of positive physical examination especially chest wall pain, decreased lung sounds and subcutaneous emphysema. Nonetheless, ultrasonography alone did not show convincing results regarding the false-negative cases of hemothorax and contusion. The possible cause may be the small amounts of blood or pulmonary contusion which can be well-defined in CT scan. Of note, the clinical significance of the detection of small PTX, HTX or contusion is questionable. The beneficial information added by PoCUS to clinical findings serves as a valuable diagnostic guide in emergency situations. In hemodynamically unstable patients not responding to resuscitation, PoCUS can be a useful guide to discover the source of instability. Non-massive hemothorax and contusion can be evaluated and treated after life-threatening conditions are obviated even if missed in the very first critical patient presentation. Additionally, in perfectly stable patients for whom CT scan may be safely deferred, it is beneficial to apply PoCUS as a screening tool to discharge patients safely without the need for CT scan.

### **Recommendations and limitations**

The accuracy of bedside ultrasonography may vary between intercostal spaces in the diagnosis of pneumothorax. Clinically significant lung injuries were difficult



to follow as the subgroup analysis did not acquire sufficient sample size to reach desirable power. Occasionally, the small size of positive samples cause wide confidence intervals that can be further studied with larger sample sizes. This stratification of results based on the ISS, intubated patients, and decreased level of consciousness were not adequately powered and reliable.

The extent of lung contusion can be further studied regarding the hospital observation and long-term outcomes. Furthermore, the lung injuries leading to admission usually coincide with other traumatic injuries that also deserve close monitoring, hospital admissions, surgery or intubation and the differentiation between the exact leading causes was often difficult. In addition, there is a concern about a simple pneumothorax to expand and evolve into tension pneumothorax due to positive pressure ventilation and this issue can be addressed comparing US and CT scan in the future.

## Conclusion

The diagnostic performance of point-of-care ultrasonography was sensitive for blunt pneumothorax and can be beneficial for making disposition of stable patients and helpful in detecting PTX in unstable patients. POCUS was a moderately appropriate modality for diagnosing hemothorax and lung contusion compared to the gold standard, CT scan. Physical exam and ultrasonography augment the diagnostic accuracy of detecting traumatic lung injuries. Pitfalls and caveats should be considered to interpret lung ultrasound in specific situations regarding false-negative and false-positive instances.

## Abbreviations

PGY-3: Post-graduate year-3; PoCUS: Point-of-care ultrasonography; PPV: Positive-predictive value; NPV: Negative-predictive value; CI: Confidence interval; ATLS: Advanced trauma life support; PTX: Pneumothorax; HTX: Hemothorax; CT: Computed tomography; CXR: Chest X-ray; eFAST: Extended focused assessment with sonography in trauma; AIS: Alveolo-interstitial syndrome; PPL: Peripheral parenchymal lesions; US: Ultrasonography; ARDS: Acute respiratory distress syndrome.

## Acknowledgements

None.

## Authors' contributions

Concept and design: MB, SM, AJ, Data collection: SM, MB, AJ, Writing the article: MB, SM, AJ, AH, PZ, Critical revision of the article: MB, SM, AJ, AH, PZ. All authors read and approved the final manuscript.

## Funding

This study was funded by the Sina Trauma and Surgery Research Center of Sina Hospital (Grant No. 33,207-38-03-95).

## Availability of data and materials

None.

## Ethics approval and consent to participate

The ethics of this report have been approved by the Tehran University of Medical Sciences Institutional Review Board. This Research involving human participants meets the declaration of Helsinki principles.

## Consent for publication

Written consent was obtained from the patients.

## Competing interests

The authors declare that they have no competing interests.

## Author details

<sup>1</sup> Emergency Department, Shariati Hospital, Tehran University of Medical Sciences, Tehran, Iran. <sup>2</sup> Tehran University of Medical Sciences, Tehran, Iran. <sup>3</sup> Knowledge Utilization Research Center, Tehran University of Medical Sciences, Tehran, Iran. <sup>4</sup> Trust ST1/2 in Emergency Medicine, Mid Essex NHS Trust Broomfield Hospital, Chelmsford, Essex, UK. <sup>5</sup> Department of Emergency Medicine, Sina Trauma and Surgery Research Center, Sina Hospital, Tehran University of Medical Sciences, Tehran, Iran.

Received: 29 January 2020 Accepted: 3 July 2020

Published online: 04 August 2020

## References

- Kline JP, Dionisio D, Sullivan K, Early T, Wolf J, Kline D (2013) Detection of pneumothorax with ultrasound. *AANA J*. 81:265–271
- Broderick SR (2013) Hemothorax: etiology, diagnosis, and management. *Thorac Surg Clin*. 23(89–96):6–7
- Ludwig C, Koryllos A (2017) Management of chest trauma. *J Thorac Dis*. 9:172
- Helmy S, Beshay B, Abdel Hady M, Mansour A (2015) Role of chest ultrasonography in the diagnosis of lung contusion. *Egypt J Chest Diseases and Tuberc*. 64:469–475
- Ianniello S, Piccolo CL, Trinci M, Ajmone Cat CA, Miele V (2019) Extended-FAST plus MDCT in pneumothorax diagnosis of major trauma: time to revisit ATLS imaging approach? *J Ultrasound* 22:461–469
- Rodriguez RM, Anglin D, Langdorf MI et al (2013) NEXUS chest: validation of a decision instrument for selective chest imaging in blunt trauma. *JAMA Surg*. 148:940–946
- Kaya S, Cevik AA, Acar N, Doner E, Sivrikoz C, Ozkan R (2015) A study on the evaluation of pneumothorax by imaging methods in patients presenting to the emergency department for blunt thoracic trauma. *Ulusal travma ve acil cerrahi dergisi* 21:366–372
- Baker SP, Oneill B, Haddon WJ, Long WB (1974) The injury severity score: a method for describing patients with multiple injuries and evaluating emergency care. *J Trauma Acute Care Surg*. 14:187–196
- Tohira H, Jacobs I, Mountain D, Gibson N, Yeo A (2012) Systematic review of predictive performance of injury severity scoring tools. *Scand J Trauma Resusc Emerg Med*. 20:63
- Forouzanfar MM, Safari S, Niazazari M et al (2014) Clinical decision rule to prevent unnecessary chest X-ray in patients with blunt multiple traumas. *Emerg Med Australas*. 26:561–566
- Hyacinthe AC, Broux C, Francony G et al (2012) Diagnostic accuracy of ultrasonography in the acute assessment of common thoracic lesions after trauma. *Chest* 141:1177–1183
- Wilkerson RG, Stone MB (2010) Sensitivity of bedside ultrasound and supine anteroposterior chest radiographs for the identification of pneumothorax after blunt trauma. *Acad Emerg Med* 17:11–17
- Ianniello S, Di Giacomo V, Sessa B, Miele V (2014) First-line sonographic diagnosis of pneumothorax in major trauma: accuracy of e-FAST and comparison with multidetector computed tomography. *Radiol Med (Torino)* 119:674–680
- Markota A, Golub J, Stozar A et al (2016) Absence of lung sliding is not a reliable sign of pneumothorax in patients with high positive end-expiratory pressure. *Am J Emerg Med* 34:2034–2036
- Lichtenstein DA, Meziere G, Lascols N et al (2005) Ultrasound diagnosis of occult pneumothorax. *Crit Care Med* 33:1231–1238

16. Kubodera T, Adachi YU, Hatano T, Ejima T, Numaguchi A, Matsuda N (2013) Subcutaneous emphysema and ultrasound sonography. *J Intensive care*. 1:8
17. Yadav K, Jalili M, Zehtabchi S (2010) Management of traumatic occult pneumothorax. *Resuscitation*. 81:1063–1068
18. Helland G, Gaspari R, Licciardo S et al (2016) Comparison of four views to single-view ultrasound protocols to identify clinically significant pneumothorax. *Acad Emerg Med* 23:1170–1175
19. Aspler A, Stone MB (2014) Pitfalls in the ultrasound diagnosis of pneumothorax: the authors respond. *Am J Emerg Med* 32:1127
20. Blaivas M, Lyon M, Duggal S (2005) A prospective comparison of supine chest radiography and bedside ultrasound for the diagnosis of traumatic pneumothorax. *Acad Emerg Med* 12:844–849
21. Cunningham J, Kirkpatrick AW, Nicolaou S et al (2002) Enhanced recognition of “lung sliding” with power color Doppler imaging in the diagnosis of pneumothorax. *J Trauma* 52:769–771
22. Jahanshir AH, Seyed Hosseini J, Bahreini M (2014) Misinterpretation of achalasia as a pneumothorax in transthoracic ultrasonography. *J Emerg Med Case Rep*. 5:2149–9934
23. Ojaghi Haghighi SH, Adimi I, Shams Vahdati S, Sarkhoshi Khiavi R (2014) Ultrasonographic diagnosis of suspected hemopneumothorax in trauma patients. *Trauma Mon*. 19:e17498
24. Brooks A, Davies B, Smethhurst M, Connolly J (2004) Emergency ultrasound in the acute assessment of haemothorax. *Emerg Med J*. 21:44–46
25. Atkinson P, Milne J, Loubani O, Verheul G (2012) The V-line: a sonographic aid for the confirmation of pleural fluid. *Crit Ultrasound J*. 4:19
26. Leblanc D, Bouvet C, Degiovanni F et al (2014) Early lung ultrasonography predicts the occurrence of acute respiratory distress syndrome in blunt trauma patients. *Intensive Care Med* 40:1468–1474
27. Soldati G, Testa A, Silva FR, Carbone L, Portale G, Silveri NG (2006) Chest ultrasonography in lung contusion. *Chest* 130:533–538
28. Watkins TR, Nathens AB, Cooke CR et al (2012) Acute respiratory distress syndrome after trauma: development and validation of a predictive model. *Crit Care Med* 40:2295–2303
29. Miller PR, Croce MA, Bee TK et al (2001) ARDS after pulmonary contusion: accurate measurement of contusion volume identifies high-risk patients. *J Trauma* 51:223–228
30. Bakowitz M, Bruns B, McCunn M (2012) Acute lung injury and the acute respiratory distress syndrome in the injured patient. *Scand J Trauma Resus Emerg Med*. 20:54
31. Haider T, Halat G, Heinz T, Hajdu S, Negrin LL (2017) Thoracic trauma and acute respiratory distress syndrome in polytraumatized patients: a retrospective analysis. *Minerva Anesthesiol* 83:1026–1033
32. Copetti R, Soldati G, Copetti P (2008) Chest sonography: a useful tool to differentiate acute cardiogenic pulmonary edema from acute respiratory distress syndrome. *Cardiovasc Ultrasound*. 6:16
33. Daabis R, Banawan L, Rabea A, Elnakedy A, Sadek A (2014) Relevance of chest sonography in the diagnosis of acute respiratory failure: comparison with current diagnostic tools in intensive care units. *Egypt J Chest Dis Tuberc*. 63:979–985

### Publisher's Note

Springer Nature remains neutral with regard to jurisdictional claims in published maps and institutional affiliations.

Submit your manuscript to a SpringerOpen<sup>®</sup> journal and benefit from:

- Convenient online submission
- Rigorous peer review
- Open access: articles freely available online
- High visibility within the field
- Retaining the copyright to your article

---

Submit your next manuscript at ► [springeropen.com](https://www.springeropen.com)

---