

EDITORIAL

Open Access



The challenge of ventilator-associated pneumonia diagnosis in COVID-19 patients

Bruno François^{1*} , Pierre-François Laterre², Charles-Edouard Luyt³ and Jean Chastre³

While different phenotypes have been evidenced in ICU COVID-19 pneumonia [1], most patients meet ARDS Berlin definition associating bilateral radiologic infiltrates with severe hypoxemia. COVID-19 patients frequently require prolonged invasive mechanical ventilation (MV) including prone positioning, heavy sedation, and muscle blockers for several weeks. In addition, there is clear evidence of prolonged immunosuppression including deep lymphopenia [2]. This accounts for a high risk of secondary hospital-acquired infections, primarily ventilator-associated pneumonia (VAP). The diagnosis of ventilator-associated infections remains challenging due to major definition heterogeneity of multiple clinical entities, and no consensus has yet been reached on appropriate diagnostic strategies for VAP. Irrespective of the definition, accurate diagnosis of VAP requires clinical signs of infection, microbiological documentation, and chest X-ray findings, even if the latter may be difficult to interpret due to preexisting parenchymal injury [3].

The clinical presentation of COVID-19 pneumonia is relatively homogenous and commonly associates high fever, hyperleukocytosis, severe hypoxemia, extensive bilateral radiologic infiltrates, and biological inflammatory syndrome. Since this presentation is shared with VAP, traditional diagnostic criteria for VAP are not valid in the critical COVID-19 population. Similarly, the Clinical Pulmonary Infection Score (CPIS), assessing body temperature, tracheal secretions, radiologic infiltrate, hyperleukocytosis, and PaO₂/FiO₂, has little additional value since its components overlap with those of COVID-19 pneumonia in MV patients [4]. In our experience, more than 90% of COVID-19 patients had qualifying CPIS > 6 on day 2 following ICU admission in the absence of any documented VAP or co-infection. Accordingly, the microbiological documentation from deep respiratory

secretions currently remains the sole criterion to support VAP diagnosis in COVID-19 patients. Fiberoptic bronchoalveolar lavage is hardly feasible in severely hypoxemic COVID-19 patients due to the inherent risk of worsening hypoxemia. Hence, many ICU perform less invasive endotracheal aspirate (ETA) with quantitative or semi-quantitative cultures, even if less reliable for deciding whether to institute antibiotic treatment or not. It is near impossible to distinguish COVID-19-associated ARDS with asymptomatic bacterial colonization from a true VAP based solely on traditional threshold values (i.e., 10⁵ CFU/ml for ETA). Interestingly, despite heavy bacterial load, white blood cell count in bronchial secretions appears very low in most COVID-19 patients developing a superinfection. Accurate identification of COVID-19 patients who require treatment with new antibiotics for a clinically relevant bacterial superinfection is difficult, leading to overuse of broad-spectrum antibiotics despite the absence of supporting data in the literature [5]. As a result, most ventilated COVID-19 patients with ARDS are treated with prophylactic antibiotics to prevent from undocumented VAP. Such a strategy is at high risk of selection of multi-drug-resistant bacteria or even fungi in patients expected to remain under invasive MV for a long period. The COVID-19 pandemic and the severity of its clinical presentation cannot justify “emotional” and blind antibiotic therapy on the sole argument that traditional VAP definition is invalid. Specific COVID-19 antimicrobial stewardship and guidelines are required to avoid this detrimental approach, considering that within the first 10 days, most of the pathogens documented in the lung are from the community with minimal resistant profile (unpublished data). While it is reasonable to initiate antibiotics in patients with suspected VAP and hemodynamic instability or severe hypoxemia following European guidelines [6] regardless of clinical certainty, a more conservative approach may be beneficial for stable patients (Fig. 1). It remains to be seen whether routine assessment tools such as daily variations of CPIS score,

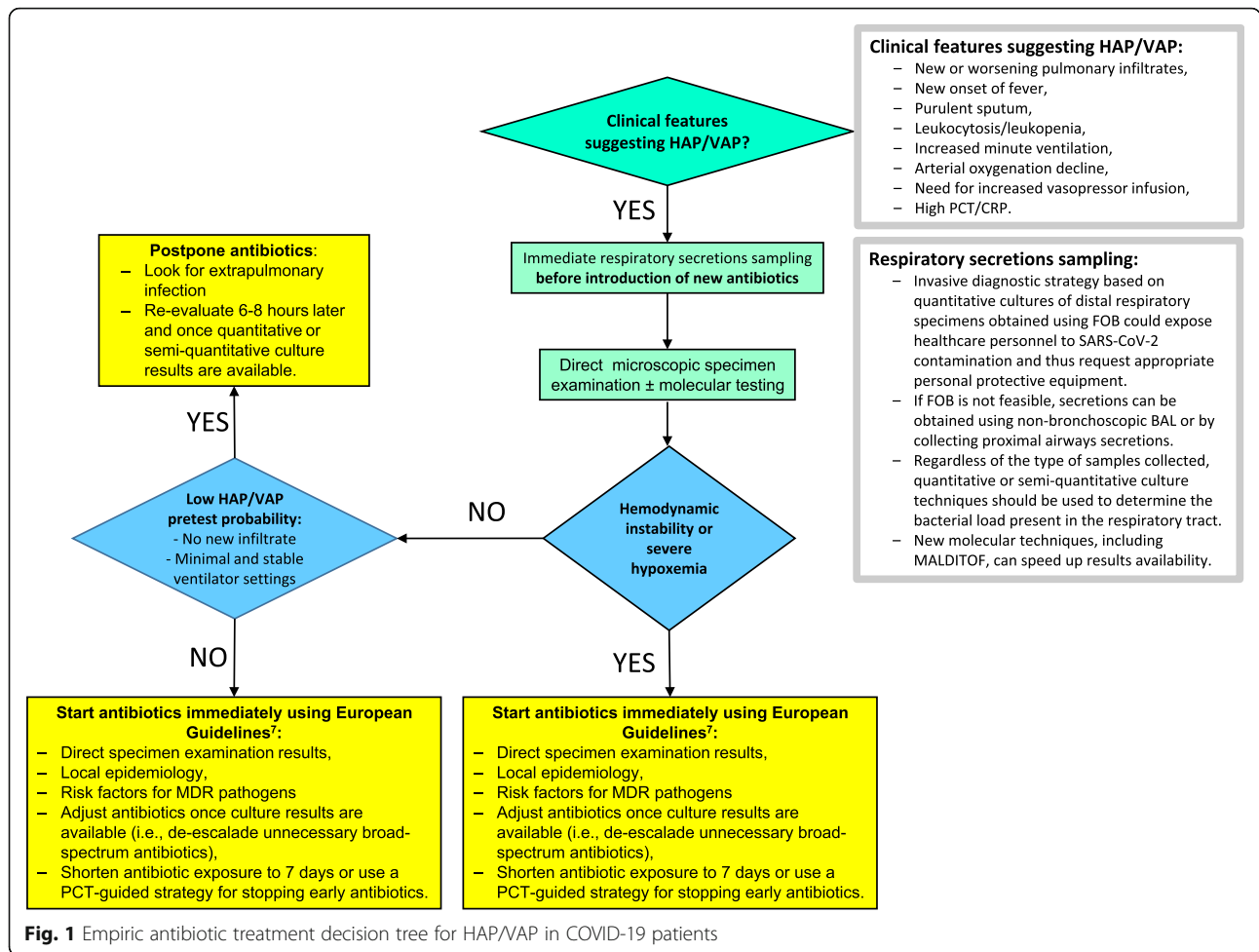
* Correspondence: b.francois@unilim.fr

¹Intensive Care Unit and Inserm CIC1435 & UMR1092, CHU Dupuytren, Limoges, France

Full list of author information is available at the end of the article



© The Author(s). 2020 **Open Access** This article is licensed under a Creative Commons Attribution 4.0 International License, which permits use, sharing, adaptation, distribution and reproduction in any medium or format, as long as you give appropriate credit to the original author(s) and the source, provide a link to the Creative Commons licence, and indicate if changes were made. The images or other third party material in this article are included in the article's Creative Commons licence, unless indicated otherwise in a credit line to the material. If material is not included in the article's Creative Commons licence and your intended use is not permitted by statutory regulation or exceeds the permitted use, you will need to obtain permission directly from the copyright holder. To view a copy of this licence, visit <http://creativecommons.org/licenses/by/4.0/>. The Creative Commons Public Domain Dedication waiver (<http://creativecommons.org/publicdomain/zero/1.0/>) applies to the data made available in this article, unless otherwise stated in a credit line to the data.



serial viral load aspirates, new molecular techniques, or lung ultrasonography will help improving decisions regarding antibiotic treatment in such a clinically complex population. Diagnostic algorithms using a PCT-guided strategy for stopping early empiric antimicrobial treatment [7] or pathogen quantification trends could be alternatively tested for VAP diagnosis. Overall, studies in this field are urgently needed.

Abbreviations

ARDS: Acute respiratory distress syndrome; CPIS: Clinical Pulmonary Infection Score; ETA: Endotracheal aspirate; ICU: Intensive care unit; MV: Mechanical ventilation; PCT: Procalcitonin; VAP: Ventilator-associated pneumonia; FOB: Fiberoptic bronchoscopy

Acknowledgements

NA

Authors' contributions

BF, PFL, CEL, and JC wrote the manuscript. They all reviewed and approved the final version.

Funding

None

Availability of data and materials

NA

Ethics approval and consent to participate

NA

Consent for publication

NA

Competing interests

None

Author details

¹Intensive Care Unit and Inserm CIC1435 & UMR1092, CHU Dupuytren, Limoges, France. ²Intensive Care Unit, St Luc University Hospital, Université Catholique de Louvain, Brussels, Belgium. ³Intensive Care Unit, Hôpital La Pitié-Salpêtrière, APHP-Sorbonne Université, Paris, France.

Received: 9 May 2020 Accepted: 20 May 2020

Published online: 05 June 2020

References

- Gattinoni L, Chiumello D, Rossi S. COVID-19 pneumonia: ARDS or not? *Crit Care*. 2020;24(1):154.
- Tan L, Wang Q, Zhang D, Ding J, Huang Q, Tang YQ, Wang Q, Miao H. Lymphopenia predicts disease severity of COVID-19: a descriptive and predictive study. *Signal Transduct Target Ther*. 2020;5:33.
- Chastre J, Luyt CE. Does this patient have VAP? *Intensive Care Med*. 2016; 42(7):1159–63.
- Schurink CAM, Nieuwenhoven CAV, Jacobs JA, Rozenberg-Arska M, Joore HCA, Buskens E, Hoepelman AIM, Bonten MJM. Clinical pulmonary infection

score for ventilator-associated pneumonia: accuracy and inter-observer variability. *Intensive Care Med.* 2004;30(2):217–24.

5. Rawson TM, Moore LSP, Zhu N, Ranganathan N, Skolimowska K, Gilchrist M, Satta G, Cooke G, Holmes A. Bacterial and fungal co-infection in individuals with coronavirus: a rapid review to support COVID-19 antimicrobial prescribing. *Clin Infect Dis.* 2020. <https://doi.org/10.1093/cid/ciaa530>.
6. Torres A, Niederman MS, Chastre J, Ewig S, Fernandez-Vandellos P, Hanberger H, Kollef M, Li Bassi G, Luna CM, Martin-Loeches I, Paiva JA, Read RC, Rigau D, Timsit JF, Welte T, Wunderink R. International ERS/ESICM/ESCMID/ALAT guidelines for the management of hospital-acquired pneumonia and ventilator-associated pneumonia: Guidelines for the management of hospital-acquired pneumonia (HAP)/ventilator-associated pneumonia (VAP) of the European Respiratory Society (ERS), European Society of Intensive Care Medicine (ESICM), European Society of Clinical Microbiology and Infectious Diseases (ESCMID) and Asociación Latinoamericana del Tórax (ALAT). *Eur Respir J.* 2017;50(3). doi: <https://doi.org/10.1183/13993003.00582-2017>.
7. Brechot N, Hekimian G, Chastre J, Luyt CE. Procalcitonin to guide antibiotic therapy in the ICU. *Int J Antimicrob Agents.* 2015;46:S19–24.

Publisher's Note

Springer Nature remains neutral with regard to jurisdictional claims in published maps and institutional affiliations.