

RESEARCH ARTICLE

Open Access



# Single volar locking plating for the intra- and extra-articular distal radius fractures with dorsal metaphyseal comminution

Xue-yang Gui<sup>1†</sup>, Zhao-hui Cheng<sup>2†</sup>, Hong-fei Shi<sup>2\*</sup>, Yi-xin Chen<sup>1</sup>, Jin Xiong<sup>1</sup>, Jun-fei Wang<sup>1</sup>, Xu-sheng Qiu<sup>1</sup> and Zi-tao Zhang<sup>1</sup>

## Abstract

**Background:** Volar locking plating remains a popular method for the surgical management of distal radius fractures. Dorsal metaphyseal comminution (DMC) is a common fracture pattern which weakens the stability during fracture fixation. In this study, we aimed to compare the radiographic and functional outcome of the intra- and extra-articular distal radius fractures with DMC following single volar locking plate fixation.

**Materials and methods:** Patients suffered from a distal radius fracture with DMC were reviewed in the clinical database of the authors' institution between Jan 2016 and Jan 2020. The included patients were classified into the extra-articular (A3) group or the intra-articular (C2 and C3) group according to the AO/OTA system. The radiological parameters, wrist range of motion, and functional outcomes were evaluated following open reduction and volar locking plate fixation.

**Results:** A total of 130 patients were included in this study with a mean follow-up length of 17.2 months. Compared with the A3 fracture group, no significant fracture re-implacement or reduced wrist ROMs was observed in the C2 fractures after 12-month's follow-up. However, significant decreased volar tilt ( $P = 0.003$ ) as well as the extension/flexion ROMs were observed in the C3 fractures comparing to the A3 fractures. Most of the patients achieved an excellent ( $n = 75$ ) or good ( $n = 51$ ) Gartland and Wesley wrist score. Four patients with C3 fractures resulted in a fair functional outcome due to a significant loss of volar tilt during follow-up.

**Conclusions:** The single volar locking plate fixation provided sufficient stability for distal radius fractures with DMC, and resulted in similar radiological and functional outcomes in the intra-articular distal radius fractures with a simple articular component (C2 fractures) and those in the extra-articular fractures. Considering the intra-articular fractures with multifragmentary articular component (C3 fracture), despite of the subsequent loss of volar tilt, the majority of the patients achieved good to excellent wrist function following single volar locking plating.

**Trial registration.** This study has been registered on the ClinicalTrials.gov.

**Keywords:** distal radius fracture, comminution, locking plate, stability, intra-articular fracture

\* Correspondence: [michaelshi@nju.edu.cn](mailto:michaelshi@nju.edu.cn)

<sup>†</sup>Xue-yang Gui and Zhao-hui Cheng contributed equally to this work.

<sup>2</sup>Nanjing Drum Tower Hospital Clinical College of Nanjing Medical University, Nanjing, China

Full list of author information is available at the end of the article



## Introduction

Distal radial fractures are common orthopedic injuries comprising 15% of all extremity fractures [1]. Though The K-wire pinning and minimally invasive system [2], external fixation [3] and dorsal plating [4] are considered as reasonable fixation options for the distal radial fractures, volar plating remains the most popular fixation techniques because of the safe and straightforward surgical approach, the low rate of complication, and the rapid return to function recovery [5]. Dorsal metaphyseal comminution (DMC) is the most common fracture pattern observed in 60% of the distal radius fractures [6]. It is well-recognized that DMC weakens the stability of the distal radius and leads to higher rates of secondary displacement when managed conservatively [6–9]. Despite the improved strength characteristics compared with the traditional nonlocking plates, the stability provided by single volar fixed-angled locking plating has also been questioned in this fracture pattern. In vitro, biomechanical studies have testified the stability of volar locking plate in extra-articular distal radius fracture models with DMC, and an equivalent [10] or slightly less stability [4, 11] can be provide compared with dorsal plating. However, the efficacy of single volar locking plating in the intra-articular distal radius fracture with DMC has not yet been adequately analyzed in biomechanical or clinical studies. The purpose of the present study is to analyze the radiographic and functional outcome of the intra- and extra-articular distal radius fractures with DMC treated with single volar locking plating.

## Materials and methods

We retrospectively reviewed the patients with distal radius fractures who received open reduction and internal fixation in the authors' institution between Jan 2016 and Jan 2020. The study respects national ethical standards and the Helsinki Convention. The study protocol was approved by our institution's Medical Ethics Committee and the informed consent was obtained.

Patients were enrolled into this study according to the following inclusion criteria: 1) the distal radius fracture was fixed with a single volar locking plate; 2) DMC was confirmed in the preoperative radiographs and computed tomographic (CT) images according to the definition in literature [12]; 3) patients were followed for a minimum of 1-year postoperatively. Exclusion criteria were: open fractures, delayed fractures, neurovascular injuries, additional ipsilateral upper extremity fractures, or the fractures fixed with additional dorsal or radial plates. The included patients were classified into the extra-articular (A3) group or the intra-articular (C2 and C3) group according to the AO/OTA system [13].

All patients were operated on by two senior attending surgeons (JX and HFS). During operation, the fracture

was accessed through the modified volar Henry approach. Briefly, the skin was incised along the course of the flexor carpi radialis (FCR) tendon. The sheath of the FCR was opened and the FCR tendon and the flexor pollicis longus tendon were retracted ulnarly. The radial artery was carefully protected. The pronator quadratus was incised longitudinally and elevated to expose the distal radius. For extra-articular fractures, a applied longitudinal traction and reduced the fracture under direct visualization. For intra-articular fractures, either the radial column or the palmoulnar fragment could be reduced firstly to provide reference for the radial height and radial inclination. Dorsal ulnar fragments were then reduced to restore joint congruency and volar tilt. The joy-stick technique with percutaneous pinning from the dorsal side was used to facilitate reduction of the dorsal fragment if necessary [14]. In case the dorsal fragment could not be adequately reduced percutaneously, an additional dorsal incision immediately ulnar to the Lister tubercle was performed to facilitate fracture reduction. Following incision of the extensor retinaculum and mobilization of the extensor pollicis longus tendon (EPL), the third and the fourth extensor compartment was opened. The dorsal fracture fragment was then reduced under direct visualization. After temporary K-wire fixation, a satisfactory reduction of the extra- and intra-articular fracture was checked using intraoperative C-arm according to the radiographic guidelines described in literature [15]. The fracture was then fixed with the 2.4 mm volar locking plate system (Depuy-Synthes, Oberdorf, Switzerland). The distal edge of the plate was carefully positioned proximal to the watershed line to avoid prominence in this area [16]. Multiple fluoroscopic views were checked to avoid intraarticular screw penetration and dorsal screw prominence [17]. The stability of the distal radioulnar joint (DRUJ) was routinely checked and compared with the contralateral side. Cast immobilization, radioulnar pinning, or ulnar styloid ORIF was performed based on the instability of DRUJ according to the established protocol [18, 19]. Clinical and radiological assessments were performed at 6 weeks, 3 months, 6 months, and 12 months postoperatively according to our routine follow-up regime [19].

We measured four radiological parameters: radial inclination, volar tilt, radial height, and ulnar variance on the Picture Archiving and Communication System (PACS) according as described previously [20]. The fracture re-displacement (FRD), defined as the absolute value of the difference between the postoperative parameters and those taken at the 12-month follow-up. The values were calculated by three different observers, and the final value reported was the mean among the three values reported. Clinical assessment and complications of included patients were recorded during follow-up.

Patient wrist range of motion (ROMs), pain, and functional outcomes were evaluated according to the Disabilities of the Arm, Shoulder and Hand (DASH) score and the Gartland and Werley score at 12 months postoperatively.

The primary outcome is the maintenance of radiological reduction. The secondary outcome is the reaching of the ROMs recovery (compared with the contralateral side). ROMs on the affected side was calculated in percentage compared with the contralateral side. The fracture healing rate and the presence of complication were also assessed.

SPSS software (SPSS version 18.0, SPSS, IBM Inc., Armonk, NY, USA) was used for all statistical analyses. Data were reported as percentage and frequency for categorical variables. The population normality is checked by K-S test and S-W test. When the variables obey a normal distribution, they were reported as mean ± standard deviation (SD). Differences in the radiological parameters between the postoperative values and those taken at the 12-month follow-up were compared using paired-samples t test. FRD was calculated and compared between the intra- and extra-articular distal radius fractures using independent t test. Pearson's chi-squared test was used for nonparametric data. For all statistical tests, P<0.05 was considered statistically significant.

**Results**

A total of 173 distal radius fracture patients treated with volar locking plating between Jan 2016 and Jan 2020 were eligible for inclusion in this study. All patients were operated within 48h from the trauma. Forty-three patients were excluded because of incomplete data settings, open fractures, neurovascular injuries, or additional ipsilateral upper extremity injuries. Finally, 130 patients (58 males, 72 females) were included in the study. According to the AO/OTA system, the patients were classified into A3 (41 cases), C2 (56 cases), or C3 (33 cases) fractures. The mean length of follow-up was 17.2 (12-

24) months. The demographics of the patients were summarized in Table 1.

Fracture healing was achieved in all patients during follow-up. The union of bone was observed at 6 weeks postoperatively in 97 patients, and at 3 months in the other 33 patients. Three patients had a superficial wound infection postoperatively. The incision healed smoothly after dressing changes and antibiotic treatment. No serious complication, such as nerve injury, tendon rupture, or implant failure was recorded during follow-up.

The measured radiological parameters were shown in Table 2. No statistically significant change in volar tilt, radial inclination, radial height, or ulnar variance was observed between the immediate postoperative and 12-month follow-up measurements in either of the A3 or the C2 fracture group. However, a significant change of the volar tilt was observed in the C3 fracture group comparing the immediate postoperative measurements with the 12-month follow-up data (P = 0.037). Comparing the FRD calculated on the C3 fractures to the A3 ones, a significant decrease of the volar tilt was observed in C3 fractures than in A3 (P = 0.003) fractures (Table 3). The difference between the C2 and A3 fractures, however, did not achieve statistical significance (P = 0.540). Considering the radial height, the ulnar variance, and the radial inclination, no significant difference of FRD was observed between the intra-articular and the extra-articular fractures (Table 3).

**Table 1** Patient demographics in different groups

	AO/OTA A3 (n = 41)	AO/OTA C2 (n = 56)	AO/OTA C3 (n = 33)	P value
Age (years)	58.5 ± 12.3	60.2 ± 11.8	63.1 ± 12.6	0.487 <sup>a</sup>
Gender				
Female	22	32	18	0.519 <sup>b</sup>
Male	19	24	15	
Side				
Dominant	21	29	19	0.144 <sup>b</sup>
Nondominant	20	27	14	

<sup>a</sup>One-way ANOVA test.  
<sup>b</sup>Pearson's chi-squared test

**Table 2** Radiological parameters measured in different groups (Mean ± SD)

	Postoperatively	At 12 months	P value <sup>t</sup>
AO/OTA A3 fractures			
RI (°)	20.52 ± 4.08	20.16 ± 4.14	0.548
VT (°)	5.06 ± 3.36	4.83 ± 3.37	0.455
UV (mm)	0.19 ± 0.32	0.22 ± 0.27	0.231
RH (mm)	9.54 ± 4.18	9.97 ± 5.08	0.461
AO/OTA C2 fractures			
RI (°)	19.70 ± 4.19	19.33 ± 4.31	0.122
VT (°)	3.21 ± 4.46	3.72 ± 4.04	0.260
UV (mm)	0.19 ± 0.29	0.21 ± 0.33	0.441
RH (mm)	9.50 ± 4.17	9.91 ± 5.37	0.304
AO/OTA C3 fractures			
RI (°)	19.24 ± 4.34	19.73 ± 4.77	0.302
VT (°)	3.32 ± 5.42	2.06 ± 6.48	0.037*
UV (mm)	0.21 ± 0.37	0.25 ± 0.40	0.185
RH (mm)	9.15 ± 5.26	9.51 ± 5.75	0.237

RH radial height, RI radial inclination, VT volar tilt, UV ulnar variance  
<sup>t</sup> Paired samples t test  
\* P < 0.05

**Table 3** Fracture re-displacement (FRD) calculated in different fracture groups (Mean ± SD)

FRD	A3	C2	P value†	C3	P value‡
RI (°)	0.36 ± 0.41	0.37 ± 0.39	0.525	0.41 ± 0.33	0.571
VT (°)	0.23 ± 0.16	0.21 ± 0.61	0.540	0.16 ± 0.90	0.003*
UV (mm)	0.03 ± 0.32	0.04 ± 0.27	0.868	0.04 ± 0.31	0.892
RH (mm)	0.57 ± 0.41	0.59 ± 0.49	0.832	0.64 ± 0.47	0.496

† independent-samples t test, comparison between the A3 and C2 groups  
 ‡ independent-samples t test, comparison between the A3 and C3 groups  
 \* P < 0.05.

At 12 months postoperatively, the mean ROMs of the wrist were shown in Table 4. All of the patients achieved more than 75% recovery of extension/flexion and more than 95% recovery of pronation/supination in the injured wrist compared to the contralateral normal wrist. All of the patients achieved adequate functional ROMs according to Ryu’s standard [21]. Considering the pronation/supination ROM, no significant difference was observed between the intra-articular (either C2 or C3) fractures and the extra-articular (A3) fractures. However, the C3 fracture group presented significantly decreased extension/flexion ROMs compared with the A3 fracture group. The mean DASH score was 9.8 (0-40) at 12 months follow-up. Most patients in our study achieved an excellent (n = 75) or good (n = 51) Gartland and

Werley wrist score. Four patients with C3 fractures resulted in a fair functional outcome due to a significant loss of volar tilt during follow-up (Figs. 1, 2, 3 and 4).

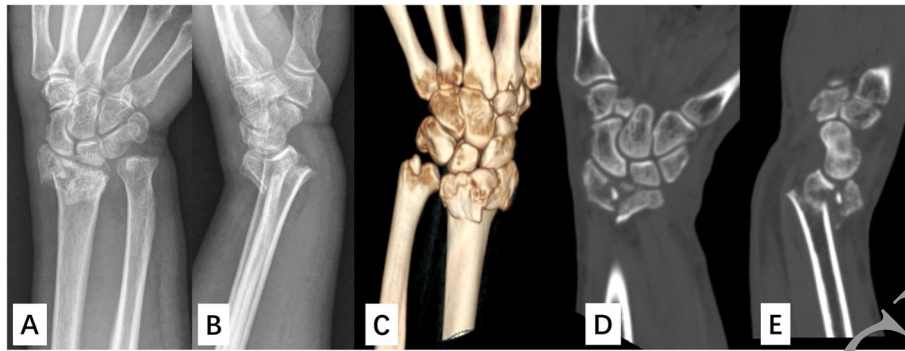
**Discussion**

Whether the single volar locking plate fixation could provide sufficient stability in the intraarticular distal radius fractures with DMC was not elaborated in literature. Previously, biomechanical studies using extra-articular fracture models have confirmed that the single volar locking plating could provide an equivalent or slightly less stability compared with dorsal plating in distal radius fractures with DMC [4, 10, 11]. In clinical studies, Guillou reported 10 patients with a dorsally comminuted extra-articular distal radius fracture fixed with volar locking plate. Most (5.4%) of the patients maintained the stability without secondary displacement at 6 months postoperatively [22]. Considering the intra-articular fractures with DMC, no straightforward biomechanical studies could be found in literature. In clinical studies, Khamaisy compared the outcome of volar locking plating for the dorsally comminuted (DC) and the dorsally intact (DI) distal radius fractures [23]. The vast majority of the cases included in Khamaisy’s study were AO/OTA type C fractures, and a satisfied fracture reduction was preserved in the DC fractures compared to the DI ones with no significant difference observed in

**Table 4.** Comparison of the range of motion between the Injured and the Contralateral normal wrist at 12 months postoperatively (Mean ± SD)

Variables	Injured Side	Contralateral Side	% of contralateral wrist	P value†
AO/OTA A3 fractures (°)				
Extension	81.81 ± 9.71	89.22 ± 9.90	91.7	
Flexion	80.97 ± 9.79	88.78 ± 9.65	91.2	
Pronation	82.20 ± 7.32	83.46 ± 6.93	98.4	
Supination	82.37 ± 5.48	83.51 ± 5.56	98.7	
AO/OTA C2 fractures (°)				
Extension	75.48 ± 11.40	89.39 ± 9.51	84.4	0.095
Flexion	73.41 ± 10.20	88.34 ± 9.36	83.1	0.179
Pronation	81.03 ± 6.44	83.23 ± 7.22	97.3	0.560
Supination	81.56 ± 5.27	83.97 ± 6.13	97.1	0.567
AO/OTA C3 fractures (°)				
Extension	72.51 ± 17.39	88.36 ± 7.51	79.8	0.044*
Flexion	69.57 ± 19.89	88.97 ± 7.35	78.2	0.035*
Pronation	79.84 ± 8.75	82.49 ± 6.56	96.7	0.311
Supination	80.69 ± 5.96	83.18 ± 5.64	96.9	0.560

† Pearson’s chi-squared test, compared with the A3 fracture group  
 \* P < 0.05



**Fig. 1** Case 1. A 69-year-old woman presented with an AO/OTA C3 distal radius fracture with dorsal metaphyseal comminution. **A, B** Preoperative anteroposterior and lateral view radiographs. **C**, Three-dimensional computed tomographic image shows the dorsal metaphyseal comminution. **D, E**: Two-dimensional computed tomographic images confirm the multi-fragmentary articular components

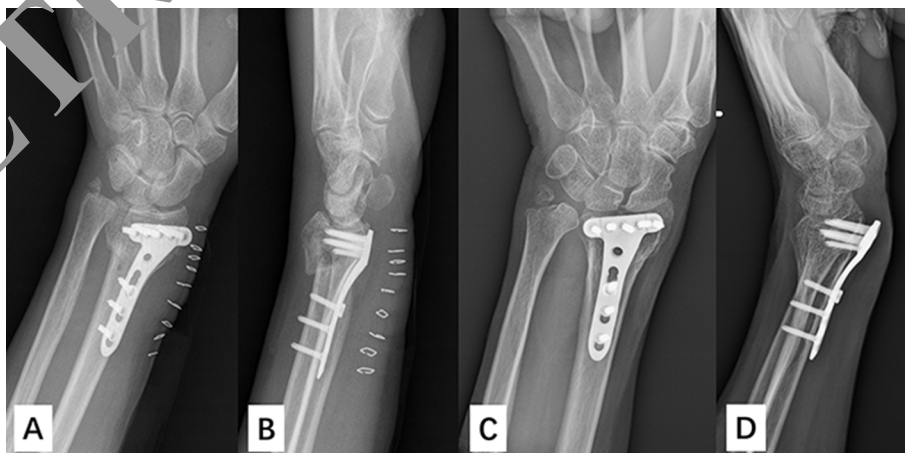
radial inclination, volar tilt, and radial length. These results implied that volar locking plating could provide sufficient stability for the intra-articular fractures despite of the occurrence of DMC. However, the authors didn't compare the outcome among different sub-types of intra-articular fractures due to limited sample size.

In this study, we analyzed the efficacy of volar locking plating in the distal radius fractures with DMC. Compared with the A3 fractures, no significant fracture re-displacement or reduced wrist ROMs was observed in the intra-articular distal radius fractures with a simple articular component (C2 fractures). However, a significant decrease of the volar tilt as well as the extension, flexion ROMs were observed in the intra-articular fractures with multi-fragmentary articular component (C3 fracture) during follow-up.

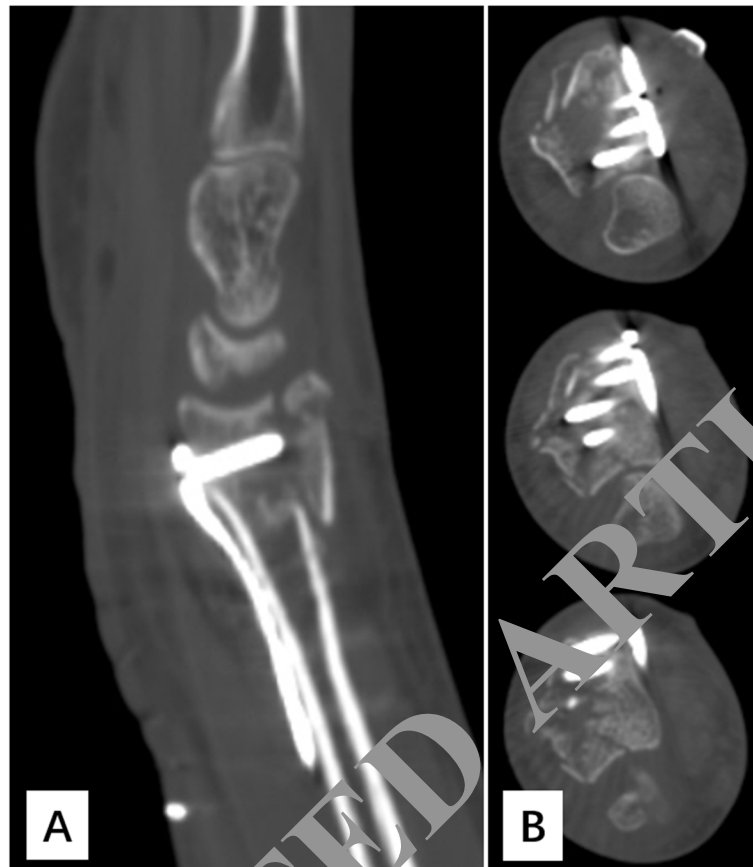For extra-articular fractures with DMC, we observed similar radiological results. Compared with Guillou's report [22], wherein no significant radiographic change in volar tilt, radial inclination, radial height, or ulnar

variance was found in the C3 fracture group during the 12 months' follow-up. Our findings provided extra clinical evidence for the application of volar locking fixation in the extra-articular distal radius fractures with DMC.

For intra-articular fractures with DMC, volar locking plating was tested to preserve fracture reduction in the C2 fractures, but not in the C3 fractures in this study. Our results were in contrast to Chou's study, wherein 41 patients with AO/OTA C3 dorsally comminuted distal radius fractures were treated using either dorsal ( $n = 22$ ) or volar ( $n = 19$ ) locking plate [17]. In both groups, no significant re-displacement was observed in terms of radial inclination, volar tilt, and ulnar variance. Compared with Chou's study, a larger number of cases were included in our study, and the significant loss of volar tilt in the C3 fractures in our study was possibly caused by a compromised subchondral support of the thin and displaced dorsal fragment provided by the distal row of screws with inadequate length (Fig. 3) [24–26]. The subsequent loss of fracture reduction was also observed by



**Fig. 2** Case 1. Significant loss of volar tilt was observed at 12-months' follow-up. **A, B**: Postoperative posteroanterior and lateral radiographs. **C, D**: Posteroanterior and lateral radiographs at 12-months' follow-up



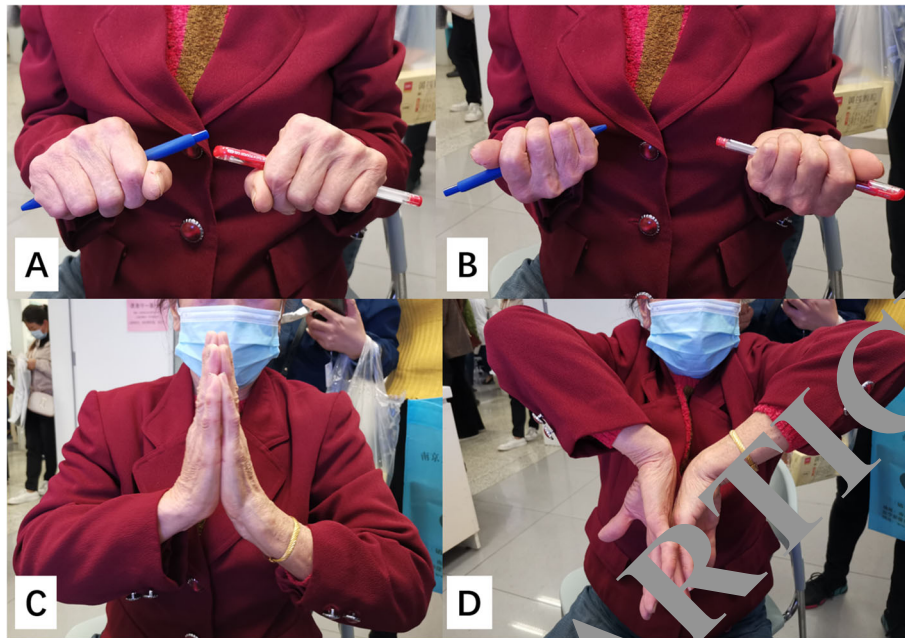
**Fig. 3** Case 1. Postoperative computed tomographic images confirmed an inadequate support of the thin and displaced dorsal fracture provided by the distal row of locking screws. **A**, Sagittal view of the CT image. **B**, Cross-sectional CT images

Gogna's study, wherein 33 dorsally comminuted distal radius fractures were fixed with volar locking plate and followed for over a year [17, 22, 27]. Totally three cases of C3 fractures (18.7%) were reported to present a dorsal subluxation of the carpus or a loss of dorsal tilt after one-year follow-up. These results were comparable with our study, and called for attention to the usage of volar locking plate in the C3 fractures with DMC, especially for the fractures with the occurrence of radiocarpal fracture dislocation or dorsal rim fractures [28].

To prevent the loss of reduction in C3 fractures, different solutions were reported in literature. An appropriate length of the distal row of locking screws was proven crucial for the single volar plating construct [26]. However, the risk of extensor tendon irritation would increase with longer distal radius screws [29]. Multi-row of volar locking screws was considered more stable than the single row screw construct. However, little evidence was provided to support the use of two rows of distal screws over one row in the fixation of distal radius fractures [29]. Besides, the combined usage of volar and dorsal plating was recommended to provide extra buttress for the dorsal fragment [4, 30, 31].

Dorsal plating was considered as another fixation option to treat distal radial fractures with DMC. Cadaveric reports showed that dorsal plating provided better support than volar plating, and served as a buttress against dorsal comminution [32]. Similar results were confirmed in a dorsally-comminuted sawbone model, in which dorsal pi-plate fixation presented better resistance to fracture gap motion than four different types of volar plate fixation [11]. In clinical studies investigating AO type C3 distal radial fractures, radiological analysis showed a significant difference in comparison with the contralateral side in terms of volar tilt for patients treated with volar plating, whereas there were no significant differences in patients receiving dorsal plating [33]. However, our study found no significant redisplacement in the A3 or C2 fractures when comparing postoperative and 12-month follow-up measurements, indicating that volar locking plates provided sufficient stability in the intra-articular distal radius fractures with a simple articular component.

With regard to the recovery of wrist function, Chou reported a progressive improvement of wrist range of motion following volar plating of C3 dorsally



**Fig. 4** Case 1. Wrist range of motion at 12-months' follow-up. **A, B:** A 95% recovery of pronation/supination was achieved in the injured wrist. **C, D:** A 78% recovery of extension/flexion was achieved in the injured wrist

comminuted distal radius fractures [17]. After one-year follow-up, the patients showed an 89% recovery of flexion-extension and a 97% recovery of supination-pronation compared with that of the contralateral healthy wrists. Compared with Chou's study, the patient with C3 fractures achieved comparable recovery of supination-pronation range of motion in our study. The relatively lower percentage of flexion-extension recovery in our study was possibly associated with the loss of volar tilt in radiological findings. Even so, the majority (87.9%) of the patients with C3 fractures achieved an excellent or good Gartland and Werley wrist score. Four patients (3.1%) with a significant loss of volar tilt resulted in decreased flexion-extension range of motion and a fair functional outcome (Fig. 4). This was consistent with Gupta and Arugia's findings that volar tilt was one of the most important radiographic parameters affecting the functional outcome of distal radius fractures [34, 35].

There were several limitations to our study. First, the study was based on retrospective data, which could harbor confounding sources of bias. Second, the length of the follow-up in our study was reported to be sufficient for the conclusion of radiological and functional outcome, but relatively short for the record of long-term complications [36].

In conclusion, the volar locking plate fixation provided sufficient stability for distal radius fractures with DMC, and resulted in similar radiological and functional outcomes in all of the C2 fractures as those in the extra-

articular fractures. Considering the C3 fractures, despite the subsequent loss of volar tilt, the majority of the patients achieved good to excellent wrist function following volar locking plating. Attention should be paid to the C3 fractures with thin and displaced dorsal fragment, for which the dorsal plating might be an option.

#### Abbreviations

DMC: Dorsal metaphyseal comminution; AAOS: American Association of Orthopaedic Surgeons; FCR: Flexor carpi radialis; DRUJ: distal radioulnar joint; ORIF: Open reduction and internal fixation; FRD: The fracture re-displacement; ROM: Range of motion; DASH: Disabilities of the Arm, Shoulder and Hand score; SPSS: Statistical Product and Service Solutions; DC: The dorsally comminuted distal radius fracture; DI: The dorsally intact distal radius fracture

#### Acknowledgements

Not applicable.

#### Authors' contributions

Hong-fei SHI and Yi-xin CHEN researched literature and conceived the study. All authors were involved in protocol development. Jin XIONG and Jun-fei WANG were involved in patient recruitment. Xu-sheng QIU and Zi-tao ZHANG were involved in data analysis. Xue-yang GUI and Zhao-hui CHENG wrote the first draft of the manuscript. All authors reviewed and edited the manuscript and approved the final version of the manuscript.

#### Funding

This study was funded by the National Natural Science Foundation of China (81401793 and 81572132), the Six Talent Peaks Project in Jiangsu Province (2016-WSW-060), and the Key Project supported by Medical Science and technology development Foundation, Nanjing Department of Health (YKK20086, QRX17007).

#### Availability of data and materials

The datasets generated and/or analysed during the current study are not publicly available due to the regulations of IRB, but can be made available from the corresponding author on reasonable request.

## Declarations

### Ethics approval and consent to participate

This study was conducted in accordance with the Declaration of Helsinki and with approval from the institutional review board (IRB) of Nanjing Drum Tower Hospital. Written informed consent was obtained from all participants.

### Consent for publication

Not applicable.

### Competing interests

The authors declare that they have no competing interests.

### Author details

<sup>1</sup>Department of Orthopedics, Nanjing Drum Tower Hospital, The Affiliated Hospital of Nanjing University Medical School, No. 321 Zhongshan Road, Nanjing, China. <sup>2</sup>Nanjing Drum Tower Hospital Clinical College of Nanjing Medical University, Nanjing, China.

Received: 26 May 2021 Accepted: 28 July 2021

Published online: 25 August 2021

## References

- Kennedy SA, Hanel DP. Complex distal radius fractures. *J Orthopedic Clinics*. 2013;44(1):81–92.
- Passiatore M, De Vitis R, Perna A, D'Orio M, Cilli V, Taccardo G. Extraphyseal distal radius fracture in children: is the cast always needed? A retrospective analysis comparing Epibloc system and K-wire pinning. *Eur J Orthop Surg Traumatol*. 2020;30(7):1243–50. <https://doi.org/10.1007/s00590-020-02698-z>.
- Maccagnano G, Noia G, Vicenti G, Baglioni M, Masciale MR, Cassano GD, et al. Volar locking plate versus external fixation in distal radius fractures: A meta-analysis. *Orthop Rev*. 2021;13(1):9147. <https://doi.org/10.4081/or.2021.9147>.
- Disseldorp DJ, Hannemann PF, Poeze M, Brink PR. Dorsal or Volar Plate Fixation of the Distal Radius: Does the Complication Rate Help Us to Choose? *J Wrist Surg*. 2016;5(3):202–10. <https://doi.org/10.1055/s-0036-1571842>.
- Asadollahi S, Keith PP. Flexor tendon injuries following plate fixation of distal radius fractures: a systematic review of the literature. *J Orthop Traumatol*. 2013;14(4):227–34. <https://doi.org/10.1007/s10195-013-0245-z>.
- Makhni EC, Taghinia A, Ewald T, Zurakowski D, Day CS. Comminution of the dorsal metaphysis and its effects on the radiographic outcomes of distal radius fractures. *J Hand Surg Eur Vol*. 2010;35(8):812–8. <https://doi.org/10.1177/1753193409338750>.
- Chuang PY, Yang TY, Shen SH, Tsai YH, Huang KC. The Effects of Dorsal Cortical Comminution on Radiographic Results following Percutaneous Pinning for Extra-Articular Colles' Fractures. *BMC Musculoskelet Disord*. 2015;2015: 714351.
- Mackenney PJ, McQueen MM, Ellis R. Prediction of instability in distal radial fractures. *J Bone Joint Surg Am*. 2006;88(9):1944–51. <https://doi.org/10.2106/JBJS.D.02520>.
- Wadsten MA, Sayed-Noor AS, Eriksson E, Buttazzoni GG, Sjoden GO. Cortical comminution in distal radial fractures can predict the radiological outcome: a cohort multicentre study. *Bone Joint J*. 2014;96-b(7):978–83.
- Kandemir U, Matiyahu A, Desai R, Puttlitz C. Does a volar locking plate provide equivalent stability as a dorsal nonlocking plate in a dorsally comminuted distal radius fracture?: a biomechanical study. *J Orthop Trauma*. 2009;23(9):605–10. <https://doi.org/10.1097/BOT.0b013e318186004f>.
- Miller M, Kusumi K, Zobitz ME, Cooney WP 3rd. Internal fixation of dorsally displaced fractures of the distal part of the radius. A biomechanical analysis of volar plate fracture stability. *J Bone Joint Surg Am*. 2006;88(11):2411–7. <https://doi.org/10.2106/0004623-200611000-00013>.
- Wadsten MA, Sayed-Noor AS, Sjoden GO, Svensson O, Buttazzoni GG. The Buttazzoni classification of distal radial fractures in adults: interobserver and intraobserver reliability. *Hand (New York, NY)*. 2009;4(3):283–8.
- Marsh JL, Slong TF, Agel J, Broderick JS, Creevey W, DeCoster TA, et al. Fracture and dislocation classification compendium - 2007: Orthopaedic Trauma Association classification, database and outcomes committee. *J Orthop Trauma*. 2007;21(10 Suppl):S1–S133. <https://doi.org/10.1097/00005131-200711101-00001>.
- Gui XY, Shi HF, Xiong J, Chen YX, Wang JF, Huang J, et al. A modified intrafocal pinning technique with three-dimensional planning to facilitate volar plating in dorsally comminuted AO/OTA C2 and C3 distal radius fractures. *BMC Musculoskelet Disord*. 2021;22(1):379. <https://doi.org/10.1186/s12891-021-04265-x>.
- Nana AD, Joshi A, Lichtman DM. Plating of the distal radius. *J Am Acad Orthop Surg*. 2005;13(3):159–71. <https://doi.org/10.5435/00124635-200505000-00003>.
- Soong M, Earp BE, Bishop G, Leung A, Blazar P. Volar locking plate implant prominence and flexor tendon rupture. *J Bone Joint Surg Am*. 2011;93(4): 328–35. <https://doi.org/10.2106/JBJS.J.00193>.
- Chou YC, Chen AC, Chen CY, Hsu YH, Wu CC. Dorsal and volar 4-mm titanium locking plate fixation for AO type C3 dorsally comminuted distal radius fractures. *J Hand Surg*. 2011;36(6):974–81. <https://doi.org/10.1054/jhsa.2011.02.024>.
- Sammer DM, Chung KC. Management of the distal radius/ulnar joint and ulnar styloid fracture. *Hand Clin*. 2012;28(2):199–206. <https://doi.org/10.1016/j.hcl.2012.03.011>.
- Chen YX, Zheng X, Shi HF, Wangyang YF, Fan H, Xie JX, et al. Will the untreated ulnar styloid fracture influence the outcome of unstable distal radial fracture treated with external fixation when the distal radioulnar joint is stable. *BMC Musculoskelet Disord*. 2015;16(1):186. <https://doi.org/10.1186/1471-2474-14-186>.
- Kreder HJ, Hanel DP, McNeel M, Winter J, McGillivray G, Swiontkowski MF. X-ray film measurement for healed distal radius fractures. *J Hand Surg*. 1996; 21(1):31–9. [https://doi.org/10.1016/S0363-5023\(96\)80151-1](https://doi.org/10.1016/S0363-5023(96)80151-1).
- Ryu JY, Cooney WP 3rd, An KN, Chao EY. Functional ranges of motion of the wrist. *J Hand Surg*. 1991;16(3):409–19. [https://doi.org/10.1016/S0363-5023\(91\)90066-W](https://doi.org/10.1016/S0363-5023(91)90066-W).
- Guillou J, Dard M, Pougès C, Christiaens N, Guerre E, Chantelot C. What happens to the posterior comminution in extra-articular fractures of the distal radius treated with volar locking plates? *Hand Surg Rehabil*. 2019; 38(2):91–6. <https://doi.org/10.1016/j.hansur.2018.10.238>.
- Mahmady S, Weil YA, Safran O, Liebergall M, Mosheiff R, Khoury A. Outcome of dorsally comminuted versus intact distal radial fracture fixed with volar locking plates. *Injury*. 2011;42(4):393–6. <https://doi.org/10.1016/j.injury.2010.10.011>.
- Figl M, Weninger P, Jurkowsky J, Hofbauer M, Schauer J, Leixnering M. Unstable distal radius fractures in the elderly patient—volar fixed-angle plate osteosynthesis prevents secondary loss of reduction. *J Trauma*. 2010;68(4): 992–8. <https://doi.org/10.1097/TA.0b013e3181b99f71>.
- Rhee SH, Kim J, Lee YH, Gong HS, Lee HJ, Baek GH. Factors affecting late displacement following volar locking plate fixation for distal radial fractures in elderly female patients. *Bone Joint J*. 2013;95-b(3):396–400.
- Wall LB, Brodt MD, Silva MJ, Boyer MJ, Calfee RP. The effects of screw length on stability of simulated osteoporotic distal radius fractures fixed with volar locking plates. *J Hand Surg*. 2012;37(3):446–53. <https://doi.org/10.1016/j.jhsa.2011.12.013>.
- Gogna P, Selhi HS, Singla R, Devgan A, Magu NK, Mahindra P, et al. Dorsally comminuted fractures of the distal end of the radius: osteosynthesis with volar fixed angle locking plates. *ISRN Orthopedics*. 2013;2013:131757.
- Garg R, Mudgal CS. When a volar locking plate is not the right choice in fractures of the distal radius: Case based technical considerations. *J Clin Orthop Trauma*. 2020;11(4):542–53. <https://doi.org/10.1016/j.jcot.2020.05.040>.
- Ramavath A, Howard N, Lipscombe S. Biomechanical considerations for strategies to improve outcomes following volar plating of distal radius fractures. *J Orthop*. 2019;16(5):445–50. <https://doi.org/10.1016/j.jor.2019.04.006>.
- Day CS, Kamath AF, Makhni E, Jean-Gilles J, Zurakowski D. "Sandwich" plating for intra-articular distal radius fractures with volar and dorsal metaphyseal comminution. *Hand (New York, NY)*. 2008;3(1):47–54.
- Farhan MF, Wong JH, Sreedharan S, Yong FC, Teoh LC. Combined volar and dorsal plating for complex comminuted distal radius fractures. *J Orthop Surg (Hong Kong)*. 2015;23(1):19–23. <https://doi.org/10.1177/230949901502300105>.
- Blythe M, Stoffel K, Jarrett P, Kuster M. Volar versus dorsal locking plates with and without radial styloid locking plates for the fixation of dorsally comminuted distal radius fractures: a biomechanical study in cadavers. *J Hand Surg*. 2006;31(10):1587–93. <https://doi.org/10.1016/j.jhsa.2006.09.011>.
- Rein S, Schikore H, Schneiders W, Amlang M, Zwipp H. Results of dorsal or volar plate fixation of AO type C3 distal radius fractures: a retrospective study. *J Hand Surg*. 2007;32(7):954–61.
- Batra S, Gupta A. The effect of fracture-related factors on the functional outcome at 1 year in distal radius fractures. *Injury*. 2002;33(6):499–502. [https://doi.org/10.1016/S0020-1383\(01\)00174-7](https://doi.org/10.1016/S0020-1383(01)00174-7).



35. Perugia D, Guzzini M, Civitenga C, Guidi M, Dominedò C, Fontana D, et al. Is it really necessary to restore radial anatomic parameters after distal radius fractures? *Injury*. 2014;45(Suppl 6):S21–6. <https://doi.org/10.1016/j.injury.2014.10.018>.
36. Hattori Y, Doi K, Sakamoto S, Yukata K. Delayed rupture of extensor digitorum communis tendon following volar plating of distal radius fracture. *Hand Surgery*. 2008;13(3):183–5.

### Publisher's Note

Springer Nature remains neutral with regard to jurisdictional claims in published maps and institutional affiliations.

RETRACTED ARTICLE

Ready to submit your research? Choose BMC and benefit from:

- fast, convenient online submission
- thorough peer review by experienced researchers in your field
- rapid publication on acceptance
- support for research data, including large and complex data types
- gold Open Access which fosters wider collaboration and increased citations
- maximum visibility for your research: over 100M website views per year

At BMC, research is always in progress.

Learn more [biomedcentral.com/submissions](https://biomedcentral.com/submissions)

