

RESEARCH ARTICLE

Open Access



# Less blood loss in supercapsular percutaneously assisted versus posterolateral total hip arthroplasty

Yong Hu<sup>1</sup>, Min-Cong Wang<sup>1</sup>, Tao Wang<sup>2</sup>, Yue Meng<sup>1</sup>, Xiao-Min Chao<sup>1</sup>, Hui-Feng Zhu<sup>1</sup>, Cheng-Guo Li<sup>1</sup>, Cheng-Long Pan<sup>1\*</sup>  and He-Bei He<sup>1\*</sup>

## Abstract

**Background:** Although excellent clinical outcomes of supercapsular percutaneously assisted total hip arthroplasty (SuperPath) have been reported, the peri-operative blood loss has rarely been reported. The current study determined the blood loss during SuperPath and compared the blood loss with conventional posterolateral total hip arthroplasty (PLTH).

**Methods:** This retrospective study enrolled patients who underwent unilateral primary THA between January 2017 and December 2019. The demographic data, diagnoses, affected side, radiographic findings, hemoglobin concentration, hematocrit, operative time, transfusion requirements, and intra-operative blood loss were recorded. The peri-operative blood loss was calculated using the OSTHEO formula. Blood loss on the 1st, 3rd, and 5th post-operative days was calculated. Hidden blood loss (HBL) was determined by subtracting the intra-operative blood loss from the total blood loss.

**Results:** Two hundred sixty-three patients were included in the study, 85 of whom were in the SuperPath group and 178 in the posterolateral total hip arthroplasty (PLTH) group. Patient demographics, diagnoses, affected side, operative times, and pre-operative hemoglobin concentrations did not differ significantly between the two groups (all  $P > 0.05$ ). Compared to the PLTH group, the SuperPath group had less blood loss, including intra-operative blood loss, 1st, 3rd, and 5th post-operative days blood loss, and HBL (all  $P < 0.05$ ). Total blood loss and HBL was  $790.07 \pm 233.37$  and  $560.67 \pm 195.54$  mL for the SuperPath group, respectively, and  $1141.26 \pm 482.52$  and  $783.45 \pm 379.24$  mL for the PLTH group. PLTH led to a greater reduction in the post-operative hematocrit than SuperPath ( $P < 0.001$ ). A much lower transfusion rate ( $P = 0.028$ ) and transfusion volume ( $P = 0.019$ ) was also noted in the SuperPath group.

**Conclusion:** SuperPath resulted in less perioperative blood loss and a lower transfusion rate than conventional PLTH.

**Keywords:** Total hip arthroplasty, Supercapsular percutaneously assisted, Minimally invasive, Blood loss, Transfusion

\* Correspondence: [pclgjwk@163.com](mailto:pclgjwk@163.com); [beihehe889@gmail.com](mailto:beihehe889@gmail.com)

<sup>1</sup>Present Address: Department of Joint Surgery, The Fifth Affiliated Hospital of Southern Medical University, Guangzhou City, Guangdong Province, China  
Full list of author information is available at the end of the article



© The Author(s). 2021 **Open Access** This article is licensed under a Creative Commons Attribution 4.0 International License, which permits use, sharing, adaptation, distribution and reproduction in any medium or format, as long as you give appropriate credit to the original author(s) and the source, provide a link to the Creative Commons licence, and indicate if changes were made. The images or other third party material in this article are included in the article's Creative Commons licence, unless indicated otherwise in a credit line to the material. If material is not included in the article's Creative Commons licence and your intended use is not permitted by statutory regulation or exceeds the permitted use, you will need to obtain permission directly from the copyright holder. To view a copy of this licence, visit <http://creativecommons.org/licenses/by/4.0/>. The Creative Commons Public Domain Dedication waiver (<http://creativecommons.org/publicdomain/zero/1.0/>) applies to the data made available in this article, unless otherwise stated in a credit line to the data.

## Introduction

Total hip arthroplasty (THA) is an effective treatment option for advanced degenerative and ischemic hip arthropathy. The traditional posterolateral approach is the most widely applied approach for primary and revision hip arthroplasties [1]. Despite the advantages of good exposure to the hip capsule and easing the insertion of implants, the considerable peri-operative blood loss during posterolateral total hip arthroplasty (PLTH) approach has hindered popularization of this approach [2]. Hidden blood loss (HBL), possibly associated with post-operative bleeding from muscle, tendon, and bone trauma, has been reported and has attracted attention, which accounts for 24–60% of the total blood loss [3, 4]. Minimally invasive THA has been developed with the rationale that less tissue trauma reduces the surgical blood loss and hastens patient recovery [5].

The fact that the length of incision is less important with respect to surgical outcome than disruption of muscles, impairment of soft tissue vascularization, innervation, and preservation of bone has been increasingly accepted by surgeons [6]. A novel minimally invasive surgical technique and initial experience with supercapsular percutaneously assisted total hip arthroplasty (SuperPath) was introduced by Dr. James Chow in 2011 [7]. SuperPath uses the interval between the gluteus minimus and piriformis, accesses the capsule from the top, prepares the femur without dislocating the femoral head, and reams the acetabulum through an accessory portal, which preserves capsular attachments and maintains the integrity of the external rotators [8]. This tissue-sparing technique is advocated with reported advantages of a low complication rate, excellent gait kinematics, a low transfusion rate, and a shortened length of hospital stay [9]. Compared to conventional PLTH, SuperPath allows for early post-operative rehabilitation and a faster recovery [10].

Existing studies mainly have emphasized the clinical outcomes of the SuperPath approach [10–12]. To our knowledge, the existing study that reported the peri-operative blood loss of SuperPath was limited. Surgical blood loss is always a concern among orthopedic surgeons because of the close relationship with allogenic blood transfusion. A large demand for transfusion has been reported due to the considerable perioperative blood loss during THA. Indeed, a previous study reported that 16–37% of patients who underwent THA needed a blood transfusion [13]. Accordingly, the risk of transfusion complications is increased, such as infections and immunologic reactions [14]. Therefore, we determined the peri-operative blood loss in SuperPath, and compared blood loss with conventional PLTH in the current study. We hypothesized that SuperPath resulted in less blood loss due to a mini-incision and preservation

of the external rotators, hip capsule, and abductor integrity.

## Methods

### Patients

This retrospective study enrolled patients who underwent unilateral primary THA between January 2017 and December 2019. The surgical technique used SuperPath or PLTH. The common exclusion criteria were as follows: active infection; tumors; and hematologic diseases, such as blood coagulation disorders, thrombocytopenia, and other hemorrhagic disorders. The additional exclusion criteria for SuperPath were as follows: severe deformation of the proximal femur; congenital high hip dysplasia; and osteosynthesis of the proximal femur [15]. Variables, such as gender, age, height, weight, BMI, diagnoses, affected side, pre- and post-operative radiographic findings, pre-operative hemoglobin (Hb) concentrations, pre- and post-operative hematocrit (Hct), operative time, and transfusion blood volume were recorded.

### Surgical protocol

Preoperative preparations were the same between the two groups, such as general condition assessment, patient educations, carbohydrate loading, and preoperative digital templating measurements. The surgery was performed under general or continuous epidural anesthesia. Antibiotics were routinely administered intra-operatively and 24 h post-operatively. One gram of tranexamic acid was administered intravenously at the beginning of the operation. Periarticular injection of analgesics consisting of 7.5 mg of ropivacaine, 7.5 mg of adrenaline, and 10 mg of betamethasone was performed, as suggested by Pepper et al. [16]. One gram of tranexamic acid was topically infiltrated after closing incision. All surgeries were performed by the same senior orthopedic chief surgeon. All patients received cementless THA implants. Drainage was not used after incision closure to obtain enhanced recovery after surgery [17].

### SuperPath approach

The patient was placed in the standard lateral decubitus position with the involved leg in the “home position,” (45°–60° of flexion, 20°–30° of internal rotation) [18]. An incision was made from the tip of the greater trochanter 6–8 cm proximally in line with the femur. The gluteus maximus muscle was split by blunt dissection, followed by the gluteus medius and minimus, and the piriformis tendon was retracted to access the capsule without dissecting any muscles. The capsule was incised along the path of the skin incision from the saddle of the femoral neck to 1 cm proximal to the acetabular rim. A sharp starter reamer was used to create the femoral canal, then sequential femoral broaches were used to complete the

preparation and size the proximal femoral canal (Micro-Port Scientific Corporation, Shanghai, China). The femoral neck osteotomy was performed level with the broach neck. Acetabular preparation and cup impaction were completed through a portal without needing release of the iliotibial band or remaining external rotators [18]. The reamer shaft was passed through the cannula and mated with the acetabular reamers inside the capsule. Following sequential reaming to size, the chosen acetabular implant was placed through the main incision. The final components were implanted after satisfactory trial reductions. Finally, closure was limited to the capsule, fat, and skin because no muscles were dissected during this procedure. The capsule was anatomicallly repaired with a running suture or single stitches.

#### **Posterior-lateral THA approach**

The patient was placed in a lateral position. The incision was made 6–8 cm anterior to the posterior superior iliac spine and distal to the iliac crest, overlying the anterior border of the gluteus maximus muscle, then extended distally to the anterior edge of the greater trochanter and further distally along the line of the femur for 12–15 cm. The iliotibial band was cut in line with its fibers, extending proximally to the greater trochanter. A further incision was performed to expose the greater trochanter and the muscles that insert into the greater trochanter. Blunt dissection was used to separate the posterior border of the gluteus medius muscle from the adjacent piriformis tendon. After identification of the piriformis, the short external rotators and piriformis were dissected at their insertion, then tagged with a braided suture for identification and repaired at the end of the procedure. The capsule was incised superiorly in the axis of the femoral neck from the acetabulum to the intertrochanteric line. The posterior dislocation of the hip joint was completed by flexion of the hip, and medial adduction and internal rotation of the lower limb. The standard posterior technique was as follows: femoral neck osteotomy, acetabulum and femoral preparations, and prosthesis implantation. Repair of the posterior capsule and reattachment of the external rotators were completed before closure of the skin incision.

#### **Post-operative treatment**

All patients received the same rehabilitation protocol by a physical therapist in our hospital. Patients can begin indoor walking independently using crutches when tolerating weight-bearing under the supervision of physical therapists. Combined venous thrombosis embolism prophylaxis with mechanical and pharmacologic methods was provided during hospitalization. Blood parameters were routinely tested on the 1st, 3rd, and 5th

post-operative days. Post-operative radiographs were obtained to evaluate the place of implants (Fig. 1).

#### **Estimation of blood loss**

The intra-operative blood loss was estimated by weighing sterile cotton gauze pads and analysis of the aspirated blood volume. Considering the significant difference between estimated and calculated blood loss, the latter was the main method of evaluation [19]. Peri-operative blood loss was calculated using the Orthopedic Surgery Transfusion Hemoglobin European Overview (OSTHEO) formula [19, 20], which was based on the change in Hct. The estimated blood loss on the 1st, 3rd, and 5th post-operative days was included. The detailed formulae are shown in Table 1.

#### **Transfusion protocol**

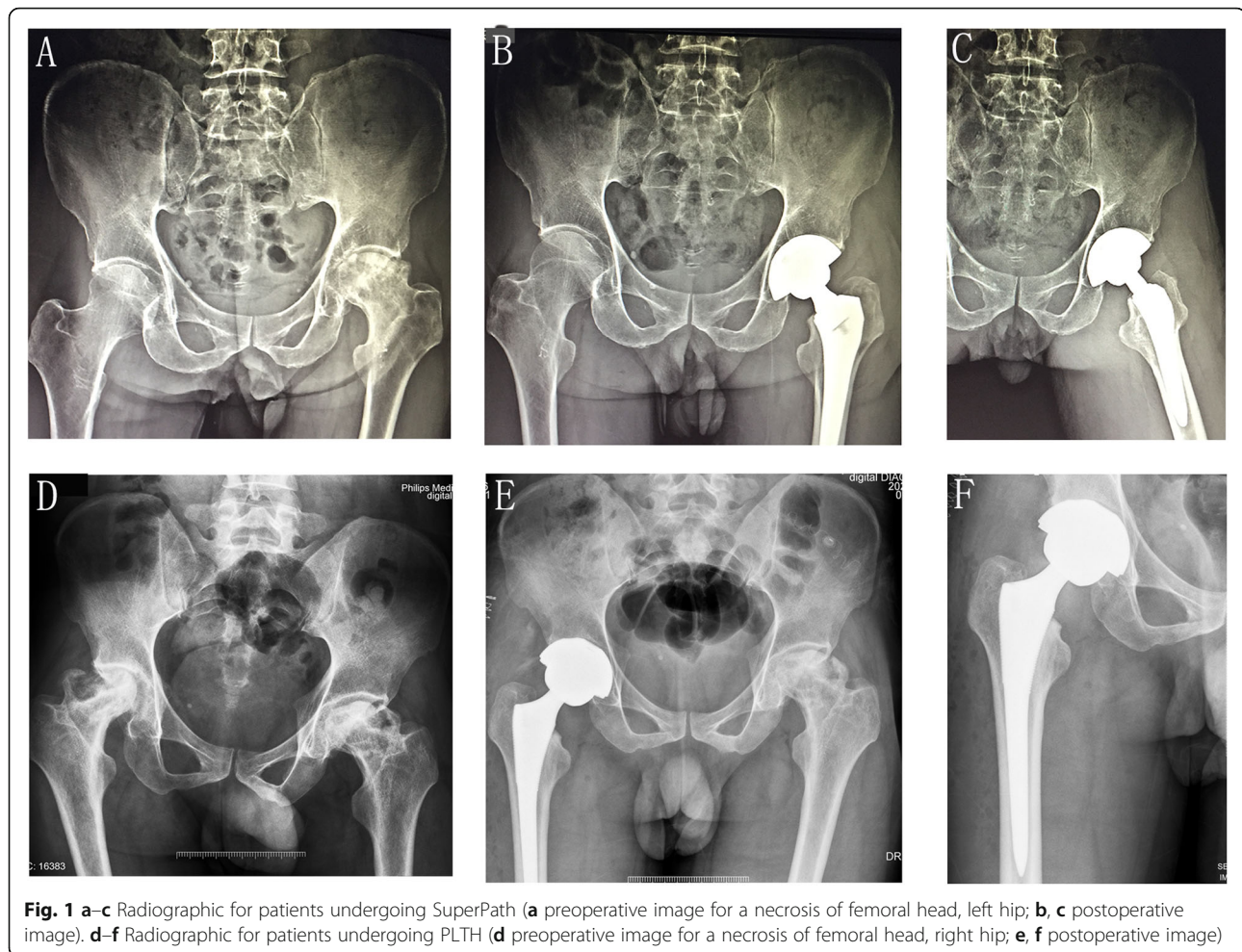
Autogenous blood was not applicable in the current study. Allogenic transfusion was performed based on the British guidelines (22) and clinical judgment. The traditional view on transfusion triggers was a Hb < 70 g/L and a hematocrit < 25%. A Hb < 80 g/L was a transfusion trigger for patients with cardiovascular and respiratory disorders or patients > 65 years of age. Acute anemia, a drop in blood pressure (< 90/60 mmHg), dizziness, lip pallor, weakness, and shortness of breath were also transfusion triggers.

#### **Statistical methods**

All statistical analyses were performed using SPSS for Windows (version 23.0; SPSS Inc., Chicago, IL, USA). Continuous data are presented as the mean  $\pm$  standard deviation (SD). Comparisons of quantitative variables were performed using an unpaired Student's *t* test. In the case of heteroscedasticity, the Mann-Whitney *U* test was used. Repeated measure analysis of variance was used to compare the change in Hct between the two groups. A chi-square test was executed to compare the frequencies of qualitative variables. Differences at a *P* < 0.05 level were identified as statistically significant.

#### **Results**

A total of 263 patients who had complete records were included in the study. Eighty-five patients (17 males and 68 females) with a mean age of 67 years (range 23–84 years) underwent SuperPath. In the PLTH group, there were 178 patients (25 males and 153 females) with a mean age of 65 years (range 28–82 years). Demographic data and diagnoses were summarized in Table 2. There were no significant differences in age, gender, BML, diagnoses, and involved side between the SuperPath and the PLTH groups (all *P* > 0.05). In the SuperPATH group, the diagnoses included femoral neck fracture (FNF; 23.5%), necrosis of femoral head (ONFH; 63.5%), and



hip osteoarthritis (OA; 13%). In the PLTH group, the diagnoses included FNF (24.2%), ONFH (52.2%), and OA (23.6%).

#### Blood loss and transfusion

Operative time and the pre-operative Hb concentration were not statistically different between the two groups

**Table 1** Estimations of Perioperative Blood Loss Volume

#### Orthopedic Surgery Transfusion Hemoglobin European Overview (OSTHEO) formula:

⊙ Estimated blood volume (EBV) =  $(0.0235 \times \text{height in cm}^{0.42246} \times \text{weight in kg}^{0.51456}) \times k$ , where  $k = 2430$  for women and  $2530$  for men.

⊙ Total RBC loss (mL) = [Uncompensated RBC loss (mL) + Compensated RBC loss (mL)]/0.35  
 Uncompensated RBC loss (mL) = EBV × (preoperative Hct levels – postoperative Hct levels),  
 Compensated RBC loss (mL) = allogeneic erythrocyte units × 150 + autologous transfusion volume × 0.3.

Notably, postoperative Hct levels were collected from the laboratory test which was carried out on the 1st, 3rd, and 5th day after operation. Only transfusions that were executed before phlebotomizing for laboratory test were included in the study.

( $P = 0.111$  and  $0.871$ , respectively). An apparent decrease in the Hct was noted post-operatively in both groups. PLTH resulted in a greater reduction in the Hct post-operatively than SuperPath ( $P < 0.001$ ; Fig. 2). Patients in the SuperPath group had less intra-operative blood loss ( $P < 0.001$ ; 95% CI, – 154.62 to – 102.17), and day 1 ( $P = 0.036$ ; 95% CI, – 324.58 to – 178.03), day 3 ( $P < 0.001$ ; 95% CI, – 549.55 to – 373.51), and day 5 post-operatively ( $P < 0.001$ ; 95%CI, – 467.70 to – 277.83) blood loss than the PLTH group. The surgical blood loss reached a maximum on day 3 post-operatively in the SuperPath and PLTH groups. Thus, this volume was considered as the total blood loss (TBL), which peaked at  $790.07 \pm 233.37$  mL in the SuperPath group and  $1141.26 \pm 482.52$  mL in the PLTH group. The hidden blood loss (HBL) was estimated by subtracting the intra-operative loss from the TBL [21]. As a result, the HBL was  $560.67 \pm 195.54$  mL in the SuperPath group, and  $783.45 \pm 379.24$  mL in the PLTH group ( $P < 0.001$ ; 95% CI, – 292.63 to – 152.95).

The SuperPath group had a significantly lower transfusion rate than the PLTH group (5.8% and 15.7%,

**Table 2** Demographics and diagnosis of the patients

		SuperPath group	PLTH group	P
Number of patients		85	178	
Age (years)		66.91 ± 9.14	65.22 ± 8.69	0.149
BMI (kg/m <sup>2</sup> )		25.98 ± 3.13	26.47 ± 4.07	0.577
Gender	Male	17	25	0.280
	Female	68	153	
Diagnosis	FNF	20	43	0.102
	ONFH	54	93	
	OA	11	42	
Involved hip	Left	34	86	0.234
	Right	51	92	

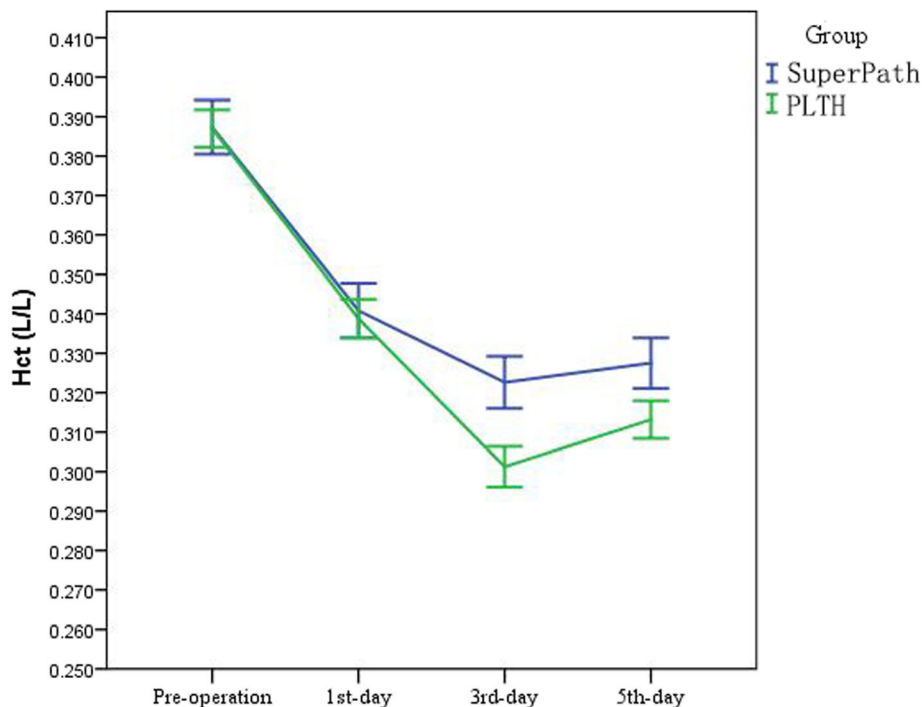
respectively;  $P = 0.028$ ). Accordingly, a lower allogenic blood volume was required in the SuperPath group than the PLTH group ( $P = 0.019$ ; 95% CI,  $-0.355$  to  $-0.123$ ). The detailed results were presented in Table 3 and Fig. 3.

**Discussion**

In the current study, we focused on the surgical blood loss associated with the SuperPath approach and compared to the PLTH approach. In agreement with Sehat et al. [21] and Shen et al. [22], we found that the surgical blood loss reached a maximum on day 3 post-operatively in the SuperPath and PLTH groups. Thus, this volume was defined as the TBL, which was 1141 mL

for patients who underwent PLTH in the current study. Miao et al. [4] enrolled 322 patients who underwent PLTH and reported that the TBL was  $1155 \pm 377$  mL, which was in agreement with our findings. Another study by Shen et al. [22] reported a larger amount of TBL for PLTH (1438 mL). For patients in the SuperPath group, the TBL was much less ( $790.07 \pm 233.37$  mL). Greater than 300 mL TBL occurred in the PLTH group than the SuperPath group. Accordingly, PLTH also resulted in a greater reduction in Hct post-operatively than SuperPath.

Meng et al. [1] compared the short-term outcomes of staged THA with SuperPath or through the posterolateral approach for bilateral ONFH in a prospective study; however, their findings were opposite to our results. Meng et al. [1] reported that the mean blood loss was higher in the SuperPath group (1108.50 mL) than the PLTH group (843.50 mL). Of note, only four male patients were enrolled in Meng et al. [1] study. Thus, the limited sample size may compromise the conclusions. Meng et al. [1] argued that the unexpected outcomes were possibly attributed to the intra-operative mechanical stresses from the specific trocar cannula and the elongated operative times during SuperPath. Our findings were also inconsistent with their results, which showed comparable operation time between the SuperPath and PLTH groups. The learning curve for SuperPath is thought to account for the discrepancy [23].



**Fig. 2** Hct was decreased postoperatively in both groups. PLTH resulted in a greater reduction in the Hct post-operatively than SuperPath ( $P < 0.001$ )

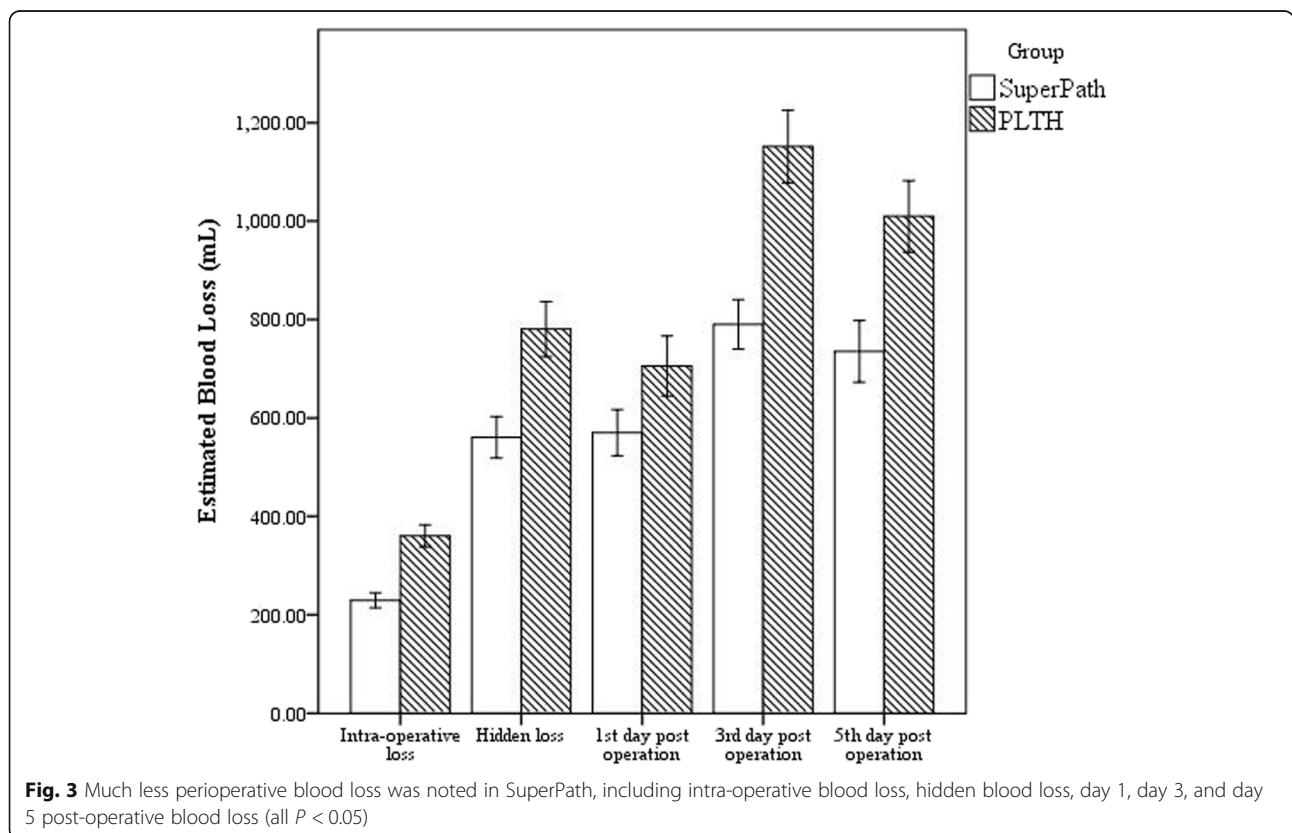
**Table 3** Patients' perioperative data

	SuperPath group	PLTH group	P values
Preoperative hemoglobin (g/L)	127.27 ± 12.52	127.98 ± 12.07	0.638
Preoperative hematocrit (L/L)	0.387 ± 0.018	0.387 ± 0.0324	0.916
Operation time	100.72 ± 12.18	98.34 ± 11.04	0.111
Intra-operative blood loss (mL)	229.41 ± 70.64	357.81 ± 145.30	< 0.001
Blood loss (1st day) (mL)	570.26 ± 218.27	699.03 ± 482.53	0.036
Blood loss (3rd day) (mL)	790.07 ± 233.37	1141.26 ± 482.52	< 0.001
Blood loss (5th day) (mL)	735.10 ± 291.91	1002.20 ± 483.53	< 0.001
Hidden blood loss (mL)	560.67 ± 195.54	783.45 ± 379.24	< 0.001
Transfusion rate	5.8% (5/85)	15.7% (28/178)	0.028
Transfusion volume (u)	0.060 ± 0.237	0.300 ± 0.710	0.019

Another study conducted by Xie et al. [10] suggested that the intra-operative blood was comparable between SuperPath and PLTH, which was also inconsistent with our results. Xie et al. [10] attached importance to the use of electrocautery when releasing external rotators close to the bone surface, which might not lead to a large amount of blood loss during the conventional posterolateral approach.

We also favored the hemostatic effect of electrocautery in THA; however, our findings indicated that the increased blood loss during the PLTH approach was mainly attributed to dissecting the piriformis, obturator,

gemellus superior, and gemellus inferior, in agreement with Chimento et al. [24] and Mazoochian et al. [25]. Repantis et al. [26] proposed that the main source of blood loss is the bone (femur and acetabulum) in a cementless THA. Thus, Repantis et al. [26] found that no significant differences in perioperative blood loss were present between the minimally invasive approach and the conventional approach that completely released gluteus minimus insertion, partially released gluteus medius insertion, and subtotally, resected capsule. Our findings suggested that the intra- and post-operative



blood loss caused by impairment of soft tissues cannot be omitted.

Although SuperPath has been advocated as a “micro” (external rotator sparing) and “mini” (external rotator sacrificing) posterior approach [7], the significant post-operative HBL (560.67 mL) cannot be dismissed, which on average accounted for 70.96% of the TBL. We reported more HBL in the PLTH group compared to the SuperPath group, which reached 783.45 mL (accounting for 68.64% of the TBL). The large amount of HBL might attribute to lacking intravenous administration of tranexamic acid post operation. Administration of tranexamic acid is an effective strategy when compared to placebo for reducing calculated blood loss and the need for transfusion during the perioperative episode of a primary THA; however, its optimal administration remains controversia l[27]. Fibrinolysis activation contributes to post-operative bleeding after THA, which reaches peak 6 h after THA and then gradually decreases to the pre-operative level 24 h after the operation [28, 29]. Jia [28] found that the serum antifibrinolytic activity of IV tranexamic acid with one dose merely maintained for 7 to 8 h; thus, another dose of tranexamic acid post operation is favored to reduce HBL.

We believed that perseveration of integrity of muscle without impairing any muscular artery/vein should mainly contribute to a reduction of post-operative bleeding for SuperPath. During the operation, the gluteus maximus muscle was split by blunt dissection in line with the fibers, followed by the gluteus medius and minimus, and the piriformis tendon were retracted to access to the capsule without dissecting any muscles [11].

The entire capsular incision is perfectly repaired with a continuous suture after implantation during SuperPath[18]. Hip capsule preservation is a revolutionary concept that ensures anatomic restoration, length, and offsets near the native joint [8]. The pressure after anatomically repairing the capsule may exert a hemostasis effect by compression. Liu et al. [3] proposed that retaining and repairing the articular capsule cannot only significantly decrease the hidden blood loss, but also the peri-operative bleeding. Furthermore, preservation of the short external rotators and posterior capsular allowed no particular range of motion restrictions post-operatively and achieved a high level of function with a very low dislocation risk. The dislocation rate of SuperPath (0.8%) was significantly decreased from those reported in some recent THA studies (2.9–6.0%) [11]. Bergin et al. [30] suggested that the tissue-sparing minimally invasive approach resulted in less surgical trauma and possibly lower levels of inflammation. The inflammation cascade will inevitably impair the tissue through inducing cytokines, lysosomal enzymes, free oxygen

radicals, and metabolic derivatives of arachidonic acid, which leads to endothelial cell injury and increased bleeding. The inflammation cascade might also be responsible for the destruction of erythrocytes because hemolysis is considered an important reason for HBL [31, 32].

A large TBL can result in the need for an allogenic transfusion. In the current study, we noted a significantly higher transfusion rate in the PLTH group compared to the SuperPath group. The transfusion rate was 5.8% for SuperPath, whereas it reached 15.7% for PLTH. A multicenter, retrospective study by Gofton et al. [11] also reported a low transfusion rate for patients who underwent SuperPath (3.3%). In contrast, Yoshihara et al. [33] reported that the overall transfusion rate for THA was 25.5%. Another study by Mednick et al. [34] reviewed 27130 primary THAs and found a transfusion rate of 22.2%. Allogenic transfusion is associated with several severe complications, such as hemolytic reactions, graft versus host disease, transfusion-associated circulatory overload, and transfusion-related acute lung injury. Gofton et al. [11] reported that the 30-day all-cause readmission rate was 2.3 % or a 1.9% reduction from the described national average for SuperPath, profiting by the low transfusion and complication rates.

There were several limitations in our study. First, the present study was a retrospective case series. In addition, the significant difference in gender ratio was observed in the enrolled patients. More female patients were enrolled than male patients. The sample size was relatively small, which might have influenced the power of significance. A prospective, randomized controlled trial is warranted to more appropriately evaluate the peri-operative blood loss of different approaches.

## Conclusion

In our study, we demonstrated that SuperPath is a veritable minimally invasive approach that results in less intra-operative blood loss, TBL, and HBL than the conventional PLTH approach, which was consistent with our initial hypothesis. On average, the TBL (300 mL) was less in the SuperPath group than that in the PLTH group. A much lower transfusion rate was also noted in the SuperPath group (5.8% vs. 15.7%). Therefore, our results indicated that the SuperPath approach is a reliable technique for patients who need a primary THA.

## Abbreviations

THA: Total hip arthroplasty; PLTH: Posterolateral total hip arthroplasty; SuperPath: Supercapsular percutaneously assisted total hip arthroplasty; HBL: Hidden blood loss; TBL: Total blood loss; Hb: Hemoglobin; Hct: Hematocrit; OSTHEO: Orthopedic Surgery Transfusion Hemoglobin European Overview

## Acknowledgements

Not applicable.

**Authors' contributions**

TW, YH, and CLP contributed to the conception and design of the study. YH was a major contributor for drafting the manuscript. CLP was the chief surgeon responsible for operation. HBH, YM, MXC, and MCW contributed to the acquisition of the data. YH, CGL, HFZ, and MCW contributed to the analysis and interpretation of the data. YH, TW, YM, and MCW make important revisions. HBH and CLP contributed responsibly for the overall content as guarantors. All authors read and approved the final manuscript.

**Funding**

This research received no specific grant from any funding agency in the public, commercial or not-for-profit sectors.

**Availability of data and materials**

The datasets used and/or analyzed during the current study are available from the corresponding author on reasonable request.

**Declarations****Ethics approval and consent to participate**

The study has gotten approval from Medical Ethics Committee of the Fifth Affiliated Hospital of Southern Medical University. Consent to participate is not applicable for this retrospective study.

**Consent for publication**

This section is not applicable for our study.

**Competing interests**

The authors declare that they have no competing interests.

**Author details**

<sup>1</sup>Present Address: Department of Joint Surgery, The Fifth Affiliated Hospital of Southern Medical University, Guangzhou City, Guangdong Province, China.

<sup>2</sup>Present Address: Department of Orthopaedic Surgery, The Third Affiliated Hospital of Guangzhou Medical College, Guangzhou City, Guangdong Province, China.

Received: 10 October 2020 Accepted: 18 March 2021

Published online: 25 March 2021

**References**

- Meng W, Huang Z, Wang H, Wang D, Luo Z, Bai Y, et al. Supercapsular percutaneously-assisted total hip (SuperPath) versus posterolateral total hip arthroplasty in bilateral osteonecrosis of the femoral head: a pilot clinical trial. 2019;21(1):2. <https://doi.org/10.1186/s12891-019-3023-0>.
- Spahn DR. Anemia and patient blood management in hip and knee surgery: a systematic review of the literature. *Anesthesiology*. 2010;113(2):482–95. <https://doi.org/10.1097/ALN.0b013e3181e08e97>.
- Liu X, Zhang X, Chen Y, Wang Q, Jiang Y, Zeng B. Hidden blood loss after total hip arthroplasty. *J Arthroplasty*. 2011;26(7):1100–1105.e1101. <https://doi.org/10.1016/j.arth.2010.11.013>.
- Miao K, Ni S, Zhou X, Xu N, Sun R, Zhuang C, et al. Hidden blood loss and its influential factors after total hip arthroplasty. *J Orthop Surg Res*. 2015;10(1):36. <https://doi.org/10.1186/s13018-015-0185-9>.
- Migliorini F, Biagini M, Rath B, Meisen N, Tingart M, Eschweiler J. Total hip arthroplasty: minimally invasive surgery or not? Meta-analysis of clinical trials. *Int Orthop*. 2019;43(7):1573–82. <https://doi.org/10.1007/s00264-018-4124-3>.
- Barrett WP, Turner SE, Leopold JP. Prospective randomized study of direct anterior vs postero-lateral approach for total hip arthroplasty. *J Arthroplast*. 2013;28(9):1634–8. <https://doi.org/10.1016/j.arth.2013.01.034>.
- Chow J, Penenberg B, Murphy S. Modified micro-superior percutaneously-assisted total hip: early experiences & case reports. *Curr Rev Musculoskeletal Med*. 2011;4(3):146–50. <https://doi.org/10.1007/s12178-011-9090-y>.
- Cardenas-Nylander C, Bellotti V, Astarita E, Moya Gomez E, Fernandez MR. Innovative approach in total hip arthroplasty: supercapsular percutaneously-assisted. *Hip Int*. 2016;26(Suppl 1):34–7. <https://doi.org/10.5301/hipint.5000409>.
- Della Torre PK, Fitch DA, Chow JC. Supercapsular percutaneously-assisted total hip arthroplasty: radiographic outcomes and surgical technique. *Ann Transl Med*. 2015;3(13):180. <https://doi.org/10.3978/j.issn.2305-5839.2015.08.04>.
- Xie J, Zhang H, Wang L, Yao X, Pan Z, Jiang Q. Comparison of supercapsular percutaneously assisted approach total hip versus conventional posterior approach for total hip arthroplasty: a prospective, randomized controlled trial. *J Orthop Surg Res*. 2017;12(1):138. <https://doi.org/10.1186/s13018-017-0636-6>.
- Gofton W, Chow J, Olsen KD, Fitch DA. Thirty-day readmission rate and discharge status following total hip arthroplasty using the supercapsular percutaneously-assisted total hip surgical technique. *Int Orthop*. 2015;39(5):847–51. <https://doi.org/10.1007/s00264-014-2587-4>.
- Gofton W, Fitch DA. In-hospital cost comparison between the standard lateral and supercapsular percutaneously-assisted total hip surgical techniques for total hip replacement. *Int Orthop*. 2016;40(3):481–5. <https://doi.org/10.1007/s00264-015-2878-4>.
- Min JK, Zhang QH, Li HD, Li H, Guo P. The Efficacy of Bipolar Sealer on Blood Loss in Primary Total Hip Arthroplasty: A Meta-Analysis. *Medicine*. 2016;95(19):e3435. <https://doi.org/10.1097/md.0000000000003435>.
- Vamvakas EC, Blajchman MA. Transfusion-related mortality: the ongoing risks of allogeneic blood transfusion and the available strategies for their prevention. *Blood*. 2009;113(15):3406–17. <https://doi.org/10.1182/blood-2008-10-167643>.
- Quitmann H. Supercapsular percutaneously assisted (SuperPath) approach in total hip arthroplasty. *Oper Orthop Traumatol*. 2019;31(6):536–46. <https://doi.org/10.1007/s00064-019-0597-5>.
- Pepper AM, Mercuri JJ, Behery OA, Vigdorchik JM. Total Hip and Knee Arthroplasty Perioperative Pain Management: What Should Be in the Cocktail. *JBJS reviews*. 2018;6(12):e5. <https://doi.org/10.2106/jbjs.rvw.18.00023>.
- Wainwright TW, Gill M, McDonald DA, Middleton RG, Reed M, Sahota O, et al. Consensus statement for perioperative care in total hip replacement and total knee replacement surgery: Enhanced Recovery After Surgery (ERAS<sup>®</sup>) Society recommendations. *Acta Orthop*. 2020;91(1):3–19. <https://doi.org/10.1080/17453674.2019.1683790>.
- Chow J. SuperPath: The Direct Superior Portal-Assisted Total Hip Approach. *JBJS essential surgical techniques*. 2017;7(3):e23. <https://doi.org/10.2106/jbjs.st.16.00061>.
- Rosencher N, Kerckamp HE, Macheras G, Munuera LM, Menichella G, Barton DM, et al. Orthopedic Surgery Transfusion Hemoglobin European Overview (OSTHEO) study: blood management in elective knee and hip arthroplasty in Europe. *Transfusion*. 2003;43(4):459–69. <https://doi.org/10.1046/j.1537-2995.2003.00348.x>.
- Martinez V, Monsaingeonlion A, Cherif K, Judet T, Chauvin M, Fletcher D. Transfusion strategy for primary knee and hip arthroplasty: impact of an algorithm to lower transfusion rates and hospital costs. *Hum Reprod*. 1994;9(7):1297–9.
- Sehat KR, Evans RL, Newman JH. Hidden blood loss following hip and knee arthroplasty. Correct management of blood loss should take hidden loss into account. *J Bone Joint Surg (Br)*. 2004;86(4):561–5.
- Shen J, Gu J, Lin S-B, Li Q, Li L-B, Dong Q-R. Impact factors of perioperative hidden blood loss after total hip arthroplasty in osteoarthritis patients. *Int J Clin Exp Med*. 2016;9:8599–604.
- Rasuli KJ, Gofton W. Percutaneously assisted total hip (PATH) and Supercapsular percutaneously assisted total hip (SuperPATH) arthroplasty: learning curves and early outcomes. *Ann Transl Med*. 2015;3(13):179. <https://doi.org/10.3978/j.issn.2305-5839.2015.08.02>.
- Chimento GF, Pavone V, Sharrock N, Kahn B, Cahill J, Sculco TP. Minimally invasive total hip arthroplasty: a prospective randomized study. *J Arthroplast*. 2005;20(2):139–44. <https://doi.org/10.1016/j.arth.2004.09.061>.
- Mazoochian F, Weber P, Schramm S, Utzschneider S, Fottner A, Jansson V. Minimally invasive total hip arthroplasty: a randomized controlled prospective trial. *Arch Orthop Trauma Surg*. 2009;129(12):1633–9. <https://doi.org/10.1007/s00402-009-0870-4>.
- Repantis T, Bouras T, Korovessis P. Comparison of minimally invasive approach versus conventional anterolateral approach for total hip arthroplasty: a randomized controlled trial. *Eur J Orthop Surg Traumatol*. 2015;25(1):111–6. <https://doi.org/10.1007/s00590-014-1428-x>.
- Fillingham YA, Ramkumar DB, Jevsevar DS, Yates AJ, Bini SA, Clarke HD, et al. Tranexamic Acid Use in Total Joint Arthroplasty: The Clinical Practice Guidelines Endorsed by the American Association of Hip and Knee Surgeons, American Society of Regional Anesthesia and Pain Medicine,



- American Academy of Orthopaedic Surgeons, Hip Society, and Knee Society. *J Arthroplast.* 2018, 3065;33(10):–3069. <https://doi.org/10.1016/j.arth.2018.08.002>.
28. Jia J. Combined use of intravenous and topical tranexamic acid in patients aged over 70 years old undergoing total hip arthroplasty. *J Orthop Surg Res.* 2019;14(1):345. <https://doi.org/10.1186/s13018-019-1384-6>.
  29. Dahl OE, Pedersen T, Kierulf P, Westvik AB, Lund P, Arnesen H, et al. Sequential intrapulmonary and systemic activation of coagulation and fibrinolysis during and after total hip replacement surgery. *Thromb Res.* 1993;70(6):451–8. [https://doi.org/10.1016/0049-3848\(93\)90087-5](https://doi.org/10.1016/0049-3848(93)90087-5).
  30. Bergin PF, Doppelt JD, Kephart CJ, Benke MT, Graeter JH, Holmes AS, et al. Comparison of minimally invasive direct anterior versus posterior total hip arthroplasty based on inflammation and muscle damage markers. *J Bone Joint Surg Am.* 2011;93(15):1392–8. <https://doi.org/10.2106/jbjsj.00557>.
  31. Faris PM, Ritter MA, Keating EM, Valeri CR. Unwashed filtered shed blood collected after knee and hip arthroplasties. A source of autologous red blood cells. *J Bone Joint Surg Am.* 1991;73(8):1169–78. <https://doi.org/10.2106/00004623-199173080-00005>.
  32. Pattison E, Protheroe K, Pringle RM, Kennedy AC, Dick WC. Reduction in haemoglobin after knee joint surgery. *Ann Rheum Dis.* 1973;32(6):582–4. <https://doi.org/10.1136/ard.32.6.582>.
  33. Yoshihara H, Yoneoka D. National trends in the utilization of blood transfusions in total hip and knee arthroplasty. *J Arthroplast.* 2014;29(10):1932–7. <https://doi.org/10.1016/j.arth.2014.04.029>.
  34. Mednick RE, Alvi HM, Krishnan V, Lovecchio F, Manning DW. Factors Affecting Readmission Rates Following Primary Total Hip Arthroplasty. *J Bone Joint Surg Am.* 2014;96(14):1201–9. <https://doi.org/10.2106/jbjs.m.00556>.

## Publisher's Note

Springer Nature remains neutral with regard to jurisdictional claims in published maps and institutional affiliations.

**Ready to submit your research? Choose BMC and benefit from:**

- fast, convenient online submission
- thorough peer review by experienced researchers in your field
- rapid publication on acceptance
- support for research data, including large and complex data types
- gold Open Access which fosters wider collaboration and increased citations
- maximum visibility for your research: over 100M website views per year

**At BMC, research is always in progress.**

Learn more [biomedcentral.com/submissions](https://biomedcentral.com/submissions)

