


CASE REPORT

Open Access



# Molecular investigation and clinical management of *Hepatozoon Canis* infection in an Indian jackal – a case report

S.M. Kolangath<sup>1\*</sup> , S.V. Upadhye<sup>1</sup>, V.M. Dhoot<sup>1</sup>, M.D. Pawshe<sup>1</sup>, A.S. Shalini<sup>1</sup> and R.M. Kolangath<sup>2</sup>

## Abstract

**Background:** Hepatozoonosis is a common tick-borne illness reported from all over the world. The infection has been well documented in dogs and cats, and has also been identified in wild canids and felids. India is home to many canid species; however, the incidence of Hepatozoonosis in wild canids is rarely reported. A wide variety of protocols have been discussed for the clinical management of the infection in companion animals; however, the suitability of treatment protocols in wild canids is understudied. The current case report highlights the clinical management of Hepatozoonosis in an Indian jackal and molecular investigation to provide vital insights into the epidemiology of the disease.

**Case Presentation:** A paraplegic Indian jackal was rescued from Melghat Tiger Reserve, Maharashtra, India. The animal had extensive decubital ulcers on the left pin bone and could not walk; however, the animal was active and dragged the hindlimb during locomotion. The vital parameters, blood and serum investigations were normal. Post physiotherapy, massage and infrared therapy, the animal could walk but started knuckling, resulting in injuries. Eight weeks into rehabilitation, the animal had a steep fall in haemoglobin concentration, platelet count, weight loss and was diagnosed with Hepatozoonosis. Considering the altered vital parameters, the jackal was rationally treated with Doxycyclin @ 20 mg/Kg O.D. (Once Daily) for 45 days along with supportive therapy. The jackal recovered after the treatment and led a normal life.

**Conclusion:** Mono-drug regime using Doxycycline was effective in the alleviation of *H. canis* infection in jackal. The drug was effective in alleviating the clinical presentation without alteration of vital parameters. The molecular investigation provided qualitative inputs in understanding the epidemiology of *Hepatozoon* in wild canids.

**Keywords:** *Hepatozoon canis*, *Leucocytozoon*, Indian jackal, Doxycycline, *Rhipicephalus*, Wildlife, Conservation efforts

## Background

Tick-borne diseases have been extensively studied in companion animals; however, the epidemiology of protozoal diseases in the wild is understudied. Ticks transmit various infections in the tropical region. The hot and humid climate of the tropics is conducive to the propagation of

ticks [1]. There are numerous reports of tick-borne diseases emerging from the Indian subcontinent every year. Hepatozoonosis is a tick-borne disease of companion and wild animals. *Rhipicephalus* and *Amblyomma* species are considered important transmitting agents for infection. Recently, the role of *Dermacentor reticulatus* has been investigated in the transmission of multiple infections, including Hepatozoonosis in red fox (*Vulpes vulpes*) [2]. The infection has been reported in dogs [3] and cats [4–7]; however, few reports from the wild have been documented. The reports of wild are primarily limited to

\*Correspondence: [brosujit@gmail.com](mailto:brosujit@gmail.com)

<sup>1</sup>Wildlife Research & Training Centre, Gorewada, MAFSU, Nagpur Opp. Hindustan Lever Godown Square, Mahurzhari Road, Fetri, Nagpur 441501, India  
Full list of author information is available at the end of the article



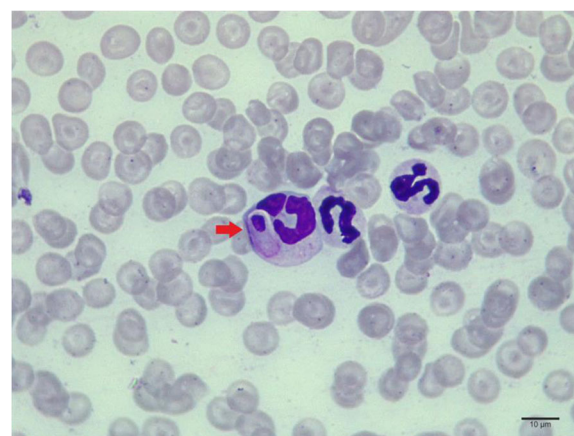
© The Author(s). 2022 **Open Access** This article is licensed under a Creative Commons Attribution 4.0 International License, which permits use, sharing, adaptation, distribution and reproduction in any medium or format, as long as you give appropriate credit to the original author(s) and the source, provide a link to the Creative Commons licence, and indicate if changes were made. The images or other third party material in this article are included in the article's Creative Commons licence, unless indicated otherwise in a credit line to the material. If material is not included in the article's Creative Commons licence and your intended use is not permitted by statutory regulation or exceeds the permitted use, you will need to obtain permission directly from the copyright holder. To view a copy of this licence, visit <http://creativecommons.org/licenses/by/4.0/>. The Creative Commons Public Domain Dedication waiver (<http://creativecommons.org/publicdomain/zero/1.0/>) applies to the data made available in this article, unless otherwise stated in a credit line to the data.

canids [8–10], ursids [11], felids [12–17], rodents [18], reptiles [19], mustelids [20] and procyonids [21]. Dogs are considered reservoirs of *H. canis*; they can be infested with brown dog ticks (*Rhipicephalus* sp.), the definitive hosts. Many species of wild felids and canids are known to be infected with Hepatozoonosis. India has reported incidences of *H. canis* in wild dogs (*Cuon alpinus*) in the recent past; however, no reports in any other wild canid species have surfaced from the region [12]. The current case report highlights the clinical management and molecular investigation of Hepatozoonosis in an Indian jackal (*Canis aureus indicus*).

### Case presentation

An adult male Indian jackal (*Canis aureus indicus*) was rescued from Melghat Tiger Reserve, Maharashtra, India with a history of paraplegia due to a possible automobile accident. The animal was rationally treated at the Transit Treatment Centre and was transferred to Wildlife Research & Training Centre, Gorewada, Nagpur, for further care and rehabilitation after a couple of months. On reception the vital parameters, blood and serum values were within the normal range. The radiological examination revealed an L6 spinal fracture with L6-L7 dislocation resulting in paraplegia. The animal was treated rationally with Injection Ceftiofur Sodium @ 22 mg/Kg, Injection Methyl Prednisolone 2.2 mg/ Kg, Injection Ranitidine HCl (Hydrochloride) @ 4.4 mg total dose once a day. This was supplemented with physiotherapy and infra-red therapy. Post 15 days into rehabilitation, the jackal was found to support his weight on the hind limbs and could walk. However, it was noticed that the jackal started knuckling during the walk and resulted in lacerations and wounds.

The jackal exhibited fever, anaemia, depression, weight loss, rough hair coat, lethargy and inappetence on day 55 of rehabilitation (Day 0). Blood investigation revealed decreased haemoglobin concentration (6.1 g/dL), thrombocytopenia, leucocytosis and neutrophilia; peripheral blood smear examination revealed anisocytosis and the presence of gamonts in neutrophils (Fig. 1). Serum biochemistry showed hypoglycemia and elevated AST (Aspartate Aminotransferase). On day 0, 12.5% of the circulating neutrophils were found to contain gamonts. Considering the low haemoglobin concentration and altered vitals, a mono antiprotozoal therapy was employed using Doxycycline @ 20 mg/Kg body weight once a day along with supportive therapy including hepatoprotectants, iron supplements, vitamins and probiotics. The mono antiprotozoal regime was continued for 45 days, during which vital parameters were monitored on days 0, 21, 45 (Table 1) and monthly thereafter. During the course of the therapy, blood indices and clinical presentation gradually improved, and the percentage of neutrophils containing gamonts gradually improved, and the percent-



**Fig. 1** Blood smear examination revealed presence of gamonts in the neutrophils (indicated by arrow). Normal neutrophils can be seen in the periphery

age of neutrophils containing gamonts gradually tapered from 12.5%, 7.66% to 0% on days 0, 21 and 45, respectively.

To further investigate the infection, DNA (Deoxyribonucleic Acid) was isolated from 100  $\mu$ l of whole blood using DNeasy® Blood and Tissue Kit (Mfg. Qiagen Inc, MD, USA) as per the manufacturer's instructions and Polymerase Chain Reaction (PCR) was performed targeting the 18S ribosomal RNA gene of *Hepatozoon* sp [22]. An amplification of 650 bp was obtained (Fig. 2), which was sequenced using HepF and HepR primer pairs on ABI 3130 automated DNA sequencer (Mfg. Applied Biosystems, CA, USA). *H. felis* amplicon reported from tiger was used as a positive control, while the negative control was devoid of any template. To monitor the progression of the infection, PCR studies were repeated on days 21 and 35 (Fig. 2, Lane 1, 2 and 3). To limit relapses, blood samples were examined every month and were found to be negative consistently. The obtained sequence was submitted to the NCBI nucleotide database using the nBLAST tool. It was found to be 99.68% identical to the previously reported *H. canis* in dogs from India (Accession No. MH922768, MN252045). A systematic phylogenetic analysis was undertaken by including sequences of *Hepatozoon* identified in wild canids, ursids and felids. The sequences were selected based on similarity with the query sequence (Details in Table 2). Sequences reported in domestic and wild were included without preference. Neighbour joining phylogenetic trees using the bootstrap method were constructed using Mega X software to study the topologies of the phylogenetic trees (Fig. 3) [23]. The bootstrap values (1000 replications) were analysed to ensure tree consistency.


### Discussion and conclusion

Most of *Hepatozoon* spp. infection in wild and companion animals is subclinical, and it produces clinical outcomes

**Table 1** Haemato-biochemical values and peripheral blood smear studies evaluated on Day 0, 21 and 45 along with normal reference values

Sr. No.	Parameter	On Arrival	Day 0	Day 21	Day 45	Reference Value
1	Lymphocytes (%)	14.2	16.5	16	18	12-30
2	Monocytes (%)	6.4	8.2	6	5.2	3-10
3	Neutrophils (%)	76.2	74.7	76	72.7	60-70
4	Eosinophils (%)	3.0	0.4	2	3.8	2-10
5	Basophils (%)	0.2	0.2	00	0.3	0-1
6	WBC ( $10^9/L$ )	19.87	24.87	20.43	18.32	6-17
7	RBC ( $10^{12}/L$ )	7.14	6.92	6.08	7.01	5.5-8.5
	Platelets ( $10^9/L$ )	419	192	212	321	200-500
8	Haemoglobin (g/dL)	11.65	6.1	6.8	7.4	12-18
9	HCT	37.65	37.16	38.02	38.23	37-55
10	Mean Corpuscular Volume (fL)	59	54	55	57	58-79
11	Mean Concentration Haemoglobin (MCH) (pg)	16.8	16.0	16.9	16.79	19.5-24.5
12	MCHC (g/dl)	31.2	29.7	30.4	30.8	32-36
13	BUN (mg/dL)	21	20	20	29	7-25
14	Creatinine (mg/dL)	0.6	0.6	0.5	0.6	0.3-1.4
15	ALT (U/L)	52	58	100	48	10-118
16	AST (U/L)	58	61	62	51	14-45
17	ALP (U/L)	68	71	26	36	20-150
18	Total Bilirubin (mg/dl)	0.3	0.3	0.3	0.3	0.1-0.6
19	Glucose (mg/dl)	72	31	88	76	60-110
20	Calcium (mg/dl)	8.6	8.6	9.1	9.0	8.6-11.8
21	Total Protein (g/dL)	5.8	6.0	6.6	6.9	5.4-8.2
22	Albumin (g/dL)	2.4	2.5	2.6	2.6	2.5-4.4
23	Globulin (g/dL)	3.4	3.5	4.0	4.3	2.3-5.2
24	Na <sup>+</sup> (mmol/ L)	138	136	138	138	138-160
25	K <sup>+</sup> (mmol/ L)	5.4	5.4	5.2	4.8	3.7-5.8
26	Cl <sup>-</sup> (mmol/ L)	105	105	105	116	95-119
27	tCO <sub>2</sub> (mmol/ L)	19	19	22	18	12-27
28	Body weight (Kg)	6.7	6.3	6.1	6.63	
29	Peripheral Smear	Normal	Hepatozoon +++ Thrombocytopenia	Hepatozoon +	Normal	
30	% of neutrophils containing gamont	None	12.5%	07.66%	None	
31	Clinical Presentation	Normal appetite; active, wound on pin bone, urine & faeces normal, locomotion by dragging hind limbs, drag injuries. Vital parameter normal	Fever, depression, inappetence, lethargy, urine & faeces normal, weight loss, anaemia	Lethargy, faeces and urine normal, appetite slightly reduced, anaemia	Active, wounds healed, appetite restored, active, weight gained, anaemia	

Reference: Haematology and Serum Biochemistry reference ranges, 10th edn. The Merck Veterinary Manual (Cynthia, 2011)



only in very young and immunocompromised individuals [10]. Reports of death in hyenas [8] and coyotes [24] due to Hepatozoonosis highlight the need to investigate the disease among endangered wild canids. The impact of stress, habitat destruction and concurrent viral and bacterial infection on the spread of Hepatozoonosis under free-range has been studied [25]. Conventionally the diagnosis of Hepatozoonosis is primarily based on the blood smear examination; however, when the quantum of infection is scarce, the detection of infection becomes uncertain. Also, Rhipicephalus spp. transmit an array of protozoal infections, coinfection of *Anaplasma platys*, *Ehrlichia canis*, *H. canis* and *Rickettsia monacensis* has been reported in dogs [26] and wild canids [2, 27]. Molecular techniques can provide sensitive diagnostic tools for detecting protozoal diseases. When augmented with molecular tools like sequencing, qualitative inputs on the epidemiological aspects can be provided.

In the current case report, the jackal exhibited a steep fall in haemoglobin concentration, neutrophilia, leucocytosis, elevated AST levels indicative of hepatic involvement [28, 29]. During the treatment, blood parameters

and corpuscular indices showed marginal improvement, with the haemoglobin concentration improving slightly from 6.1 gm/dl (Day 0) to 7.4 gm/dl (Day 45). Clinically, the animal regained its weight and began having a normal appetite and behaviour. The animal showed two instances of loose stools during treatment which was rationally treated with probiotics and diet management. The haemoglobin concentration returned to 10.5 after 90 days, probably due to concurrent blood loss from nursing injuries. Relapses of Hepatozoonosis have been reported in dogs [30, 31]. Hence, a monthly peripheral blood smear and PCR tests were conducted to rule out the relapse, which was consistently negative.

The selection of a therapeutic agent is critical in treating infection in patients with altered vital parameters. The therapeutic agent for treating Hepatozoonosis is selected based on the species of *hepatozoon* identified. The drugs employed vary from agent to agent; for *H. americanum*, a multi-drug combination of trimethoprim, pyrimethamine, clindamycin, decoquinatone [32]. Also, anticoccidial agent toltrazuril has been found effective in the treatment of experimentally infected voles with *H. erhardovae* [33]. However, *H. canis* responds to a combination of imidocarb dipropionate and Doxycycline [29, 34]. Side-effects like hepatic necrosis, kidney failure and death have been reported in dogs treated with imidocarb [35], and the drug has failed to eliminate *H. canis* in naturally infected dogs [36]. Considering the safety and duration of treatment, mono drug therapy of Doxycycline for 45 days was opted for. The elimination of *Hepatozoon* infection on day 45 was confirmed by blood smear examination and PCR (Fig. 2 lane 5). It is worth pointing out that the jackal showed no deviations from normal during blood and serum examination on reception. The upsurge of infection was in coincidence with trauma and stress due to tissue injury, as reported in Lions [37]. The jackal recovered uneventfully; thus, Doxycycline has value in the clinical management of *H. canis* infection in wild canids with compromised vitals.

A Polymerase Chain Reaction (PCR) was carried out to confirm the finding further [22]. The amplicon of 650 bp was sequenced and submitted to National Center for Biotechnology Information (NCBI) database for reference. The sequence was allotted accession number MZ823614. In the current study, sequence analysis revealed 99.68% identity with previously reported sequences of *H. canis* in dogs from India (Accession No. MH922768, MN252045). There are only a couple of previously reported *H. canis* in wild dogs (*Cuon alpinus*) from India (Accession No. HQ829448, HQ829447). No reports of Hepatozoonosis from other wild species have been reported from the country. The phylogenetic analysis revealed the presence of the query sequence (MZ823614) in clade I A consisting of sequences of *H. canis* reported


**Table 2** List of sequences along with their attributes used for the neighbour-joining phylogenetic studies

Sr. No.	Accession No.	Organism	Host	Country	Author
1	HQ829448	Hepatozoon canis	Cuon alpinus	India	[12]
2	HQ829447	Hepatozoon canis	Cuon alpinus	India	[12]
3	KF322144	Hepatozoon canis	Vulpes vulpes	Hungary	[38]
4	KU893118	Hepatozoon canis	Vulpes vulpes	Czech Republic	[39]
5	FJ497012	Hepatozoon canis	Canis lupus familiaris	Croatia	Vajota et al., 2009 (Unpublished)
6	KP715303	Hepatozoon canis	Vulpes vulpes	Italy	[40]
7	DQ439542	Hepatozoon canis	Vulpes vulpes	Spain	Criado-Fonelio., 2007
8	MZ823614	Hepatozoon canis	Canis aureus indicus	India	Kolangath et al., 2021 (Unpublished)
9	MN252045	Hepatozoon canis	Canis lupus familiaris	India	Angeline et al., 2019 (Unpublished)
10	MH922768	Hepatozoon canis	Canis lupus familiaris	India	[19]
11	MG241124	Hepatozoon canis	Hemaphysalis	India	[41]
12	MN150506	Hepatozoon ursi	Ursus arctos	Turkey	[42]
13	MN463021	Hepatozoon ursi	Ursus arctos	Turkey	[43]
14	LC431855	Hepatozoon ursi	Ursus thibetanus japonicus	Japan	[44]
15	LC431853	Hepatozoon ursi	Ursus thibetanus japonicus	Japan	[44]
16	HQ829430	Hepatozoon ursi	Melursus ursinus	India	[11]
17	LC431855	Hepatozoon ursi	Ursus thibetanus japonicus	Japan	[44]
18	HQ829445	Hepatozoon felis	Panthera tigris tigris	India	[12]
19	MT634695	Hepatozoon felis	Panthera tigris tigris	India	Kolangath et al., 2020 (Unpublished)
20	GQ377218	Hepatozoon felis	Prionailurus bengalensis	Korea	[17]
21	KX757033	Hepatozoon felis	Felis silvestris silvestris	Bosnia & Herzegovina	[45]
22	AB771554	Hepatozoon felis	Prionailurus bengalensis eupilurus	Japan	[46]
23	AB771576	Hepatozoon felis	Prionailurus bengalensis eupilurus	Japan	[46]
24	MH078194	Hepatozoon silvestris	Felis catus	Switzerland	[47]
25	KX757031	Hepatozoon silvestris	Felis silvestris silvestris	Bosnia & Herzegovina	[48]
26	MF614155	Hepatozoon silvestris	Felis silvestris silvestris	Bosnia & Herzegovina	[45]
27	GQ268314	Hepatozoon silvestris	Felis silvestris silvestris	Germany	Hertwig et al., 2009 (Unpublished)
28	GQ268314	Hepatozoon silvestris	Felis silvestris silvestris	Germany	Hertwig et al., 2009 (Unpublished)
29	JX415171	Hepatozoon americanum	Canis latrans	USA	[49]
30	EU146062	Hepatozoon americanum	Canis lupus familiaris	USA	[50]
31	EU249992	Hepatozoon americanum	Canis lupus familiaris	USA	[50]
32	EU249993	Hepatozoon americanum	Sigmodon hispidus	USA	[50]
33	JX415176	Hepatozoon americanum	Canis latrans	USA	[49]
34	DQ162616	<i>Plasmodium vivax</i> (Outgroup)	——	Brasil	[51]

in dogs and other wildlife from India and abroad. The major clade II consisted mainly of the sequences of *H. felis* reported in wild felids from India, Korea, Bosnia & Herzegovina (Table2); *H. silvestris* and *H. americanum* isolated from a variety of host species including wild and domestic

animals (Details provided in Table2). *Plasmodium vivax* formed a distinct outgroup.

The case report highlights the utility of oral Doxycycline in the clinical management of Hepatozoonosis in wild canids with altered vitals. Molecular techniques are



sensitive and can be effectively utilised in the monitoring of the progression of the disease. The insights provided by high throughput technologies like sequencing can help understand the epidemiology and prevalence of Hepatozoonosis. It is essential to study the dynamics of the infection in the wild to ensure the survival of the endangered wildlife. Further investigation in sympatric canids species in the wild and captivity can provide critical insights on Hepatozoonosis.

**Abbreviations**

O.D.: Once Daily; HCl: Hydrochloride; PCR: Polymerase Chain Reaction; DNA: Deoxyribonucleic Acid; AST: Aspartate Aminotransferase; NCBI: National Center for Biotechnology Information

**Acknowledgments**

The authors acknowledge the kind approval of the Principal Chief Conservator of Forest (Wildlife) & Chief Wildlife Warden, Maharashtra State, for carrying out the research work. Forest Development Corporation of Maharashtra Ltd., Nagpur and Office of the Divisional Manager, Gorewada Project, Nagpur, for the facilities provided for the research. Director, Wildlife Research & Training Centre to facilitate the research work at WRTC, Gorewada, Nagpur.

**Authors' contributions**

KSM major contributor and involved in all phases of research, including writing the manuscript, performing the PCR, sequencing. USV and DVM supervised the study, collected samples, transported them to the lab, contributed to writing, PMD and SAS assisted in the clinical management of the Indian jackal. KRM performed phylogenetic analysis and assisted in manuscript preparation. All authors have read and approved the final manuscript.

**Funding**

The authors self-funded the study. The Corresponding author is not in receipt of any funding from research agencies in India or abroad.

**Availability of data and materials**

The sequence identified in the study is available in the public domain database of nCBI under accession no. mZ823614. <https://www.ncbi.nlm.nih.gov/nucleotide/MZ823614>

**Declarations****Ethics approval and consent to participate**

The study is a clinical case, and the sample was drawn for diagnosis and treatment of the animal presented to Wildlife Research & Training Centre, Gorewada, Nagpur; hence does not draw the ethical committee approval. However, as per the existing Wildlife Protection Act, 1972 permission from Principal Chief Conservator of Forest (Wildlife), Maharashtra State was sought to vide No. Desk-22(8)/Res/CR-59(19-20)/3838/19-20, Nagpur, date 15 January 2020 for the study and publication of scientific findings. All the sample collection during the study has been executed as per ARRIVE guidelines.

**Consent for publication**

Not Applicable.

**Competing interests**

The authors declare that they have no competing interests.

**Author details**

<sup>1</sup>Wildlife Research & Training Centre, Gorewada, MAFSU, Nagpur Opp. Hindustan Lever Godown Square, Mahurzhari Road, Fetri, Nagpur 441501, India. <sup>2</sup>Department of Biotechnology & Biochemistry, Saint Francis DeSales College, Seminary Hills, Nagpur 440006, India.

Received: 15 October 2021 Accepted: 11 March 2022

Published online: 20 April 2022

**References**

- Githeko AK, Lindsay SW, Confalonieri UE, Patz JA. Climate change and vector-borne diseases: a regional analysis. *Bull World Health Organ.* 2000;78:1136–47.
- Mierzejewska EJ, Dwuznik D, Koczwarska J, Stańczak Ł, Opalińska P, Krokowska-Paluszak M, Wierzbicka A, Górecki G, Bajera A. The red fox (*Vulpes vulpes*), a possible reservoir of *Babesia vulpes*, *B. canis* and *Hepatozoon canis* and its association with the tick *Dermacentor reticulatus* occurrence. *Ticks Tick-borne Dis.* 2021;12(1):101551.
- Anderson M, Turcitu MA, Stefanache M, Tamba P, Barbuceanu F, Chitima L. First evidence of *Anaplasma platys* and *Hepatozoon canis* co-infection in a dog from Romania—a case report. *Ticks Tick-borne Dis.* 2013;4(4):317–9.
- Braga ÍA, de Souza Ramos DG, Marcili A, Melo AL, Taques II, Amude AM, Chitarra CS, Nakazato L, Dutra V, de Campos Pacheco R, Aguiar DM. Molecular detection of tick-borne protozoan parasites in a population of domestic cats in midwestern Brazil. *Ticks Tick-borne Dis.* 2016;7(5):1004–9.
- André MR, Herrera HM, de Jesus Fernandes S, de Sousa KC, Gonçalves LR, Domingos IH, de Macedo GC, Machado RZ. Tick-borne agents in domesticated and stray cats from the city of Campo Grande, State of Mato Grosso do Sul, midwestern Brazil. *Ticks Tick-borne Dis.* 2015;6(6):779–86.
- Díaz-Regañón D, Villaescusa A, Ayllón T, Rodríguez-Franco F, Baneth G, Calleja-Bueno L, García-Sancho M, Agulla B, Sainz Á. Molecular detection of *Hepatozoon spp* and *Cytauxzoon sp.* in domestic and stray cats from Madrid, Spain. *Parasites Vectors.* 2017;10(1):112.
- East ML, Wibbelt G, Lieckfeldt D, Ludwig A, Goller K, Wilhelm K, Schares G, Thierer D, Hofer H. A *Hepatozoon* species genetically distinct from *H. canis* infecting spotted hyenas in the Serengeti ecosystem, Tanzania. *J Wildl Dis.* 2008;44(1):45–52.
- Giannitti F, Diab SS, Uzal FA, Fresneda K, Rossi D, Talmi-Frank D, Baneth G. Infection with a *Hepatozoon sp.* closely related to *Hepatozoon felis* in a wild Pampas gray fox (*Lycalopex–Pseudalopex–gymnocercus*) co-infected with canine distemper virus. *Vet Parasitol.* 2012;186(3–4):497–502.
- Garrett JJ, Kocan AA, Reichard MV, Panciera RJ, Bahr RJ, Ewing SA. Experimental infection of adult and juvenile coyotes with domestic dog and wild coyote isolates of *Hepatozoon americanum* (Apicomplexa: Adeleorina). *J Wildl Dis.* 2005;41(3):588–92.
- Pawar RM, Poornachandar A, Arun AS, Manikandan S, Shivaji S. Molecular prevalence and characterization of *Hepatozoon ursi* infection in Indian sloth bears (*Melursus ursinus*). *Vet Parasitol.* 2011;182(2–4):329–32.
- Pawar RM, Poornachandar A, Srinivas P, Rao KR, Lakshmi Kantan U, Shivaji S. Molecular characterization of *Hepatozoon spp.* infection in endangered Indian wild felids and canids. *Vet Parasitol.* 2012;186(3–4):475–9.
- Furtado MM, Metzger B, de Almeida Jácomo AT, Labruna MB, Martins TF, O'Dwyer LH, Paduan KD, Porfirio GE, Silveira L, Sollmann R, Taniwaki SA. *Hepatozoon spp.* infect free-ranging jaguars (*Panthera onca*) in Brazil. *J Parasitol.* 2017;103(3):243–50.
- Hodžić A, Mrowietz N, Cezanne R, Bruckschwaiger P, Punz S, Habler VE, Tomsik V, Lazar J, Duscher GG, Glawischign W, Fuehrer HP. Occurrence and diversity of arthropod-transmitted pathogens in red foxes (*Vulpes vulpes*) in western Austria, and possible vertical (transplacental) transmission of *Hepatozoon canis*. *Parasitology.* 2018;145(3):335–44.
- Tateno M, Sunahara A, Nakanishi N, Izawa M, Matsuo T, Setoguchi A, Endo Y. Molecular survey of arthropod-borne pathogens in ticks obtained from Japanese wildcats. *Ticks Tick-borne Dis.* 2015;6(3):281–9.
- Rafiqi SI, Kumar S, Reena KK, Garg R, Ram H, Karikalan M, Mahendran K, Pawde AM, Sharma AK, Banerjee PS. Molecular characterization of *Hepatozoon sp.* and *Babesia sp.* isolated from endangered Asiatic Lion (*Panthera leo persica*). *Indian J Anim Sci.* 2018;88:662–6.
- Kubo M, Jeong A, Kim SI, Kim YJ, Lee H, Kimura J, Agatsuma T, Sakai H, Yanai T. The first report of *Hepatozoon* species infection in leopard cats (*Prionailurus bengalensis*) in Korea. *J Parasitol.* 2010;96(2):437–9.
- Kamani J, Harrus S, Nachum-Biala Y, Gutiérrez R, Mumcuoglu KY, Baneth G. Prevalence of *Hepatozoon* and *Sarcocystis spp.* in rodents and their ectoparasites in Nigeria. *Acta Trop.* 2018;187:124–8.
- Ujvari B, Madsen T, Olsson M. High prevalence of *Hepatozoon spp.* (Apicomplexa, Hepatozoidae) infection in water pythons (*Liasis fuscus*) from tropical Australia. *J Parasitol.* 2004;90(3):670–2.
- Guardone L, Ebani VV, Verin R, Nardoni S, Consolazione A, Bennett M, Mancianti F. Molecular detection of arthropod-borne pathogens in Eurasian badgers (*Meles meles*) from the United Kingdom. *Animals.* 2020;10(3):446.
- Meneses A, Alvarado G, Runnebaum M, Herrera M, Gutiérrez-Espeleta G, Chaves A. First Report of *Hepatozoon procyonis* in Raccoons from Costa Rica. *Rev Cien Veterinarias.* 2016;34(1):51–4.
- Inokuma H, Okuda M, Ohno K, Shimoda K, Onishi T. Analysis of the 18S rRNA gene sequence of a *Hepatozoon* detected in two Japanese dogs. *Vet Parasitol.* 2002;106(3):265–71.
- Kumar S, Stecher G, Li M, Knyaz C, Tamura K. MEGA X: molecular evolutionary genetics analysis across computing platforms. *Mol Biol Evol.* 2018;35(6):1547–9.
- Kocan AA, Cummings CA, Panciera RJ, Mathew JS, Ewing SA, Barker RW. Naturally occurring and experimentally transmitted *Hepatozoon americanum* in coyotes from Oklahoma. *J Wildl Dis.* 2000;36(1):149–53.
- Penzhorn BL, Kjemtrup AM, López-Rebollar LM, Conrad PA. *Babesia leo* n. sp. from lions in the Kruger National Park, South Africa, and its relation to other small piroplasms. *J Parasitol.* 2001;87(3):681–5.
- Lauzi S, Maia JP, Epis S, Marcos R, Pereira C, Luzzago C, Santos M, Puente-Payo P, Giordano A, Pajoro M, Sironi G. Molecular detection of *Anaplasma platys*, *Ehrlichia canis*, *Hepatozoon canis* and *Rickettsia monacensis* in dogs from Maio Island of Cape Verde archipelago. *Ticks Tick-borne Dis.* 2016;7(5):964–9.
- Silva MR, Mattoso CR, Costa A, Saito ME, Tchaicka L, O'Dwyer LH. *Rangelia vitalii* and *Hepatozoon canis* coinfection in pampas fox *Lycalopex gymnocercus* from Santa Catarina State, Brazil. *Rev Bras Parasitol Vet.* 2018;27:377–83.

27. Baneth G, Weigler B. Retrospective case-control study of *Hepatozoonosis* in dogs in Israel. *J Vet Intern Med*. 1997;11(6):365–70.
28. Thakur N, Chethan GE, Akhilesh AL, Kumari P, Shehzad M, Rajesh JB, Mahendran K, De UK, Banerjee PS. Therapeutic management of *Hepatozoon canis* induced acute hepatitis in a dog. *J Entomol Zool Stud*. 2018;6(4):1037–9.
29. Attipa C, Neofytou K, Yiapanis C, Martínez-Orellana P, Baneth G, Nachum-Biala Y, Brooks-Brownlie H, Solano-Gallego L, Tasker S. Follow-up monitoring in a cat with leishmaniasis and coinfections with *Hepatozoon felis* and '*Candidatus Mycoplasma haemominutum*'. *J Feline Med Surg Open Rep*. 2017;3(2):2055116917740454.
30. Skeldon N, Klaassen J, Hinds M. Diagnosis of *Hepatozoon canis*. *Vet Rec*. 2017;180(5):124.
31. Allen KE, Little SE, Johnson EM, Hostetler J, Panciera RJ, Ewing SA. Treatment of *Hepatozoon americanum* infection: review of the literature and experimental evaluation of efficacy. *Vet Ther Res Appl Vet Med*. 2010;11(4):E1–8.
32. Krampitz HE, Haberkorn A. Experimental treatment of *Hepatozoon* infections with the anticoccidial agent toltrazuril. *J Vet Med Ser B*. 1988;35(1-10):131–7.
33. Sarma K, Monda DB, Saravanan M, Kumar M, Mahendran K. Haemato-biochemical changes in *Hepatozoon canis* infected dog before and after therapeutic management. *J Vet Parasitol*. 2012;26(1):35–8.
34. Abdullah AS, Sheikh-Omar AR, Baggot JD, Zamri M. Adverse effects of imidocarb dipropionate (Imizol®) in a dog. *Vet Res Commun*. 1984;8(1):55–9.
35. Sasanelli M, Paradies P, Greco B, Eyal O, Zaza V, Baneth G. Failure of imidocarb dipropionate to eliminate *Hepatozoon canis* in naturally infected dogs based on parasitological and molecular evaluation methods. *Vet Parasitol*. 2010;171(3-4):194–9.
36. Munson L, Terio KA, Kock R, Mlengeya T, Roelke ME, Dubovi E, Summers B, Sinclair AR, Packer C. Climate extremes promote fatal co-infections during canine distemper epidemics in African lions. *PLoS ONE*. 2008;3(6):e2545.
37. Farkas R, Solymosi N, Takács N, Hornyák Á, Hornok S, Nachum-Biala Y, Baneth G. First molecular evidence of *Hepatozoon canis* infection in red foxes and golden jackals from Hungary. *Parasites Vectors*. 2014;7(1):1–7.
38. Mitková B, Hrazdilová K, Steinbauer V, D'Amico G, Mihalca AD, Modrý D. Autochthonous *Hepatozoon* infection in hunting dogs and foxes from the Czech Republic. *Parasitol Res*. 2016;115(11):4167–71.
39. Battisti E, Zanet S, Khalili S, Trisciunglio A, Hertel B, Ferroglio E. Molecular survey on vector-borne pathogens in alpine wild carnivorans. *Front Vet Sci*. 2020;7:1.
40. Ortuño A, Castellà J, Criado-Fornelio A, Buling A, Barba-Carretero JC. Molecular detection of a *Hepatozoon* species in stray cats from a feline colony in North-eastern Spain. *Vet J*. 2008;177(1):134–5.
41. Nimisha M, Devassy JK, Pradeep RK, Pakideery V, Sruthi MK, Pious A, Kurbet PS, Amrutha BM, Chandrasekhar L, Deepa CK, Ajithkumar KG. Ticks and accompanying pathogens of domestic and wild animals of Kerala, South India. *Exp Appl Acarol*. 2019;79(1):137–55.
42. Akyuz M, Kirman R, Guven E. Morphological and molecular data of *Hepatozoon ursi* in two brown bears (*Ursus arctos*) in Turkey. *Folia Parasitol*. 2020;67:032.
43. Orkun Ö, Emir H. Identification of tick-borne pathogens in ticks collected from wild animals in Turkey. *Parasitol Res*. 2020;119(9):3083–91.
44. Moustafa MA, Sasaki A, Shimozuru M, Nakao R, Sashika M, Yamazaki K, Koike S, Tanaka J, Tamatani H, Yamanaka M, Ishinazaka T. Molecular detection of apicomplexan protozoa in Hokkaido brown bears (*Ursus arctos yesoensis*) and Japanese black bears (*Ursus thibetanus japonicus*). *Parasitology Research*. 2020;119(11):3739–53.
45. Giannelli A, Latrofa MS, Nachum-Biala Y, Hodžić A, Greco G, Attanasi A, Annoscia G, Otranto D, Baneth G. Three different *Hepatozoon* species in domestic cats from southern Italy. *Ticks Tick-borne Dis*. 2017;8(5):721–4.
46. Tateno M, Sunahara A, Nakanishi N, Izawa M, Matsuo T, Setoguchi A, Endo Y. Molecular survey of arthropod-borne pathogens in ticks obtained from Japanese wildcats. *Ticks Tick-borne Dis*. 2015;6(3):281–9.
47. Kegler K, Nufer U, Alic A, Posthaus H, Olias P, Basso W. Fatal infection with emerging apicomplexan parasite *Hepatozoon silvestris* in a domestic cat. *Parasites Vectors*. 2018;11(1):1–5.
48. Hodžić A, Alić A, Prašović S, Otranto D, Baneth G, Duscher GG. *Hepatozoon silvestris* sp. nov.: morphological and molecular characterization of a new species of *Hepatozoon* (*Adeleorina: Hepatozoidae*) from the European wild cat (*Felis silvestris silvestris*). *Parasitology*. 2017;144(5):650–61.
49. Starkey LA, Panciera RJ, Paras K, Allen KE, Reiskind MH, Reichard MV, Johnson EM, Little SE. Genetic diversity of *Hepatozoon spp.* in coyotes from the south-central United States. *J Parasitol*. 2013;99(2):375–8.
50. Li Y, Wang C, Allen KE, Little SE, Ahluwalia SK, Gao D, Macintire DK, Blagburn BL, Kaltenboeck B. Diagnosis of canine *Hepatozoon spp.* infection by quantitative PCR. *Vet Parasitol*. 2008;157(1-2):50–8.
51. Albrecht L, Merino EF, Hoffmann EH, Ferreira MU, de Mattos Ferreira RG, Osakabe AL, Dalla Martha RC, Ramharter M, Durham AM, Ferreira JE, Del Portillo HA. Extense variant gene family repertoire overlap in Western Amazon *Plasmodium falciparum* isolates. *Mol Biochem Parasitol*. 2006;150(2):157–65.
52. Cyntia K. The Merck veterinary manual. White Station: Merck & Company, Incorporated; 2011.

### Publisher's Note

Springer Nature remains neutral with regard to jurisdictional claims in published maps and institutional affiliations.

#### Ready to submit your research? Choose BMC and benefit from:

- fast, convenient online submission
- thorough peer review by experienced researchers in your field
- rapid publication on acceptance
- support for research data, including large and complex data types
- gold Open Access which fosters wider collaboration and increased citations
- maximum visibility for your research: over 100M website views per year

At BMC, research is always in progress.

Learn more [biomedcentral.com/submissions](https://biomedcentral.com/submissions)

