

CASE REPORT

Open Access



Dynamic cord compression induced by proximal junctional failure and loose pedicle screws after thoracolumbar fusion surgery: a case report

Takahiro Kozaki¹, Takuhei Kozaki^{1,2*}, Keiji Nagata¹, Shunji Tsutsui¹, Yusuke Noda¹, Howard S An² and Hiroshi Yamada¹

Abstract

Background One of the common mechanical complications following spinal fusion surgery is proximal junctional failure (PJF). The incidence of neurological deficit associated with PJF has been poorly described in the literature. Here, we report a case in which numbness in the lower extremities was recognized as the first symptom, but the discrepancy in the imaging findings made PJF difficult to diagnose.

Methods A 71-year-old female underwent corrective fusion surgery. Three weeks later, she complained of persistent right leg numbness. Standing X-ray showed the back-out of the pedicle screws (PSs) in the upper instrumented vertebra (UIV), but there was no obvious evidence of cord compression on computed tomography (CT), which caused the delay of diagnosis. Five weeks later, magnetic resonance image (MRI) did not show cord compression on an axial view, but there were signal changes in the spinal cord.

Results The first reason for the delayed diagnosis was the lack of awareness that leg numbness could occur as the first symptom of PJF. The second problem was the lack of evidence for spinal cord compression in various imaging tests. Loosened PSs were dislocated on standing, but were back to their original position on supine position. In our case, these contradictory images led to a delay in diagnosis.

Conclusion Loosened PSs caused dynamic cord compression due to repeated deviation and reduction. Supine and standing radiographs may be an important tool in the diagnosis of PJF induced by dynamic cord compression.

Keywords Adult spinal deformity, Proximal junctional failure, Dynamic cord compression, Pedicle screw loosening

*Correspondence:

Takuhei Kozaki

t.kozaki@wakayama-med.ac.jp

¹Department of Orthopaedic Surgery, Wakayama Medical University, 811-1 Kimiidera, Wakayama 641-0012, Japan

²Department of Orthopaedic Surgery, Rush University Medical Center, 1611 W. Harrison St, Chicago, IL 60612, USA



© The Author(s) 2023. **Open Access** This article is licensed under a Creative Commons Attribution 4.0 International License, which permits use, sharing, adaptation, distribution and reproduction in any medium or format, as long as you give appropriate credit to the original author(s) and the source, provide a link to the Creative Commons licence, and indicate if changes were made. The images or other third party material in this article are included in the article's Creative Commons licence, unless indicated otherwise in a credit line to the material. If material is not included in the article's Creative Commons licence and your intended use is not permitted by statutory regulation or exceeds the permitted use, you will need to obtain permission directly from the copyright holder. To view a copy of this licence, visit <http://creativecommons.org/licenses/by/4.0/>. The Creative Commons Public Domain Dedication waiver (<http://creativecommons.org/publicdomain/zero/1.0/>) applies to the data made available in this article, unless otherwise stated in a credit line to the data.

Background

Adult spinal deformity (ASD) has become a common spinal disorder in the aging population. Patients with ASD often present with severe low back pain and a diminished quality of life. Accordingly, the number of surgical procedures for ASD with the aim of reducing pain and improving the quality of life has increased. However, the surgical treatment for ASD is a major undertaking that can be accompanied by a wide range of postoperative complications [1–3]. One of the most common mechanical complications following spinal fusion surgery is proximal junctional kyphosis (PJK) [1]. Some studies have reported that the occurrence of PJK ranges from 20 to 61% [4–6] and causes degenerative changes or fracture at the proximal level next to the fusion segments [7, 8]. PJK is often problematic and can adversely influence the functional and neurological outcomes, and often requires further surgical intervention [9]. Preventing mechanical complications is a key factor in maintaining good radiological and clinical outcomes [10–12].

Proximal junctional failure (PJF) is often induced by fractures of the upper instrumented vertebra (UIV) and/or posterior complex of the ligaments. In severe cases, myelopathy can occur from cord compression [13]. PJF frequently requires surgical revision for correction and decompression of the spinal cord. The rate of PJF following surgery for ASD varies widely in the literature and is estimated to be between 1% and 35% [11, 14]. The incidence of neurological deficit associated with PJF has been poorly described. One study reported a rate of

myelopathy following PJF or PJK was 11.4% [14]. Delayed diagnosis is likely to cause permanent paralysis, and several preventive methods have been reported [15]. PJF with myelopathy should be diagnosed and surgically corrected early to minimize permanent neurological injury [13].

Here, we report a case in which numbness in the lower extremities was recognized as the first symptom of PJF with myelopathy, but the diagnosis was delayed because of the lack of evidence of spinal cord compression on static images.

Case presentation

A 71-year-old woman presented with low back pain related to kyphoscoliosis and flat back syndrome. She had a past medical history of osteoporosis (bone mineral density: 0.633 g/cm^2 , T score: -2.5) and osteoporotic vertebral fracture at L2. She underwent corrective fusion surgery involving T10 to sacrum fusion with instrumentation including iliac fixation (Fig. 1). The preoperative parameters were: lumbar lordosis, 7° ; sacral slope, 30° ; sagittal vertical axis, 252 mm; and thoracic kyphosis, 23° . The pelvic incidence was 75° .

The patient started walking with the help of several assistants 5 days after surgery. Three weeks later, she complained of persistent right leg numbness. A standing X-ray showed back-out of the pedicle screws (PSs) in the UIV at T10 (Fig. 2a, b). However, there was no obvious evidence of cord compression on computed tomography (CT) (Fig. 2c). Five weeks later, the numbness had

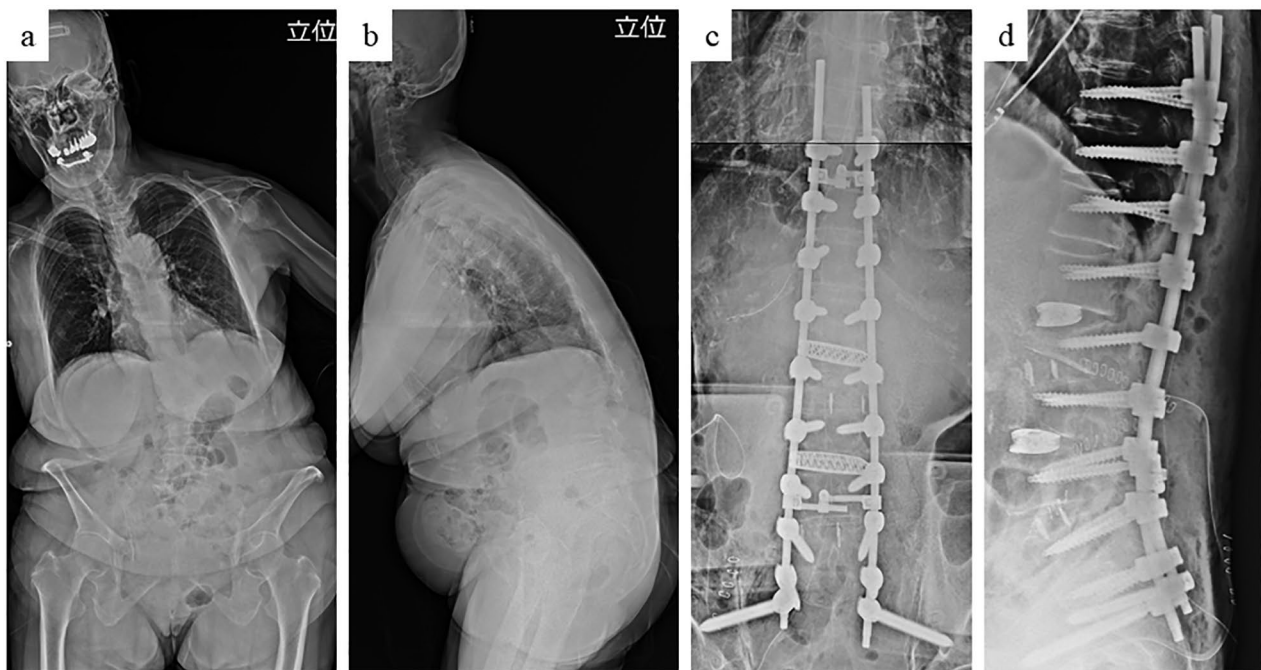


Fig. 1 Standing X-ray before (a, b) and during (c, d) the operation

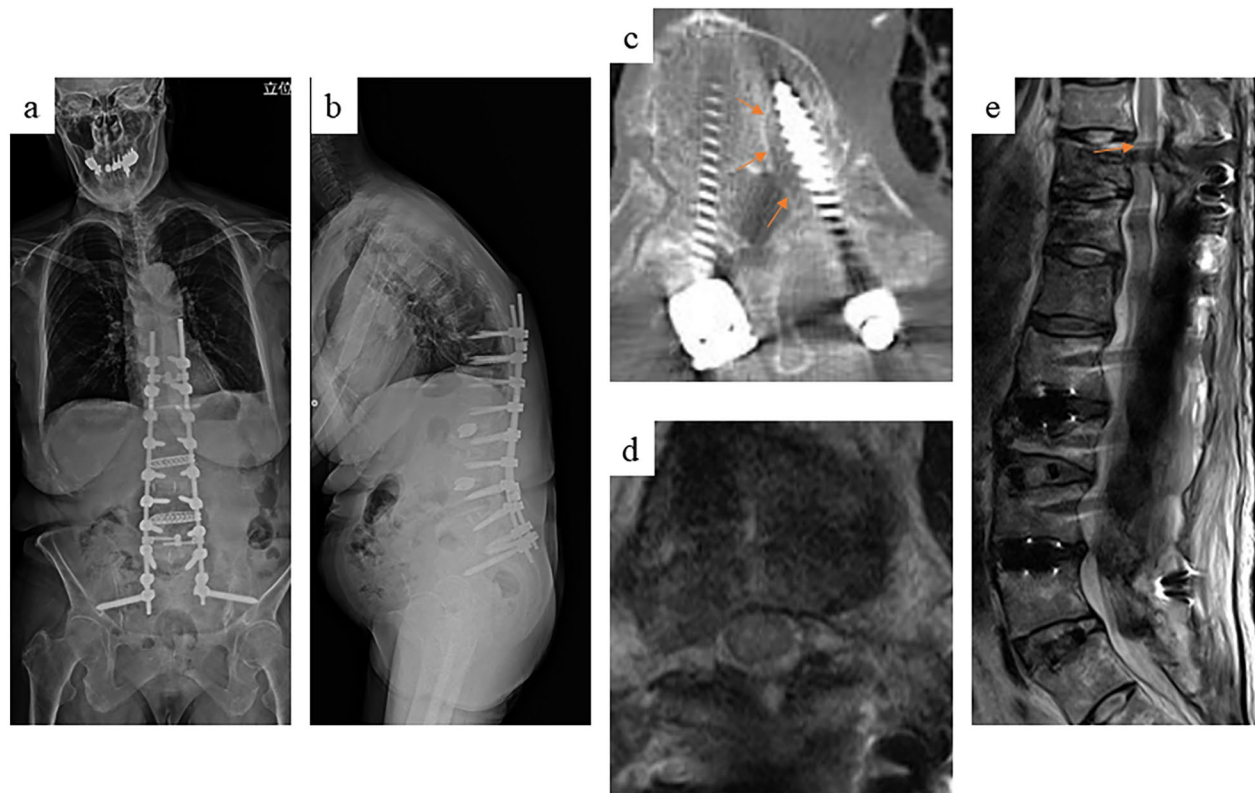


Fig. 2 Standing X-ray 1 week after surgery showing back-out of the pedicle screws at the upper instrumented vertebrae (a, b). Computed tomography showing a clear zone around the loosened pedicle screws but no migration into the spinal canal (c). Magnetic resonance imaging also showed that the pedicle screws did not compress on the spinal cord in the axial view (d). However, several signal changes in the spinal cord were visible in the sagittal view (e)

worsened and extended from the right sole and dorsum of her foot through the entire lower extremity up to her groin. In addition, she developed muscle weakness in her left lower leg. Manual muscle test results were as follows: quadriceps, 2/2 (right/left); tibialis anterior muscle, 2/3; gastrocnemius, 2/3; extensor hallucis longus, 2/2; and flexor hallucis longus, 2/2. Both sides of the patellar tendon exhibited hyperflexion. There were no urinary symptoms. Magnetic resonance imaging (MRI) showed no obvious cord compression in the axial view, but there was a hyperintense signal change in the spinal cord at the level of T10 in the T2-weighted sagittal image (Fig. 2d, e).

We suspected the pathology involved dynamic cord compression induced by loosening of the PSs. The patient underwent revision surgery to remove the loosened PSs at T10 and to extend the fusion and fixation to T5 (Fig. 3). The patient was placed carefully in the prone position during surgery, and we checked to ensure there were no differences in the transcranial motor evoked potentials between the supine and prone positions. Following this procedure, her leg weakness and numbness improved. She had no neurological symptoms 1 year after surgery.

Discussion

We have described a rare case of spinal cord compression induced by loosening of the PSs in the UIV following ASD surgery. The standing images showed back-out of the loosened PSs, but no compression of the spinal cord was visible on supine MRI and CT. This lack of compression contributed to the delay in the diagnosis and revision surgery despite progression of the patient's neurological symptoms. This case illustrates the importance of recognizing the dynamic aspect of PJE, which can lead to neurological impairment if left untreated.

The first reason for the delayed diagnosis was the lack of awareness that unilateral foot numbness can occur as the first symptom of thoracic myelopathy associated with PJE. There is no report in the literature of foot numbness as the initial presenting symptom caused by spinal cord compression following PJK. Preoperative predictors of PJK and PJE have been studied extensively. The risk factors for PJK and PJE include advanced age, low bone quality, postmenopausal status, preoperative sagittal imbalance, severity of thoracic kyphosis, and preoperative pelvic incidence and lumbar lordosis mismatch [16–18]. Our patient displayed these risk factors.

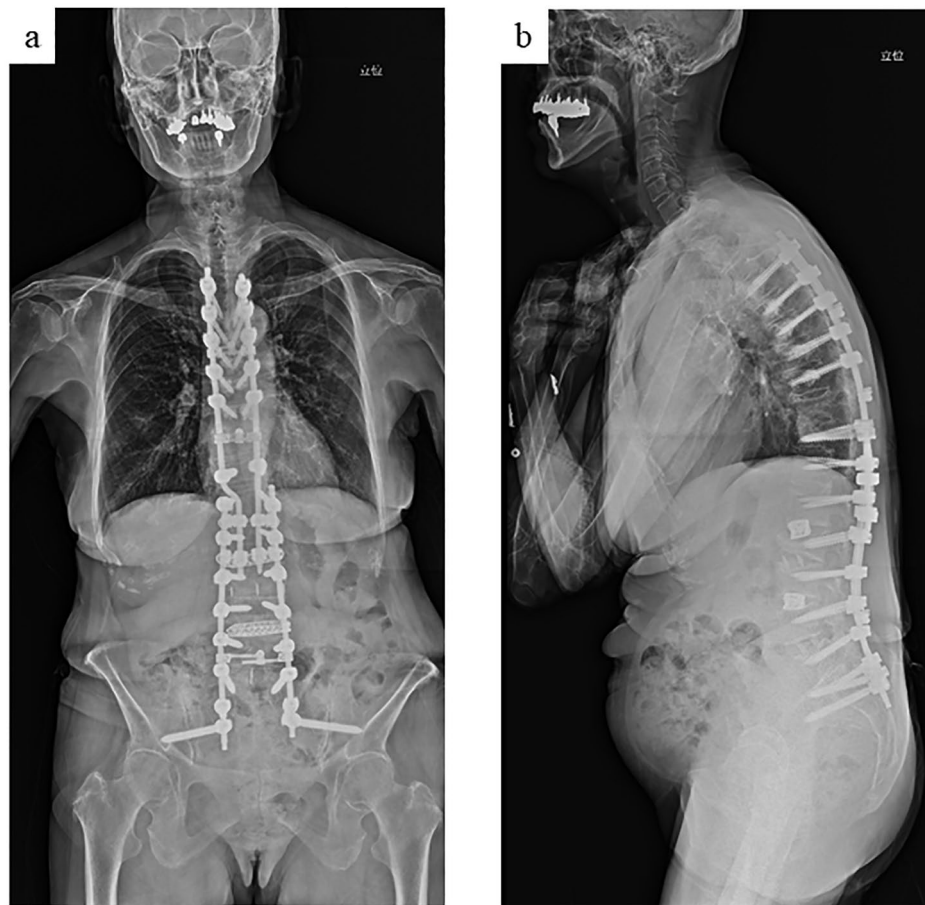


Fig. 3 Standing X-ray after revision surgery. We removed the loosened pedicle screws at T10 and extended the fusion surgery to T5

Previous reports have shown that the presenting symptoms of PJK and PJF are mostly back pain, metal prominence at the UIV, and recurrent kyphotic deformity caused by loosening and back-out of the proximal screws and implants [19, 20]. Neurological deficits associated with spinal cord compression at the lower thoracic segments include muscle weakness and numbness of the lower extremities and possible bowel and bladder dysfunction. However, this patient initially presented with only unilateral foot numbness.

Previous studies have reported that the spinothalamic tract on the lateral side of the spinal cord can cause symptoms in the lower limbs [21]. The sacral segments are located at the most lateral component of the spinothalamic tract, and the lumbar and thoracic components are arranged in that order and proceed medially toward the central canal of the thoracic spine [22, 23]. Similarly, the corticospinal tract comprises the cervical, thoracic, lumbar, and sacral segments from the inside at the thoracic lesion [22, 23]. Therefore, in this case, the loosened PSs may have caused impingement in the lumbar and sacral regions of the lateral side of the spinal cord or the

distal lumbar and sacral tracts within the spinal cord. The loosening of the PSs may have shifted them from the pedicle into the spinal canal and compressed the lateral side of the spinal cord.

The second problem was the lack of evidence for spinal cord compression on various imaging tests. The diagnosis of spinal cord compression associated with PJF is relatively straightforward on MRI. One of the causes of PJF is adjacent vertebral body fracture and intervertebral disc herniation. The intervertebral disc above the UIV withstands excess stress and, as a result, the intervertebral disc may rupture or the vertebral body may fracture, and the ligamentum flavum may buckle from the dorsal side, which compresses the spinal cord.

MRI and CT are accurate for assessing changes in the intervertebral disc, fracture, and associated spinal cord compression and cord edema [19, 24]. However, one study reported that supine MRI and CT may miss the spinal cord compression induced by dynamic instability [25]. The authors of that study reported two cases in which long thoracic fusion surgery induced a vertebral fracture at the distal side that was accompanied

by dynamic instability. Supine imaging showed almost normal alignment, but a sitting X-ray revealed severe kyphotic alignment [25]. Another study reported that long thoracolumbar fusion surgery in a patient with diffuse idiopathic skeletal hyperostosis caused PJF or fracture and more severe dynamic instability [26]. The extension radiograph in that study showed normal alignment, but an X-ray in the flexed position showed subluxation and severe kyphotic posture. In our case, a standing X-ray showed back-out of the loosening PSs, but the CT and MRI, which were both taken in the supine position, showed no evidence of screw penetration into the canal or cord compression. It is likely that the loosened PSs were displaced into the canal and caused repeated spinal cord impingement or contusion during standing and trunk movement in this patient.

Conclusions

We have described a case of PJF following surgery for ASD in which numbness in the lower extremity was initially the only symptom recognized. The diagnosis of spinal cord compression was delayed because of the apparent lack of spinal canal stenosis or screw impingement on static images. This pathology was thought to result from the loosened PSs at the UIV, which caused dynamic cord compression. In this case, the reoperation fortunately helped to restore spinal cord function; however, a missed or delayed diagnosis might result in permanent spinal cord dysfunction in other patients. This case report illustrates the importance of assessing the patient's postoperative complaints, such as numbness in the extremity, which may result from thoracic spinal cord compression. If the neurological symptom persists, the clinician should consider spinal cord compression associated with PJF in patients who have received long fusion constructs. Seemingly normal MRI or CT results do not necessarily rule out spinal cord compression caused by dynamic instability. Whenever possible, supine and standing radiographs should be obtained along with static MRI/CT to allow the prompt diagnosis of spinal cord compression.

Acknowledgements

Not applicable.

Authors' contributions

Takahiro Kozaki, and Hiroshi Yamada designed the study; Takuhei Kozaki, and Takahiro Kozaki performed experiments and analyzed the data; Hiroshi Yamada, Takuhei Kozaki, Keiji Nagata, Shunji Tsutsui and Yusuke Noda performed surgery; Takahiro Kozaki, Takuhei Kozaki, Howard An, and Hiroshi Yamada wrote the manuscript; Takahiro Kozaki, Takuhei Kozaki, and Hiroshi Yamada prepared Figs. 1, 2 and 3.

Funding

Not applicable.

Availability of data and material (ADM)

The datasets used and/or analysed during the current study available from the corresponding author on reasonable request.

Declarations

Ethics approval and consent to participate

Not applicable. Written consent to publish was obtained from the patients herself. Informed consent to allow the patient's data to be stored was obtained from the patient per letter.

Consent for publication

Written informed consent was obtained from the patient for the publication of this case report and any accompanying images in an online open-access publication. A copy of the written consent form is available for review by the editor of this journal.

Competing interests

The authors declare no competing interests.

Received: 22 May 2023 / Accepted: 9 August 2023

Published online: 24 August 2023

References

1. Soroceanu A, Diebo BG, Burton D. Radiographical and implant-related complications in adult spinal deformity surgery: incidence, patient risk factors, and impact on health-related quality of life. *Spine (Phila Pa 1976)*. 2015;40(18):1414–21.
2. Lertodomphonwanit T, Kelly MP, Bridwell KH, Lenke LG, McAnany SJ, Punyarat P, et al. Rod fracture in adult spinal deformity surgery fused to the sacrum: prevalence, risk factors, and impact on health-related quality of life in 526 patients. *Spine J*. 2018;18(9):1612–24.
3. Kozaki T, Hashizume H, Nishiyama H, Iwasaki H, Tustsui S, Takami M, et al. Adjacent segment disease on hip joint as a complication of spinal fusion surgery including sacroiliac joint fixation. *Eur Spine J*. 2021;30(5):1314–9.
4. Yagi M, Akilah KB, Boachie-Adjei O. Incidence, risk factors and classification of proximal junctional kyphosis: surgical outcomes review of adult idiopathic scoliosis. *Spine (Phila Pa 1976)*. 2011;36(1):E60–8.
5. Kim YJ, Bridwell KH, Lenke LG, Glattes CR, Rhim S, Cheh G. Proximal junctional kyphosis in adult spinal deformity after segmental posterior spinal instrumentation and fusion: minimum five-year follow-up. *Spine (Phila Pa 1976)*. 2008;33(20):2179–84.
6. Lee JH, Kim JU, Jang JS, Lee SH. Analysis of the incidence and risk factors for the progression of proximal junctional kyphosis following surgical treatment for lumbar degenerative kyphosis: minimum 2-year follow-up. *Br J Neurosurg*. 2014;28(2):252–8.
7. Alentado VJ, Lubelski D, Healy AT, Orr RD, Steinmetz MP, Benzel EC, et al. Predisposing characteristics of adjacent segment disease after lumbar fusion. *Spine (Phila Pa 1976)*. 2016;41(14):1167–72.
8. Hillbrand AS, Robbins M. Adjacent segment degeneration and adjacent segment disease: the consequences of spinal fusion? *Spine J*. 2004;4(6):190–4.
9. Luo M, Wang P, Wang W, Shen M, Xu G, Xia L. Upper thoracic versus lower thoracic as site of upper instrumented vertebrae for long fusion surgery in adult spinal deformity: a meta-analysis of proximal junctional kyphosis. *World Neurosurg*. 2017;102:200–8.
10. Glattes RC, Bridwell KH, Lenke LG, Kim YJ, Rinella A, Edwards C 2. Proximal junctional kyphosis in adult spinal deformity following long instrumented posterior spinal fusion: incidence, outcomes, and risk factor analysis. *Spine (Phila Pa 1976)*. 2005;30(14):1643–9.
11. Hostin R, McCarthy I, O'Brien M, Bess S, Line B, Boachie-Adjei O, et al. Incidence, mode, and location of acute proximal junctional failures after surgical treatment of adult spinal deformity. *Spine (Phila Pa 1976)*. 2013;38(12):1008–15.
12. O'Shaughnessy BA, Bridwell KH, Lenke LG, Cho W, Baldus C, Chang MS, et al. Does a long-fusion "T3-sacrum" portend a worse outcome than a short-fusion "T10-sacrum" in primary surgery for adult scoliosis? *Spine (Phila Pa 1976)*. 2021;37(10):884–90.

13. Piazza M, Sullivan PZ, Madsen P, Branche M, McShane B, Saylany A, et al. Proximal junctional kyphosis following T10-pelvis fusion presenting with neurologic compromise: case presentations and review of the literature. *Br J Neurosurg.* 2020;34(6):715–20.
14. Yagi M, Rahm M, Gaines R, Maziad A, Ross T, Kim HJ, et al. Characterization and surgical outcomes of proximal junctional failure in surgically treated patients with adult spinal deformity. *Spine (Phila Pa 1976).* 2014;39(10):E607–14.
15. Lau D, Funao H, Clark AJ, Nicholls F, Smith J, Bess S, et al. The clinical correlation of the Hart-ISSG proximal junctional kyphosis severity scale with health-related quality-of-life outcomes and need for revision surgery. *Spine (Phila Pa 1976).* 2016;41(3):213–23.
16. Watanabe K, Lenke LG, Bridwell KH, Kim YJ, Koester L, Hensley M. Proximal junctional vertebral fracture in adults after spinal deformity surgery using pedicle screw constructs: analysis of morphological features. *Spine (Phila Pa 1976).* 2010;35(2):138–45.
17. Etebar S, Cahill DW. Risk factors for adjacent-segment failure following lumbar fixation with rigid instrumentation for degenerative instability. *J Neurosurg.* 1999;90(2 Suppl):163–9.
18. Toyone T, Ozawa T, Kamikawa K. Subsequent vertebral fractures following spinal fusion surgery for degenerative lumbar disease: a mean ten-year follow-up. *Spine (Phila Pa 1976).* 2010;35(21):1915–8.
19. Yagi M, King AB, Boachie-Adjei O. Incidence, risk factors, and natural course of proximal junctional kyphosis: surgical outcomes review of adult idiopathic scoliosis. Minimum 5 years of follow-up. *Spine (Phila Pa 1976).* 2012;37(17):1479–89.
20. Kim YJ, Bridwell KH, Lenke LG, Rhim S, Cheh G. Sagittal thoracic decompensation following long adult lumbar spinal instrumentation and fusion to L5 or S1: causes, prevalence, and risk factor analysis. *Spine (Phila Pa 1976).* 2006;31(20):2359–66.
21. Kozaki T, Minamide A, Iwasaki H, Yukawa Y, Ando M, Yamada H. Funicular pain: a case report of intermittent claudication induced by cervical cord compression. *BMC Musculoskelet Disord.* 2020;21:302.
22. Forester O. Symptomatology der Erkrankungen des Ruckemarks und seiner Wurzeln. *Bumke u Foersters Handb Neurol.* 1936;5:1–403.
23. Schneider RC, Cherry G, Pantek H. The syndrome of acute central cervical spinal cord injury; with special reference to the mechanisms involved in hyperextension injuries of cervical spine. *J Neurosurg.* 1954;11(6):546–77.
24. Jang HJ, Park JY, Kuh SU. The fate of proximal junctional vertebral fractures after long-segment spinal fixation: are there predictable radiologic characteristics for revision surgery? *J Korean Neurosurg Soc.* 2021;64(3):437–46.
25. Hosthota A, Govindasamy R, Rudrappa S. Distal junctional failure secondary to nontraumatic fracture of lower instrumented vertebra: our experience and review of literature. *Int J Spine Surg.* 2021;15(5):1031–8.
26. Ikegami D, Matsuoka T, Miyoshi Y, Murata Y, Aoki Y. Proximal junctional failure after long-segment instrumentation for degenerative lumbar kyphosis with ankylosing spinal disorder. *Spine (Phila Pa 1976).* 2015;40(12):E740–3.

Publisher's Note

Springer Nature remains neutral with regard to jurisdictional claims in published maps and institutional affiliations.