

CASE REPORT

Open Access



Maternal septicemia caused by *Streptococcus mitis*: a possible link between intra-amniotic infection and periodontitis. Case report and literature review

Piya Chaemsaitong^{1*}, Waranyu Lertrut¹, Threebhorn Kamlungkuea¹, Pitak Santanirand², Arunee Singaneh^{2*}, Adithep Jaovisidha¹, Sasikarn Pakdeeto³, Paninee Mongkolsuk³ and Pisut Pongchaikul^{3,4,5*} 

Abstract

Background: Intra-amniotic infection has a strong causal association with spontaneous preterm birth and preterm prelabor rupture of membranes (PPROM). The most common route of intra-amniotic infection is the ascending pathway in which microorganisms from the vagina gain access to the amniotic cavity. Distant microorganisms such as those from the oral cavity have been reported in intra-amniotic infection through hematogenous spreading.

Case presentation: A 31-year-old gravida 1, para 0 Thai woman at 33⁺⁶ weeks' gestation presented with leakage of vaginal fluid and irregular uterine contraction. She developed fever at 4 h after admission and was later diagnosed with acute chorioamnionitis. A Cesarean section was performed to terminate pregnancy. In addition to a blood culture, the cultures of amniotic fluid, vaginal and chorioamniotic membrane swabs were positive for *Streptococcus mitis* with identical susceptibility profiles. After the delivery and antibiotic prescription, oral examination showed dental caries and chronic periodontitis.

Conclusions: This is the first case report demonstrating maternal septicemia and intra-amniotic infection caused by *S. mitis* which might be attributed to periodontitis in women presenting with preterm PROM. We highlighted the association of periodontal disease and preterm labor/PROM syndrome. Oral cavity examination should be included in the prenatal care to ensure good dental hygiene.

Keywords: Chorioamnionitis, Dental caries, Intra-amniotic infection, Microbial invasion of amniotic cavity, Periodontal disease, Periodontitis, Preterm, Preterm PROM, Septicemia

*Correspondence: piya.cha@mahidol.ac.th; arunee.sig@mahidol.ac.th; pisut.pongchaikul@gmail.com; pisut.pon@mahidol.edu

¹ Department of Obstetrics and Gynecology, Faculty of Medicine, Ramathibodi Hospital, Mahidol University, 270 Rama VI Rd. Ratchathewi, Bangkok 10400, Thailand

² Department of Pathology, Faculty of Medicine, Ramathibodi Hospital, Mahidol University, 270 Rama VI Rd. Ratchathewi, Bangkok 10400, Thailand

³ Chakri Naruebodindra Medical Institute, Faculty of Medicine, Ramathibodi Hospital, Mahidol University, 111 Bang Pla, Bang Phli, Samut Prakan 10540, Thailand

Full list of author information is available at the end of the article

Background

Intra-amniotic infection and/or inflammation is causally linked with spontaneous preterm birth and preterm prelabor rupture of membranes (PPROM) [1, 2]. The frequencies of intra-amniotic infection/inflammation in preterm labor and PPRM are approximately 30% and 50%, respectively [1–7]. While an ascending migration from the vagina is preponderant, pathogens may also gain access to the amniotic cavity by other pathways such as hematogenous dissemination or accidental introduction



at the time of an invasive prenatal procedure [1, 2, 8–14]. Bearfield et al. identified similar strains of *Fusobacterium nucleatum* (*F. nucleatum*) and *Streptococcus* spp. from dental plaque and amniotic fluid, which suggests an oral origin of amniotic fluid microorganism infection [15]. Subsequently, other oral bacteria such as *Capnocytophaga* spp., *Rothia dentocariosa* and *Eikenella corodens* have also been detected in amniotic fluid [15–24].

Streptococcus mitis (*S. mitis*), a member of viridans streptococci, is prevalent in the normal flora in the oropharynx [25, 26]. There have thus far been two case reports of acute histological chorioamnionitis caused by *S. mitis* [27, 28]. Both studies showed that *S. mitis* was identified in placental culture. Antecedent cunnilingus and dental scaling are proposed to be associated with *S. mitis* infection [28]. One report described that *S. mitis* is one of the polymicrobial microorganisms detected in the mid-trimester amniotic fluid of women who subsequently had fetal death [29].

Herein, we reported a unique case of *S. mitis* septicemia in a woman presenting with PPRM and clinical chorioamnionitis. Samples of amniotic fluid, vagina, chorioamnionic membranes, and maternal blood were taken for aerobic cultures. The results demonstrated similar strains of *S. mitis*. The patient was subsequently confirmed to have deep dental caries and chronic periodontitis. This is the first case report demonstrating septicemia, clinical chorioamnionitis and intra-amniotic infection may be presumably due to chronic periodontitis.

Case presentation

A 31-year-old gravida 1, para 0 Thai woman at 33 weeks and 6 days of gestation presented at the labor and delivery unit due to the leakage of amniotic fluid at 26 h prior to the admission. Her antenatal care was unremarkable except for morbid obesity (body mass index 44.5 kg/m²) and pre-gestational diabetes. She was administered 81 mg of aspirin and 16 units of insulin daily. Her fasting and two-hour postprandial blood sugar ranged between 106–123 and 99–131 mg/dL, respectively. Her blood test, serology and ultrasound abnormality examination were normal. She had no underlying disease and denied a history of smoking, alcoholic drinking, or illicit drug use.

At 33⁺⁶ weeks' gestation, she complained of vaginal leaking fluid and irregular uterine contraction 26 h prior to the admission. She had no fever or vaginal bleeding. Her fetal movement was good. Her vital signs showed no abnormalities. A dry sterile speculum examination revealed clear pooling fluid in the vagina with positive cough and nitrazine tests. Vaginal examination showed the cervix was 2 cm dilated with the effacement of 25%. Her white blood cell count (WBC) was 13,450 cells/mm³ with 80% neutrophil. Urinalysis was normal. External fetal monitoring demonstrated normal fetal heart

rate and variability. Transabdominal ultrasonography examination demonstrated that the fetal growth was normal; however, the amniotic fluid index was only 2 cm. Therefore, we did not perform any amniocentesis for the determination of intra-amniotic infection/inflammation status. Expectant management was performed; steroid as well as antibiotic therapy (intravenous ampicillin, azithromycin) were given to promote lung maturity and prolong latency period, respectively.

The patient developed fever (38.2 °C) around 4 h after admission. Her pulse and blood pressure were 90 bpm and 121/71 mmHg, respectively. Continuous cardiotocography demonstrated a fetal heart rate of 165 bpm with moderate variability. Uterine contractions were 3-min intervals with moderate intensity. No uterine tenderness or foul-smelling discharge was found. Her WBC and C-reactive protein (CRP) were elevated (WBC 17,940 cells/mm³ with 85.4% neutrophil, CRP 24.36 mg/dL). Clinical chorioamnionitis was diagnosed and oxytocin was given to augment labor progression. The antibiotics were changed to intravenous ceftriaxone (2 g/every 24 h), intravenous metronidazole (500 mg/every 8 h), and oral clarithromycin (500 mg/every 8 h) to treat intra-amniotic infection as recommended in previous studies [30–33]. Her cervical progression was arrested at 4 cm for 4 h; hence, Cesarean delivery was performed. She delivered a male fetus with Apgar score of 8, 10 at 1 min and 5 min after delivery, respectively. Birth weight of the baby was 2680 g.

After delivery, she received similar antibiotics. Cultivation of blood culture (taken at the time of fever), amniotic fluid obtained during Cesarean delivery, vaginal swab (obtained at the time of hospital admission) and placental swab (chorioamnionic membranes) revealed bacterial colonies identified as *S. mitis* (Fig. 1). Gram stain from enriched hemoculture showed Gram positive cocci in chains (Fig. 2). Interestingly, antibiotic sensitivity profiles from all specimens were similar (Table 1). Since her male neonate had respiratory distress, and severe hypoglycemia (blood sugar 16 mg/dL), which could be the sign of early onset neonatal sepsis, he was diagnosed with presumed sepsis requiring treatment. The diagnosis of presumed sepsis was based on intrapartum risk factor which involves the presence of intra-amniotic infection and the presence of respiratory distress as well as severe hypoglycemia requiring treatment in neonate [34]. Although, his WBC count, hemoculture and chest x-ray were within normal limits, infection could be present in the newborn. CRP value could be in normal limit due to low CRP value in preterm newborns. Therefore, he was given intravenous ampicillin and gentamicin for 7 days which is based on the recommendation by the American Academy of Pediatrics and the Centers for Disease Control and Prevention (CDC) [35, 36].

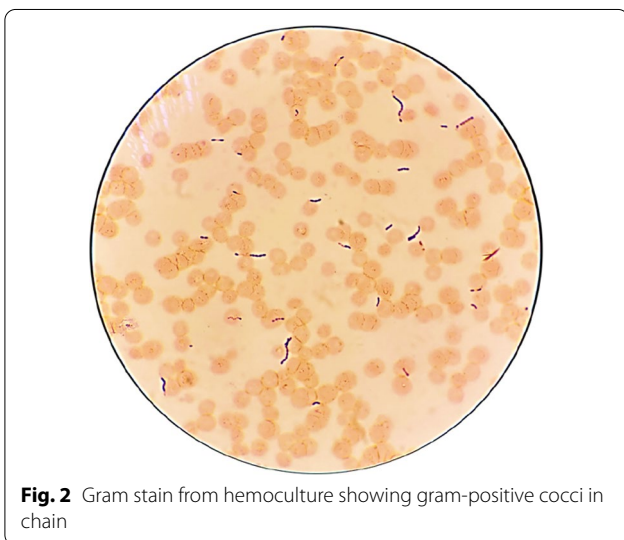
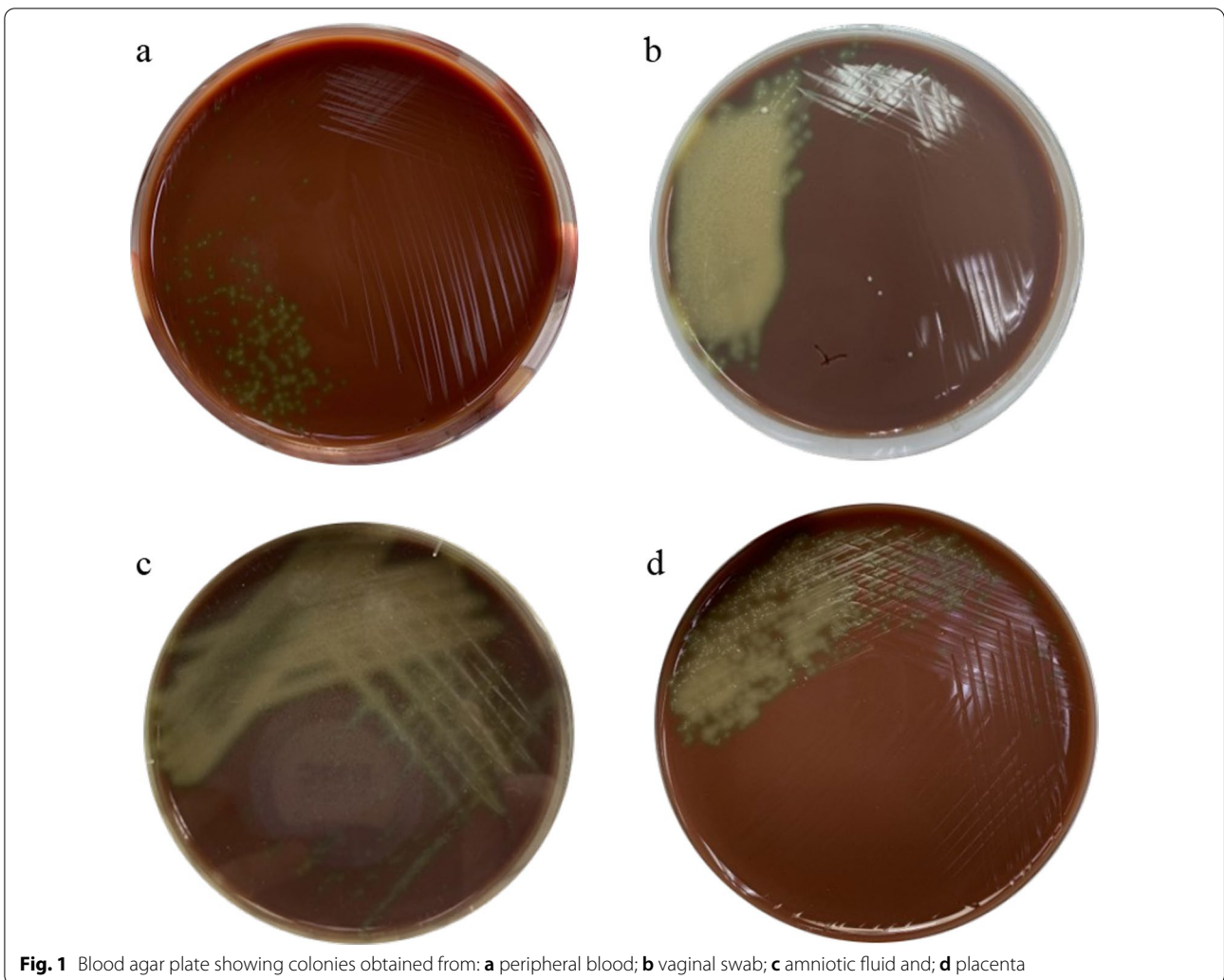


Table 1 Antibiotics sensitivity profile of the organisms derived from maternal blood, amniotic fluid, vaginal and placental cultures

Antibiotics	MIC	Interpretation
Penicillin	4 ug/mL	Resistant
Ampicillin	8 ug/mL	Resistant
Vancomycin	0.5 ug/mL	Sensitive
Clindamycin	> 2 ug/mL	Resistant
Daptomycin	≤ 0.5 ug/mL	Sensitive
Erythromycin	> 4 ug/mL	Resistant
Levofloxacin	> 8 ug/mL	Resistant
Tetracycline	> 16 ug/mL	Resistant

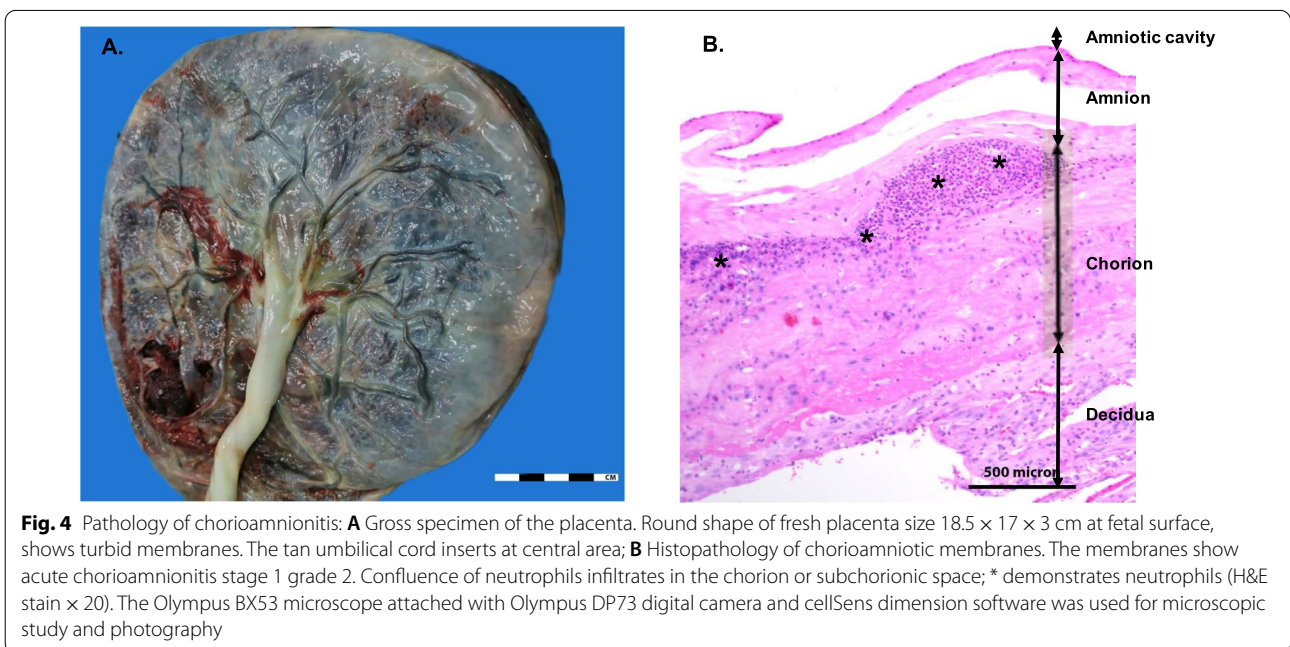
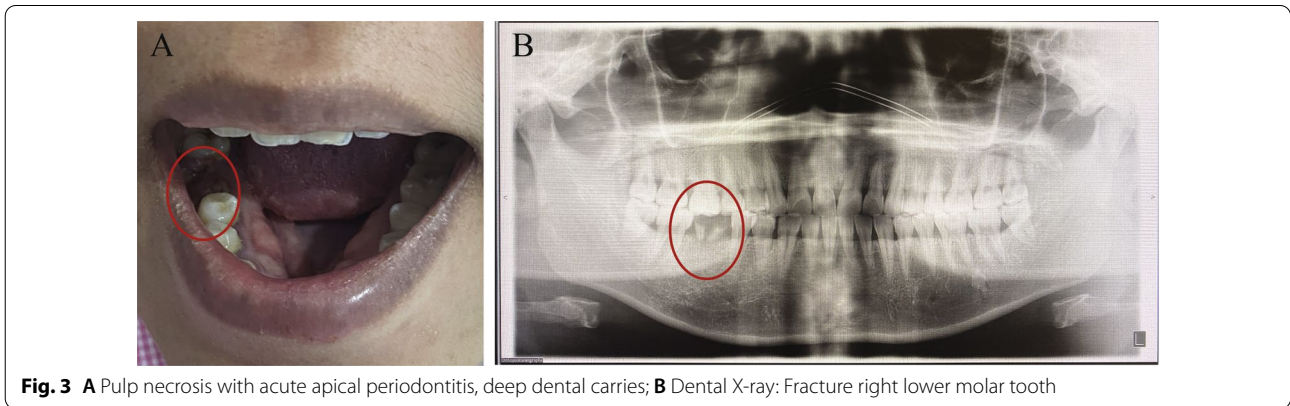
MIC: Minimum inhibitory concentration

Since the patient was diagnosed with septicemia and *S. mitis* is usually found in the oral cavity, we consulted a dentist and an infectious consultant to determine the source of infection. Dental examination showed multiple dental caries with nearly exposed pulp, pulp necrosis and acute apical periodontitis (Fig. 3). Tooth extraction and curettage were performed. Vancomycin was intravenously administered for 1 week according to antibiotic sensitivity profile. At 6th week postpartum, her vaginal and dental caries bacterial culture demonstrated no *S. mitis*, and her clinical course was unremarkable. Placental histopathological examination confirmed acute histological chorioamnionitis stage 1 grade 2 (Fig. 4A and B). Gram positive cocci in chains was identified at chorioamniotic membranes. Retrospectively, the patient denied oral sexual intercourse during pregnancy. She reported that she subjectively had dental caries 1 year ago but did

not get the treatment. The last time that she saw the dentist was more than 10 years. She did not receive dental treatment during this pregnancy. “Her partner denied having periodontal disease; however, he did not have a clinical assessment performed to determine periodontal disease status.”

Discussion and conclusions

We reported a unique case with intra-amniotic infection, clinical chorioamnionitis and septicemia from *S. mitis* in a woman presenting with PPRM. Interestingly, the profiles of antibiotic sensitivity are identical among bacteria derived from amniotic fluid, vagina, chorioamniotic membranes and maternal blood, which suggests a similar bacterial strain. Multiple tooth decay and periodontitis were subsequently revealed. These observations suggested a link between periodontal disease and



intra-amniotic infection. This is the first case report demonstrating maternal septicemia and intra-amniotic infection caused by *S. mitis* associated with periodontitis in the women presenting with PROM.

Periodontal disease is defined as a wide range of chronic inflammatory conditions of the gingiva (also called gums, the soft tissue surrounding the teeth), bone and ligament (the connective tissue collagen fibers anchoring the tooth to alveolar bone) that altogether support the teeth [37–39]. The initial stage usually begins with localized inflammation of the gingiva or “gingivitis” caused by bacteria in the dental plaque, a biofilm of microorganisms observed in the tooth surface [37–40]. Subsequently, untreated gingivitis leads to “chronic periodontitis” affecting surrounding epithelial tissues, the gingiva, alveolar bone and periodontal ligament, and eventually leads to tooth loss [37–39].

Accumulating evidence has shown that there is a relationship between periodontal disease and spontaneous preterm labor. The latest systematic review and meta-analysis including 16 case–control and 4 cohort studies demonstrated that periodontitis increases the risk of preterm birth about twofold (odd ratios 2.01; 95% confidence interval 1.71–2.36) [41]. However, the definition of periodontitis is inconsistent among these studies [41]. Proposed mechanisms whereby periodontitis is associated with preterm labor are thought to be related to systemic inflammation [34, 39–41]. Oral pathogens could enter the maternal bloodstream and amniotic cavity causing inflammatory cascade in the fetoplacental unit triggering a common pathway of preterm labor [1, 2, 12, 42–44]. In animal studies, intravenous injection of *F. nucleatum* into pregnant mice resulted in premature delivery and stillbirths [42]. *F. nucleatum* colonizes in the uterus, amniotic fluid, and the placenta through hematogenous route [23]. In addition, oral pathogens such as *Streptococcus* spp., *F. nucleatum*, *Eikenella corodens*, and *Campylobacter* species are detected in the amniotic fluid of women with preterm labor or second trimester abortion [15–24]. In addition, dysbiosis of the placental microbiome has been reported to be associated with preterm birth [43–49]. Aagaard et al. characterized the placental microbiome using the metagenomic data derived from 16S rDNA as well as the whole genome sequencing and demonstrated that the placenta has a low abundance of microbiome composed of nonpathogenic commensal microbiota from the Proteobacteria, Tenericutes, Firmicutes, Bacteroidetes and Fusobacteria phyla. Importantly, such placental microbiome was shown to be most similar to the oral microbiome, and it is also associated with preterm birth [43]. Subsequently, several studies have determined placental microbiome dysbiosis in women with preterm birth [43–55]. However, it is still unclear

whether periodontal therapy can reduce the frequency of preterm labor [46, 47].

Streptococcus mitis was first isolated and discovered by Andrews and Horder in 1986 from the human oropharynx [56]. The genus name ‘mitis’, based on the Latin root ‘mitis’, means “mild”, indicating low pathogenicity and virulence involved in different types of mild infections [26]. This species is a predominant pioneer colonizer of the oral cavity after birth and persists through life [57]. It also colonizes in other areas of the human body such as the skin, and the gastrointestinal and genital tracts as a part of the normal flora [26] although its presence in the vaginal flora is rare (2%) [58]. In the oropharynx, *S. mitis* is thought to form oral biofilms by supplying adherence sites for secondary colonizers [26, 59]. This bacterium can cause a variety of infectious complications including bacterial infective endocarditis, bacteremia, septicemia, meningitis, eye infections, and pneumonia, especially in elderly patients or immunocompromised patients [25, 28]. Currently, mortality rate from *S. mitis* bacteremia has not been reported. Nevertheless, mortality rates from viridans *Streptococcus* bacteremia range from 6 to 30% in immunocompromised hosts [60]. *S. mitis* colonizes the human oropharynx by several mechanisms including the expression of adhesins, production of immunoglobulin A proteases, and modulation of the host immune response [25, 26, 28]. Moreover, comparative genomic analysis confirms the presence of virulence genes such as hyaluronic acid synthesis-associated genes, which promote colonization and prevent bacteria from phagocytosis [61]. Importantly, bacteremia (including *S. mitis*) can occur after tooth brushing or other dental procedures [62–65]. The number of *S. mitis* significantly increases during pregnancy and is associated with dental caries, especially during the second and third trimester [66]. *S. mitis* has been infrequently isolated in the amniotic fluid of women with preterm labor (1.8%) [3, 5, 6], PPROM (2–3%) [4, 7] or short cervix (0.4%) [67].

Two previous reports discussed *S. mitis* in women with preterm labor and chorioamnionitis [27, 28]. Schmiedel et al. reported that *S. mitis* was identified from placental and fetal membranes by cultivation, fluorescence in situ hybridization and DNA sequencing techniques in women with clinical chorioamnionitis [27]. In this study, *S. mitis* could be identified only in the superficial layers of the fetal membranes but was found to be absent in the placental tissue, thereby indicative of ascending infection. However, there were no results of vaginal, blood or amniotic fluid microbiological examination. In addition, the source of *S. mitis* was not evaluated. A recent report by Hosseini et al. showed that *S. mitis* was isolated from amniotic membrane cultivation in a pregnant woman presenting with preterm labor at 21⁺⁵ weeks’ gestation

Table 2 Reported cases of acute clinical chorioamnionitis caused by *Streptococcus mitis*

Author	Year	Country	Gestational age (weeks)	Clinical presentation	Suspected risk factors	Confirmed investigations	Treatment	Pregnancy outcome
Waites et al. [29]	1984	The United States	16	Intrauterine fetal death	Retained copper IUD	Positive culture from amniotic fluid No evidence of positive culture of <i>S. mitis</i> from vaginal swab, placenta, or fetus	Post-abortion antibiotics (Metronidazole + doxycycline)	Asymptomatic intrauterine infection with intrauterine fetal death
Schmiedel et al. [27]	2014	Germany	30	Sudden onset of maternal fever and fetal tachycardia	None	Positive culture from intraoperative swabs from placenta and fetal membranes with routine culture methods and visualized on FISH analysis Vaginal swabs with routine method was negative for <i>S. Mitis</i>	Cefuroxime	Acute chorioamnionitis was diagnosed and Cesarean delivery was performed at 30 weeks' gestation
Hosseini, Hunt [28]	2020	Canada	21	Preterm labor (cervix dilated 4–5 cm) with afebrile with no evidence of any infectious symptoms	Recent dental scaling and recent cunnilingus with a partner known to have periodontal disease	<i>S. mitis</i> was isolated from a culture of amniotic membrane Placental pathology showed signs of acute chorioamnionitis including acute inflammation of placental plate chorion and acute funisitis		Delivered a male infant weight 510 g consistent with gestational age of approximately 22 weeks and died 1 h after delivery

FISH: fluorescence in situ hybridization

who had no evidence of clinical chorioamnionitis [28]. The patient had a history of dental scaling and cunnilingus with her husband who had periodontal disease about 2 weeks prior to the onset of preterm labor. The authors hypothesize that acute histological chorioamnionitis caused by *S. mitis* is attributable to dental scaling or cunnilingus. However, this case was not confirmed to have periodontal disease or intra-amniotic infection since no amniotic fluid culture was performed. Even though one study demonstrated that *S. mitis* could be transmitted from a male partner to a female partner via vaginal intercourse, the mechanism has remained unclear [68]. *S. mitis* was also identified as one of the polymicrobial microorganisms detected in mid-trimester amniocentesis in asymptomatic pregnant women who subsequently experienced fetal death at 18 weeks' gestation [29]. Other reports have shown evidence of intra-amniotic infection by viridans Streptococci and *S. mutans* in women presenting with preterm labor or short cervix [17, 18, 20, 22]. Interestingly, a successful eradication of such microorganisms is possible [17, 18, 22]. Table 2 described previous reports of *S. mitis* in acute chorioamnionitis cases.

In conclusion, we reported a PPRM case with intra-amniotic infection and septicemia caused by *S. mitis*. This particular pathogen was systematically isolated from the samples of amniotic fluid, maternal blood, vaginal and chorioamniotic membranes with similar antibiotic sensitivity profiles indicating a similar strain. Subsequently, multiple dental caries and chronic periodontitis were identified and thought to be the possible source. Although the identification of *S. mitis* in dental plaque had not been performed in our case as we already initiated antibiotic therapy, it is possible that periodontitis found in the patient could have led to a bacteremia and septicemia resulting in intra-amniotic infection and PPRM. Altogether, these observations support the hypothesis that oral bacteria can gain access into the amniotic cavity through hematogenous dissemination [43, 49]. Therefore, prenatal care should include oral cavity examination to ensure good dental hygiene [69–72]. If possible, dental care should be performed prior to pregnancy to prevent maternal septicemia or other associated infections caused by oral bacteria and to maintain overall health of pregnant woman.

We reported a case with intra-amniotic infection, clinical chorioamnionitis and septicemia caused by *S. mitis*. Dental caries or chronic periodontitis may be a source of intra-amniotic infection, thereby highlighting an association of periodontal disease and preterm labor/PROM syndrome. This is the first case report demonstrating *S. mitis* septicemia and clinical chorioamnionitis that develops from chronic periodontitis and tooth decay. We, here, support proper dental hygiene [72] and promote

dental care, including identification, prevention and treatment of oral diseases, before and during pregnancy.

Abbreviations

CRP: C-reactive protein; PROM: Prelabor rupture of membranes; PPRM: Preterm prelabor rupture of membranes; WBC: White blood cell.

Acknowledgements

We thank the patient for her permission to use the data. We gratefully thank Assistant Professor Anchalee Limrungsikul for in-depth discussion in the management of early-onset neonatal sepsis and current clinical practice guidelines. We sincerely thank staffs at labor and delivery unit, Ramathibodi hospital for cooperation and providing appropriate care to the patient. We finally thank Jitpisuth Tantasiri for proofreading and editing the manuscript.

Author contributions

PC and PP wrote the first draft of the manuscript. PC, PP, AJ and SP revised the manuscript; PC, WL, and TK collected the clinical samples and clinical information; PS, PM, and PP conducted microbiological identification; AS performed pathological examination. All authors read and approved the final manuscript.

Funding

This research project is supported by Mahidol University (Basic Research Fund: fiscal year 2022; Grant Number: BRF1-018/2565) and Faculty of Medicine Ramathibodi Hospital Mahidol University. The funding supported the cost of bacterial identification. The funding was not used in any other aspect of the study, including its design, data collection, writing of the report, or decision to submit for publication.

Availability of data and materials

All data generated or analyzed during this study are included in this published article [and the additional information files].

Declarations

Ethics approval and consent to participate

The patient was enrolled in the systemic characterization of microbiology in preterm labor protocol approved by the ethics committee of the Faculty of Medicine Ramathibodi Hospital Mahidol University (COA.MURA2021/254).

Consent for publication

The woman whose story is told in this case report has provided a written consent for the publication.

Competing interests

The authors declare that they have no competing interests.

Author details

¹Department of Obstetrics and Gynecology, Faculty of Medicine, Ramathibodi Hospital, Mahidol University, 270 Rama VI Rd. Ratchathewi, Bangkok 10400, Thailand. ²Department of Pathology, Faculty of Medicine, Ramathibodi Hospital, Mahidol University, 270 Rama VI Rd. Ratchathewi, Bangkok 10400, Thailand. ³Chakri Naruebodindra Medical Institute, Faculty of Medicine, Ramathibodi Hospital, Mahidol University, 111 Bang Pla, Bang Phli, Samut Prakan 10540, Thailand. ⁴Integrative Computational BioScience Center (ICBS), Mahidol University, Nakhon Pathom, Thailand. ⁵Institute of Infection, Veterinary and Ecological Sciences, University of Liverpool, Liverpool, UK.

Received: 9 March 2022 Accepted: 10 June 2022

Published online: 20 June 2022

References

- Romero R, Espinoza J, Kusanovic JP, Gotsch F, Hassan S, Erez O, Chaiworapongsa T, Mazor M. The preterm parturition syndrome. *BJOG*. 2006;113(Suppl 3):17–42.

2. Romero R, Dey SK, Fisher SJ. Preterm labor: one syndrome, many causes. *Science*. 2014;345(6198):760–5.
3. DiGiulio DB, Romero R, Amogan HP, Kusanovic JP, Bik EM, Gotsch F, Kim CJ, Erez O, Edwin S, Reiman DA. Microbial prevalence, diversity and abundance in amniotic fluid during preterm labor: a molecular and culture-based investigation. *PLoS ONE*. 2008;3(8): e3056.
4. DiGiulio DB, Romero R, Kusanovic JP, Gómez R, Kim CJ, Seok KS, Gotsch F, Mazaki-Tovi S, Vaisbuch E, Sanders K, et al. Prevalence and diversity of microbes in the amniotic fluid, the fetal inflammatory response, and pregnancy outcome in women with preterm pre-labor rupture of membranes. *Am J Reprod Immunol*. 2010;64(1):38–57.
5. Romero R, Miranda J, Chaiworapongsa T, Chaemsaitong P, Gotsch F, Dong Z, Ahmed AI, Yoon BH, Hassan SS, Kim CJ, et al. A novel molecular microbiologic technique for the rapid diagnosis of microbial invasion of the amniotic cavity and intra-amniotic infection in preterm labor with intact membranes. *Am J Reprod Immunol*. 2014;71(4):330–58.
6. Romero R, Miranda J, Chaiworapongsa T, Korzeniewski SJ, Chaemsaitong P, Gotsch F, Dong Z, Ahmed AI, Yoon BH, Hassan SS, et al. Prevalence and clinical significance of sterile intra-amniotic inflammation in patients with preterm labor and intact membranes. *Am J Reprod Immunol*. 2014;72(5):458–74.
7. Romero R, Miranda J, Chaemsaitong P, Chaiworapongsa T, Kusanovic JP, Dong Z, Ahmed AI, Shaman M, Lannaman K, Yoon BH, et al. Sterile and microbial-associated intra-amniotic inflammation in preterm prelabor rupture of membranes. *J Matern Fetal Neonatal Med*. 2015;28(12):1394–409.
8. Benirschke K, Clifford SH. Intrauterine bacterial infection of the newborn infant: frozen sections of the cord as an aid to early detection. *J Pediatr*. 1959;54(1):11–8.
9. Blanc WA. Pathways of fetal and early neonatal infection. Viral placentitis, bacterial and fungal chorioamnionitis. *J Pediatr*. 1961;59:473–96.
10. Riscoll SG. Pathology and the developing fetus. *Pediatr Clin North Am*. 1965;12:493–514.
11. Romero R, Sirtori M, Oyarzun E, Avila C, Mazor M, Callahan R, Sabo V, Athanassiadis AP, Hobbins JC. Infection and labor. V. Prevalence, microbiology, and clinical significance of intraamniotic infection in women with preterm labor and intact membranes. *Am J Obstet Gynecol*. 1989;161(3):817–24.
12. Romero R, Espinoza J, Gonçalves LF, Kusanovic JP, Friel LA, Nien JK. Inflammation in preterm and term labour and delivery. *Semin Fetal Neonatal Med*. 2006;11(5):317–26.
13. Romero R, Espinoza J, Gonçalves LF, Kusanovic JP, Friel L, Hassan S. The role of inflammation and infection in preterm birth. *Semin Reprod Med*. 2007;25(1):21–39.
14. Romero R, Gotsch F, Pineles B, Kusanovic JP. Inflammation in pregnancy: its roles in reproductive physiology, obstetrical complications, and fetal injury. *Nutr Rev*. 2007;65(12 Pt 2):S194–202.
15. Bearfield C, Davenport ES, Sivapathasundaram V, Allaker RP. Possible association between amniotic fluid micro-organism infection and microflora in the mouth. *BJOG*. 2002;109(5):527–33.
16. McDonald H, Gordon DL. Capnocytophaga species: a cause of amniotic fluid infection and preterm labour. *Pathology*. 1988;20(1):74–6.
17. Mazor M, Chaim W, Hershkowitz R, Wiznitzer A. Eradication of Viridans streptococci from the amniotic cavity with transplacental antibiotic treatment. *Arch Gynecol Obstet*. 1994;255(3):147–51.
18. Mazor M, Chaim W, Meirovitz M, Yohay D, Leiberman JR, Glezerman M. Eradication of viridans streptococci from the amniotic cavity by parenteral antibiotic administration. A case report. *J Reprod Med*. 1995;40(11):820–2.
19. Alanen A, Laurikainen E. Second-trimester abortion caused by Capnocytophaga sputigena: case report. *Am J Perinatol*. 1999;16(4):181–3.
20. Gherman RB, Browning J, Tramont J, Eggleston MK. Streptococcus viridans intra-amniotic infection associated with antecedent cunnilingus. *Aust N Z J Obstet Gynaecol*. 1999;39(2):257–9.
21. Kostadinov S, Pinar H. Amniotic fluid infection syndrome and neonatal mortality caused by *Eikenella corrodens*. *Pediatr Dev Pathol*. 2005;8(4):489–92.
22. Morency AM, Rallu F, Laferrrière C, Bujold E. Eradication of intra-amniotic *Streptococcus mutans* in a woman with a short cervix. *J Obstet Gynaecol Can*. 2006;28(10):898–902.
23. Gauthier S, Tétu A, Himaya E, Morand M, Chandad F, Rallu F, Bujold E. The origin of *Fusobacterium nucleatum* involved in intra-amniotic infection and preterm birth. *J Matern Fetal Neonatal Med*. 2011;24(11):1329–32.
24. Bohrer JC, Kamemoto LE, Almeida PG, Ogasawara KK. Acute chorioamnionitis at term caused by the oral pathogen *Fusobacterium nucleatum*. *Hawaii J Med Public Health*. 2012;71(10):280–1.
25. Patterson MJ. Streptococcus. In: Baron S, editor. *Medical microbiology*. Galveston (TX): University of Texas Medical Branch; 1996.
26. Mitchell J. *Streptococcus mitis*: walking the line between commensalism and pathogenesis. *Mol Oral Microbiol*. 2011;26(2):89–98.
27. Schmiedel D, Kikhney J, Masseck J, Rojas Mencias PD, Schulze J, Petrich A, Thomas A, Henrich W, Moter A. Fluorescence in situ hybridization for identification of microorganisms in acute chorioamnionitis. *Clin Microbiol Infect*. 2014;20(9):O538–541.
28. Hosseini BS, Hunt J. *Streptococcus mitis* Chorioamnionitis after dental scaling and oral sex. *Case Rep Obstet Gynecol*. 2020;2020:9251731.
29. Waites KB, Bobo RA, Davis RO, Brookings ES, Cassell GH. Clinically silent polymicrobial amnionitis and intrauterine fetal death associated with a Cu-7 intrauterine contraceptive device. *Am J Obstet Gynecol*. 1984;150(8):998–9.
30. Lee J, Romero R, Kim SM, Chaemsaitong P, Park CW, Park JS, Jun JK, Yoon BH. A new anti-microbial combination prolongs the latency period, reduces acute histologic chorioamnionitis as well as funisitis, and improves neonatal outcomes in preterm PROM. *J Matern Fetal Neonatal Med*. 2016;29(5):707–20.
31. Lee J, Romero R, Kim SM, Chaemsaitong P, Yoon BH. A new antibiotic regimen treats and prevents intra-amniotic inflammation/infection in patients with preterm PROM. *J Matern Fetal Neonatal Med*. 2016;29(17):2727–37.
32. Yoon BH, Romero R, Park JY, Oh KJ, Lee J, Conde-Agudelo A, Hong JS. Antibiotic administration can eradicate intra-amniotic infection or intra-amniotic inflammation in a subset of patients with preterm labor and intact membranes. *Am J Obstet Gynecol*. 2019;221(2):142.e141–142.e122.
33. Yeo L, Romero R, Chaiworapongsa T, Para R, Johnson J, Kmak D, Jung E, Yoon BH, Hsu CD. Resolution of acute cervical insufficiency after antibiotics in a case with amniotic fluid sludge. *J Matern Fetal Neonatal Med*. 2021. <https://doi.org/10.1080/14767058.2021.1881477>.
34. Wirtschafter DD, Padilla G, Suh O, Wan K, Trupp D, Fayard EE. Antibiotic use for presumed neonatally acquired infections far exceeds that for central line-associated blood stream infections: an exploratory critique. *J Perinatol*. 2011;31(8):514–8.
35. Polin RA, T. M.: Perinatal infections and chorioamnionitis. In: Martin RJF, A. A.; Walsh, M. C Ed. *Fanaroff and Martin's neonatal-perinatal medicine*. Volume 1, 11 edn. Elsevier; 2020: 404–414.
36. Esper F: Postnatal bacterial infections. In: Martin RJF, A. A.; Walsh, M. C Eds. *Fanaroff and Martin's neonatal-perinatal medicine*. Volume 1, 11 edn. Elsevier; 2020: 789–808.
37. Pihlstrom BL, Michalowicz BS, Johnson NW. Periodontal diseases. *Lancet*. 2005;366(9499):1809–20.
38. Kinane DF, Stathopoulou PG, Papapanou PN. Periodontal diseases. *Nat Rev Dis Primers*. 2017;3:17038.
39. Papapanou PN, Sanz M, Buduneli N, Dietrich T, Feres M, Fine DH, Flemmig TF, Garcia R, Giannobile WV, Graziani F, et al. Periodontitis: Consensus report of workgroup 2 of the 2017 World Workshop on the Classification of Periodontal and Peri-Implant Diseases and Conditions. *J Clin Periodontol*. 2018;45(Suppl 20):S162–s170.
40. Marsh PD. Dental plaque as a biofilm and a microbial community—implications for health and disease. *BMC Oral Health*. 2006;6(Suppl 1):S14.
41. Manrique-Corredor EJ, Orozco-Beltran D, Lopez-Pineda A, Quesada JA, Gil-Guillen VF, Carratala-Munuera C. Maternal periodontitis and preterm birth: systematic review and meta-analysis. *Community Dent Oral Epidemiol*. 2019;47(3):243–51.
42. Han YW, Redline RW, Li M, Yin L, Hill GB, McCormick TS. *Fusobacterium nucleatum* induces premature and term stillbirths in pregnant mice: implication of oral bacteria in preterm birth. *Infect Immun*. 2004;72(4):2272–9.
43. Aagaard K, Ma J, Antony KM, Ganu R, Petrosino J, Versalovic J. The placenta harbors a unique microbiome. *Sci Transl Med*. 2014;6(237):237ra265.

44. Doyle RM, Alber DG, Jones HE, Harris K, Fitzgerald F, Peebles D, Klein N. Term and preterm labour are associated with distinct microbial community structures in placental membranes which are independent of mode of delivery. *Placenta*. 2014;35(12):1099–101.
45. Antony KM, Ma J, Mitchell KB, Racusin DA, Versalovic J, Aagaard K. The preterm placental microbiome varies in association with excess maternal gestational weight gain. *Am J Obstet Gynecol*. 2015;212(5):653.e651–616.
46. Prince AL, Ma J, Kannan PS, Alvarez M, Gisslen T, Harris RA, Sweeney EL, Knox CL, Lambers DS, Jobe AH, et al. The placental membrane microbiome is altered among subjects with spontaneous preterm birth with and without chorioamnionitis. *Am J Obstet Gynecol*. 2016;214(5):627.e621–627.e616.
47. Leon LJ, Doyle R, Diez-Benavente E, Clark TG, Klein N, Stanier P, Moore GE. Enrichment of clinically relevant organisms in spontaneous preterm-delivered placentas and reagent contamination across all clinical groups in a large pregnancy cohort in the United Kingdom. *Appl Environ Microbiol*. 2018;84(14):e00483.
48. Chu DM, Seferovic M, Pace RM, Aagaard KM. The microbiome in preterm birth. *Best Pract Res Clin Obstet Gynaecol*. 2018;52:103–13.
49. Prince AL, Chu DM, Seferovic MD, Antony KM, Ma J, Aagaard KM. The perinatal microbiome and pregnancy: moving beyond the vaginal microbiome. *Cold Spring Harb Perspect Med*. 2015;5(6):a023051.
50. Farooqi HMU, Kim KH, Kausar F, Muhammad J, Bukhari H, Choi KH. Frequency and molecular characterization of *Staphylococcus aureus* from placenta of mothers with term and preterm deliveries. *Life*. 2022;12(2):257.
51. Seferovic MD, Pace RM, Carroll M, Belfort B, Major AM, Chu DM, Racusin DA, Castro ECC, Muldrew KL, Versalovic J, et al. Visualization of microbes by 16S in situ hybridization in term and preterm placentas without intraamniotic infection. *Am J Obstet Gynecol*. 2019;221(2):146.e141–146.e123.
52. Fischer LA, Demerath E, Bittner-Eddy P, Costalonga M. Placental colonization with periodontal pathogens: the potential missing link. *Am J Obstet Gynecol*. 2019;221(5):383–392.e383.
53. Brummaier T, Syed Ahamed Kabeer B, Lindow S, Konje JC, Pukrittayaamee S, Utzinger J, Toufiq M, Antoniou A, Marr AK, Suriyakan S, et al. A prospective cohort for the investigation of alteration in temporal transcriptional and microbiome trajectories preceding preterm birth: a study protocol. *BMJ Open*. 2019;9(1):e023417.
54. Leiby JS, McCormick K, Sherrill-Mix S, Clarke EL, Kessler LR, Taylor LJ, Hofstaedter CE, Roche AM, Mattei LM, Bittinger K, et al. Lack of detection of a human placenta microbiome in samples from preterm and term deliveries. *Microbiome*. 2018;6(1):196.
55. Doyle RM, Harris K, Kamiza S, Harjunmaa U, Ashorn U, Nkhoma M, Dewey KG, Maleta K, Ashorn P, Klein N. Bacterial communities found in placental tissues are associated with severe chorioamnionitis and adverse birth outcomes. *PLoS ONE*. 2017;12(7): e0180167.
56. Kilian M, Mikkelsen L, Henrichsen J. Taxonomic Study of Viridans Streptococci: description of *Streptococcus gordonii* sp. Nov. and emended descriptions of *Streptococcus sanguis* (White and Niven 1946), *Streptococcus oralis* (Bridge and Sneath 1982), and *Streptococcus mitis* (Andrews and Horder 1906). *Int J Syst Evolut Microbiol*. 1989;39:471–84.
57. Pearce C, Bowden GH, Evans M, Fitzsimmons SP, Johnson J, Sheridan MJ, Wientzen R, Cole MF. Identification of pioneer viridans streptococci in the oral cavity of human neonates. *J Med Microbiol*. 1995;42(1):67–72.
58. Rabe LK, Winterscheid KK, Hillier SL. Association of viridans group streptococci from pregnant women with bacterial vaginosis and upper genital tract infection. *J Clin Microbiol*. 1988;26(6):1156–60.
59. Kolenbrander PE, London J. Adhere today, here tomorrow: oral bacterial adherence. *J Bacteriol*. 1993;175(11):3247–52.
60. Bochud PY, Calandra T, Francioli P. Bacteremia due to viridans streptococci in neutropenic patients: a review. *Am J Med*. 1994;97(3):256–64.
61. Zheng W, Tan TK, Paterson IC, Mutha NV, Siow CC, Tan SY, Old LA, Jakubovics NS, Choo SW. StreptoBase: an oral *Streptococcus mitis* group genomic resource and analysis platform. *PLoS ONE*. 2016;11(5): e0151908.
62. Cobe HM. Transitory bacteremia. *Oral Surg Oral Med Oral Pathol*. 1954;7(6):609–15.
63. Silver JG, Martin AW, McBride BC. Experimental transient bacteraemias in human subjects with varying degrees of plaque accumulation and gingival inflammation. *J Clin Periodontol*. 1977;4(2):92–9.
64. Hartzell JD, Torres D, Kim P, Wortmann G. Incidence of bacteremia after routine tooth brushing. *Am J Med Sci*. 2005;329(4):178–80.
65. Forner L, Larsen T, Kilian M, Holmstrup P. Incidence of bacteremia after chewing, tooth brushing and scaling in individuals with periodontal inflammation. *J Clin Periodontol*. 2006;33(6):401–7.
66. Kamate WI, Vibhute NA, Baad RK. Estimation of DMFT, salivary *Streptococcus mutans* count, flow rate, Ph, and salivary total calcium content in pregnant and non-pregnant women: a prospective study. *J Clin Diagn Res*. 2017;11(4):ZC147–51.
67. Romero R, Miranda J, Chaiworapongsa T, Chaemsaitong P, Gotsch F, Dong Z, Ahmed AI, Yoon BH, Hassan SS, Kim CJ, et al. Sterile intra-amniotic inflammation in asymptomatic patients with a sonographic short cervix: prevalence and clinical significance. *J Matern Fetal Neonatal Med*. 2015;28(11):1343–59.
68. Mores CR, Price TK, Wolff B, Halverson T, Limeira R, Brubaker L, Mueller ER, Putonti C, Wolfe AJ. Genomic relatedness and clinical significance of *Streptococcus mitis* strains isolated from the urogenital tract of sexual partners. *Microb Genom*. 2021;7(3):mgen000535.
69. Kumar J, Samelson R. Oral health care during pregnancy recommendations for oral health professionals. *N Y State Dent J*. 2009;75(6):29–33.
70. Boggess KA, Urlaub DM, Massey KE, Moos MK, Matheson MB, Lorenz C. Oral hygiene practices and dental service utilization among pregnant women. *J Am Dent Assoc*. 2010;141(5):553–61.
71. Ahtari MD, Georgakopoulou EA, Afentoulide N. Dental care throughout pregnancy: what a dentist must know. *Oral Health Dent Manag*. 2012;11(4):169–76.
72. American College of Obstetricians and Gynecologists. Committee Opinion No. 569: oral health care during pregnancy and through the lifespan. *Obstet Gynecol*. 2013;122(2 Pt 1):417–22.

Publisher's Note

Springer Nature remains neutral with regard to jurisdictional claims in published maps and institutional affiliations.

Ready to submit your research? Choose BMC and benefit from:

- fast, convenient online submission
- thorough peer review by experienced researchers in your field
- rapid publication on acceptance
- support for research data, including large and complex data types
- gold Open Access which fosters wider collaboration and increased citations
- maximum visibility for your research: over 100M website views per year

At BMC, research is always in progress.

Learn more biomedcentral.com/submissions

