

Research article

Open Access

Acoustic stiffness and change in plug cartilage over time after autologous osteochondral grafting: correlation between ultrasound signal intensity and histological score in a rabbit model

Hiroshi Kuroki¹, Yasuaki Nakagawa², Koji Mori³, Mao Ohba², Takashi Suzuki², Yasuyuki Mizuno², Keiji Ando², Makoto Takenaka⁴, Ken Ikeuchi⁴ and Takashi Nakamura²

¹Department of Physical Therapy, School of Health Sciences, Faculty of Medicine, Kyoto University, Kyoto, Japan

²Department of Orthopaedic Surgery, Graduate School of Medicine, Kyoto University, Kyoto, Japan

³Applied Medical Engineering Science, Graduate School of Medicine, Yamaguchi University, Yamaguchi, Japan

⁴Institute for Frontier Medical Sciences, Kyoto University, Kyoto, Japan

Corresponding author: Yasuaki Nakagawa, ynaka@kuhp.kyoto-u.ac.jp

Received: 16 Mar 2004 Revisions requested: 21 Apr 2004 Revisions received: 11 Jun 2004 Accepted: 30 Jun 2004 Published: 14 Sep 2004

Arthritis Res Ther 2004, **6**:R492-R504 (DOI 10.1186/ar1219)

© 2004 Kuroki *et al.*; licensee BioMed Central Ltd. This is an Open Access article: verbatim copying and redistribution of this article are permitted in all media for any purpose, provided this notice is preserved along with the article's original URL.

Abstract

We investigated quantitative changes over time in ultrasound signal intensity (an index of stiffness), signal duration (an index of surface irregularity), and interval between signals (an index of thickness) of plug cartilage in an animal model of autologous osteochondral grafting. A full-thickness osteochondral plug was surgically removed and replaced in male Japanese white rabbits ($n = 22$). Specimens obtained at day 0 and weeks 2, 4, 8, 12 and 24 postoperatively were assessed using an ultrasound system and by macroscopic and histological evaluation (modified Mankin's score). Histology revealed that the plug sank until 2 weeks postoperatively, and that newly formed cartilage-like tissue covered the plug, but at 24 weeks the tissue detached. The plug itself survived well throughout the period of observation. Although the signal intensity at the plug site was same as that in the sham operated contralateral knee at day 0, from 2 to 24 weeks postoperatively it was less than that in the sham knee. At 8 weeks, this difference was significant ($P <$

0.05). Modified Mankin's score revealed early degenerative changes at the site, but macroscopic examination did not. Signal intensity correlated significantly with score (both at day 0 and at the five postoperative time points [$P < 0.05$, $r = -0.91$] and as a whole [$P < 0.05$, $r = -0.36$]). Signal intensity also significantly correlated with the individual subscores for 'cartilage structure' ($P < 0.05$, $r = -0.32$) and 'cartilage cells' ($P < 0.05$, $r = -0.30$) from the modified Mankin's score, but not significantly with subscores for 'staining' and 'tidemark'. Signal duration correlated significantly with total score (as a whole [$P < 0.05$, $r = 0.34$]), but not significantly with the score for cartilage structure ($P = 0.0557$, $r = 0.29$). The interval between signals reflected well the actual thickness of the plug site. The significant relationships between ultrasound signal intensity and scores suggest that early degenerative changes in plug cartilage and cartilage-like tissue, especially in the superficial layer, are detectable by high-frequency ultrasound assessment.

Keywords: articular cartilage, high-frequency ultrasound, histology, osteochondral grafting surgery

Introduction

High-frequency pulse echo ultrasound techniques, which reveal a number of features of normal and degenerated articular cartilage [1-16], were recently introduced. The ultrasound signal correlates strongly with thickness of cartilage [5,8,17,18]. The signal also provides information about the integrity of the superficial zone of cartilage [1-4,8] and about progression of osteoarthritis [6,7,9-15].

It is known that, if untreated, full thickness articular cartilage damage will progress to osteoarthritis [19,20] because articular cartilage has limited intrinsic healing ability [21]. Numerous attempts to induce healing of cartilage defects have been made, but each treatment has strengths and weaknesses [15]; therefore, regeneration and repair of articular cartilage remains a clinical and scientific challenge.

Autologous osteochondral grafts (OCGs) are used to treat small, isolated articular cartilage defects. Successful clinical treatment with OCGs has been reported, with few complications at the donor site [22-27]. Using both arthroscopic [22,23,28-31] and open surgical techniques [24,25,32,33], this type of graft has been implanted in knee joint and talus, and in end-stage osteochondritis dissecans lesions of the humeral capitellum. A requirement of the treatment is that the cylindrical plug of the autograft includes both articular cartilage and underlying subchondral bone [22-25,27-30]. OCGs have several benefits, including reliable bone union, high survival rate for grafted cartilage, and little risk for disease transmission. In human clinical and animal studies it has been shown that osteochondral plugs maintain hyaline cartilage coverage over the subchondral bone, and that the plugs retain their viability and attach to the surrounding bone [22,24,27,34].

Using a high-frequency pulse echo ultrasound technique, we found that the implantation procedure does not adversely affect the stiffness, surface regularity and thickness of OCG plug cartilage immediately after surgery (at day 0) [13]. However, no research has yet focused on ultrasonographical and histological assessment of postoperative changes in plug cartilage. We therefore investigated changes over time in the plug cartilage after OCG in a rabbit model.

Methods

Animals

This investigation was approved by the Animal Research Committee of the Kyoto University Graduate School of Medicine (approval number Med Kyo 03155). Twenty-four male Japanese white rabbits (Japan Animals Co. Ltd, Osaka, Japan) were used. The rabbits were randomly assigned to one of six groups defined by the time point at which the animals were evaluated (day 0 [immediately after surgery], and 2, 4, 8, 12 and 24 weeks after surgery; $n = 4$ in each group). The animals were maintained at the Institute of Laboratory Animals, Graduate School of Medicine, Kyoto University for 3 weeks before the start of the experiments. They were housed, each in a separate cage, in a room maintained at 22°C and 50% humidity, with a 14-hour light/10-hour dark cycle, and were given food and water *ad libitum*.

Osteochondral grafting

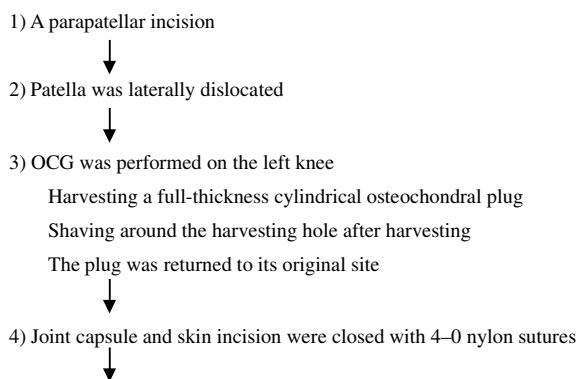
Intravenous pentobarbital sodium (25 mg/kg body weight) was used to induce and maintain general anaesthesia. The rabbits were placed supine, and the surgery was performed on both knees. The lower limbs were disinfected, and 2 ml of 0.5% lidocaine was injected subcutaneously into the parapatellar region. A parapatellar incision was made to expose the knee joint, and the patella was laterally dislocated.

OCG was performed on the left knee (Fig. 1). A full thickness cylindrical osteochondral plug (5 mm in diameter, 7 mm in depth), which went through the articular surface and into the subchondral bone, was harvested using the Osteochondral Autograft Transfer System (Arthrex, Naples, Florida). The Osteochondral Autograft Transfer System 'Recipient' Tube Harvester, 5 mm in diameter, was positioned on the patellar groove and was then driven into the subchondral bone to a depth of 7 mm. During creation of the hole, the harvester was maintained at a 90° angle to the articular surface in both sagittal and coronal planes. After insertion to 7 mm depth, the harvester was rotated 90° clockwise and then 90° anticlockwise. The harvester was then pulled out of the joint. The articular cartilage around the hole was shaved in a 7 × 7 mm square with a chisel until bleeding was observed from the subchondral bone. This procedure of inducing bleeding is believed to accelerate healing of surrounding cartilage, and some evidence has been reported that the area is filled by newly formed reparative tissue [23,26].

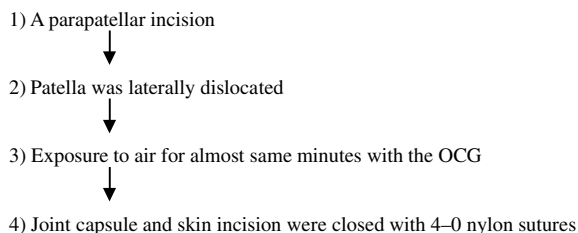
The harvested plug was then returned precisely to its original site. Thus, the recipient hole was repaired with an autologous osteochondral plug that was of exactly the same size as the hole. The chiselled area around the hole was left. The joint capsule and skin incision were closed with 4-0 nylon sutures.

Figure 1

Left knee (OCG surgery):



Right knee (sham operation):



A diagram of surgical procedures. OCG, autologous osteochondral grafts.

Sham surgery was performed on the right knee as follows: a parapatellar incision was made; the patella was laterally dislocated; and then the joint capsule and skin incision were closed, all over the same period of time as was required for the OGC procedure (Fig. 1).

All rabbits were allowed to move freely in their cages after the surgery. Two rabbits were excluded from the series; one exhibited signs of infection 7 days after surgery and in the other the plug was fractured during surgery. At day 0 (immediately after surgery; $n = 3$), or 2 ($n = 3$), 4 ($n = 4$), 8 ($n = 4$), 12 ($n = 4$) or 24 ($n = 4$) weeks after surgery, the rabbits (with a weight [mean \pm standard deviation] 3.2 ± 0.19 kg, range 2.8–3.6 kg) were killed by intravenous injection of a fatal dose of sodium pentobarbital. The implanted osteochondral plugs, the articular cartilage of the defect, and the intact region of the patellar groove were evaluated macroscopically. The plug cartilage was assessed using an ultrasound system and then evaluated histologically.

Ultrasound assessment

The ultrasound assessment system we used provides quantitative information about tissue properties, and was described previously (Fig. 2a) [10,13,14]. Briefly, the system developed by Mori and coworkers [10] consists of a transducer and a pulser/receiver (Panametrics Japan, Tokyo, Japan), a digital oscilloscope and a personal computer (Fig. 2a). The diameter of the transducer was approximately 3 mm. The central frequency of the ultrasound wave was 10 MHz. As the wave passes through interfaces between media of different acoustic impedances, reflections return to the transducer and generate electrical signals in the transducer that are proportional to the intensity [35].

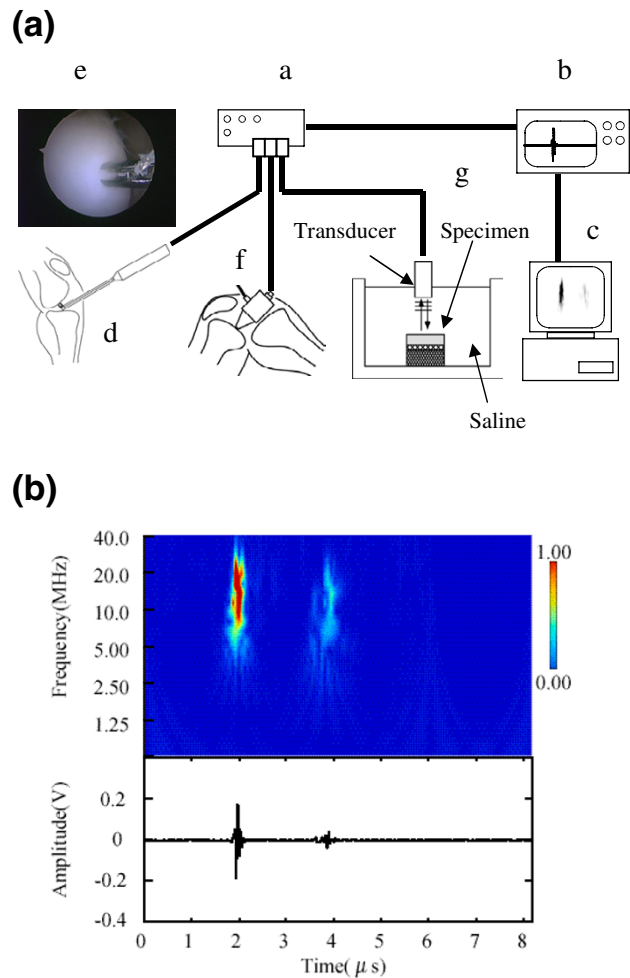
On examining cartilage, two large amplitude groups of reflected waves were observed (Fig. 2b). By using appropriate wavelet transformation for these amplitude groups [10,13,14], three properties of cartilage can be analyzed. The first amplitude group (group N) represents the signal from the surface of the cartilage, and the second (group K) represents that from the subchondral bone (Fig. 2b). The time interval (μs) between the two signals represents the thickness of the cartilage. The duration (μs) of group N represents the irregularity of the cartilage, because diffused reflection waves in a rough surface return to the ultrasound transducer with a time delay. The intensity of group N is proportional to the Young modulus of cartilage. The Young modulus is determined using the following equations [13]:

$$V = \sqrt{(E/\rho)}$$

$$Z = \rho V$$

$$R = (Z_2 - Z_1)/(Z_2 + Z_1)$$

Figure 2



(a) The ultrasonic measurement system consists of a transducer, (a) a pulser/receiver, (b) a digital oscilloscope and (c) a personal computer. The system can be used with (d, e) arthroscopy, (f) open surgery and (g) saline bath for experimental purposes. The ultrasound wave output from the transducer travels through saline. The reflected waves return to the transducer and generate electrical signals in the transducer that are proportional to the reflected wave intensity. **(b)** Typical ultrasound echo (lower) and wavelet map (upper). The wavelet map was calculated from the ultrasound echo using wavelet transform. The first (left) of the two large amplitude groups was the echo ($t = 2.0 \mu\text{s}$: group N) reflected from the cartilage surface, and the second (right; $t = 3.9 \mu\text{s}$: group K) was reflected from the subchondral bone. The signal intensity (maximum magnitude, as shown by the scale) of group N represents cartilage stiffness. The time interval between groups N and K represents cartilage thickness. The signal duration of group N represents the surface irregularity of the cartilage.

Here, E is the Young modulus, V is the speed of sound, and ρ is the density of a material. Z and R are the acoustic impedance of a material and reflectance, respectively. In the present study, Z_2 is the acoustic impedance of articular cartilage and Z_1 is that of saline. Z_1 is a constant ($1.48 \times$

$10^6 \text{ kg/m}^2\text{S}$ at room temperature). From the three equations above, the Young modulus of cartilage, E , is given by the following:

$$E = \left(\frac{R + 1}{R - 1} \right)^2 \times \frac{Z_1^2}{\rho}$$

The reflectance of cartilage in saline, R , is nearly 0.10. In the case, E is proportional to R , if the density of cartilage, P , is constant. The intensity of group N is directly proportional to R . Consequently, the intensity of group N may be used as an index of cartilage stiffness.

An indentation test demonstrated a significant relationship between the intensity of group N and the aggregate modulus [10], which is one of the indices of mechanical properties of articular cartilage [36,37]. As described above, in theory it is reasonable to regard the intensity of the wave as an index of stiffness of cartilage. The intensity was represented as relative values because the change in this index was calculated from the three equations given above. Therefore, we used signal intensity as an index of stiffness, signal duration as an index of surface irregularity, and interval between signals as an index of thickness.

The plug cartilage and the corresponding site on the sham side were evaluated at three different sites: the center of the plug, 0.25 mm distal to the center, and 0.25 mm proximal to the center.

Histological evaluation

For histological examination, the specimens were fixed in 10% neutral buffered formalin for 7 days, decalcified with 0.25 mol/l EDTA in phosphate-buffered saline (pH 7.4), dehydrated in graded ethanol, and embedded in paraffin wax. Sagittal sections (6 μm thick) were then cut, stained with safranin-O/fast green and haematoxylin and eosin, and examined microscopically. All sections were observed and evaluated by three authors. Histological evaluation of plug cartilage was performed using the modified Mankin's score [38] (original score proposed by Mankin and coworkers [39]). The grading system was composed of four categories – cartilage structure (6 points), cartilage cells (3 points), staining (4 points) and tidemark integrity (2 points) – with a highest score of 14 points; normal cartilage scored 0 (Table 1) [38]. When we observed newly formed tissue that covered the plug cartilage, the finding was counted as 'pannus and surface irregularities' (2 points).

Statistical analysis

Data for histological scores were analyzed statistically using the nonparametric Kruskal-Wallis test and the post-hoc Scheffe's F-test (for comparison between weeks postoperatively), and using the Mann-Whitney U-test (for

comparison between grafted and sham sides). Ultrasound data were analyzed using parametric repeated measures analysis of variance and the post-hoc Scheffe's F-test. The relationships between ultrasound data (mean of the three measurements) and the score were analyzed using nonparametric Spearman's rank-order correlation.

Results

Macroscopic findings

Day 0 and postoperative week 2

At day 0 (Fig. 3a) the plug was intact and the margins around the plug and the shaved square were clearly apparent. At 2 weeks postoperatively (Fig. 3b) the margin around the square could be clearly detected. Although the articular surface of the plug was smooth and regular, the plug had subsided a little.

Postoperative weeks 4 and 8

At 4 weeks (Fig. 3c) and 8 weeks postoperatively (Fig. 3d), the site around and over the plug was filled with newly formed reparative tissue. The margin around the plug and the shaved square could be easily detected at 4 weeks. At 8 weeks postoperatively the margin was a little faint but still detectable. Although the surfaces of the plug and the defect looked irregular at 4 and 8 weeks, the plug was glossy.

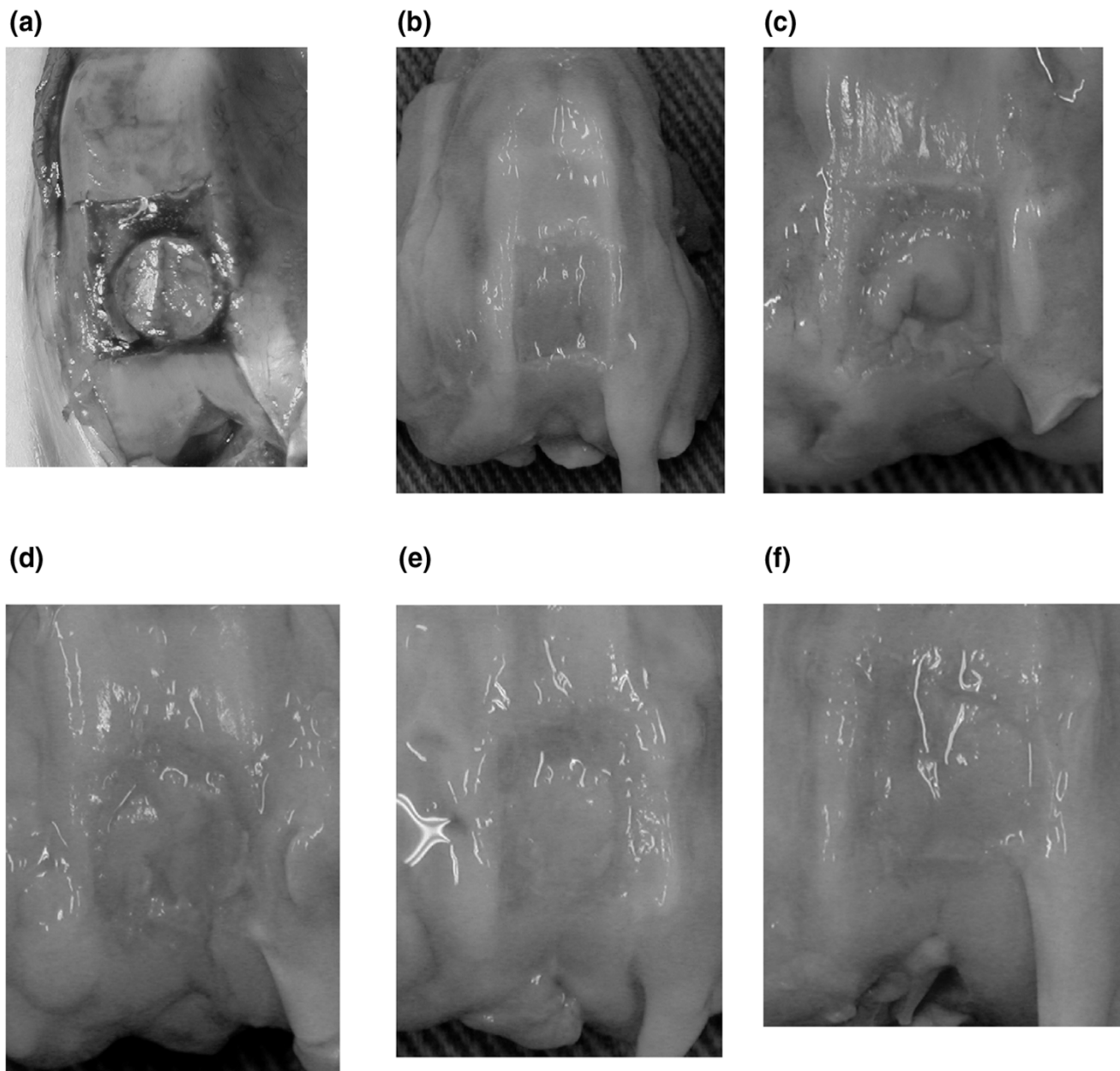
Postoperative weeks 12 and 24

The plug survived well and no osteoarthritic changes such as osteophyte formation were observed at 12 weeks (Fig. 3e) and 24 weeks postoperatively (Fig. 3f). At 12 weeks the margin around the plug and the shaved square was a little faint but it was still detectable. At 24 weeks postoperatively, however, the margin was very faint. At 12 and 24 weeks, the surface of the plug cartilage was as smooth as that of the adjacent intact cartilage. Although the plug and intact cartilage were glossy in all of the specimens obtained from 0 to 24 weeks, the appearance of the shaved area was not so. In the shaved area, no reparative tissue was observed throughout the 24 weeks. All sham-operated cartilage was grossly normal, and there was no evidence of articular damage.

Histological findings

At day 0 and postoperative week 2

Histological examination at day 0 revealed that the plug had been inserted flush with the surrounding articular surface. The site of the defect (the shaved area) was clearly recognizable because the cartilage around the plug had been shaved until it bled (Fig. 4a,4b). At 2 weeks postoperatively the plug had subsided a little and the newly formed tissue covered half of the plug. No tissue was observed at the site of the defect (Fig. 4c,4d). The actual thickness of cartilage increased a little with the overlying tissue.

Figure 3

Macroscopic findings. A full-thickness osteochondral plug of 5 mm in diameter and 7 mm in depth was harvested from the patellar groove. Articular cartilage around the hole was shaved in a 7×7 mm square until bleeding from the subchondral bone was observed. The harvested plug was then returned precisely to its original site. **(a)** At day 0, the plug was intact and the margin around the plug and the shaved square was clearly recognizable. **(b)** At 2 weeks postoperatively, the margin around the square could be clearly detected. Although the articular surface of the plug was smooth and regular, the plug had subsided a little. **(c)** The margin around the plug and the shaved square could be easily detected at 4 weeks. **(d)** At 8 weeks postoperatively the margin was a little faint but could still be detected. At 4 (panel c) and 8 weeks (panel d), the site around and over the plug was filled with newly formed reparative tissue. Although the surface of the plug and the defect looked irregular, the plug was glossy. **(e)** The margin around the plug and the shaved square was a little faint but could still be detected at 12 weeks. **(f)** At 24 weeks postoperatively, however, the margin was very faint. The plug survived well and osteoarthritic changes such as osteophyte formation were not observed at 12 and 24 weeks postoperatively (panels e and f). The surface of the plug cartilage was as smooth as that of the adjacent intact cartilage.

Table 1**Modified Mankin's histological scores**

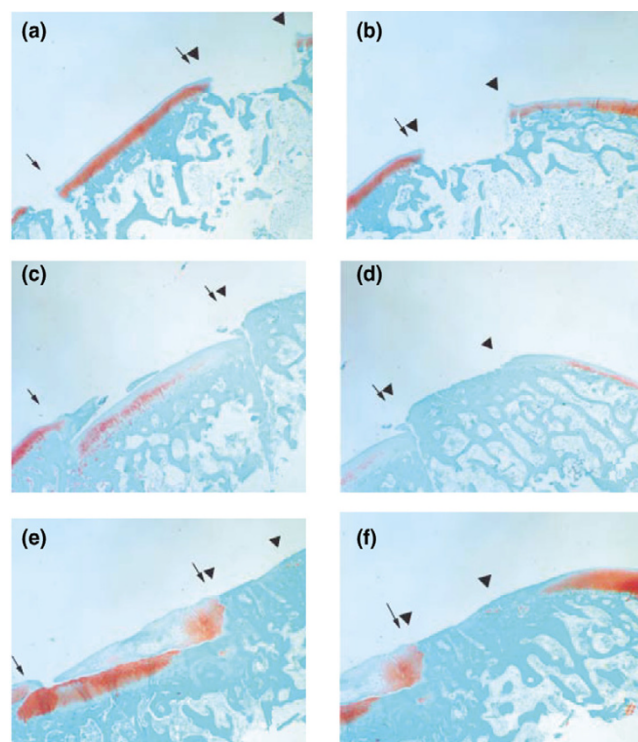
Subscore	Details
Cartilage structure	
Normal	0
Surface irregularities	1
Pannus and surface irregularities	2
Clefts to transitional zone	3
Clefts to radial zone	4
Clefts to calcified zone	5
Complete disorganization	6
Cartilage cells	
Normal	0
Pyknosis, lipid degeneration hypercellularity	1
Clusters	2
Hypocellularity	3
Safranin-O, thionine, Alcian blue	
Normal	0
Slight reduction	1
Moderate reduction	2
Severe reduction	3
No staining	4
Tidemark integrity	
Intact	0
Destroyed	1

Postoperative weeks 4 and 8

By 4 weeks postoperatively the implanted osteochondral plug had united with the area of the subchondral bone (Fig. 4e,4f). Newly formed reparative tissue, which stained faintly with safranin-O, covered the plug cartilage, and the plug cartilage was well stained (Fig. 4e). At 8 weeks (Fig. 5a) the plug cartilage was extremely well stained and was covered with the newly formed tissue, which was partly stained. The surface of the tissue was irregular. At 4 and 8 weeks postoperatively, the actual thickness of cartilage increased with the tissue. No reparative tissue was observed at the site of the defect at 4 or 8 weeks postoperatively.

Postoperative weeks 12 and 24

Although the newly formed reparative tissue over the plug cartilage was not distinctive on macroscopic observation at 12 weeks postoperatively (Fig. 3e), histological observation revealed that reparative tissue covered the

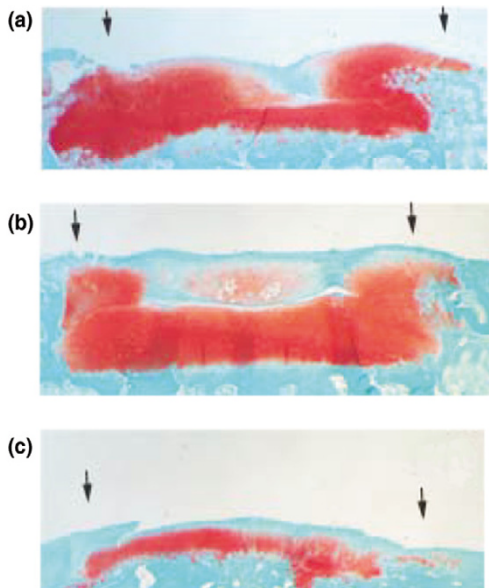
Figure 4

Safranin-O/fast green staining of plug cartilage and the shaved area (original magnification 10×). (a, b) No abnormalities were observed at day 0. The plug (between the arrows) was inserted flush with the surrounding articular surface and the site of the shaved area (between the triangles) was clearly recognizable. There was a space between the plug and the surrounding tissue. (c, d) At 2 weeks postoperatively, the plug (between the arrows) had subsided a little and newly formed tissue covered half of the plug. No tissue was observed at the site of the shaved area (between the triangles). There was a slight space between the plug and the surrounding tissue. (e, f) The implanted osteochondral plug (between the arrows) had united in the subchondral bone area by 4 weeks postoperatively. The newly formed reparative tissue, which stained faintly with safranin-O, covered the plug cartilage and the plug cartilage was well stained. No tissue was observed at the site of the shaved area (between the triangles). Bony union was observed between the plug and the host.

plug cartilage (Fig. 5b). Actual thickness of cartilage increased with the tissue. The tissue was faintly stained and the plug was well stained (Fig. 5b). At 24 weeks postoperatively, no reparative tissue was observed over the plug (Fig. 5c). Therefore, the actual thickness of cartilage decreased at 24 weeks. The plug cartilage was stained with the safranin-O but slightly less intensely than the intact cartilage. No reparative tissue was observed at the site of the defect at 12 or 24 weeks postoperatively.

Modified Mankin's score

The mean scores for the plug cartilage at day 0 and weeks 2, 4, 8, 12 and 24 postoperatively were 0.33, 1.67, 2.00, 2.75, 3.50 and 2.50, respectively. Those of the corresponding sham-operated site were 0.00, 0.67, 0.00, 1.00,

Figure 5

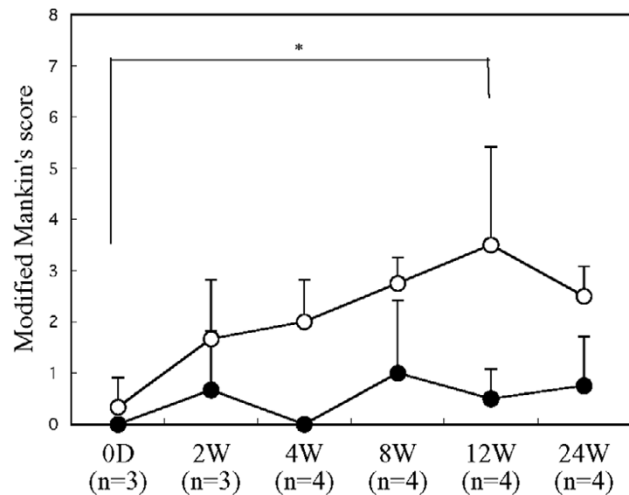
Safranin-O/fast green staining of plug cartilage (original magnification 10 \times). **(a)** At 8 weeks the plug cartilage (between the arrows) was extremely well stained and was covered with newly formed tissue, which was stained partly and the surface of the tissue was irregular. **(b)** At 12 weeks reparative tissue covered the plug cartilage (between the arrows) and the tissue was faintly stained and the plug was well stained. **(c)** At 24 weeks postoperatively no reparative tissue covered the plug (between the arrows) and the plug cartilage was stained with safranin-O, but slightly less strongly than the plug cartilage at 8 or 12 weeks.

0.50 and 0.75, respectively. No differences between scores existed on the sham side, but on the grafted side the scores differed significantly between day 0 and week 12 (Fig. 6; $P < 0.05$). Mann-Whitney U-test revealed that scores between the right and left knees at 4, 12 and 24 weeks postoperatively were significantly different ($P < 0.05$).

Ultrasound data on cartilage

Signal intensity at day 0 was the same in the grafted and sham sides at 1.5 (relative value). At 2 weeks postoperatively the signal intensity on both sides had decreased. The decrease was not significant on the sham side, but it was significant on the grafted side ($P < 0.001$; Fig. 7a and Table 2). At 8 weeks, although signal intensity on both sides had decreased, the difference was not significant on the sham side but it was significant on the grafted side ($P < 0.001$; Fig. 7a and Table 2). Between 2 and 24 weeks postoperatively, the intensity on the grafted side was lower than that on the sham side ($P < 0.05$ at 8 weeks; Fig. 7a). At 24 weeks the values were 0.6 on the grafted side and 1.0 on the sham side.

Signal duration on day 0 was 0.6 μ s on the grafted side and 0.5 μ s on the sham side. At 2 and 8 weeks postoperatively,

Figure 6

The mean modified Mankin's scores of the plug cartilage (open circles) at day 0 (0D) and at weeks 2 (2W), 4 (4W), 8 (8W), 12 (12W) and 24 (24W) postoperatively were 0.33, 1.67, 2.00, 2.75, 3.50 and 2.50, respectively. Those of the corresponding sham site (closed circles) were 0.00, 0.67, 0.00, 1.00, 0.50 and 0.50 points, respectively. The Kruskal-Wallis test and Scheffe's F-test revealed that, on the grafted side, the score differed significantly between day 0 and week 12 ($* P < 0.05$). Mann-Whitney U-test revealed that the score differed significantly ($P < 0.05$) between the sham and experimental sites at 4, 12 and 24 weeks postoperatively (not indicated in the graph).

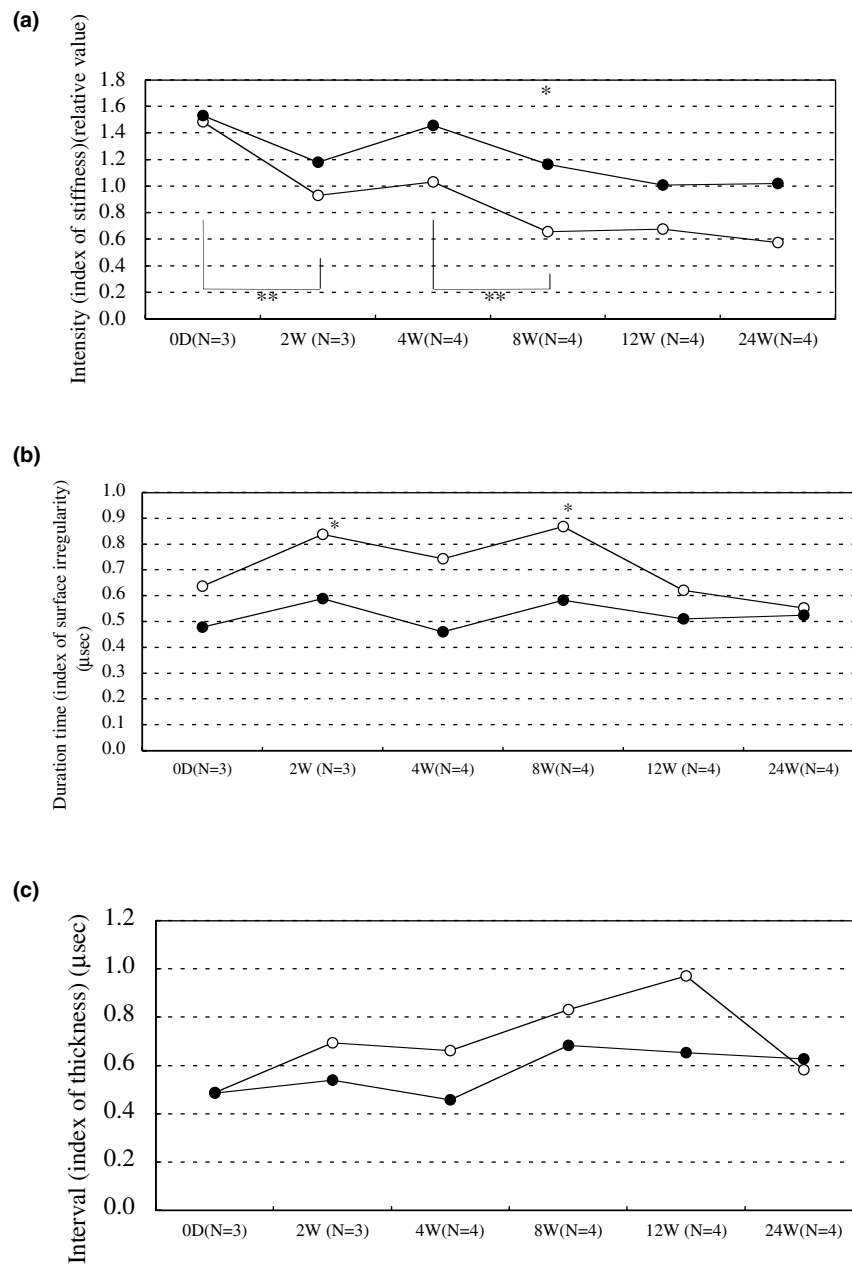
the differences in signal duration between the sides were 0.2 and 0.3 μ s, respectively ($P < 0.05$, Fig. 7b). At 12 weeks the difference in signal duration between the sides was 0.1 μ s. At 24 weeks postoperatively, the signal duration on both sides was approximately the same (0.5 μ s; Fig. 7b).

At day 0 the interval between signals on both sides was the same (0.5 μ s). Between 2 and 8 weeks postoperatively, the difference between them was 0.1 or 0.2 μ s. At 12 weeks the difference increased (0.3 μ s), but at 24 weeks postoperatively no difference was observed between the two sides (for both the interval was 0.6 μ s; Fig. 7c).

Relationship between ultrasound data and modified Mankin's score

Spearman's rank-order correlation revealed that the modified Mankin's score was significantly correlated with signal intensity ($P = 0.0176$, $r = -0.36$; Fig. 8a) and with signal duration ($P = 0.0269$, $r = 0.34$; Fig. 8b). The signal intensity was also significantly correlated with the score for category 'cartilage structure' in the modified Mankin's score ($P = 0.0343$, $r = -0.32$; Fig. 8c) and that for 'cartilage cells' ($P = 0.0499$, $r = -0.30$; Fig. 8d), but the correlation was not significant for 'staining' or 'tidemark'. The correlations between signal duration and the scores for structure ($P = 0.0557$, $r = 0.29$) and cartilage cells ($P = 0.4630$, $r =$

Figure 7



(a) Change over time in ultrasound signal intensity (an index of stiffness) of the plug site (open circles) and the sham side (closed circles). Intensity is represented as relative values. Repeated measures analysis of variance and post-hoc test (Scheffe's F-test) revealed that the signal intensity of the two sides differed significantly at 8 weeks (* $P < 0.05$) and that the signal intensity of the grafted side differed significantly among the groups (P values are presented in Table 2). Especially between day 0 (D0) and week 2 (2 W) and between weeks 4 (4 W) and 8 (8 W), the values differed significantly (** $P < 0.001$), but there was no difference between 2 W and 4 W or among the groups 8 W, 12 W and week 24 (24 W). **(b)** Change over time in signal duration (an index of surface irregularity) of the plug site and the sham side. Values are presented as μs . Signal duration of the two sides differed significantly at 2 W and 8 W (* $P < 0.05$). **(c)** Changes over time in interval between signals (an index of thickness) of the plug site and the sham side. Values are represented as μs . Values on both sides were the same (0.5 μs) at D0. After 2–8 weeks postoperatively, the values almost paralleled each other and the difference between them was 0.1 or 0.2 μs . At 12 weeks the difference increased to 0.3 μs , but by 24 weeks postoperatively no difference was observed, at which time the value for both sides was 0.6 μs .

Table 2**Level of significance (P values) in signal intensity of plug cartilage**

	24 weeks	12 weeks	8 weeks	4 weeks	2 weeks
Day 0	$P < 0.001$	$P < 0.001$	$P < 0.001$	$P < 0.001$	$P < 0.001$
2 weeks	$P < 0.001$	$P < 0.05$	$P < 0.05$	NS	-
4 weeks	$P < 0.001$	$P < 0.001$	$P < 0.001$	-	-
8 weeks	NS	NS	-	-	-
12 weeks	NS	-	-	-	-

The P value was not significant (NS) between weeks 2 and 4, or among weeks 8, 12 and 24. Values for signal intensity are presented in Fig. 7a.

0.11) were not significant. When mean values for signal intensity of the plug site were calculated among each of the six postoperative groups, the mean signal intensity was significantly and strongly correlated with the score ($P = 0.0130$, $r = -0.91$; Fig. 8e).

Discussion

Although the concept of ultrasound assessment is over a decade old [1,2,35,40], new techniques continue to be developed and reported. These techniques include measurement of surface fibrillation [3] and tissue thickness [6,8,9], comparison of the speed of sound [7], ultrasound backscatter [11,41], needle probe [5], use of high frequency (50 MHz) [4,41], real-time analysis [16], ultrasound indentation [17] and mechano-acoustic diagnosis [12], among others. It has been suggested that ultrasound examination is a sensitive method for evaluating structural properties [12,41], surface roughness [1-3] and cartilage thickness [6,8,9,17,40]. In our system [10,13,14], wavelet transformation was used to assess three indices, namely signal intensity (an index of stiffness), signal duration (an index of surface irregularity) and interval between signals (an index of thickness) [10,13]. These three indices may also be used in combination with arthroscopy, open surgery and saline bath for experimental purposes (Fig. 2a). In the present study we used the saline bath method.

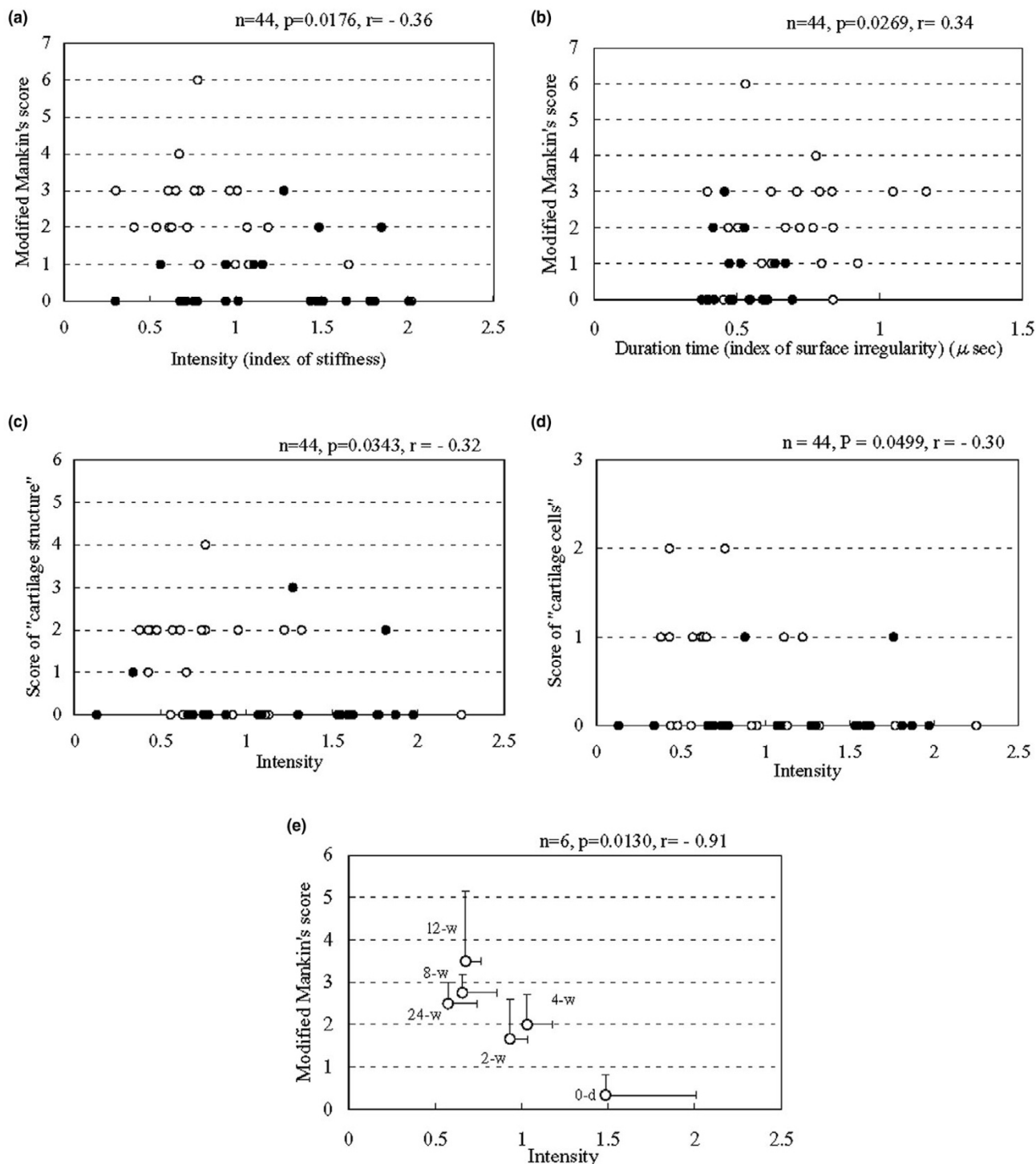
After surgery, the signal intensity of the sham cartilage dropped at 2 weeks and recovered 4 weeks postoperatively. At 8 and 12 weeks the intensity dropped again and remained at this level until 24 weeks (Fig. 7a). The sham cartilage was exposed to air for almost the same period of time as was the OCG. Therefore, some effects of this exposure might be present in both sham and plug cartilage. A study reported that 30 min drying of cartilage resulted in patchy necrosis [42]. Another study revealed that ultrastructural changes occurred in chondrocytes after arthrotomy with 1 hour exposure to air [43]. However, 6 weeks after the arthrotomy the chondrocytes had fully recovered from the changes that were noted immediately after exposure to air. Although we observed neither patchy necrosis nor changes in chondrocytes in the sham knees,

exposure to air might have some harmful effects on cartilage stiffness.

In the plug site on the OCG side a postoperative drop in intensity was also observed (Fig. 7a), but there were some differences from the sham side. At 2 weeks postoperatively the drop in intensity at the plug site was greater than that at the sham site, and recovery 4 weeks postoperatively was limited (Fig. 7a). Although the intensity in both the sham and plug sites was reduced at 8 weeks, the difference between sites was significant ($P < 0.05$). The intensity at the plug site (about half that at day 0) was then maintained until 12 weeks, but had again dropped a little at 24 weeks. The OCG might have been responsible for these differences.

Macroscopic observation revealed that surface of the plug site survived well and underwent repair. At 24 weeks postoperatively in particular, the surface was glossy and as smooth as that of the adjacent, intact cartilage (Fig. 3f). Histological observation, on the other hand, revealed that the plug had sunk or tilted a little at 2 weeks postoperatively or earlier, and that newly formed tissue covered the plug cartilage (Fig. 4c). This histological observation and the drop in signal intensity might be related to each other. The intensity of the newly formed tissue that covered the plug cartilage was lower than that of the sham cartilage (Fig. 7a). At 8 and 12 weeks postoperatively in particular, the intensity was about half that at day 0. Because of this low intensity the tissue could have become detached from the plug cartilage before 24 weeks postoperatively (Fig. 5c). The signal intensity may indicate that the tissue was not sufficiently stiff for weight bearing during these 24 weeks. Use of arthroscopy in this system may detect such weak tissue or cartilage *in vivo*, before it detaches from the host tissue. Also, we observed no tissue regrowth in the shaved area. Based on the histological findings, we speculate that early weight bearing induced slight plug sinking or tilting, and that the shaved area came into direct contact with the patella. The pressure from the patella and its movement might have prevented the growth of new tissue in the shaved area.

Figure 8



(a) Signal intensity (an index of stiffness) correlated significantly with the modified Mankin's score (plug site, open circles; corresponding site on the sham side, closed circles; $n = 44, P = 0.0176, r = -0.36$). **(b)** Signal duration (an index of surface irregularity) correlated significantly with the score ($n = 44, P = 0.0269, r = 0.34$). Signal intensity also correlated with the score categories **(c)** 'cartilage structure' ($n = 44, P = 0.0343, r = -0.32$) and **(d)** 'cartilage cells' ($n = 44, P = 0.0499, r = -0.30$) of the modified Mankin's score. **(e)** When mean values of signal intensity of the plug site were calculated among each of the six groups, the mean was significantly and strongly correlated with the total modified Mankin's score ($n = 6, P = 0.0130, r = -0.91$). D0, day 0; 2-w, 2 weeks; 4-w, 4 weeks; 8-w, 8 weeks; 12-w, 12 weeks; 24-w, 24 weeks.

Although grafts that subsided were considered failed transplants in one study [34], it did not report findings in these failed grafts. Our findings indicate that the subsided plug cartilage was covered with newly formed tissue but was not as intact as normal cartilage, and that it is important to avoid plug sinking or tilting when small, isolated articular cartilage defects are treated by OCG.

In a previous study [13] we observed the space between two types of plug and a recipient hole of 5 mm diameter. Although a 6-mm diameter plug closely fitted the 5-mm hole leaving no space, there was a slight space between a 5-mm diameter plug and the hole. In the present study, we also observed a slight space at day 0 (Fig. 4a) and at 2 weeks postoperatively (Fig. 4c); this space might have been responsible for the sinking or tilting of the plug. Also, because all of the rabbits were allowed to move freely in their cages after the surgery, this early weight bearing might have affected the results. Because bony union between plug and host was observed at 4 weeks postoperatively (Fig. 4e), early weight bearing should be avoided until at least 4 weeks.

A study conducted in a rabbit OCG model, in which a plug of 7 mm diameter and 7 mm depth was harvested and then returned to its original site, suggested that changes in histological properties between host cartilage and grafted cartilage can cause changes in the mechanical properties of the grafted cartilage [44]. It was also noted that, at 24 weeks postoperatively, the grafted cartilage was not as intact as normal cartilage, and that the grafted cartilage was thicker than the normal articular cartilage. Also, the histological appearance of the transplanted articular cartilage resembled that of immature cartilage, even 24 weeks after surgery.

Although our plug was smaller in diameter (5 mm), the procedure for returning the plugs to their original sites was the same as that used by Makino and coworkers [44]. In the present study, at 12 weeks postoperatively the thickness of the plug cartilage (including the newly formed tissue) was greater than that at the sham site (Fig. 5b). In the superficial zone we did not observe normal articular cartilage but there was a newly repaired, cartilage-like tissue that stained faintly with safranin-O. However, at 24 weeks postoperatively there was no reparative tissue covering the plug (Fig. 5c). The plug cartilage was different from normal cartilage because it stained less intensely (Fig. 5c). Also, the signal intensity (an index of stiffness) of the plug cartilage fell to below half that at day 0. This suggests that the plug cartilage lost some of its stiffness after the tissue was detached.

Contrary to our findings, in a morphological and mechanical study conducted in a goat OCG model [45] it was found that, at 12 weeks postoperatively, mechanical stiffness of

plug cartilage changed to six to seven times greater than that in the contralateral control site. That study indicated that no plug subsidence took place, but the cartilage of the plug was thin in comparison with the surrounding host cartilage. Also, the findings of that study suggested that the increased stiffness might be attributable to intrinsic differences between host and donor cartilage tissue sites. In our study, no intrinsic difference between host and donor cartilage tissue sites existed because the plugs were returned to their original position, but the plug sank. Signal intensity (an index of stiffness) decreased and the actual thickness (of the plug cartilage and the newly formed tissue) and the interval between signals (an index of thickness) had increased by 12 weeks postoperatively. These differences between the two studies raises questions as to whether OCG caused these mechanical changes to the plug cartilage, and why the changes occurred when they did. Further investigation of plug diameter and the instruments used will clarify these issues.

We used a modified Mankin's score to represent degeneration of cartilage; increases in the score indicated that degenerative changes had occurred. Because the score increased on the grafted side, degeneration of the plug cartilage appeared to have taken place. The peak score was 3.5 out of a maximum of 14 points at 12 weeks postoperatively, but by 24 weeks the score had improved a little (Fig. 6). This finding suggests that the deterioration was related to the presence of newly formed tissue. Because we counted the tissue as 'pannus and surface irregularities' (2 points), recovery of the score at 24 weeks reflected the detachment of the tissue. Here, the significant correlation of signal intensity with the mean values of modified Mankin's score suggests that, to some extent, early degenerative changes in cartilage may be detected using this ultrasound technique ($P = 0.0130$, $r = -0.91$; Fig. 8e). However, the correlation with individual scores was fairly weak ($P = 0.0176$, $r = -0.36$; Fig. 8a). Although we found that intensity significantly correlated with two categories, namely cartilage structure (Fig. 8c) and cartilage cells (Fig. 8d), these correlations were weak ($P = 0.0343$, $r = -0.32$ and $P = 0.0499$, $r = -0.30$, respectively). Therefore, the intensity may relate to another factor such as superficial structure.

Mechanical properties of articular cartilage are believed to reflect the interaction between proteoglycan and collagen [46]. The composition of cartilage, including proteoglycan content, may be evaluated by observing the intensity of staining. In the present study, however, the correlation between signal intensity and score for staining was not significant ($P = 0.8111$, $r = 0.03$). Two studies reported that high-frequency pulse echo ultrasound proved to be sensitive in detecting degeneration of the superficial collagen-rich cartilage zone [9], and that information gained from

ultrasound appears to be related to changes in the extracellular matrix collagen and probably in its fibrillar network organization [11]. Therefore, our ultrasound analysis of wavelet transformation may detect such changes in collagen rather than in proteoglycan.

Conclusion

Although the plug sank or tilted a little at or earlier than 2 weeks postoperatively, the plug cartilage survived well throughout the 24-week study period. After the plug sank or tilted, newly formed tissue covered the plug. The tissue was attached until 12 weeks, and it was detached from the plug cartilage between 12 and 24 weeks postoperatively. These findings are considered to represent failed transplants. Therefore, it is important to avoid plug sinking or tilting, and to assess the condition of the plug when articular cartilage defects are treated by OCG. The signal intensity may reveal and predict whether the tissue is sufficiently stiff to tolerate weight bearing at 8 and 12 weeks postoperatively. Ultrasound assessment using wavelet transformation may contribute to orthopaedics, rheumatology and related research in arthritis, and arthroscopic use of this system may potentially be preferable for *in vivo* assessment.

Competing interests

None declared.

Acknowledgement

This study was supported in part by a grant from the New Energy and Industrial Technology Development Organization, Japan. The study was performed at the Department of Orthopaedic Surgery, Graduate School of Medicine, Kyoto University, Kyoto, Japan.

References

- Adler RS, Dedrick DK, Laing TJ, Chiang EH, Meyer CR, Bland PH, Rubin JM: **Quantitative assessment of cartilage surface roughness in osteoarthritis using high frequency ultrasound.** *Ultrasound Med Biol* 1992, **18**:51-58.
- Chiang EH, Adler RS, Meyer CR, Rubin JM, Dedrick DK, Laing TJ: **Quantitative assessment of surface roughness using backscattered ultrasound: the effects of finite surface curvature.** *Ultrasound Med Biol* 1994, **20**:123-135.
- Chiang EH, Laing TJ, Meyer CR, Boes JL, Rubin JM, Adler RS: **Ultrasonic characterization of in vitro osteoarthritic articular cartilage with validation by confocal microscopy.** *Ultrasound Med Biol* 1997, **23**:205-213.
- Cherin E, Saied A, Laugier P, Netter P, Berger G: **Evaluation of acoustical parameter sensitivity to age-related and osteoarthritic changes in articular cartilage using 50-MHz ultrasound.** *Ultrasound Med Biol* 1998, **24**:341-354.
- Jurvelin JS, Rasanen T, Kolmonen P, Lyyra T: **Comparison of optical, needle probe and ultrasonic techniques for the measurement of articular cartilage thickness.** *J Biomech* 1995, **28**:231-235.
- Myers SL, Dines K, Brandt DA, Brandt KD, Albrecht ME: **Experimental assessment by high frequency ultrasound of articular cartilage thickness and osteoarthritic changes.** *J Rheumatol* 1995, **22**:109-116.
- Joiner GA, Bogoch ER, Pritzker KP, Buschmann MD, Chevrier A, Foster FS: **High frequency acoustic parameters of human and bovine articular cartilage following experimentally-induced matrix degradation.** *Ultrason Imaging* 2001, **23**:106-116.
- Barber FA, Chow JC: **Arthroscopic osteochondral transplanta-**
- Toyras J, Lyyra-Laitinen T, Niinimäki M, Lindgren R, Nieminen MT, Kiviranta I, Jurvelin JS: **Estimation of the Young's modulus of articular cartilage using an arthroscopic indentation instrument and ultrasonic measurement of tissue thickness.** *J Biomech* 2001, **34**:251-256.
- Toyras J, Nieminen HJ, Laasanen MS, Nieminen MT, Korhonen RK, Rieppo J, Hirvonen J, Helminen HJ, Jurvelin JS: **Ultrasonic characterization of articular cartilage.** *Biorheology* 2002, **39**:161-169.
- Mori K, Hattori K, Habata T, Yamaoka S, Aoki H, Morita Y, Takakura Y, Tomita N, Ikeuchi K: **Measurement of the mechanical properties of regenerated articular cartilage using wavelet transformation.** In *Tissue Engineering for Therapeutic Use 6* Edited by: Ikada Y, Umakoshi Y, Hotta T. Tokyo: Elsevier; 2002:133-142.
- Pellaumail B, Watrin A, Loeuille D, Netter P, Berger G, Laugier P, Saied A: **Effect of articular cartilage proteoglycan depletion on high frequency ultrasound backscatter.** *Osteoarthritis Cartilage* 2002, **10**:535-541.
- Laasanen MS, Toyras J, Vasara AI, Hyttinen MM, Saarakkala S, Hirvonen J, Jurvelin JS, Kiviranta I: **Mechano-acoustic diagnosis of cartilage degeneration and repair.** *J Bone Joint Surg Am* 2003, **Suppl 2**:78-84.
- Kuroki H, Nakagawa Y, Mori K, Ikeuchi K, Nakamura T: **Mechanical effects of autogenous osteochondral surgical grafting procedures and instrumentation on grafts of articular cartilage.** *Am J Sports Med* 2004, **32**:612-620.
- Hattori K, Mori K, Habata T, Takakura Y, Ikeuchi K: **Measurement of the mechanical condition of articular cartilage with an ultrasonic probe: quantitative evaluation using wavelet transformation.** *Clin Biomech (Bristol, Avon)* 2003, **18**:553-557.
- Hattori K, Takakura Y, Morita Y, Takenaka M, Uematsu K, Ikeuchi K: **Can ultrasound predict histological findings in regenerated cartilage?** *Rheumatology (Oxford)* 2004, **43**:302-305.
- Nieminen HJ, Toyras J, Rieppo J, Nieminen MT, Hirvonen J, Korhonen R, Jurvelin JS: **Real-time ultrasound analysis of articular cartilage degradation in vitro.** *Ultrasound Med Biol* 2002, **28**:519-525.
- Suh JK, Youn I, Fu FH: **An in situ calibration of an ultrasound transducer: a potential application for an ultrasonic indentation test of articular cartilage.** *J Biomech* 2001, **34**:1347-1353.
- Han CW, Chu CR, Adachi N, Usas A, Fu FH, Huard J, Pan Y: **Analysis of rabbit articular cartilage repair after chondrocyte implantation using optical coherence tomography.** *Osteoarthritis Cartilage* 2003, **11**:111-121.
- Sahlstrom A, Johnell O, Redlund-Johnell I: **The natural course of arthrosis of the knee.** *Clin Orthop* 1997, **340**:152-157.
- Messner K, Maletius W: **The long-term prognosis for severe damage to weight-bearing cartilage in the knee: a 14-year clinical and radiographic follow-up in 28 young athletes.** *Acta Orthop Scand* 1996, **67**:165-168.
- Buckwalter JA, Mow VC: **Cartilage repair in osteoarthritis.** In *Osteoarthritis, Diagnosis and Medical/Surgical Management* 2nd edition. Edited by: Moskowitz RW, Howell DS, Goldberg VM, Mankin HJ. Philadelphia: WB Saunders; 1992:71-107.
- Hangody L, Kish G, Karpati Z, Szerb I, Udvarhelyi I: **Arthroscopic autogenous osteochondral mosaicplasty for the treatment of femoral condylar articular defects. A preliminary report.** *Knee Surg Sports Traumatol Arthrosc* 1997, **5**:262-267.
- Matsusue Y, Yamamuro T, Hama H: **Arthroscopic multiple osteochondral transplantation to the chondral defect in the knee associated with anterior cruciate ligament disruption.** *Arthroscopy* 1993, **9**:318-321.
- Hangody L, Kish G, Karpati Z, Eberhart R: **Osteochondral plugs: autogenous osteochondral mosaicplasty for the treatment of focal chondral and osteochondral articular defects.** *Oper Tech Orthop* 1997, **7**:312-322.
- Marcacci M, Kon E, Zaffagnini S, Visani A: **Use of autologous grafts for reconstruction of osteochondral defects of the knee.** *Orthopedics* 1999, **22**:595-600.
- Nakagawa Y, Matsusue Y, Ikeda N, Asada Y, Nakamura T: **Osteochondral grafting and arthroplasty for end-stage osteochondritis dissecans of the capitellum. A case report and review of the literature.** *Am J Sports Med* 2001, **29**:650-655.
- Kish G, Modis L, Hangody L: **Osteochondral mosaicplasty for the treatment of focal chondral and osteochondral lesions of the knee and talus in the athlete. Rationale, indications, techniques, and results.** *Clin Sports Med* 1999, **18**(vi):45-66.
- Kish G, Modis L, Hangody L: **Osteochondral mosaicplasty for the treatment of focal chondral and osteochondral lesions of the knee and talus in the athlete. Rationale, indications, techniques, and results.** *Arthroscopy* 2001, **17**:832-835.

29. Berlet GC, Mascia A, Miniaci A: **Treatment of unstable osteochondritis dissecans lesions of the knee using autogenous osteochondral grafts (mosaicplasty).** *Arthroscopy* 1999, **15**:312-316.
30. Bobic V: **Arthroscopic osteochondral autograft transplantation in anterior cruciate ligament reconstruction: a preliminary clinical study.** *Knee Surg Sports Traumatol Arthrosc* 1996, **3**:262-264.
31. Matsusue Y, Kotake T, Nakagawa Y, Nakamura T: **Arthroscopic osteochondral autograft transplantation for chondral lesion of the tibial plateau of the knee.** *Arthroscopy* 2001, **17**:653-659.
32. Nakagawa Y, Matsusue Y, Nakamura T: **Osteochondral graft transplantation for steroid-induced osteonecrosis of the femoral condyle.** *Lancet* 2003, **362**:402.
33. Nakagawa Y, Matsusue Y, Nakamura T: **A novel surgical procedure for osteochondritis dissecans of the lateral femoral condyle: exchanging osteochondral plugs taken from donor and recipient sites.** *Arthroscopy* 2002, **18**:E5.
34. Handody L, Udvarhelyi I, Kish G, Toth J, Karpati Z, Dioszegi Z, Szerb I, Kendik Z: **Autogenous osteochondral graft technique for replacing knee cartilage defects in dogs.** *Orthop Int* 1997, **5**:175-181.
35. Rushfeldt PD, Mann RW, Harris WH: **Improved techniques for measuring in vitro the geometry and pressure distribution in the human acetabulum - I. Ultrasonic measurement of acetabular surfaces, sphericity and cartilage thickness.** *J Biomech* 1981, **14**:253-260.
36. Mak AF, Lai WM, Mow VC: **Biphasic indentation of articular cartilage - I. Theoretical analysis.** *J Biomech* 1987, **20**:703-714.
37. Mow VC, Gibbs MC, Lai WM, Zhu WB, Athanasiou KA: **Biphasic indentation of articular cartilage - II. A numerical algorithm and an experimental study.** *J Biomech* 1989, **22**:853-861.
38. Bulstra SK, Buurman WA, Walenkamp GH, Van der Linden AJ: **Metabolic characteristics of in vitro cultured human chondrocytes in relation to the histopathologic grade of osteoarthritis.** *Clin Orthop* 1989, **242**:294-302.
39. Mankin HJ, Dorfman H, Lippiello L, Zarins A: **Biochemical and metabolic abnormalities in articular cartilage from osteoarthritic human hips. II. Correlation of morphology with biochemical and metabolic data.** *J Bone Joint Surg Am* 1971, **53**:523-537.
40. Modest VE, Murphy MC, Mann RW: **Optical verification of a technique for in situ ultrasonic measurement of articular cartilage thickness.** *J Biomech* 1989, **22**:171-176.
41. Kim HK, Babyn PS, Harasiewicz KA, Gahunia HK, Pritzker KP, Foster FS: **Imaging of immature articular cartilage using ultrasound backscatter microscopy at 50 MHz.** *J Orthop Res* 1995, **13**:963-970.
42. Mitchell N, Shepard N: **The deleterious effects of drying on articular cartilage.** *J Bone Joint Surg Am* 1989, **71**:89-95.
43. Speer KP, Callaghan JJ, Seaber AV, Tucker JA: **The effects of exposure of articular cartilage to air. A histochemical and ultrastructural investigation.** *J Bone Joint Surg Am* 1990, **72**:1442-1450.
44. Makino T, Fujioka H, Kurosaka M, Matsui N, Yoshihara H, Tsunoda M, Mizuno K: **Histologic analysis of the implanted cartilage in an exact-fit osteochondral transplantation model.** *Arthroscopy* 2001, **17**:747-751.
45. Lane JG, Tontz WL Jr, Ball ST, Massie JB, Chen AC, Bae WC, Amiel ME, Sah RL, Amiel D: **A morphologic, biochemical, and biomechanical assessment of short-term effects of osteochondral autograft plug transfer in an animal model.** *Arthroscopy* 2001, **17**:856-863.
46. Elliott DM, Guilak F, Vail TP, Wang JY, Setton LA: **Tensile properties of articular cartilage are altered by meniscectomy in a canine model of osteoarthritis.** *J Orthop Res* 1999, **17**:503-508.