

Research article

Open Access

CT features in abdominal tuberculosis: 20 years experience.

Tariq Sinan¹, Mehraj Sheikh*¹, Salwa Ramadan², Sukhpal Sahwney² and Abdulla Behbehani³

Address: ¹Department of Radiology, Kuwait University, Jabriya, Kuwait, ²Department of Radiology, Adan Hospital, Kuwait and ³Department of Surgery, Kuwait University, Jabriya, Kuwait

E-mail: Tariq Sinan - drtariq999@yahoo.com; Mehraj Sheikh* - mehraj@hsc.kuniv.edu.kw; Salwa Ramadan - salwafais@yahoo.com; Sukhpal Sahwney - sukh48@yahoo.com; Abdulla Behbehani - quick_behbehani@yahoo.com

*Corresponding author

Published: 12 November 2002

Received: 25 June 2002

BMC Medical Imaging 2002, **2**:3

Accepted: 12 November 2002

This article is available from: <http://www.biomedcentral.com/1471-2342/2/3>

© 2002 Sinan et al; licensee BioMed Central Ltd. This is an Open Access article: verbatim copying and redistribution of this article are permitted in all media for any purpose, provided this notice is preserved along with the article's original URL.

Abstract

Background: Abdominal tuberculosis (TB) is endemic in the developing world and is reemerging in the West. Since computed tomography (CT) has the ability to demonstrate changes in the peritonium, mesentery, lymphnodes, bowel and solid organs and is being increasingly used for primary evaluation of abdominal conditions, it is important to be familiar with the CT features of the disease.

Methods: CT findings were retrospectively analysed in 49 patients with proved abdominal TB. Patients with genitourinary TB and with AIDS/HIV were not included in the study.

Results: Peritoneal involvement was the most common feature (77.5%) with ascites (wet peritonitis) seen in more than half the cases (55.2%). The rest showed peritoneal, mesenteric or omental thickening or mass formation but no ascites (dry peritonitis). Other findings included lymphadenopathy (46.9% mainly of diffuse nature, bowel wall thickening (38%) and solid organ involvement (20.4%).

Conclusions: CT reliably demonstrates the entire range of findings which need interpretation in the light of clinical and laboratory data.

Background

Tuberculosis (TB) is a re emerging global emergency which is further complicated by AIDS/HIV infection and the use of immunosuppressant drugs [1]. The disease may involve any body system and in the abdomen it can mimic many conditions, like inflammatory bowel disease, malignancy and other infectious diseases [2-4]. Untreated or delayed treatment can result in life long morbid complications. It is therefore necessary to recognize the disease early and initiate treatment for this curable disease. Abdominal TB may present varying imaging features de-

pending upon the organs involved. CT offers the unique ability to image the entire abdominal structures in a single examination and is widely available. It is therefore important to be familiar with the CT features of the disease and its complications. Our retrospective study describes the CT features of abdominal TB in 49 proven cases.

Methods

Between April 1982 and February 2002, 49 consecutive patients with proven abdominal TB who had CT scans of the abdomen as part of their diagnostic work up were re-

viewed. There were 37 males and 12 females, with age range of 10 to 78 years (mean age 35.27 years). The scans were independently reviewed by 2 radiologists and any disagreement in findings was resolved by combine review of the scans and a consensus reached. The diagnosis was established on the basis of at least one of the following criteria:

- a) Histological evidence of caseating granuloma.
- b) Histological demonstration of acid fast bacilli in the lesion or ascetic fluid.
- c) Growth of mycobacterium tuberculosis on culture of tissue or ascetic fluid.
- d) Satisfactory therapeutic response to chemotherapy in patients with clinical, radiological and operative evidence of abdominal tuberculosis.

The case records were analysed according to age, sex, nationality clinical presentation and CT findings. Immuno-compromised and AIDS/HIV patients were not included in the study. Genitourinary TB was also excluded except in those cases with co-existing abdominal lymphadenopathy.

Results

The majority (63.26%) of the patients were non-Kuwaitis. The symptoms of these patients on presentation are shown in Table 1. The common sites of involvement are shown in table 2. CT analysis of the pattern of abdominal TB revealed peritoneal involvement in 38/49 (77.5%) cases and was classified as "wet peritonitis" defined as free or loculated ascites of large or small volume, depending upon the depth of ascites (whether more or less than 3 cm respectively; Figs 1 &2) or "dry peritonitis" represented by peritoneal mesenteric or omental thickening or mass but without ascites (Fig 3). Wet peritonitis [21/38 cases (52.3%)] and the "dry" type [17/38 (45.7%)] were both commonly seen. The details regarding the "free" and "loculated" nature and the volume of ascites (i.e. small or large), is shown in table 3. The pattern of mesenteric and omental disease with or without ascites revealed that stranding of the mesenteric fat (18 cases; 47.3%) and omental thickening (9 cases; 23.6%) (Fig 3 and Fig 4) was more common than mesenteric or omental mass (3 cases; 7.8%) Fig. 1.

Lymphnode involvement was detected in 23/49 (46.9%) patients of whom 11 cases (47.8%) had diffuse involvement throughout the abdomen [Fig. 5]. Localised or regional adenopathy was seen in several sites including mesentric (6/23; 26%) peripancreatic/portal (3/23, 13%) and para aortic (3/23; 13%) (Table 4). GIT disease was

noted in 19/49 (38.7%) cases. Majority of the cases (17/20; 86.8%) involved the small bowel, with or without the caecum. (Table 5) showing strictures and thickening of the bowel wall [Figs. 4 &6]. Isolated large bowel disease was less frequent (2/19 cases; 10.5%). Perforation of the gut was seen in 3 cases, 2 of the large bowel leading to a parietal abscess in 1 patient [Fig. 6] and hydropneumoperitium in the other. The third case was a perforating tuberculous gastric ulcer, resulting in an inflammatory mass of the lesser sac and the pancreas [Fig. 7]. Vesico-colic fistula was seen in 1 case. The solid organ disease occurred in 10/49 cases (20.4%) and the distribution is shown in Table 6. The liver and spleen involvement was seen as multi focal hypodense lesions [Fig. 8 and Fig. 9] where as the pancreas showed focal abscess, one of which was due to direct involvement from perforating TB gastric ulcer [Fig. 7]. A combination of these findings was seen in 21/49 cases (42,8 %) involving more than one system in varying combination.

Table 1:

Symptoms	No. of patients n = 49
Abdominal pain:	37 (75.5%)
Fever:	32 (65.3%)
Weight loss:	18 (36.7%)
Vomiting:	7 (14.2%)
Abdominal mass:	5 (10.2%)
Diarrhoea:	1 (2.0%)
Acute Abdominal pain:	1 (2.0%)
Pneumaturia:	1 (2.0%)
* Convulsions:	1 (2.0%)

* This patient had intracranial tuberculomas. A lower abdominal tubercular mass was diagnosed on routine examination.

Table 2: Summary of CT Findings n = 49

Peritonitis (Mesentry, omental and peritoneal disease):	38 (77.5%)
Lymph nodes:	23 (46.9%)
G.I.T:	19 (38.7%)
Solid organ involvement:	10 (20.4%)

Discussion

The causative organism for abdominal TB is usually mycobacterium tuberculosis or mycobacterium avium – intracellulare, the latter being more common in immuno-compromised hosts [5]. Abdominal TB is usually caused by injection of bacilli in infected sputum or contaminated food. The bacilli cause caseation necrosis in the intestine, followed by spread to the mesenteric lymph nodes that

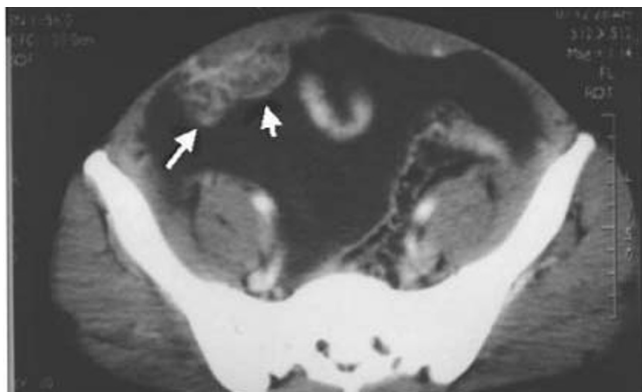


Figure 1
Wet peritonitis: CT scan of the pelvis showing large volume free ascites. Note omental mass (arrows).

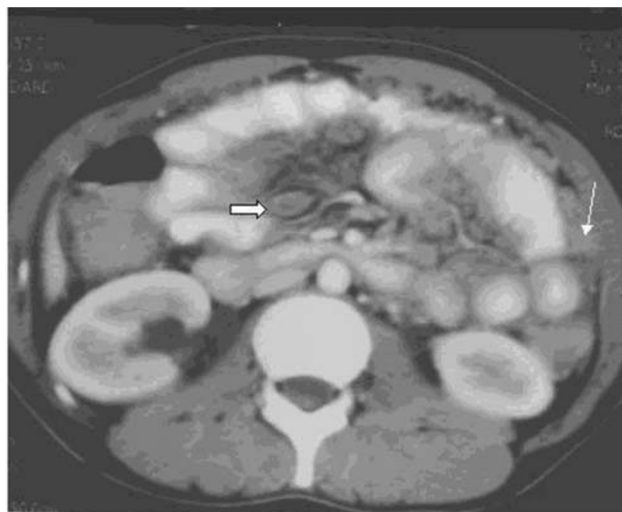

Figure 3
Dry peritonitis: CT scan showing diffuse mesenteric strands, mesenteric nodes and omental thickening.

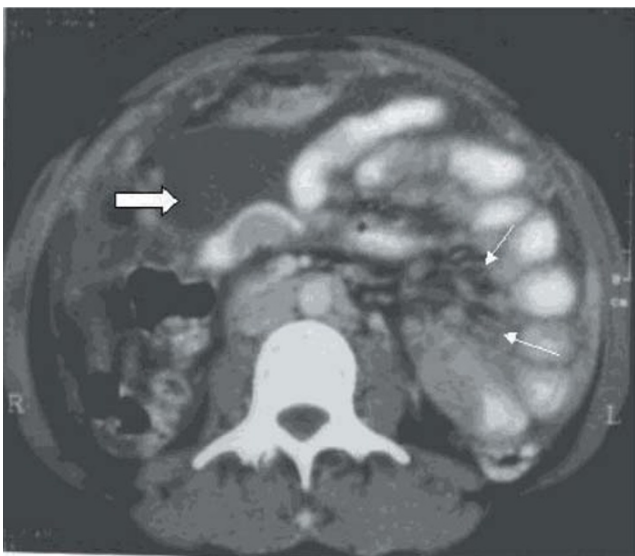


Figure 2
Wet peritonitis: CT scan mid-abdomen showing small volume loculated ascites (thick arrow) Note mesenteric strands and mesenteric nodes (thin arrow). Peritoneal thickening is seen in the right side.

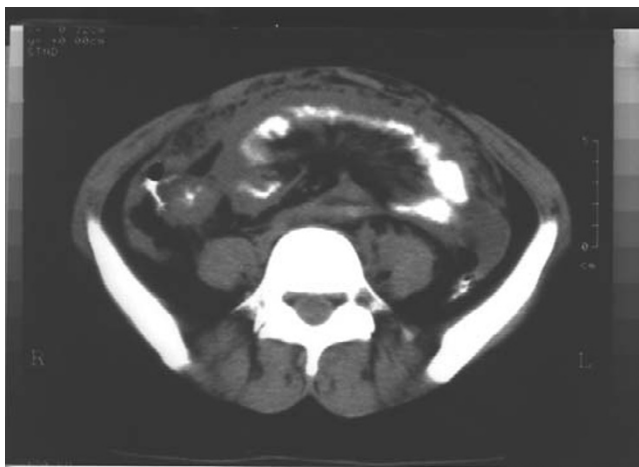

Figure 4
Circumferential thickening of the caecum and narrowing of the terminal ileum. Also note mesenteric strands and omental thickening.

Table 3: CT features of Peritoneal TB (n = 38; wet = 21; dry = 17)

Ascites + Mesenteric and/or omental disease n = 13					Ascites only n = 8				
Free		Loculated			Free		Loculated		
LV	SV	LV	SV		LV	SV	LV	SV	
3	2	6	2		5	1	1	1	

LV = large volume; SV = small volume

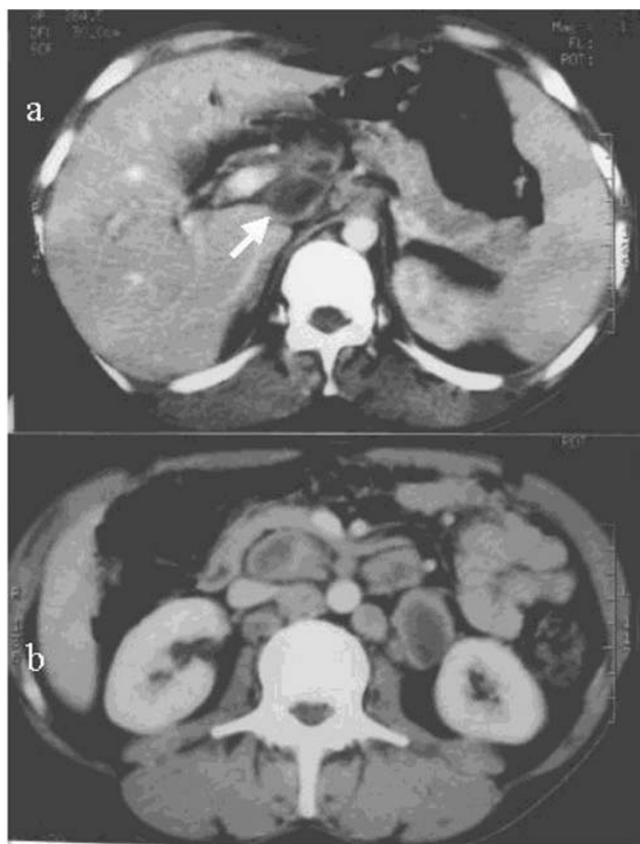


Figure 5
Necrotic lymph nodes with lucent center seen in the (a) port/peri pancreatic region (arrow) and (b) para-aortic area.

Table 4: Distribution of Lymph nodes (n = 23)

Diffuse (Peripancreatic ± Mesenteric ± paraaortic)	11 (48%)
Mesenteric:	6 (26%)
Peripancreatic/Portal:	3 (13%)
Para aortic:	3 (13%)

Table 5: GIT Tuberculosis (n = 20)

Ileocecal and distal ileum:	10 (50%)
Small bowel:	7 (36.8%)
Large bowel:	2(10.5%)
Stomach (ulcer):	1 (5.2%)
* Perforation:	2
* Fistulae:	1

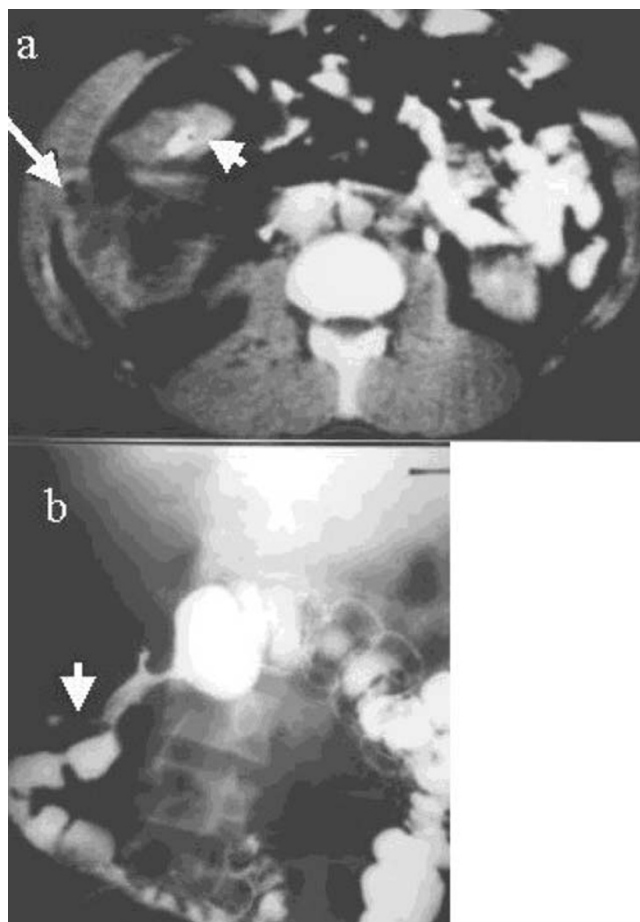


Figure 6
(a) CT scan showing circumferential thickening of the ascending colon (short arrow). Note right parietal abscess with free air (long arrow). (b) This was due to a fistula (arrow) of the ascending colon confirmed by barium enema.

Table 6: Solid Organ Involvement (n = 10)

Spleen:	3 (30%)
Liver:	2 (20%)
Liver + Spleen:	2 (20%)
Pancreas:	2 (20%)
Kidneys*:	1 (10%)

*This patient with abdominal lymphadenopathy had coexistent kidney disease.

taken for a tumour. In our series, peritonitis was equally likely to be either of the wet or dry type and the ascites (both free and loculated) was more commonly large volume. Isolated omental disease was not seen in any of our cases, though the omentum was involved in a vast majority of our cases in combination with other features of the disease. Ascites in abdominal TB can be due to an earlier transudate stage of immune reaction or due to late cell

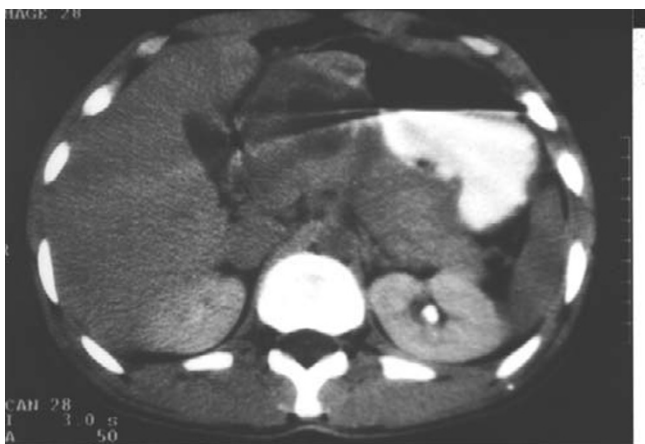

Figure 7
CT of the upper abdomen showing large necrotic inflammatory mass in the lesser sac and involving the pancreas. This was due to perforating gastric TB ulcer.

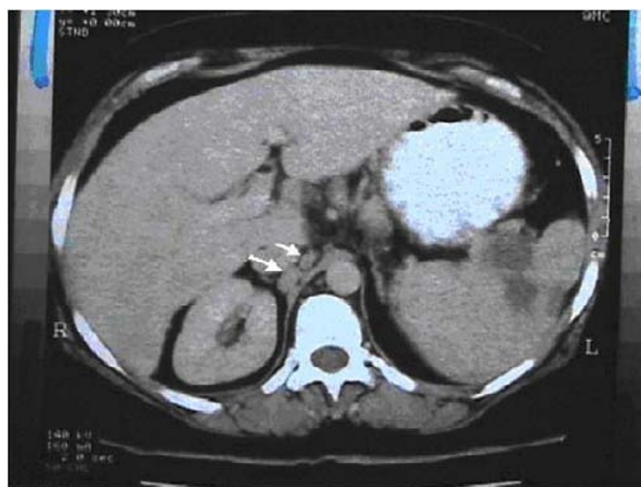


Figure 9
CT of the upper abdomen focal lesions in the spleen. Note associated para aortic nodes (arrows).

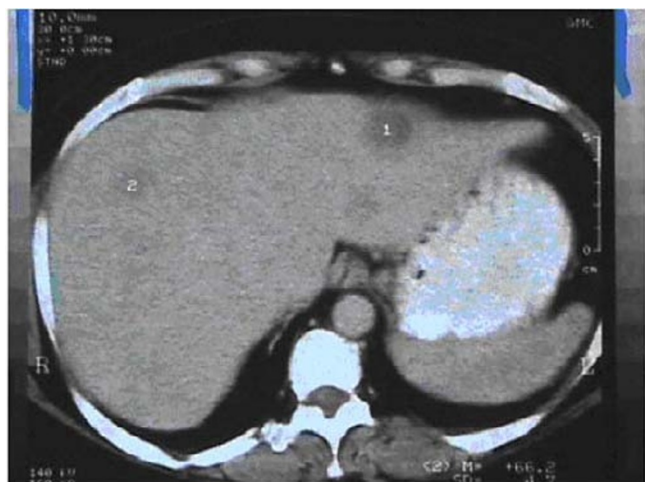

Figure 8
CT of the upper abdomen showing multiple focal hypodense lesions in the liver.

mediated immunity when the fluid is complex with strands, septation and debris [9]. Unlike US the complex nature of the ascites is difficult to demonstrate by CT, [12] however CT is useful in determining the density of the ascitic fluid which is reported to be high; presumably due to the complex nature of the fluid. The high density nature of the fluid is reported by some authors [13,14] as specific for TB whereas other [15] suggest that it is not a reliable factor and can overlap with peritoneal carcinomatosis. The differential diagnosis of complex ascites includes wide spread lymphoma and carcinomatous as well as pyogenic peritonitis [14]. Mesenteric disease is an important and common manifestation of early stage abdominal TB

[16]. The mesentery is initially thickened with a few discrete lymph nodes interspersed within it and, the later stage mesenteric disease represents irregular inflammatory masses of caseating lymph nodes [16]. CT offers the distinct advantage of demonstrating these features unlike US where the bowel gas may prevent adequate visualization of the mesentery [17].

Abdominal lymph adenopathy commonly involves mesenteric, portal and peripancreatic sites reflecting the lymphatic drainage of the small bowel [5]. The retroperitoneal lymph nodes are relatively spared [16] and their involvement rarely occurs in isolation. In disseminated TB however diffuse lymphadenopathy without predilection to any site may be seen, though the retroperitoneal node's size is out of proportion to the lymphadenopathy elsewhere in the abdomen [6]. The nodes are usually matted together with hypodense centers which probably is due to caseation and many occasionally contain calcification [18,19]. Lymphnode enlargement is non specific and occurs in metastatic disease, lymphoma Whipple's disease and pyogenic infection [20]. In our series 47% of patients had a lymphadenopathy pattern similar to that reported by others [6]. Central necrosis with rim enhancement, though not pathognomonic, is a useful sign and readily seen in the current generation of CT scanners.

The commonest sites of gastro intestinal tract TB are terminal ileum and cecum [21–24]. Other sites in which the disease occurs are, in descending order of frequency, the ileum, cecum, ascending colon, jejunum, other parts of colon, rectum, duodenum and stomach [25]. GIT TB may be ulcerative type, hyperplastic type or a combination of

the two. The ileo-cecal TB is often hyperplastic type [26]. In early stage disease a few regional nodes and circumferential thickening of the wall of the cecum and terminal ileum are seen. In later stages of the disease the ileocecal valve and adjacent medial wall of the cecum are predominantly and symmetrically thickened. These changes are however nonspecific and may also be seen in cecal carcinoma, Crohn's disease, lymphoma and amebiasis. In advanced ileocecal disease gross wall thickening, adherent small bowel loops, large regional lymphnodes and exophytic mesenteric thickening together form a complex mass of varied density, which is characteristic of CT appearance of TB and is reported to be seen in 45% of the cases [22]. Isolated colonic, duodenal and gastric TB are rare [25]. There was one case of gastric TB in our study. Although mucosal changes are best evaluated by barium examinations, evidence of extramucosal disease is both indirect and incomplete and CT is valuable in evaluating directly the extramucosal component of the disease.

Visceral TB is rarely seen in isolation and is more frequently part of multifocal or disseminated disease [9,11,27,28]. Liver and spleen are the main organs involved and their involvement can occur in the form of micro abscesses in miliary TB, pattern represented by CT as diffuse low density focal lesions, or in the form of larger abscesses [29,30]. Often the only feature of visceral TB is organomegaly with calcified granulomas visible in the late stage disease or after healing. Pancreatic TB is rare and may result from either hematogenous dissemination or direct spread of the disease from adjacent nodes. There were 2 cases of pancreatic TB in our series, one of them was due to direct spread from a penetrating tuberculous gastric ulcer. Two more cases of perforations of large bowel was seen in our study, one in the ascending colon presenting as a parietal abscess and other in the colon leading to hydropneumoperitonim and peritonitis. One case of vesico-colic fistula was also seen which presented as pneumoturia.

Conclusions

Manifestations of TB in the abdomen are variable. CT reliably demonstrates the entire range of findings. Although no single CT feature is diagnostic of the disease, CT findings, interpreted in the light of clinical and laboratory data can be a valuable tool in the diagnosis of abdominal tuberculosis.

Competing interest

None declared

Author's contributions

Authors TS and MS contributed case material from Mubarak Al-Kabeer Hospital. Authors SR and SS contributed case material from Adan Hospital. MS drafted the manu-

script. Author AB participated in the coordination of the study. All the authors read the manuscript.

Acknowledgements

The authors would like to thank Sally Roy for recording the patients data base and Delphine D'Souza for typing this manuscript.

References

1. Dye C, Scheele S, Dolin P, Pathania V, Raviglione MC: **Consensus statement. Global burden of tuberculosis: estimated incidence, prevalence, and mortality by country. WHO Global Surveillance and Monitoring Project.** *JAMA* 1999, **282**:677-686
2. Suri S, Gupta S, Suri R: **Computed tomography in abdominal tuberculosis.** *B J Radiol* 1999, **72**:92-8
3. Jadvar H, Mindelzun RE, Olcott EW, Levitt DB: **Still the great mimicker: Abdominal tuberculosis.** *AJR Am J Roentgenol* 1997, **168**:1455-60
4. Akhan O, Pringot J: **Imaging of abdominal tuberculosis.** *Eur Radiol* 2002, **12**:312-23
5. Batra A, Gulati MS, Sarma D, Paul SB: **Sonographic appearances in abdominal tuberculosis.** *J of Clin Ultrasound* 2000, **28**:233-245
6. Hulnick DH, Megibow AJ, Naidich DP, Hilton S, Cho KC, Balthazar EJ: **Abdominal tuberculosis: CT evaluation.** *Radiology* 1985, **157**:199-204
7. Hanson RD, Hunter TB: **Tuberculous peritonitis: CT appearance.** *AJR Am J Roentgenol* 1985, **144**:931-932
8. Dahlene DH Jr, Stanley RJ, Koehler RE, et al: **Abdominal tuberculosis: CT findings.** *J Comput Assist Tomogr* 1984, **8**:443-445
9. Lee DH, Lim JH, Ko YT, et al: **Sonographic findings of tuberculous peritonitis of wet ascitic type.** *Clin Radiol* 1991, **44**:306-10
10. Al-Hilaly MA, Abu Zidan FM, Zayed FF, et al: **Tuberculous appendicitis with perforation.** *Br J Clin Pract* 1990, **44**:632-3
11. Thoeni RF, Margulis AR: **Gastrointestinal tuberculosis.** *Semin Roentgenol* 1979, **14**:283
12. Ozkan K, Gurses N: **Ultrasonic appearance of tuberculous peritonitis: Case report.** *J Clin Ultrasound* 1987, **15**:350-2
13. Sheikh M, Mossa I, Hussein FMY, Qurttom MAF, Behbehani AI: **Ultrasonographic diagnosis in abdominal tuberculosis.** *Australasian Radiology* 1999, **43**:175-179
14. Seshul MB, Coulam CM: **Pseudomyxoma peritonei: Computed tomography and sonography.** *AJR Am J Roentgenol* 1981, **136**:803-6
15. Bankier AA, Fleischman D, Wiesmayr MN, Wiesman MN, Putz D, Kontrus M, et al: **Update: Abdominal tuberculosis – unusual findings on CT.** *Clin Radiol* 1995, **50**:223-228
16. Jain R, Sawhney S, Bhargava DK, et al: **Diagnosis of abdominal tuberculosis: sonographic findings in patients with early disease.** *AJR Am J Roentgenol* 1995, **165**:1391
17. Sheikh M, Abu Zidan FM, Al-Hilaly MA, Behbehani AI: **Abdominal Tuberculosis. Comparison of sonography and computed tomography.** *J Clin Ultrasound* 1995, **23**:413-17
18. Epstein BM, Mann JH: **CT of abdominal tuberculosis.** *AJR Am J Roentgenol* 1982, **139**:861-6
19. Gulati MS, Sarma D, Paul SB: **CT appearances in abdominal tuberculosis: A pictorial essay.** *Clinical Imag* 1999, **23**:51-59
20. Li DKD, Rennie CS: **Abdominal computed tomography in Whipple's disease.** *J Comput Assist Tomogr* 1980, **4**:630-633
21. Lundstedt C, Myman R, Brismar J, Hugosson C, Kagevi I: **Imaging of tuberculosis II. Abdominal manifestations in 112 patients.** *Acta Radiol* 1996, **37**:489-405
22. Balthazar EJ, Gordon R, Hulnick D: **Ileocecal tuberculosis: CT and radiologic evaluation.** *AJR Am J Roentgenol* 1990, **154**:499-503
23. Underwood MJ, Thompson MM, Sayers RD, Hall AWW: **Presentation of abdominal tuberculosis to general surgeons.** *Br J Surg* 1992, **79**:1077-1079
24. Aston NO, de Costa AM: **Abdominal tuberculosis.** *Br J Clin Pract* 1990, **44**:58-61
25. Paustian FF, Marshal JB: **Intestinal tuberculosis.** In: *Gastroenterology (Edited by: Berk JE) Philadelphia: WB Saunders Co* 1985, 2018
26. Lim JH, Ko YT, Lee DH, et al: **Sonography of inflammatory bowel disease: findings and value in differential diagnosis.** *AJR Am J Roentgenol* 1994, **163**:343
27. Bhansali SK: **Abdominal tuberculosis. Experience with 300 cases.** *Am J Gastroenterol* 1977, **67**:324-337

28. Denath FM: **Abdominal Tuberculosis in children: CT findings.** *Gastrointest Radiol* 1990, **15**:303-306
29. Jain R, Sawhney G, Gupta RG, et al: **Sonographic appearances and percutaneous management of primary tuberculous liver abscess.** *J Clin Ultrasound* 1999, **27**:159
30. Zisper RD, Rav JE, Ricketts RR, Lynn CB: **Tuberculous pseudotumors of the liver.** *Am J Med* 1976, **61**:946-951

Pre-publication history

The pre-publication history for this paper can be accessed here:

<http://www.biomedcentral.com/1471-2342/2/3/prepub>

Publish with **BioMed Central** and every scientist can read your work free of charge

"BioMed Central will be the most significant development for disseminating the results of biomedical research in our lifetime."

Sir Paul Nurse, Cancer Research UK

Your research papers will be:

- available free of charge to the entire biomedical community
- peer reviewed and published immediately upon acceptance
- cited in PubMed and archived on PubMed Central
- yours — you keep the copyright

Submit your manuscript here:
http://www.biomedcentral.com/info/publishing_adv.asp

