

# The developing occlusion of children and young people in general practice: when to watch and when to refer

J. K. Scott<sup>\*1</sup> and N. E. Atack<sup>2</sup>

## IN BRIEF

- Discusses the assessment of developing occlusions in children and adolescents.
- Reviews the potential of interceptive orthodontics, and uses case examples.
- Provides a quick reference guide to orthodontic assessment, treatment need and referral.

This paper discusses the assessment of the developing occlusions of children and adolescents in the general practice setting; that is, reviewing the potential of interceptive orthodontics. In particular we will illustrate the management of these individuals with case examples. We have also provided a handy pull-out guide with this issue of the Journal which can be used in the GDP's surgery for quick reference.

## INTRODUCTION

In 2013/2014, 457,248 orthodontic assessment claims were submitted for payment to the NHS Business Services Authority which gives an indication of the number of patients referred from general dental practitioners (GDPs) for orthodontic treatment. In the same year over £250 million of NHS dental budget was spent on orthodontic care (2013–14 figures provided by the NHS Business Services Authority). With increasing pressure on these resources the importance of the GDP as gatekeeper to specialist services is vital. Although routine orthodontic treatment is usually started after the age of 11, there are a number of children for which an earlier referral for a specialist opinion is appropriate.

The demand for straight teeth is increasing and many patients will ask their GDP about orthodontic treatment, while others are unaware of significant issues, such as impacted teeth. The role of the GDP is to monitor dental development and highlight any variations from the expected.<sup>1</sup> They must then decide whether to monitor the patient or to refer them, either to a specialist orthodontist in practice, community or hospital setting. To know when there is a deviation from the expected development you must first understand what is normal. There are many textbooks available which

describe dental development and it is not the aim of this paper to give details on this subject. When assessing a patient of any age you should have an idea of what you would expect to see. One of the aims of the GDP is to spot the unusual. There are a number of questions you can ask yourself to help with this process such as:

- Are the teeth healthy?
- Is the patient in the deciduous, mixed or permanent dentition?
- Is the correct number of teeth present? If not, why not?
- Is the shape, size and position of teeth correct?
- Is the eruption pattern symmetrical and correct for the child's 'dental age'?
- Is the occlusion good? That is, are there any crossbites?
- What, if the patient's oral hygiene/dental health is inadequate for orthodontic treatment, should you advise the family?

Orthodontic intervention or treatment in the mixed dentition is often called 'interceptive orthodontics'. This is not a new concept and is taken to mean any treatment procedure which eliminates or reduces the severity of a developing malocclusion.<sup>2</sup> It is useful as undertaking appropriate interception may reduce the need for further treatment or make this simpler. In a way these procedures can be viewed as 'orthodontic forward planning'.

## PATIENTS IN THE DECIDUOUS DENTITION

When the deciduous teeth are developing you should look to see if the number of teeth and pattern of eruption is normal. Please see the quick reference guide which

accompanies this article and can be used in the surgery.

Anomalies to look-out for include:

- Supplemental deciduous incisors, may be a precursor for supplemental permanent teeth
- Missing deciduous teeth, may indicate permanent successor absence.

Adverse skeletal patterns are sometimes seen in this age group. A class 2 skeletal pattern may naturally improve with growth whereas a class 3 skeletal pattern may worsen. As there is no way of predicting facial growth the parents should be reassured and the patient's growth monitored. If an adverse pattern persists or worsens into the permanent dentition then the patient may be referred for an opinion.

Digit/dummy sucking is common in young children and should be actively discouraged and stopped before the age of seven. Nocturnal habits can be hard to break but can be aided by a parent taping a glove or a sock onto the child's hand(s) every night for two weeks, along with verbal reminders during the day. Persistent habits beyond the age of seven years are likely to have an adverse effect on the permanent dentition. The British Orthodontic Society (BOS) provides a series of patient information leaflets that can be accessed online and include one on dummy and thumb sucking (<http://www.bos.org.uk/PILs>).

## PATIENTS IN THE MIXED DENTITION

In the mixed dentition the pattern of eruption should be monitored (see quick reference guide). It should be remembered that the patient's dental age does not always

<sup>1</sup>Consultant Orthodontist, Derriford Hospital, Plymouth, PL6 8DH; <sup>2</sup>Consultant Orthodontist, University of Bristol Department of Oral and Dental Science, Bristol, BS1 2LY  
\*Correspondence to: Dr Julia Scott  
Email: [juliascott3@nhs.net](mailto:juliascott3@nhs.net)

### Refereed Paper

Accepted 14 January 2015  
DOI: 10.1038/sj.bdj.2015.54

©British Dental Journal 2015; 218: 151–156

match their chronological age. Patients and parents can be reassured that the teeth are developing normally but at a slower rate than average; this alone should not raise any concerns. Once a tooth has erupted its contralateral counterpart usually erupts within six months. If this is not the case then you should question why. If there is a difference in timing then the patient should be asked about any history of trauma to the deciduous teeth. A periapical or upper occlusal radiograph may provide information towards the diagnosis of unerupted incisor or canine teeth. The British Orthodontic Society orthodontic radiograph guidelines provide guidance that should be followed when taking radiographs for the orthodontic patient.<sup>3</sup>

### MANAGEMENT OF THE UNERUPTED UPPER CENTRAL INCISOR

*What should raise alarms:* If no mobility is evident in a remaining deciduous central incisor if the contralateral permanent tooth has erupted. If at least six months has passed since the eruption of a permanent upper central incisor and the contralateral tooth is unerupted. There is a known history of trauma to the deciduous upper central incisor.

*When to refer:* Delayed eruption of upper central incisor, lack of space for eruption of upper central incisor.

*Possible orthodontic management:* Extraction of deciduous central incisor, creation of space using a removable/fixed appliance ± extractions, expose and bond UE central incisor and alignment using appliances, removal of central incisor of hopeless prognosis.

*Guidelines:* RCS Guidelines on management of unerupted maxillary incisors.<sup>4</sup>

### A case of unerupted upper central incisors

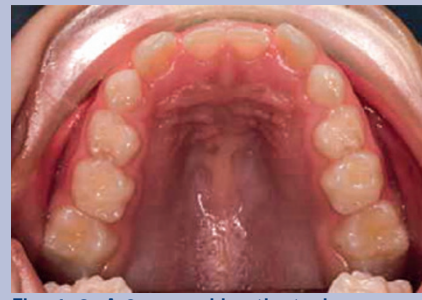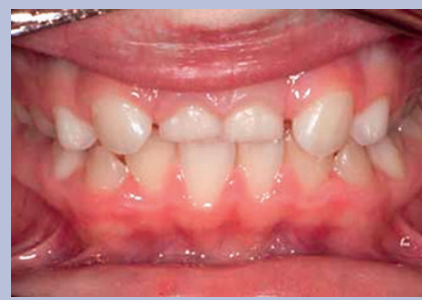FT was a fit, healthy 9-year-old patient who presented with the upper deciduous central incisors retained (Figs 1-2).

#### What should you ask?

- Is there a history of trauma to the front teeth? There was none
- When did the upper lateral incisors erupt? FT's mother reports these teeth erupted about 9 months previously
- Is there a family history of missing teeth? There was none and upper central incisors are rarely developmentally absent.

#### What should you look for?

- Mobility of the As – in this case the As were not mobile
- Palpation of the labial sulcus – no bulges could be palpate in the labial sulcus.



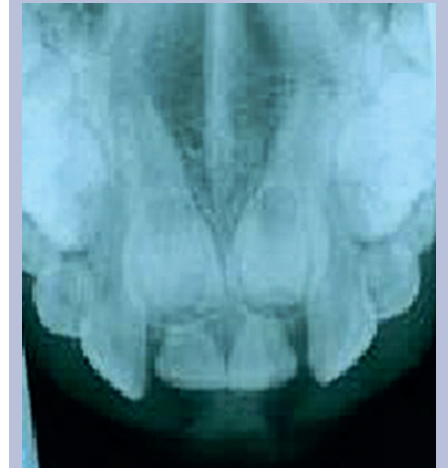
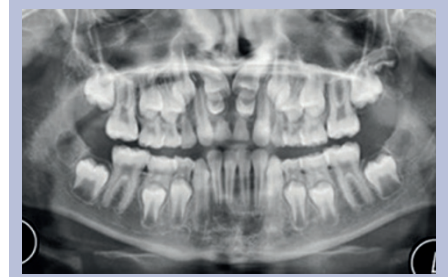
Figs 1-2 A 9-year-old patient who presented with the upper deciduous central incisors retained

#### What should you do now?

- Take an intra-oral radiograph of the upper labial segment
- Consider referral – in this case tuberculate supernumeraries are clearly visible on both the standard occlusal radiograph and dental panoramic tomography (DPT). Applying the parallax principle these views indicate that these supernumeraries are palatal. See Figures 3-4.

In the case FT was referred to surgical colleagues to have the upper As and the unerupted supernumeraries removed as well as bonding gold chain to the two unerupted permanent central incisors.

Patients often raise concerns about spaces between the teeth, especially the upper incisors during the mixed dentition phase. They should be advised that this is normal development and that when the maxillary canines erupt they will help to close the space. If the patient has a particularly large diastema after the canines have erupted or prominent fraenum they should be referred for an orthodontic opinion. A frenectomy may be considered in conjunction with the definitive orthodontic treatment if there is excessive soft tissue that is hindering adequate oral hygiene or space closure. If a supplemental tooth is present in the mixed dentition an orthodontic referral may be indicated before making an extraction decision. If the patient presents with a supernumerary tooth or mesiodens they may again be referred for an opinion before extraction. An orthodontist may be able to advise on an appropriate extraction to help guide dental development and also the timing of



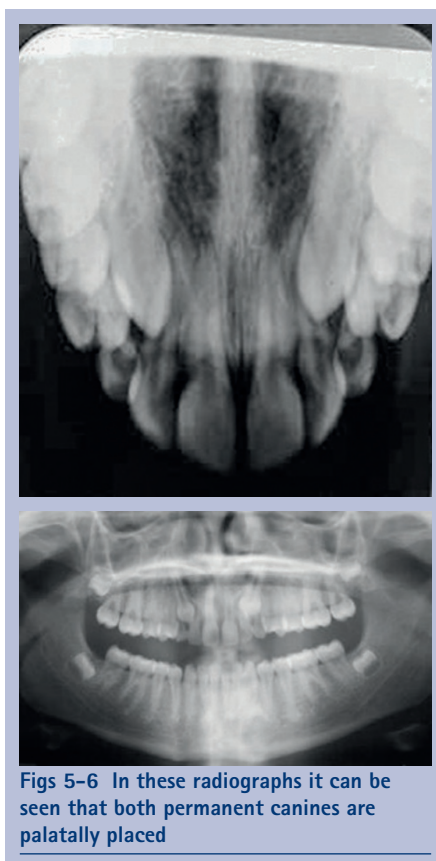Figs 3-4 Standard occlusal radiography and DPT with clearly visible tuberculate supernumeraries

any extraction, in particular, in relation to the root development of permanent incisors. An upper occlusal radiograph should be taken to check for any other associated anomalies in the region. Missing teeth can go unnoticed for some time. If a tooth has not erupted in the expected pattern a radiograph to confirm its presence, root form and location may be indicated. Although hypodontia may be diagnosed in the mixed dentition comprehensive treatment is often not undertaken until the patient is in the full permanent dentition. This said, an earlier referral for reassurance or the consideration of early loss of deciduous teeth to facilitate space closure may be appropriate.

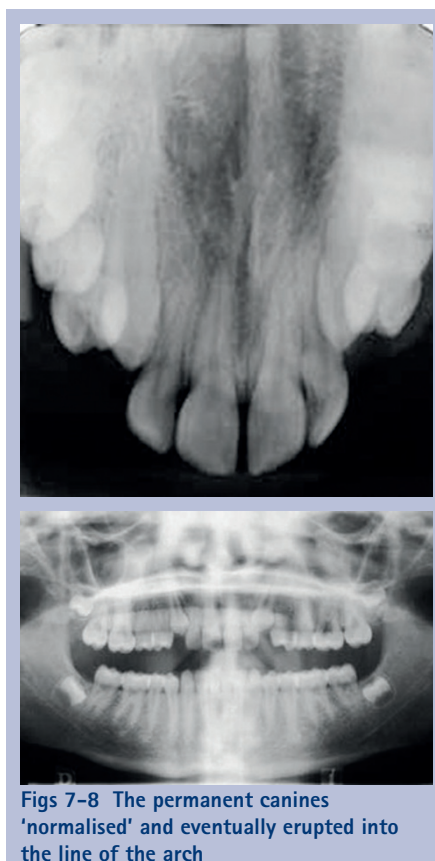Upper and lower second premolars can often develop in an ectopic position, especially in a crowded dentition. Early referral for an orthodontic opinion may be indicated in these cases as interceptive orthodontics may remove the need for or simplify any future orthodontic treatment. Canines are a particular example of the unerupted tooth. It is sometimes easy to mistake a deciduous tooth for its successor in these cases. It is useful to carefully examine the shape and colour of the tooth, deciduous canines are often whiter and more bulbous near the gingival margin.

### MANAGEMENT OF THE UNERUPTED MAXILLARY CANINE

*What should raise alarms:* If no mobility is evident in a remaining deciduous maxillary



**Figs 5-6** In these radiographs it can be seen that both permanent canines are palatally placed



**Figs 7-8** The permanent canines 'normalised' and eventually erupted into the line of the arch

canine if the contralateral permanent tooth has erupted. If at least six months has passed since the eruption of a maxillary canine and the contralateral tooth is unerupted. Canines are not palpable at the age of ten years. There is no mobility of the deciduous canine. If there are missing or microdont lateral incisors.

*When to refer:* Delayed eruption of maxillary canine, lack of space for eruption of maxillary canine, canines not palpable at the age of ten years. There is radiographic evidence of an ectopic canine or resorption of adjacent permanent teeth roots. Late referrals of impacted canines can result in longer and more complex treatment for the patient.

*Possible orthodontic management:* Extraction of deciduous canine, creation of space using a removable/fixed appliance ± extractions, expose and bond canine and alignment using appliances, removal of canine in very poor position.

*Guidelines:* RCS Guidelines on management of the palatally ectopic maxillary canine.<sup>5</sup>

### A case of unerupted maxillary canines

This patient was referred as they had retained deciduous canines.

#### What should you look for clinically?

- Bulges in the labial sulcus above the

deciduous canines or possibly more labial positioned indicating the position of the unerupted teeth

- Mobility of the deciduous canines – if mobile this usually indicates that the permanent canines are present
- Labially proclined or rotated upper lateral incisors – this can indicate that the permanent canines are labially placed.

#### What should you do now?

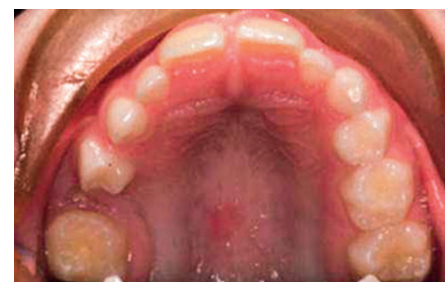- Take radiographs to establish the three 'P's' – *presence, position* and *pathology*
- Refer if unsure as to whether to remove the deciduous canines.

In this case (Figs 5-6), using the vertical parallax technique it can be seen that both permanent canines are palatally placed, the 23 more than the 13. The 23 appears slightly magnified on the DPT, a second indication that the tooth is palatal.

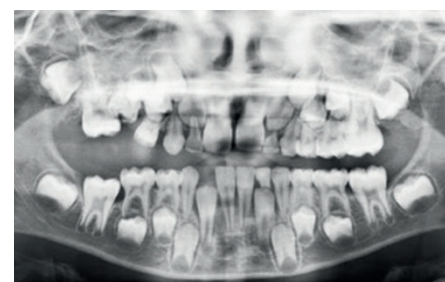
The extraction of the deciduous canines was all the treatment the patient underwent. The permanent canines 'normalised' and eventually erupted into the line of the arch (Figs 7-8).

### MANAGEMENT OF THE INFRAOCCLUDED DECIDUOUS MOLAR

The first sign of a missing or unerupted tooth maybe the infraocclusion of its deciduous counterpart, which is illustrated in the following case.



**Fig. 9** Eight-year-old patient who presented in the mixed dentition with a 'sinking tooth'



**Fig. 10** Take a radiograph to establish if 55 and the permanent successor is present

TR was a fit, healthy 8-year-old patient who presented in the mixed dentition with 'a sinking tooth' (Fig. 9).

#### What should you look for?

- Ask family of any history of previous tooth removal if patient new to practice
- Note on previous charting if 55 was previously present in mouth
- Ask if there had been any pain from upper right quadrant
- Probe distal to 54 to see if you can feel a tooth present
- Any tipping of adjacent teeth

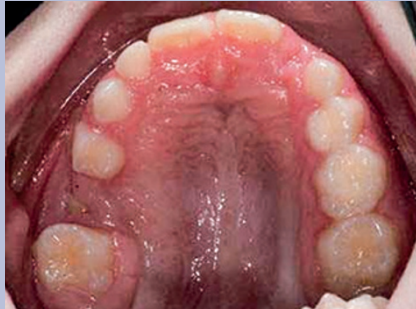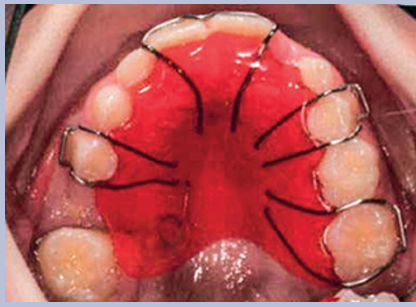
#### What should you do now?

- Take a radiograph to establish if 55 is present and to establish if the permanent successor is present (Fig. 10)
- This is an excellent time to consider a referral.

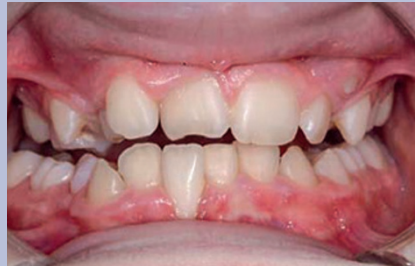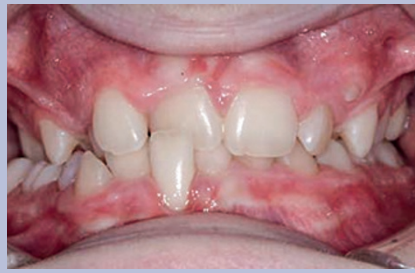In this case TR was fitted with an upper removable appliance to tip the 16 distally to allow surgical access to remove the 55 (Figs 11-12). This approach results in the loss of the 55 only as great space is given for surgical access. This active orthodontic treatment is quick, on average 4-6 months. The result is retained by placing a band and loop type of retainer which allows dental development to continue. If the patient had been referred at an earlier stage by their GDP then surgery could have been avoided.

### MANAGEMENT OF THE CROSSBITE

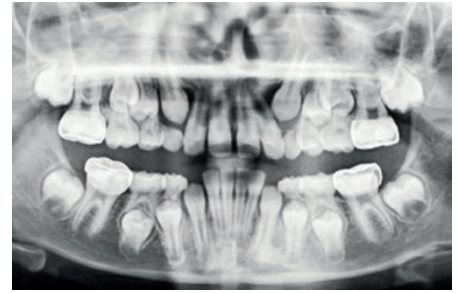
Cross bites may be anterior or posterior presenting with or without displacement and



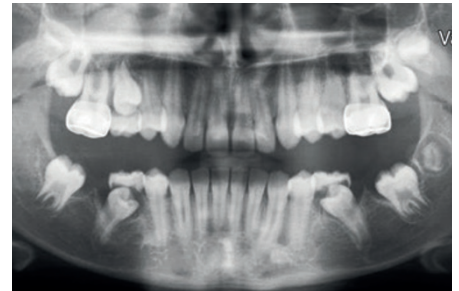
**Figs 11-12** In this case the patient with fitted with an upper removable appliance (51) to tip the 15 distally to allow surgical access to remove the 55



**Figs 13-14** Ten-year-old boy in the mixed dentition with crowding and an anterior crossbite



**Fig. 15** Ten-year-old patient with MIH, a Class 2 skeletal pattern, a 9 mm overjet and a bilateral full unit Class II molar relationship



**Fig. 16** A patient who had lower first permanent molars removed to encourage spontaneous space closure

can occur in the deciduous and permanent dentitions. This 10-year-old boy was fit and healthy (Figs 13-14). He was referred in the mixed dentition because he was crowded and had an anterior crossbite. On clinical examination he was found to have posterior crossbite. Patients rarely complain of these and, as such, can be missed. They can be associated with lateral displacements resulting in centreline discrepancies.

**What should you look for?**

- The patient should have no anterior or posterior crossbites. In this case the patient has both an anterior crossbite affecting the 11 and a posterior crossbite of the right first permanent molars
- Gingival recession on any displaced teeth – there was gingival recession on the 41
- Mobility of any teeth – the 41 was Grade 1 mobile
- Look for signs of incisal wear – it was also noted that there was significant incisal wear on the 11 as a result of the crossbite
- Ask the patient if they have any difficulties biting or chewing things.

**What should you do now?**

- Assess the patient to see if there is a displacement associated with the crossbite – an anterior and lateral (to the right) displacement was noted on closure. This is a good time to refer the patient.

**MANAGEMENT OF FIRST PERMANENT MOLARS WITH POOR PROGNOSIS**

Patients referred for orthodontic treatment should be motivated, have stopped any digit sucking habits and have excellent oral hygiene. However, orthodontists are often asked to see patients with neglected mouths and first molars of poor prognosis to provide an orthodontic opinion before extractions. If there are concerns that the patient may need orthodontic treatment in the future, despite their OH, they should be referred. A timely referral could obviate or minimise the need for future orthodontic treatment. Sometimes an orthodontist will see such a patient and ask for a tooth to be restored in order to maintain space or because there are missing teeth.

*Guidelines:* RCS guidelines for first permanent molar extraction in children.<sup>6</sup>

**Two cases of molars of poor prognosis**

LC was a fit, healthy 10-year-old patient who presented in the mixed dentition with molar-incisor hypomineralisation (MIH). The first molars have all been temporised with stainless steel crowns. LC presented with a Class 2 skeletal pattern, a 9 mm overjet and a bilateral full unit Class II molar relationship (Fig. 15).

**What should you look for?**

- Prognosis of the erupted teeth – this will influence the extractions planned
- Permanent teeth that can be seen developing on the DPT – this will influence the extractions planned
- Stage of development of the second

molars, in particular the lower second molar Amount of crowding present – should we maintain the first molars in order for them to act as short-term space maintainers?

- Molar relationship – important when considering compensating the extraction of first molars to stop overeruption of a retained tooth
- Incisor relationship – this will influence orthodontic treatment planning.

**What should you do now?**

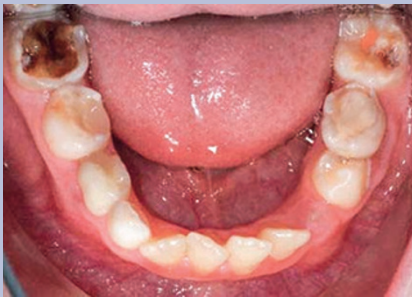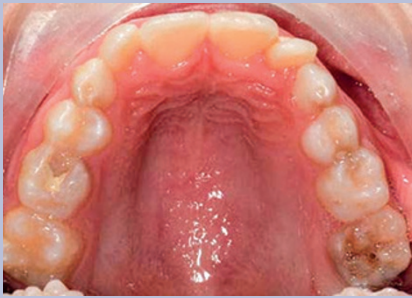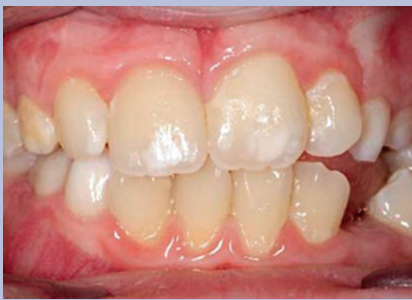- Refer for advice – the patient has a marked Class II malocclusion as well as 6's of poor prognosis.

In this case (Fig. 16) LC has lower first permanent molars removed to encourage spontaneous space closure. The upper first molars were retained in order that a functional appliance could be fitted with Adams clasps incorporated into the design.

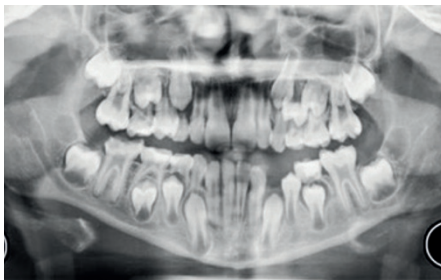JT was a fit healthy 9-year-old patient who presented in the mixed dentition with pain from the 46 (Figs 17-19). There are a number of carious teeth present, both deciduous and permanent, and the 73 has been lost early, almost certainly due to resorption by the 32 as it erupted. The patient had molar-incisor hypomineralisation but subsequent breakdown of the 26 and lower 6's.

**What should you look for?**

- Prognosis of the erupted teeth – this will influence the extractions planned (Fig. 20)



**Figs 17–19** A 9-year-old patient in the mixed dentition with pain from the 46



**Fig. 20** Prognosis of the erupted teeth

- Permanent teeth that can be seen developing on the DPT – this will influence the extractions planned. If for example a lower premolar was developmentally absent restoration of carious 6's may be considered
- Stage of development of the second molars, in particular the lower second molar – this, again, influences the timing of 6's extractions as we are often keen on encouraging spontaneous space closure as the 7's erupt
- Amount of crowding present – should we maintain and temporise the carious first molars in order for them to act as short-term space maintainers if the patient is very crowded?
- Molar relationship – important when

considering compensating the extraction of first molars to stop overeruption of the retained opposing tooth

- Centreline relationship – as the 73 has exfoliated early there has been a shift in the lower dental centreline to the left. Consideration of the loss of the 83 may allow spontaneous correction of the lower centreline.

#### What should you do now?

- This is an excellent time to consider a referral for consideration of loss of all 6's. All permanent teeth are present (possibly with the exception of the 28) and the bifurcation of the lower second molars is just beginning to form.

In this case JT had all first permanent molars removed at the same time as all deciduous molars and the 83. The 83 was taken to help the centreline correct.

#### MANAGEMENT OF INCREASED/ REVERSE OVERJETS

Increased overjets can be related to an increased risk of trauma.<sup>7</sup> Often it is necessary to wait for some time before treating the increased overjet as early treatment starts can prolong the overall treatment time. All patients in this group should be given advice on preventing dental trauma and advised to wear a mouth guard while involved in high risk activities. If the patient is experiencing bullying or psychological trauma due to their malocclusion an early referral and early treatment may be indicated. In these cases it is sometimes necessary to consider a second course of treatment following the eruption of all permanent teeth, but early intervention may offer positives psychological benefits and a reduction in trauma.<sup>8–10</sup> There is some evidence (Facemask study) that early treatment of reverse overjets can be successful although there appears to be little effect on the patient's self-esteem or the personal impact of the Class 3 relationship.<sup>11</sup>

As always all children should be assessed as individuals and, as such, early treatment may be considered by a family once the pros and cons have been outlined and discussed.

#### EARLY LOSS OF DECIDUOUS TEETH

A paper discussing interceptive orthodontics must briefly discuss the enforced early loss of deciduous teeth. These teeth are the normal space maintainers. In general early loss tends to redistribute existing crowding. If there is no crowding then early loss is not usually a problem unless you are considering the removal of an upper E.

Guidelines: RCS guidelines of the extraction of primary teeth.<sup>12</sup>

The potential problems include:

- Asymmetric loss – centreline shift
- Mesial migration of 6s
- Loss in upper arch only – shift of molar relationship.

The effect on the developing dentition depends on which tooth is lost and when:

- Incisor – little effect on occlusion
- Canine – possible effect on the dental centreline. Early asymmetric loss of a deciduous canine will have the most effect on the incisor region with a centreline shift towards the affected side. The most noticeable effect will occur if a maxillary and a mandibular deciduous canine are lost on opposite sides of the mouth. Why is a centreline shift a potential problem? In order for the teeth in the buccal segments to interdigitate fully, it is normally necessary for the centrelines to be coincident. If they are not then fixed appliances are needed to correct them and such treatment can be lengthy. A potentially simple case to treat may become complicated by unbalanced deciduous extractions
- Deciduous first molar – possible effect on both centreline and buccal segment. Early asymmetric loss of a deciduous first molar may have effects on the centreline and may allow mesial migration of the posterior teeth
- Deciduous second molar – possible mesial movement of buccal segments. Asymmetric loss of a lower deciduous second molar is likely to allow mesial movement of the 6's. Loss of an upper deciduous second molar will be followed by rapid space closure from behind even in relatively uncrowded arches. This will encourage a Class II molar relationship to develop.

#### What can we do?

- Balancing extraction – Removal of a second tooth in the same arch but on the opposite side in order to maintain the centreline and molar symmetry
- Compensating extraction – Removal of a tooth on the same side of the mouth but in the opposing arch in order to maintain molar relationship. It is usually advocated if an upper deciduous molar is lost. The worry is that the molars will move into a Class II relationship making treatment more difficult later. If a lower deciduous molar is removed to compensate the 6's should move forwards together. It is not common to compensate for lower extractions
- Space maintenance – this is usually advocated in cases where there will only

just be enough space to accommodate all the permanent teeth or where there is so much crowding that further space loss would require the loss of more than one unit in each quadrant. This can be difficult to assess so you could consider an orthodontic opinion before considering any extractions. The best space maintainer is the deciduous tooth. Orthodontic space maintainers will only be used in patients with good OH and diet.

## OTHER CONSIDERATIONS IN THE MIXED DENTITION

Space constraints curtail exhaustive coverage of all anomalies that the GDP should be aware of. The British Orthodontic Society publish a useful guide for dental practitioner on the management of the developing occlusion, which covers a broader spectrum of issues, including impacted first permanent molars.<sup>1</sup>

## PERMANENT DENTITION

A patient who presents in the permanent dentition in the surgery should be reviewed with 'an orthodontic eye'. This review should include an assessment of the following items:

- Assessment of oral hygiene
- Assessment of dental health
- Assessment of Index of Treatment Need (IOTN) (see pull out guide for reference).

Consider a referral of the patient if they are motivated or if treatment is indicated due to pathology, that is, root resorption of a lateral incisor as a result of an ectopic impacted canine. The patient should be made aware of why and to whom you are making the referral.

## THE PRACTICALITIES OF MAKING ANY REFERRAL

Provision of orthodontic care varies across the UK and may be in specialist practice, community dental settings or hospitals. Many orthodontic providers have guidelines for referral and some many also have

proformas on which referrals are made, you should check with your local providers so you can follow these guidelines. If no guidelines are available for referral then a good referral letter, as recommended by the BOS (guidelines for referrals for orthodontic treatment) include the following information:

- Patient demographics
- Reason for referral ie, treatment or advice
- Salient features of the patient's malocclusion
- History of previous treatment
- Original or high quality prints of recent radiographs where relevant.<sup>13</sup>

The importance of excellent dental health should not be underestimated. In an ideal world all patients referred for an orthodontic opinion should be well motivated, have excellent oral hygiene and a well-controlled diet. However, there are situations where this may not be the case and yet a referral should still be considered. For example, a patient with first permanent molars of poor prognosis may have less than ideal oral hygiene, but they should still be referred for an orthodontic opinion to provide advice on extraction patterns. A patient with impacted permanent maxillary canines and a class I occlusion may have very little motivation, but they should still be referred so they can be fully assessed and the options can be discussed with them. If the patient is not likely to be disadvantaged then delaying the referral and spending time helping them to improve their oral hygiene is invaluable. This may act to motivate the patient with the 'carrot' of being able to orthodontic treatment once their dental health improves. If a patient fails to improve their oral hygiene then the consequences of this and accepting their malocclusion should be discussed with the patient and their parents.

## SUMMARY

This article should have provided you with useful information to help you monitor and refer orthodontic patients appropriately so

we can offer the best possible care at the right time, while making careful use of the valuable resources we have.

We have tried to give you an overview of 'what to look out for' in the developing dentition. In the space allowed we cannot include an exhaustive list of all anomalies/faults in eruption and development. To help your in-surgery management we have included a handy quick reference guide to orthodontic assessment and referral. This can be found as a printed supplement with this issue of the Journal and also in the online supplementary information associated with this article.

1. British Orthodontic Society. *Managing the developing occlusion. A guide for dental practitioners.* London, 2010.
2. Ackerman J L, Proffit W R. Preventive and interceptive orthodontics: a strong theory proves weak in practice. *Angle Orthod* 1980; **50**: 75-87.
3. Isaacson K, Thom A, Horner K, Whaites E. *Guidelines for the use of radiographs in clinical orthodontics.* London: British Orthodontic Society, 2008.
4. Yaqoob O, O'Neill J, Gregg T, Noar J, Cobourne M, Morris D. *Management of unerupted maxillary incisors.* London: Royal College of Surgeons of England Guidelines, 2010.
5. Husain J, Burden D, McSherry P. *Management of the palatally ectopic maxillary canine.* London: Royal College of Surgeons of England Guidelines, 2010.
6. Cobourne M, Williams A, McMullan R. *A guideline for first permanent molar extraction in children.* London: Royal College of Surgeons of England Guidelines, 2009.
7. Nguyen Q, Bezemer P, Habets L, Pahl-Andersen B. A systematic review of the relationship between overjet size and traumatic dental injuries. *Eur J Orthod* 1999; **21**: 503-515.
8. Seehra J, Fleming P, Newton T, DiBiase A. Bullying in orthodontic patients and its relationship to malocclusion, self-esteem and oral health-related quality of life. *J Orthod* 2011; **38**: 247-256.
9. Seehra J, Newton T, DiBiase A. Intercepting orthodontic treatment in bullied adolescents and its impact on self-esteem and oral health-related quality of life. *Eur J Orthod* 2013; **35**: 615-621.
10. Thiruvengkatachari B, Harrison J E, Worthington H V, O'Brien K D. Orthodontic treatment for prominent upper front teeth (Class II malocclusion) in children. *Cochrane Database Syst Rev* 2013; CD003452.
11. Mandall N. A, Cousley R, DiBiase A *et al.* Is early Class III protraction facemask treatment effective? A multicentre, randomized, controlled trial: 3-year follow-up. *J Orthod* 2012; **39**: 176-185.
12. Royal College of Surgeons. *Extraction of primary teeth - balance and compensation.* 2006.
13. FGDP(UK). *Selection criteria for dental radiography,* 3rd ed. 2013.