



Remote and non-invasive quantification of ‘Tattoo Skin Disease-Like’ dermatopathy in endangered Arabian Sea humpback whales using drone photography

Matthew S. Leslie^{1,2} · Louis Kant³ · Colin Perkins-Taylor⁴ · Marie-Françoise Van Bressem⁵ · Gianna Minton⁶ · Darryl MacDonald⁷ · Fredrik Christiansen⁸ · Maia Sarrouf Willson⁹ · Tim Collins¹⁰ · Robert Baldwin¹¹ · Suaad Al Harthi⁹ · Andrew Willson¹²

Received: 17 April 2022 / Accepted: 21 November 2022 / Published online: 13 January 2023
© The Author(s) under exclusive licence to Deutsche Gesellschaft für Säugetierkunde 2023

Abstract

Arabian Sea humpback whales (*Megaptera novaeangliae*; ASHW) are listed as Endangered by the International Union for the Conservation of Nature (IUCN). The long-term presence and increased prevalence of tattoo skin disease-like (TSD-L) dermatopathy is a concern for this small non-migratory population. Characterized by irregular or rounded, light gray or whitish cutaneous lesions, this condition resembles tattoo skin disease, caused by cetacean poxviruses. Although the etiological agent and pathogenicity of TSD-L dermatopathy are unknown, previous studies have suggested that it is an indicator of population health. Until now, disease diagnosis had been based on photographs collected from survey vessels. In this study, we describe a novel method of identifying and quantifying TSD-L lesions in ASHW, using drone aerial photography. Aerial photos of the entire dorsum were selected for 18 whales with the same criteria applied for assessing body condition to quantify the percent coverage for each individual. We effectively diagnosed this condition from close-up aerial photos or good-quality photos of the lateral body surface taken from the research vessel in 13 whales. TSD-L dermatopathy coverage ranged from 2.34 to 57.00% and measurements were consistent between photographs of the same whale ($SD = 1.86\%$). Drone aerial photography provided a useful and complimentary approach to identify and quantify TSD-L lesions. Continued monitoring using this non-invasive method should be combined with other population and health monitoring tools to increase our understanding of the characteristics and epidemiology of this condition, and to provide critical information for conservation efforts that ensure the recovery of this endangered population.

Keywords Arabian Sea · Cetacean · Disease monitoring · Endangered species · Gulf of Masirah, Oman · Health assessment · *Megaptera novaeangliae* · Unmanned aerial vehicle (UAV/Drone)

Introduction

Arabian Sea humpback whales (*Megaptera novaeangliae*, ASHW) are a non-migratory population that feed and breed in the Arabian Sea, in the Northern Indian Ocean. They are genetically distinct and believed to have diverged from an ancestral southern hemisphere migratory population approximately 70,000 years BP (Pomilla et al. 2014). They are designated as “Endangered” on the IUCN Red List (Minton et al. 2008) due to their low abundance (82 animals estimated for the subregion off the coast of Oman, 95% CI: 60–111), isolation from other neighboring populations, and mounting threats in their range (Minton et al. 2008, 2011). The population was significantly depleted by Soviet whaling operations, which illegally harvested 242 ASHW from

Handling editors: Leszek Karczmarski and Stephen C.Y. Chan.

This article is a contribution to the special issue on “Individual Identification and Photographic Techniques in Mammalian Ecological and Behavioural Research – Part 2: Field Studies and Applications” — Editors: Leszek Karczmarski, Stephen C.Y. Chan, Scott Y.S. Chui and Elissa Z. Cameron.

✉ Matthew S. Leslie
matt.s.leslie@gmail.com

Extended author information available on the last page of the article

this region in the 1960s (Mikhalev 1997). Compared to the scale of global industrial whaling activities that killed approximately three million whales (Rocha et al. 2015), a catch of 242 whales seems relatively small. However, the scientists on board the Soviet whaling vessels estimated that they took ~60% of the ASHW present in the Arabian Sea, and that the low catch from this non-migratory population likely indicates ASHW had naturally low abundance prior to whaling (Mikhalev 1997). ASHW have a significantly lower genetic diversity compared to other southern hemisphere humpback whale populations, a pattern consistent with ancient and recent genetic bottlenecks (Pomilla et al. 2014). Pomilla et al. (2014) also noted genetic isolation from other southern hemisphere humpback whale populations, indicating a lack of migration and genetic exchange. Low genetic diversity can negatively impact population viability for several reasons, including increased susceptibility to disease (Lacy 1997). Due to their low abundance and rising anthropogenic threats, such as ship strikes and entanglement in fishing gear (Baldwin et al. 2010; Willson et al. 2014; Minton et al. 2022), ASHW are at a much higher risk of extinction than other humpback whale populations (Stevick et al. 2003; Bejder et al. 2016; Bettridge et al. 2015). Part of the ASHW home range overlaps with the busy Arabian Sea marine corridor (Baldwin et al. 2010; IWC 2019; Johnson et al. 2022; Minton et al. 2022). Given their low abundance, the loss of any breeding adult is likely to reduce population viability even further (Minton et al. 2022; Wade 1998). Therefore, understanding and minimizing threats to individual whale health in this population are essential for their long-term survival.

Worldwide, several odontocete and mysticete populations are affected by tattoo skin disease (TSD), an illness caused by cetacean poxviruses and characterized by irregular whitish, light gray, or black stippled skin lesions with a contrasting outline (Geraci et al. 1979; Van Bresseem and Van Waerebeek 1996; Bracht et al. 2006; Van Bresseem et al. 2009; Blacklaws et al. 2013; Fiorito et al. 2015). Tattoo skin disease-like (TSD-L) dermatopathy, a condition similar to TSD but of unknown etiology, has been observed in ASHW since 2000 (Fig. 1; Van Bresseem et al. 2015). The lesions were observed on most body parts, but especially on the back, flanks, head, and peduncle. Their size varied between small and very large, while their coverage fluctuated between less than 10% to over 50% of the visible body surface (VBS). The dermatopathy persisted for several years in 10 whales, with the proportion of the affected VBS increasing over time in six of them (Minton et al. 2022). Besides, prevalence of TSD-L dermatopathy in 29 whales significantly rose from 27.6% in the period 2000–2011 to 51.7% in the period 2012–2018 (Minton et al. 2022). In this context, evaluating the impact of this disease on the long-term health of this endangered population of humpback

whales is a crucial element of assessing the population's conservation status and viability.

Qualitative and quantitative remote health assessments methods have proven to be effective in evaluating general health and body condition in free-ranging cetaceans (Pettis et al. 2004; Van Bresseem et al. 2014; Marón et al. 2015; Christiansen et al. 2020b; see also several examples profiled in Karczmarski et al. 2022) and have been identified as an important key ecological attribute for tracking the status of ASHW (Convention on Migratory Species 2017). An initial health assessment of ASHW based on existing photographic data of the lateral body surface taken from research vessels was recently conducted (Minton et al. 2022), and preliminary data collection has begun for an ASHW monitoring program aimed at regular evaluation of individual and population-wide body condition, anthropogenic scarring, and disease (Van Bresseem et al. 2015; Willson et al. 2018; Christiansen et al. 2020a).

The use of unoccupied aerial vehicles (UAV; i.e., drones) is fast advancing the study of cetacean biology (e.g., Durban et al. 2016; Dawson et al. 2017; Leslie et al. 2020; Sprogis et al. 2020; Azizeh et al. 2021; Currie et al. 2021; Ramos et al. 2022). Drones have been used to identify individuals (Hartman et al. 2020; Ramos et al. 2021), to assess cetacean body condition (Christiansen et al. 2016, 2018, 2020b, 2021; Durban et al. 2021; Johnston et al. 2022), to sample their microbiome or hormones (Apprill et al. 2017; Atkinson et al. 2021), and to remotely measure cetacean physiological parameters (Horton et al. 2019; Martins et al. 2020; Lonati et al. 2022). To date, however, only a few drone studies have examined disease in cetaceans (Christiansen et al. 2020b, 2021). In the current paper, we present a novel method and preliminary findings for non-invasively identifying, quantifying, and monitoring TSD-L prevalence and severity in ASHW using drone imagery.

Materials and methods

Small (<5 kg) multi-rotor drones were used to collect aerial images of ASHW in the Gulf of Masirah, Oman (Fig. 2), during two field surveys: 16–30 November 2017 and 25–26 November 2019. These field surveys focused on multiple objectives: photo identification, genetic biopsy collection, satellite tagging, and health assessment. Drones were hand-launched from small research vessels (~6 m) and flown by certified pilots with appropriate permission from Omani authorities. In 2017, we used an APH-22 hexacopter (Aerial Imaging Solutions; described in detail by Goebel et al. 2015) to capture photographs of surfacing ASHW from an altitude of approximately 30–50 m, following the procedures described by Durban et al. (2016) and Willson et al. (2018). In 2019, we captured video footage of whales

Fig. 1 Examples of three ASHW exhibiting tattoo skin disease-like (TSD-L) lesions characterized by irregular rounded, light gray marks with a contrasting outline (red arrows). Images for each whale were taken on the same day. **A** Three images of a high-coverage whale (OM17-008), including of the dorsolateral surface (lower left) collected from boat-based operations, very low-altitude (~2 m) drone image (upper left) showing TSD-L lesions (red arrows) and intraspecific or anthropogenic scarring (yellow arrows), and a standard-altitude image on the right (distinct TSD-L lesion shown with red arrow). **B** Two images of a low-coverage whale (OM15-006), including the dorsolateral body surface (above) with TSD-L lesions (red arrow), and a standard-altitude image of the dorsal surface (below) with the same lesion shown with a red arrow. **C** (displayed on the next page) Images of OM01-013 the dorsolateral body surface (above; taken from the research vessel) and the aerial image of the dorsum taken from the drone (below). This individual's TSD-L diagnosis was inconclusive from the boat-based images but determined to be TSD-L positive from the drone images



Fig. 1 (continued)

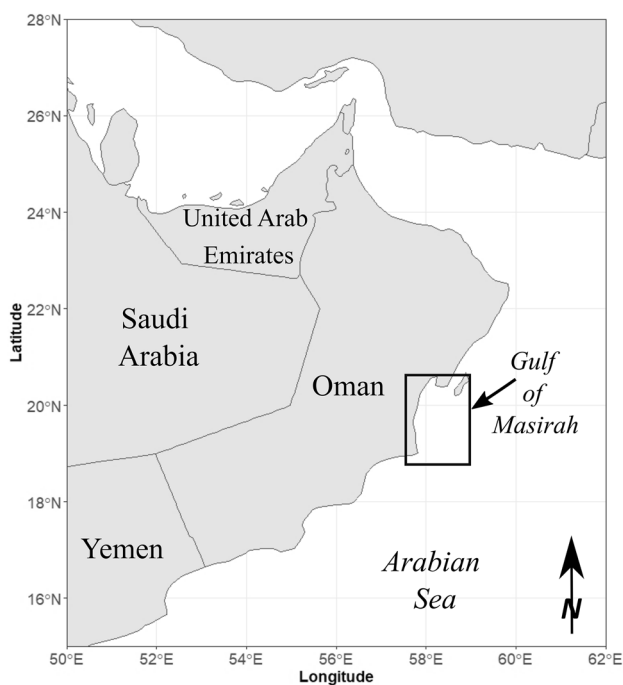


Fig. 2 Map of the survey area in the Gulf of Masirah of the Arabian Sea off the coast of Oman

from an altitude of 20–60 m using a modified DJI Inspire 1 Pro quadcopter (www.dji.com) as described by Christiansen et al. (2018). Still images were captured from the video for downstream processing. The main purpose of these higher-altitude flights (> 20 m) was to measure body condition using aerial photogrammetry (Christiansen et al. 2016, 2018). During 2017, the APH-22 was also flown at very low altitudes (2–4 m) to gather respiratory exhalent samples for microbiome analysis (Apprill et al. 2017), and close-range UAV images were collected opportunistically during these lower-altitude flights (Fig. 1B) but were not used for systematic quantification of body condition or TSD-L. Altitude of flights varied according to the study/survey purpose; variation in altitude of higher flights (20–60 m) was to obtain total body images of whales. Higher altitudes were required to capture full-body images of larger whales or groups containing more than one whale, while lower altitudes allowed the capture of entire body images for smaller or single whales.

Images of the lateral surface of the whale dorsal fin were obtained for photo identification with DSLR cameras using 100–300 mm variable zoom lenses (Fig. 1A). These photographs were assigned a quality score that considered angle, glare, focus, and resolution following Friday et al. (2008) and Urian et al. (2015). Scores ranged from 0 (no photo obtained) to 4 (excellent photo at the perfect angle

Table 1 Comparing vessel and drone-based images for the diagnosis of TSD-L lesions and coverage evaluation. The 18 ASHW photographed using UAV in 2017 and 2019 with associated diagnosis (boat-based images, drone images, and final diagnosis) and coverage estimates. Diagnoses were made by examining images collected using a DSLR with telephoto lens during small boat operations ("Boat-based diagnoses") and using the images collected by the UAV ("UAV-based diagnosis"). "T –" means a TSD-L condition not

present, "T +" means TSD-L dermatopathy present, and "inconclusive" could not be determined. Quality scores of boat-based image(s) included 3 (good), 2 (regular), and 1 (poor). A "Final diagnosis" was made based on all available photographic evidence. For images collected from the boat, the % coverage of TSD-L covering one side of the flank and dorsal fin was assessed by eye. For UAV images, the % coverage of the dorsal surface was calculated (Average \pm Standard Deviation if multiple images were available)

Whale ID	Year	Boat-based diagnosis	Quality of boat-based image(s)	UAV-based diagnosis	Final diagnosis	% coverage (boat)	% coverage (UAV)
OM01-001	2019	T+	3	T+	T+	30	32.64
OM01-004	2019	inconclusive	3	T+	T+	–	4.66
OM01-013	2019	T–	3	T+	T+	–	3.02 \pm 2.63
OM01-017	2019	T–	3	T–	T–	–	–
OM02-001	2019	inconclusive	3	T–	T–	–	–
OM02-019	2019	T+	3	T+	T+	30–40	32.68
OM04-008	2017	T–	2	T–	T–	–	–
OM11-011	2017	T+	3	T+	T+	70	54.69 \pm 0.59
OM11-012	2017	T+	3	T+	T+	5	4.24 \pm 0.20
OM14-023	2019	T+	3	T+	T+	15	24.24
OM15-006	2019	T+	3	T+	T+	1	2.34
OM16-001	2019	T–	3	T–	T–	–	–
OM17-005	2017	T+	3	T+	T+	20	16.84 \pm 2.61
OM17-007	2017	T+	3	T+	T+	10–20	15.25 \pm 3.26
OM17-008	2017	T+	3	T+	T+	80–90	57.00
OM17-010	2019	T+	3	T+	T+	1	10.72
OM17-012	2017	Inconclusive	1	Inconclusive	Inconclusive	–	–
OM19-001	2019	T+	3	T+	T+	5	23.19

and lighting, showing all details in high resolution). These images, in combination with those of tail flukes were used for individual identification and matching against the Oman Humpback Whale Photo-Identification Catalog (Environment Society of Oman 2022, <http://www.eso.org.om/>).

TSD-L was diagnosed using vessel-based and UAV images with the final diagnosis made by a cetacean skin disease expert (MFB), using all available imagery (Table 1). Percent coverage was also estimated using vessel-based images of the dorsolateral surface and compared to UAV quantification (Table 1). All of the boat-based images that were taken of whales observed in 2017 were examined for TSD-L, while only the best-quality pre-selected dorsal fin photos used for photo identification were examined for those whales photographed in 2019 (Table 1). TSD-L was visually identified through the presence of distinctive small to very large, white to light gray, irregular, or rounded skin lesions with a contrasting outline (Fig. 1). The field protocol of collecting photographic data and the workflow of quantifying TSD-L lesions from aerial images is summarized in Fig. 3.

Percent coverage was assessed by eye using vessel-based images of the dorsolateral surface and compared to UAV quantification (Table 1). Lateral photos of the flank and dorsal fin do not always show the same proportion of the flank,

making standardized quantification challenging (see Minton et al. 2022 for detailed analysis of TSD-L dermatopathy from boat-based images). Aerial images present a much more standardized proportion of the dorsal body surface area, making them better for quantification. Only high-quality aerial images that met our robust photo selection criteria were used for analysis of percent TSD-L lesion coverage (Fig. 4). The selection criteria were the same as those used in quantifying body condition (Christiansen et al. 2018) or for remote morphometrics (Leslie et al. 2020): images including the entire dorsal surface of the whale in a straight-backed (non-arched) position and the outline of the body and tail (excluding the pectoral fins) were discernible from the surrounding water. These images provided the clearest view of the whale's dorsal surface, favoring the detection of TSD-L areas. If surface water disturbance, turbid water, blowhole discharge, and/or high sun glare obscured the dorsal surface of the whale, the photo was excluded.

To determine the percent coverage of TSD-L lesions on each whale, images were imported into Adobe Photoshop (Adobe 2019) for analysis (Fig. 5A). Each photograph was converted into a layer, and a new blank layer was created. No attempts were made to correct for the curvature of the dorsal surface of the whale, therefore we will refer to this

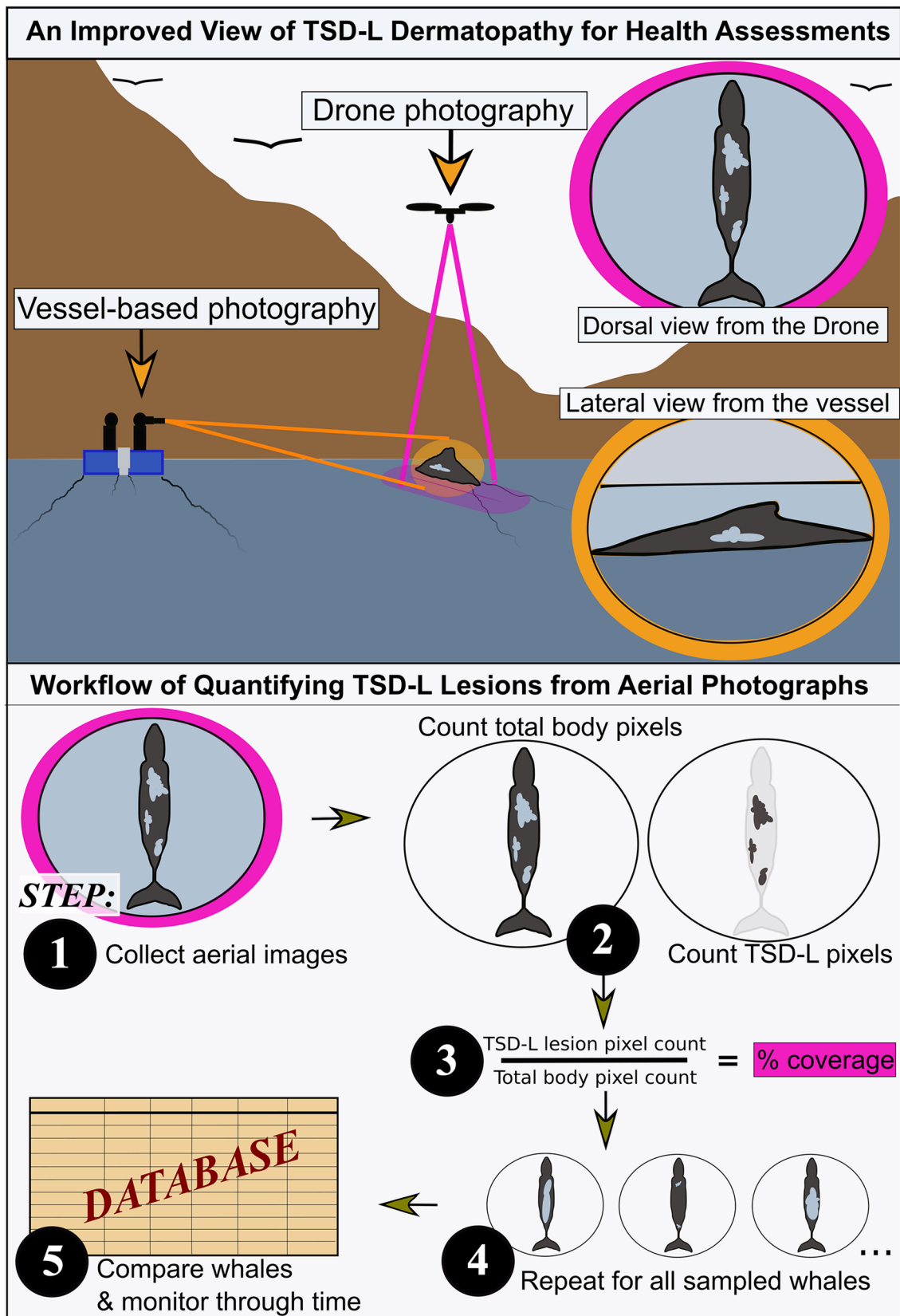
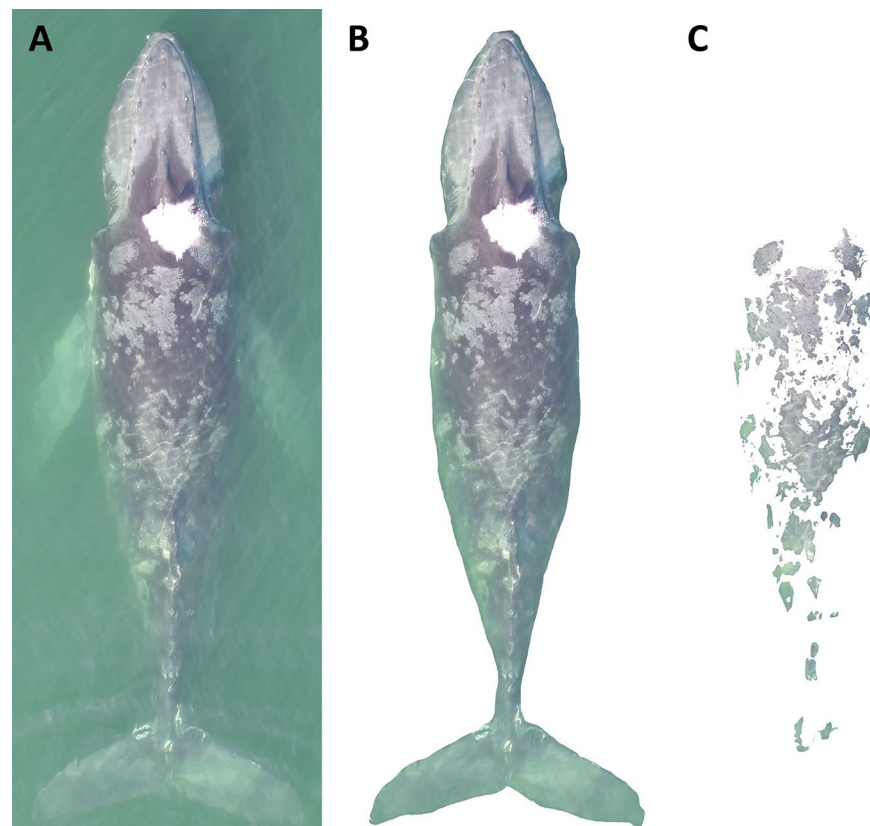


Fig. 3 An infographic displaying the complimentary views of vessel-based and drone-based photography for large whale health assessments, and a general workflow of TSD-L dermatopathy quantification from aerial photos

Fig. 4 An example of aerial images used in quantifying tattoo skin disease-like (TSD-L) dermatopathy. The upper image (A), an aerial photo of OM02-019, met our robust photo selection criteria and was included in the subsequent analyses. The lower image (B), an aerial photo of OM14-023, did not meet our photo selection criteria



Fig. 5 Quantifying the percent of tattoo skin disease-like (TSD-L) dermatopathy covering the dorsal surface of an Arabian Sea humpback whale (OM19-001) using aerial images from drones. **A** The raw image was imported into Adobe Photoshop (Adobe Inc. 2019). **B** The visible dorsal visual index of the whale was cropped to obtain a pixel count of the total dorsal surface. **C** The pixel count of the TSD-L condition affected areas was obtained by selecting the distinct gray and whitish circular skin lesions (i.e., "tattoos") on the dorsal surface and cropping out all other areas. The TSD-L lesion percent coverage was calculated by dividing the value from C by the value from B. For this individual, the % coverage was 23.19%



approximation of the dorsal surface area as a “dorsal visual index”. The outline of the entire whale excluding the pectoral fins was selected using the lasso tool (Fig. 5B), and the pixel count was recorded using the histogram window. This pixel count was considered the total dorsal visual index of the whale. We then removed areas that did not show TSD-L marks using a combination of the lasso, magic wand, and quick selection tools (Fig. 5C). The total pixel count of this area was recorded and considered to be the area of the whale affected by TSD-L dermatopathy. By dividing the pixel count of the affected area by the total dorsal visual index pixel count, we estimated the percentage of the dorsal surface of the whale that was covered by the skin lesions. Each photo was treated the same, regardless of the altitude of collection. All data analyses were performed in R version 4.1.2 and the data were plotted in R using the “ggplot2” (R Core Team 2021) and “musculusColors” packages (“Bmpoop” color palette; available at <https://github.com/dawnbarlow/musculusColors>).

Results

A total of 18 unique whales were photographed by drone in 2017 ($n=7$) and 2019 ($n=11$) and compared to known individuals in the Oman Humpback Whale Photo-Identification Catalog (Environment Society of Oman 2022, <http://www.eso.org.om/>). There were no whales re-sighted between the two years. In total, 27 high-quality images that met all the aerial image photo selection criteria were analyzed for TSD-L dermatopathy percent coverage. The minimum altitude was set by the distance needed to fit the entire whale in the frame. Higher altitudes were used to capture images of several whales simultaneously. However, we saw resolution decrease with altitude (up to 60 m), limiting our ability to diagnose TSD-L dermatopathy using only these images. In these cases, a definite diagnosis was obtained after examining other photographs (low altitude or boat-based). Because images were divided by the total pixel count, our measure of percent coverage was comparable across whales, regardless of the altitude. TSD-L lesions tend to be fainter toward the edges of the animal due to distal surfaces (lower flanks, tail flukes, etc.) dipping deeper into the water. The average number of drone photographs used to quantify the percent coverage of TSD-L on each whale was 1.5, although the number of photos assessed per whale ranged from 1 to 3 ($n_1=11$, $n_{2-3}=7$).

Boat-based images of all these whales were evaluated in parallel. Sixteen of the 18 individuals were represented by at least one good-quality boat-based photograph of at least one lateral surface of the dorsal fin (scoring at least 3 out of a maximum possible 4 points on a quality scale). One individual was represented by a fair-quality boat-based photo only (2 of 4 possible points), and one (OM17-012)

was represented only by one very poor-quality boat-based photo of the lateral surface of the dorsal fin (scoring 1 out of 4 points).

Thirteen of the 18 whales (72%) exhibited TSD-L lesions (Table 1). We could not confidently diagnose the presence or absence of TSD-L in whale OM17-012 using either drone or boat-based images, because of a combination of poor boat images and a low number of possible lesions visible in all boat and drone images. Except for one case, diagnoses based on boat-based and drone images were highly comparable (Table 1). In 2019, one whale (OM01-013) was considered negative based on photographs of the right and left flanks taken from the boat, while typical TSD-L lesions were discernable on an UAV image of the dorsal surface of this animal (Table 1). In two other cases from the 2019 dataset, the presence or absence of TSD-L lesions was only conclusive on drone images of OM01-004 (T+) and OM02-001 (T−). For OM01-004, the lesions were on an anterior body region that was not photographed from the boat. For OM02-001, the boat images of the left side of the body were poor while boat-based images of the right side and peduncle were negative. The limited number of boat-based images examined for 2019 likely reduced our ability to conclusively diagnose TSD-L condition from this source. The percent coverage of TSD-L lesions assessed by vessel images was generally comparable to the quantified drone images (Table 1). It varied greatly between whales, ranging from 2.34 to 57.00% on the UAV images (Table 1; Figs. 1 and 6), a result consistent

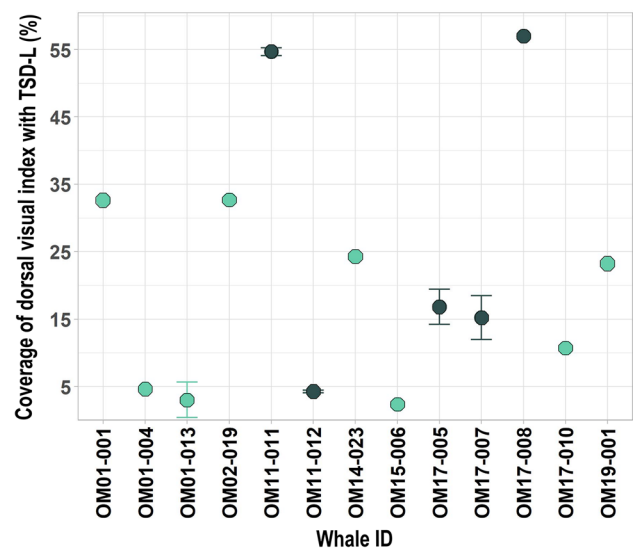


Fig. 6 Percentage of the total dorsal visual index covered by tattoo skin disease-like (TSD-L) dermatopathy for 13 unique Arabian Sea humpback whales (ASHW) photographed by drone in 2017 and 2019. Dark green colored points represent the five whales photographed in 2017 while blue-green dots represent the eight whales photographed in 2019. No ASHW were observed in both years. Error bars represent the standard deviation of TSD-L lesions percent coverage for five whales that were measured in multiple images

with estimates from the boat-based images (Table 1). The average percent TSD-L coverage across all 13 whales was 21.65% and varied between 29.60% in 2017 and 16.68% in 2019. Multiple drone images were successfully collected for five whales (OM01-013, OM11-011, OM11-012, OM17-005, OM17-007) during a single or several sightings during the same season. The average standard deviation of TSD-L percent coverage across these five whales was 1.86% and ranged from 0.20 to 3.26%.

Discussion

The presence or absence of TSD-L on the dorsal cutaneous surface of ASHW could be diagnosed in all but one of the 18 whales studied in 2017 and 2019 using drone images. Results were inconclusive only in whale OM17-012 using both drone and boat images. Prevalence of the disease was 72% of the 18 whales photographed with this method (Table 1). Overall, there was very high agreement between boat-based and drone assessments. Disagreement between these sources only occurred for one whale (OM01-013), whose flanks were negative on three boat-based photographs but had recognizable TSD-L lesions on its dorsum on drone footage. The high prevalence of TSD-L dermatopathy lies in agreement with the significant prevalence increase observed during the past decade (Minton et al. 2022). By causing stress and weakening the whale immune system, increasing levels of maritime traffic in the Arabian Sea, and a high rate of severe entanglements with fishing gear may contribute to the rise of documented cases of TSD-L dermatopathy in this population (Minton et al. 2022). Our results suggest that both drones and boat-based photography should continue to be used to monitor TSD-L prevalence in ASHW.

The qualitative comparison of images collected from the boat and drones (Table 1) is presented instead of a more quantitative analysis for two reasons. First, Minton et al. (2022) present a complete analysis of the boat-based images using the most appropriate method for photos of the dorsal fin/flank taken from the vessel. Second, lateral photos, such as those taken from a research vessel, do not always show the same proportion of the flank. Additional challenges to standardizing boat-based images for a pixel-based analysis include contending with differences in body position (flat, arched, tilted, etc.) and the angle between the boat and the whale at the time of image capture. Aerial imagery controls for many of these issues and provides a more standardized proportion of the body, rendering them more suitable for the pixel proportion analysis presented in this paper.

Our inability to diagnose TSD-L dermatopathy for some whales using aerial images was most common in images that contained multiple whales. Capturing multiple whales in a single frame required a larger field of view which

necessitated a higher operating altitude. This resulted in lower resolution and lower ability to confidently diagnose the condition in some whales. We recommend that researchers focus on capturing full-body images of one whale at a time to maintain resolution. This will aid in diagnosis and offer a more standard resolution for quantification. UAV sensors are rapidly improving and the ability to collect high resolution images from greater distances may be possible in future. Low-altitude photos (Fig. 1B) can also be collected in conjunction with other drone operations, including the collection of blowhole exhalent samples for microbiome or hormone analyses (Atkinson et al. 2021), to help with diagnosis. Absolute altitude will vary based on the body size of the individual being imaged. For instance, the entire surface of a calf or smaller cetacean species could be photographed from lower altitudes.

Another related consideration for future studies is whether it is necessary to correct for misestimation of lesion size because of the aerial perspective to a curved dorsal surface. Even though we are photographing whales in their flattest posture, lesions on the body margins (extreme distal area of the flanks) are going to appear smaller in area because they are on more vertical surfaces. Similarly, affected areas nearer to the dorsal fin will be underestimated because they are more vertical in orientation. In contrast, when taking lateral photos from a boat the opposite will occur; images will underestimate the area of lesions located on the dorsal side of the whale, while more accurately capturing the size of lesions on the flanks. This is another reason why comparing images collected from different platforms can be challenging and the two perspectives are complimentary but not directly comparable.

Based on our analysis, UAV images collected in favorable visual conditions (relatively calm sea surface with low seawater turbidity) can offer a consistent means of quantifying TSD-L coverage on the dorsal surfaces of ASHW. Furthermore, this method can be used to compare differences in TSD-L coverage between whales and track the progression of the disease for individuals through time. For instance, we found that TSD-L coverage ranged from 2.34 to 57% of the whales' dorsal surfaces (Fig. 6), a finding that is consistent with previous studies using boat-based imagery (Van Bresssem et al. 2015; Minton et al. 2022). While these results show the wide range in TSD-L coverage across individuals, the coverage average standard deviation for the five whales measured in multiple aerial photos was low (average of 1.86%; range 0.20–3.26%), demonstrating the accuracy and consistency of this method to quantify skin diseases. Using images of 10 ASHW individuals re-sighted multiple times between 2000 and 2017, Minton et al. (2022) observed that TSD-L lesion coverage increased over time in six whales but remained the same in the four other animals, indicating that this skin condition is chronic. Future UAV-based studies

could evaluate the duration and rate of change of this cutaneous condition.

Using UAV photography to study TSD-L dermatopathy in ASHW has some benefits over traditional boat-based photography, with the main advantage being the possibility to collect images of the entire dorsal surface. If combined with accurate-altitude data corresponding to each photo, the whale dorsal visual index can be quantified using photogrammetry, thus allowing for measurement of the spatial extent of TSD-L lesions (area in m²) in addition to the percent coverage as we present here. In contrast, though essential for the disease diagnosis, boat-based images from DSLR cameras only capture smaller and less standardized portions of the dorsolateral surface (see Fig. 1). Furthermore, UAVs may be more effective in approaching and following whales that avoid boats and are not easily accessible for high-quality dorsolateral photos.

While this novel application of drone-based photography is particularly well suited to studying the progression of TSD-L in ASHW, it could be used to detect other skin conditions in cetaceans and to monitor abnormal behavior and stranding events during illness outbreaks or unusual mortality events (Smith et al. 2009; Jepson et al. 2013; Morris et al. 2015; Flach et al. 2019). Cetacean cutaneous conditions that could be monitored using drone imagery include wounds, ‘lobomycosis-like disease’ and ‘freshwater skin disease’ (Marón et al. 2015; Ramos et al. 2018; Duignan et al. 2020). Future studies should include collecting skin samples to determine the etiology of TSD-L dermatopathy through histological and molecular analysis (Geraci et al. 1979; Luciani et al. 2022) and to further investigate the link between the disease prevalence and severity and the intensity of anthropogenic factors, such as entanglements, water pollution, maritime traffic and ship strikes. Additional work could also include the use of drones to collect radiometric thermal data to test if areas of active TSD-L lesions present heat loss compared to normal skin (Lonati et al. 2022).

Conclusions

Together with boat-based photo surveys, aerial visual assessments by drone photography represent an effective method for non-invasively monitoring the prevalence, severity and persistence of TSD-L dermatopathy in the Endangered ASHW population. Drone surveys allow the research vessel to remain at a safe distance from the focal whale to minimize impact on whale behavior and avoid additional stress. Employing this approach together with studies to evaluate body condition increases the utility of aerial images from drones and further addresses the requirement of generating key ecological attribute data for this at-risk population as

detailed in Convention for Migratory Species (2017) Plans for Concerted Action.

Supplementary Information The online version contains supplementary material available at <https://doi.org/10.1007/s42991-022-00337-0>.

Acknowledgements We are thankful for the support of the Sultanate of Oman, especially the Oman Civil Aviation Authority and National Survey Authority for authorization for drone operations and the Environment Authority for the general survey permit. We are grateful for support and guidance provided by the Scientific Committee of the International Whaling Commission. We also thank Don LeRoi and Drs. Michael Moore, Amy Apprill and Caroline Miller for their support with field equipment and supplies. We extend special thanks to those who helped with field surveys including Tilen Genov, Simon Childerhouse, Alec Burslem and Joonas Kinni. We also thank two anonymous reviewers for their valuable comments that helped improving this manuscript. Finally, we thank both editors, Leszek Karczmarski and Stephen C.Y. Chan for their thoughtful and thorough editorship, and for accommodating this manuscript in the thematic Special Issue despite a late submission and tight timeline.

Author contributions MSL was responsible for the conceptualizing, conducting, and supervising the research. MSL and LK designed the methodology. MSL, DM, and FC collected the data. LK, CP-T, and ML analyzed the data and prepared the original draft of the manuscript. MVB and GM analyzed boat-based photos and provided valuable contributions to the manuscript. AW, RB, SAH, MSW and TC coordinated and led field research operations. AW, RB, TC, MSL, and GM secured funding for field research. All the authors gave the final approval for publication.

Data availability The datasets generated and analysed during the current study are available from the corresponding author on reasonable request.

Code availability The code supporting the current study is available from the corresponding author on request.

References

- Adobe Inc (2019) Adobe Photoshop. Berkeley, CA, Peachpit Press. <https://www.adobe.com/products/photoshop.html>
- Apprill A, Miller CA, Moore MJ, Durban JW, Fearnbach H, Barrett-Lennard LG (2017) Extensive core microbiome in drone-captured whale blow supports a framework for health monitoring. *Msystems* 2(5):e00119–e217. <https://doi.org/10.1128/mSystems.00119-17>
- Atkinson S, Rogan A, Baker CS, Dagdag R, Redlinger M, Polinski J, Urban J, Sremba A, Branson M, Mashburn K, Pallin L, Klink A, Steel D, Bortz E, Kerr I (2021) Genetic, endocrine, and microbiological assessments of blue, humpback and killer whale health using unoccupied aerial systems. *Wildl Soc Bull* 45:654–669. <https://doi.org/10.1002/wsb.1240>
- Azizeh TR, Sprogis KR, Soley R, Nielsen MLK, Uhart MM, Sironi M, Rowntree V, Marón CF, Bejder L, Madsen PT, Christiansen F (2021) Acute and chronic behavioral effects of kelp gull micropredation on southern right whales. *Mar Ecol Prog Ser* 668:133–148. <https://doi.org/10.3354/meps13716>
- Baldwin RM, Collins T, Minton G, Findlay K, Corkeron P, Willson A, Van Bresse M (2010) Arabian Sea humpback whales: Canaries for the Northern Indian Ocean? Report to the Scientific Committee of the International Whaling Commission. SC/62/SH20.

- (unpublished), p 5. [Paper available from the International Whaling Commission]
- Bejder M, Johnston DW, Smith J, Friedlaender A, Bejder L (2016) Embracing conservation success of recovering humpback whale populations: evaluating the case for downlisting their conservation status in Australia. *Mar Policy* 66:137–141. <https://doi.org/10.1016/j.marpol.2015.05.007>
- Bettridge S, Baker CS, Barlow J, Clapham PJ, Ford M, Gouveia D, Mattila DK, Pace RM, Rosel PE, Silber GK, Wade PR (2015) Status review of the humpback whale (*Megaptera novaeangliae*) under the Endangered Species Act. NOAA Technical Memorandum NMFS-SWFSC 540. <https://repository.library.noaa.gov/view/noaa/4883>
- Blacklaws BA, Gajda AM, Tippelt S, Jepson PD, Deaville R, Van Bresse MF, Pearce GP (2013) Molecular characterization of poxviruses associated with tattoo skin lesions in UK cetaceans. *PLoS ONE* 8:e71734. <https://doi.org/10.1371/journal.pone.0071734>
- Bracht AJ, Brudek RL, Ewing RY, Manire CA, Burek KA, Rosa C, Beckmen KB, Maruniak JE, Romero CH (2006) Genetic identification of novel poxviruses of cetaceans and pinnipeds. *Arch Virol* 151:423–438. <https://doi.org/10.1007/s00705-005-0679-6>
- Christiansen F, Dujon AM, Sprogis KR, Arnould JPY, Bejder L (2016a) Noninvasive unmanned aerial vehicle provides estimates of the energetic cost of reproduction in humpback whales. *Ecosphere* 7(10):e01468. <https://doi.org/10.1002/ecs2.1468>
- Christiansen F, Vivier F, Charlton C, Ward R, Amerson A, Burnell S, Bejder L (2018) Maternal body size and condition determine calf growth rates in southern right whales. *Mar Ecol Prog Ser* 592:267–282. <https://doi.org/10.3354/meps12522>
- Christiansen F, Baldwin RL, Minton G, Collins T, Sprogis KR, Rudd J, Harthi SA, Leslie MS, Macdonald D, Willson A (2020a) Assessing the body condition of the world's only non-migratory humpback whale population, the endangered Arabian Sea humpback whale. Document Presented to the Scientific Committee of the International Whaling Commission. IWC/SC68B/CMP23Rev1. (unpublished), p 12. [Paper available from the International Whaling Commission]
- Christiansen F, Dawson SM, Durban JW, Fearnbach H, Miller CA, Bejder L, Uhart M, Sironi M, Corkeron P, Rayment W, Leunissen E, Haria E, Ward R, Warick HA, Kerr I, Lynn MS, Pettis HM, Moore MJ (2020b) Population comparison of right whale body condition reveals poor state of the North Atlantic right whale. *Mar Ecol Prog Ser* 640:1–16. <https://doi.org/10.3354/meps13299>
- Christiansen F, Rodríguez-González F, Martínez-Aguilar S, Urbán J, Swartz S, Warick H, Vivier F, Bejder L (2021) Poor body condition associated with an unusual mortality event in gray whales. *Mar Ecol Prog Ser* 658:237–252. <https://doi.org/10.3354/meps13585>
- Convention on Migratory Species (2017) Concerted action for humpback whales (*Megaptera novaengliae*) of the Arabian Sea. Adopted by the Conference of the Parties at its 12th Meeting (Manila, Philippines). https://www.cms.int/sites/default/files/document/cms_cop12_ca.12.4_humpback-whales-arabian-sea_e.pdf
- Currie JJ, van Aswegen M, Stack SH, West KL, Vivier F, Bejder L (2021) Rapid weight loss in free ranging pygmy killer whales (*Feresa attenuata*) and the implications for anthropogenic disturbance of odontocetes. *Sci Rep* 11(1):1–12. <https://doi.org/10.1038/s41598-021-87514-2>
- Dawson SM, Bowman MH, Leunissen E, Sirguey P (2017) Inexpensive aerial photogrammetry for studies of whales and large marine animals. *Front Mar Sci* 4:366. <https://doi.org/10.3389/fmars.2017.00366>
- Duignan PJ, Stephens NS, Robb K (2020) Fresh water skin disease in dolphins: a case definition based on pathology and environmental factors in Australia. *Sci Rep* 10:21979. <https://doi.org/10.1038/s41598-020-78858-2>
- Durban JW, Moore MJ, Chiang G, Hickmott LS, Bocconcelli A, Howes G, Bahamonde PA, Perryman WL, LeRoi DJ (2016) Photogrammetry of blue whales with an unmanned hexacopter. *Mar Mamm Sci* 32(4):1510–1515. <https://doi.org/10.1111/mms.12328>
- Durban JW, Fearnbach H, Paredes A, Hickmott LS, LeRoi DJ (2021) Size and body condition of sympatric killer whale ecotypes around the Antarctic Peninsula. *Mar Ecol Prog Ser* 677:209–217. <https://doi.org/10.3354/meps13866>
- Fiorito C, Palacios C, Golemba M, Bratanich A, Argüelles MB, Fazio A, Bertelotti M, Lombardo D (2015) Identification, molecular and phylogenetic analysis of poxvirus in skin lesions of southern right whale. *Dis Aquat Org* 116:157–163. <https://doi.org/10.3354/dao02918>
- Flach L, Alonso MB, Marinho T, Van Waerebeek K, Van Bresse MF (2019) Clinical signs in free-ranging Guiana dolphins (*Sotalia guianensis*) during a morbillivirus epidemic: case study in Sepetiba Bay. *Brazil Dis Aquat Org* 133(3):175–180. <https://doi.org/10.3354/dao03343>
- Friday NA, Smith TD, Stevick PT, Allen J, Fernald T (2008) Balancing bias and precision in capture-recapture estimates of abundance. *Mar Mamm Sci* 24(2):253–275. <https://doi.org/10.1111/j.1748-7692.2008.00187.x>
- Geraci JR, Hicks BD, St Aubin DJ (1979) Dolphin pox: a skin disease of cetaceans. *Can J Comp Med* 43(4):399–404
- Goebel ME, Perryman WL, Hinke JT, Krause DJ, Hann NA, Gardner S, LeRoi DJ (2015) A small unmanned aerial system for estimating abundance and size of Antarctic predators. *Polar Biol* 38(5):619–630. <https://doi.org/10.1007/s00300-014-1625-4>
- Hartman K, Van der Harst P, Vilela R (2020) Continuous focal group follows operated by a drone enable analysis of the relation between sociality and position in a group of male Risso's dolphins (*Grampus griseus*). *Front Mar Sci* 7:283. <https://doi.org/10.3389/fmars.2020.00283>
- Horton TW, Hauser N, Cassel S, Klaus KF, Fettermann T, Key N (2019) Doctor Drone: non-invasive measurement of humpback whale vital signs using unoccupied aerial system infrared thermography. *Front Mar Sci* 6:466. <https://doi.org/10.3389/fmars.2019.00466>
- International Whaling Commission (2019) Report of the IWC workshop on bycatch mitigation opportunities in the Western Indian Ocean and Arabian Sea, 8–9 May 2019, Nairobi, Kenya. Report for IWC Conservation Committee. [Available at: <https://archive.iwc.int/?r=9612>]
- Jepson PD, Deaville R, Acevedo-Whitehouse K, Barnett J, Brownlow A, Brownell RL Jr, Clare FC, Davison N, Law RJ, Loveridge J, Macgregor SK (2013) What caused the UK's largest common dolphin (*Delphinus delphis*) mass stranding event? *PLoS ONE* 8(4):e60953. <https://doi.org/10.1371/journal.pone.0060953>
- Johnson C, Reisinger R, Palacios D, Friedlaender A, Zerbini A, Willson A, Lancaster M, Battle J, Graham A, Cosandey-Godin A, Jacob T, Felix F, Grilly E, Shahid U, Houtman N, Alberini A, Montecinos Y, Najera E, Kelez S (2022) Protecting Blue Corridors - Challenges and solutions for migratory whales navigating international and national seas. WWF, Oregon State University, University of California, Santa Cruz, Publisher: WWF International, Switzerland. [Available at <https://zenodo.org/record/6196131#.YxiuznbMLIU> Downloaded on 5 May 2022]
- Johnston DR, Rayment W, Dawson SM (2022) Morphometrics and body condition of southern right whales on the calving grounds at Port Ross, Auckland Islands. *Mamm Biol (Special Issue)* 102(4). <https://doi.org/10.1007/s42991-021-00175-6>
- Karczmarski L, Chan SCY, Chui SYS, Cameron EZ (2022) Individual identification and photographic techniques in mammalian ecological and behavioural research – Part 2: Field studies and

- applications. *Mamm Biol (Special Issue)* 102(4). <https://link.springer.com/journal/42991/volumes-and-issues/102-4>
- Lacy RC (1997) Importance of genetic variation to the viability of mammalian populations. *J Mammal* 78:320–335. <https://doi.org/10.2307/1382885>
- Leslie MS, Perkins-Taylor CM, Durban JW, Moore MJ, Miller CA, Chanarat P, Bahamonde P, Chiang G, Apprill A (2020) Body size data collected non-invasively from drone images indicate a morphologically distinct Chilean blue whale (*Balaenoptera musculus*) taxon. *Endanger Species Res* 43:291–304. <https://doi.org/10.3354/esr01066>
- Lonati GL, Zitterbart DP, Miller CA, Corkeron P, Murphy CT, Moore MJ (2022) Investigating the thermal physiology of critically endangered North Atlantic right whales *Eubalaena glacialis* via aerial infrared thermography. *Endanger Species Res* 48:139–154. <https://doi.org/10.3354/esr01193>
- Luciani L, Piorkowsky G, de Lamballerie X, Van Waerebeek K, Van BresseM M-F (2022) Detection of cetacean poxvirus in Peruvian common bottlenose dolphins (*Tursiops truncatus*) using a Pan-Poxvirus PCR. *Viruses* 14:1850. <https://doi.org/10.3390/v1409185>
- Marón CF, Beltramino L, Di Martino M, Chirife A, Seger J, Uhart M, Sironi M, Rowntree VJ (2015) Increased wounding of southern right whale (*Eubalaena australis*) calves by kelp gulls (*Larus dominicanus*) at Península Valdés, Argentina. *PLoS ONE* 10(10):e0139291. <https://doi.org/10.1371/journal.pone.0139291>
- Martins MCI, Miller C, Hamilton P, Robbins J, Zitterbart DP, Moore M (2020) Respiration cycle duration and seawater flux through open blowholes of humpback (*Megaptera novaeangliae*) and North Atlantic right (*Eubalaena glacialis*) whales. *Mar Mamm Sci* 36(4):1160–1179. <https://doi.org/10.1111/mms.12703>
- Mikhalev YA (1997) Humpback whales *Megaptera novaeangliae* in the Arabian Sea. *Mar Ecol Prog Ser* 149:13–21. <https://doi.org/10.3354/meps149013>
- Minton G, Collins T, Pomilla C, Findlay K, Rosenbaum H, Baldwin R, Brownell Jr. RL (2008) *Megaptera novaeangliae* (Arabian Sea sub-population). eT132835A3464679. IUCN Red List of Threatened Species. <https://doi.org/10.2305/IUCN.UK.2008.RLTS.T132835A3464679.en>. Downloaded on 5 July 2022]
- Minton G, Collins T, Findlay K, Ersts P, Rosenbaum H, Berggren P, Baldwin R (2011) Seasonal distribution, abundance, habitat use and population identity of humpback whales in Oman. *J Cetacean Res Manag* 3(Special Issue):185–198. <https://doi.org/10.47536/jcrm.vi3.329>
- Minton G, Van BresseM MF, Willson A, Collins T, Al Harthi S, Sarrouf Willson M, Baldwin R, Leslie M, Van Waerebeek K (2022) Visual health assessment and evaluation of anthropogenic threats to Arabian Sea humpback whales in Oman. *J Cetacean Res Manag*. <https://doi.org/10.47536/jcrm.v23i1.336>
- Morris SE, Zelner JL, Fauquier DA, Rowles TK, Rosel PE, Gulland F, Grenfell BT (2015) Partially observed epidemics in wildlife hosts: modelling an outbreak of dolphin morbillivirus in the northwestern Atlantic, June 2013–2014. *J R Soc Interface* 12:20150676. <https://doi.org/10.1098/rsif.2015.0676>
- Pettis HM, Rolland RM, Hamilton PK, Brault S, Knowlton AR, Kraus SD (2004) Visual health assessment of North Atlantic right whales (*Eubalaena glacialis*) using photographs. *Can J Zool* 82(1):8–19. <https://doi.org/10.1139/z03-207>
- Pomilla C, Amaral AR, Collins T, Minton G, Findlay K, Leslie MS, Ponnampalam L, Baldwin R, Rosenbaum H (2014) The world's most isolated and distinct whale population? Humpback whales of the Arabian Sea. *PLoS ONE* 9(12):e114162. <https://doi.org/10.1371/journal.pone.0114162>
- R Core Team (2021) R: A language and environment for statistical computing. R Foundation for Statistical Computing, Vienna, Austria. <http://www.r-project.org/>
- Ramos EA, Castelblanco-Martínez DN, García J, Arias JR, Foley JR, Audley K, Van Waerebeek K, Van BresseM MF (2018) Lobo-mycosis-like disease in common bottlenose dolphins *Tursiops truncatus* from Belize and Mexico: bridging the gap between the Americas. *Dis Aquat Org* 128(1):1–12. <https://doi.org/10.3354/dao03206>
- Ramos EA, Kiszka JJ, Pouey-Santalou V, Ramirez Barragan R, Garcia Chavez AJ, Audley K (2021) Food sharing in rough-toothed dolphins off southwestern Mexico. *Mar Mamm Sci* 37:352–360. <https://doi.org/10.1111/mms.12727>
- Ramos EA, Santoya L, Verde J, Walker Z, Castelblanco-Martínez N, Kiszka JJ, Rieucan G (2022) Lords of the Rings: Mud ring feeding by bottlenose dolphins in a Caribbean estuary revealed from sea, air, and space. *Mar Mamm Sci* 38(1):364–373. <https://doi.org/10.1111/mms.12854>
- Rocha RC, Clapham PJ, Ivaschenko YI (2015) Emptying the oceans: a summary of industrial whaling catches in the 20th century. *Mar Fish Rev* 76(4):37–48
- Smith KF, Acevedo-Whitehouse K, Pedersen AB (2009) The role of infectious diseases in biological conservation. *Anim Conserv* 12(1):1–12. <https://doi.org/10.1111/j.1469-1795.2008.00228.x>
- Sprogis KR, Videsen S, Madsen PT (2020) Vessel noise levels drive behavioural responses of humpback whales with implications for whale-watching. *Elife* 9:e56760. <https://doi.org/10.7554/eLife.56760>
- Stevick PT, Allen J, Clapham PJ, Friday N, Katona SK, Larsen F, Lien J, Mattila DK, Palsbøll PJ, Sigurjónsson J, Smith TD, Øien N, Hammond PS (2003) North Atlantic humpback whale abundance and rate of increase four decades after protection from whaling. *Mar Ecol Prog Ser* 258:263–273. <https://doi.org/10.3354/meps258263>
- Urian K, Gorgone A, Read A, Balmer B, Wells RS, Berggren P, Durban J, Eguchi T, Rayment W, Hammond PS (2015) Recommendations for photo-identification methods used in capture-recapture models with cetaceans. *Mar Mamm Sci* 31(1):298–321. <https://doi.org/10.1111/mms.12141>
- Van BresseM MF, Van Waerebeek K (1996) Epidemiology of poxvirus in small cetaceans from the eastern south pacific. *Mar Mamm Sci* 12:371–382. <https://doi.org/10.1111/j.1748-7692.1996.tb00590.x>
- Van BresseM MF, Van Waerebeek K, Aznar FJ, Raga JA, Jepson PD, Duignan P, Deaville R, Flach L, Viddi F, Baker JR, Paula Di Benedetto A, Echeagaray M, Genov T, Reyes J, Felix F, Gaspar R, Ramos R, Peddemors V, Sanino GP, Siebert U (2009) Epidemiological pattern of tattoo skin disease: a potential general health indicator for cetaceans. *Dis Aquat Org* 85(3):225–237. <https://doi.org/10.3354/dao02080>
- Van BresseM MF, Duignan P, Banyard A, Barbieri M, Colegrove K, De Guise S, Di Guardo G, Dobson A, Domingo M, Fauquier D, Fernandez A, Goldstein T, Grenfell B, Groch K, Gulland F, Jensen B, Jepson P, Hall A, Kuiken T, Mazzariol S, Morris SE, Nielsen O, Raga JA, Rowles TK, Saliki J, Sierra E, Stephens N, Stone B, Tomo I, Wang J, Waltzek T, Wellehan JF (2014) Cetacean morbillivirus: current knowledge and future directions. *Viruses* 6(12):5145–5181. <https://doi.org/10.3390/v6125145>
- Van BresseM MF, Minton G, Collins T, Willson A, Baldwin R, Van Waerebeek K (2015) Tattoo-like skin disease in the endangered subpopulation of the Humpback Whale, *Megaptera novaeangliae*, in Oman (Cetacea: Balaenopteridae). *Zool Middle East* 61(1):1–8. <https://doi.org/10.1080/09397140.2014.994316>
- Wade PR (1998) Calculating limits to the allowable human-caused mortality of cetaceans and pinnipeds. *Mar Mamm Sci* 14(1):1–37. <https://doi.org/10.1111/j.1748-7692.1998.tb00688.x>
- Willson A, Collins T, Baldwin R, Cerchio S, Geyer Y, Godley B, Gray H, Al-Harthi S, Minton G, Al-Zehlawi N, Witt M, Rosenbaum HC, Zerbini A (2014) Preliminary results and first insights from satellite tracking studies of male Arabian Sea humpback whales.


Document Presented to the Scientific Committee of the International Whaling Commission. IWC/SC/65b/SH19. Bled, Slovenia. (unpublished), p 12. [Paper available from the International Whaling Commission]

Willson A, Baldwin R, Cerchio S, Childerhouse S, Collins T, Findlay K, Genov T, Godley BJ, Al Harthi S, Leslie M, MacDonald D, Minton G, Zerbin AN, Witt MJ (2018) Update on satellite telemetry studies and first unoccupied aerial vehicle assisted health assessment studies of Arabian Sea humpback whales off the coast of Oman. Document Presented to the Scientific Committee of the International Whaling Commission. IWC/SC67B/CMP13Rev1. Bled, Slovenia. (unpublished), p 11. [Paper available from the International Whaling Commission]

Publisher's Note Springer Nature remains neutral with regard to jurisdictional claims in published maps and institutional affiliations.

Springer Nature or its licensor (e.g. a society or other partner) holds exclusive rights to this article under a publishing agreement with the author(s) or other rightsholder(s); author self-archiving of the accepted manuscript version of this article is solely governed by the terms of such publishing agreement and applicable law.

Authors and Affiliations

Matthew S. Leslie^{1,2}  · Louis Kant³ · Colin Perkins-Taylor⁴ · Marie-Françoise Van Bresse⁵ · Gianna Minton⁶ · Darryl MacDonald⁷ · Fredrik Christiansen⁸ · Maia Sarrouf Willson⁹ · Tim Collins¹⁰ · Robert Baldwin¹¹ · Suaad Al Harthi⁹ · Andrew Willson¹²

¹ Oak Ridge Institute for Science and Education, Oak Ridge, TN, USA

² Environmental Studies Department, Ursinus College, Collegeville, PA, USA

³ Biology Department, Swarthmore College, Swarthmore, PA, USA

⁴ Biology Department, College of Charleston, Charleston, SC, USA

⁵ Cetacean Conservation Medicine Group, Peruvian Centre for Cetacean Research, Lima, Peru

⁶ Megaptera Marine Conservation, The Hague, The Netherlands

⁷ Clear Blue Photo, Calgary, AB, Canada

⁸ Zoophysiology, Department of Biology, Aarhus University, Aarhus C, Denmark

⁹ Environment Society of Oman, Muscat, Oman

¹⁰ Ocean Giants Program, Wildlife Conservation Society, Bronx, NY, USA

¹¹ Five Oceans Environmental Services LLC, Muscat, Oman

¹² Future Seas Global SPC, Muscat, Oman