



# Anomalies of tooth eruption

Jane Ann Soxman<sup>1</sup> · Patrice Barsamian Wunsch<sup>2</sup>

Received: 10 May 2019 / Accepted: 21 May 2019 / Published online: 6 June 2019  
© Springer Nature Switzerland AG 2019

## Abstract

Anomalies of tooth eruption occur due to a variety of reasons. A thorough understanding of the growth and development of the child is crucial for the management of the eruptive anomalies of teeth. The outcome of the treatment of these anomalies depends on the proper diagnosis and timing of the intervention.

**Keywords** Anomaly · Eruption · Ectopic · Mixed dentition · Primary dentition · Malocclusion

## Quick reference/description

Anomalies of tooth eruption occur due to a variety of reasons. A thorough understanding of the growth and development of the child is crucial for the management of the eruptive anomalies of teeth. The outcome of the treatment of these anomalies depends on the proper diagnosis and timing of the intervention.

---

✉ Jane Ann Soxman

Patrice Barsamian Wunsch  
pbwunsch@vcu.edu

<sup>1</sup> Allison Park, USA

<sup>2</sup> Department of Pediatric Dentistry, Virginia Commonwealth University, Richmond, USA

## Overview

Treatment approaches for eruptive anomalies	Indications	Contraindications
<b>Natal/neonatal teeth</b>		
Smoothing off or covering the incisal edge	Natal/neonatal teeth that pose an irritation risk	<i>For smoothing</i> difficulty in gaining cooperation of the patient to safely remove sharp edges with sand paper disc mouted in a rotary hand piece <i>For restoration</i> difficulty in isolation and bonding due to hypoplastic enamel surface
Extraction of natal/neonatal teeth	Extremely loose natal/neonatal teeth	Extraction is contraindicated in neonates less than 10 days old
<b>Ankylosis/deep submersion of primary molars</b>		
Observation and monitoring	For primary molars till 6–12 months after the expected time of exfoliation	Retention of the primary molar for more than 6–12 months after the expected time of exfoliation
Extraction and space maintenance	To permit eruption of the succedaneous tooth without allowing the adjacent tooth to occupy the space For future implant placement, if succedaneous tooth is absent	Certain space maintainers are contraindicated in the lower arch prior to the eruption of the permanent mandibular incisors
Extraction and orthodontic space closure	Arch alignment in case of crowding and absence of the succedaneous tooth	
Restorative treatment	Maintenance of occlusion Prevent tipping of adjacent teeth and supraeruption of opposing teeth	Primary molars with resorbed roots and crowns compromised with caries or structural defects
<b>Ectopic eruption of maxillary first permanent molars</b>		
Placement of separating spring, brass ligature wire or orthodontic elastic separator	De-impaction of the first permanent molar	Patients with severely compromised immunity Severe resorption of the maxillary second primary molar when extraction and space maintenance would be indicated Abscessed second primary molar
Interproximal enamel reduction of the distal surface of second primary molar	De-impaction of the first permanent molar	Uncooperative young child
Active appliance therapy	De-impaction of the first permanent molar	If de-impaction of the molar can be achieved with other minimally invasive interventions

Treatment approaches for eruptive anomalies	Indications	Contraindications
Extraction of second primary molar and space maintenance	If the second primary molar is symptomatic, mobile and diseased with an abscess or has advanced root resorption Maintenance of space for maxillary second premolar	If the second primary molar is sound and asymptomatic
Ectopic eruption and impaction of maxillary permanent canines		
Use of cervical headgear	Increase or maintenance of space in the maxillary arch Improvement of intraosseous canine position	Class I or Class III molar relationship
Rapid palatal expansion	Alleviation of anterior crowding that can improve the eruption path of the canine	No posterior crossbite
Extraction of primary canines and primary first molars	Extraction of first primary molar can stimulate eruption of first premolar and guide the eruption path of the permanent canine Primary canine obstructing the path of permanent canine Palatally displaced permanent canines	First primary molars cannot be extracted if the root of the first premolar is not adequately formed
Surgical exposure of palatally impacted ectopic maxillary canines and orthodontic correction	Correction of palatally impacted ectopic maxillary canines	Horizontal position of the impacted canine above the apices of adjacent teeth and in close proximity of the midline
Dental transposition		
Orthodontic correction	Proper positioning of the transposed teeth	If orthodontic repositioning would result in loss of alveolar bone
Reshaping after eruption	For appropriate esthetics and function of the teeth	Minor additional restorative or prosthodontic treatment would be required
Extraction with orthodontic space closure	Arch alignment and improved function	

## Materials/instruments

- Sandpaper disk
- Composite resin
- Stainless steel crowns
- Space maintainers
- Separating spring
- Brass ligature wire
- Howe plier
- Orthodontic elastic separator

- Ballista loops
- Gold chain
- Chain elastic
- Waxed dental floss
- 169 L carbide bur
- Dental wedge
- Halterman appliance
- Ectopic spring loaded distalizer
- Cervical headgear
- Orthodontic brackets

## Procedure

Eruptive anomalies of teeth are caused by numerous factors. Various theories are used to describe the etiology of the abnormal eruption. However, no precise etiology has been identified. An essential factor in the management of anomalies of tooth eruption is a detailed understanding of the growth and development of the child. A correct timing of the interceptive treatment is critical for the success of the management. The various eruptive anomalies and their treatment modalities are as follows:

### Natal/neonatal teeth

The primary teeth that erupt early being present at birth or erupting within the first 30 days of life of a neonate are known as natal and neonatal teeth, respectively. The natal/neonatal teeth pose an irritation risk and can be treated by

#### Smoothing off or covering the incisal edge

The incisal edge of natal/neonatal teeth can be smoothed with a sandpaper disk. The incisal edge can also be covered with a composite resin for achieving a smooth surface.

#### Extraction of natal/neonatal teeth

Extraction is the treatment of choice for extremely loose natal/neonatal teeth. Extraction should not be performed before the child is 10 days old as vitamin-K that is necessary for thrombin production and clot formation requires 10 days for its production. Careful curettage of the socket under local anesthesia for removal of the residual dental papilla. This is essential as the internal dental papilla can continue to develop.

**Table 1** Classification of ankylosis/submergence

Severity of ankylosis/submergence	Amount of infra-occlusion
Slight ankylosis	Infra-occlusion less than 2 mm
Moderate ankylosis	Infra-occlusion at the interproximal contact area
Severe ankylosis	Infra-occlusion is well below the interproximal contact area

### Ankylosis/deep submersion of primary molars

Anatomical fusion of the cementum of the tooth root and the surrounding bone is known as ankylosis. The affected tooth appears to be sinking, while in reality, the rest of the dentition develops around the tooth being anchored to the alveolar bone. Ankylosed primary molars appear lower than the occlusal plane clinically and elicit a dull ‘cracked teacup’ sound on percussion. Ankylosis/submergence can be classified on the basis of amount of infra-occlusion as (Table 1):

The eruption and development of the permanent dentition is impaired as occlusal development is affected by ankylosed primary molars. The various treatment modalities for ankylosis/deep submersion of primary molars are as follows:

#### Observation and monitoring

Observation and monitoring of retained primary molars is the treatment of choice in sound teeth for 6–12 months after the expected time of exfoliation.

#### Extraction and space maintenance

Extraction of the ankylosed molar followed by placement of a space maintainer is beneficial for eruption of the succedaneous tooth by preventing the shift of the adjacent teeth into the vacant space. The various space maintainers are:

**Lower lingual holding arch** In case of infra-occlusion of bilateral mandibular primary second molars causing mesial tipping of the mandibular permanent molars, a lower lingual holding arch can be used. Initially, extraction of the mandibular primary second molars is performed followed by fitting the mandibular first permanent molars with bands for fabrication of a lower lingual holding arch. After cementation of the bands, the lingual arch wire prevents further mesial tipping of the mandibular first permanent molars by contacting the permanent mandibular incisors and allowing eruption of the second premolars. This space maintainer should be placed only after eruption of the mandibular incisors to prevent interference of the arch wire with the eruption of the incisors.

**Distal shoe space maintainer** In cases of severely infra-occluded mandibular second primary molar with an actively erupting mandibular first permanent molar, a distal shoe space maintainer is used after extraction of the primary molar. As the infra-occluded mandibular second primary molar cannot guide the erupting permanent molar into a normal occlusal position, extraction of the primary second molar followed by cementation of a band on the primary first molar with an extension arm engaging the mesial aspect of the erupting first permanent molar is recommended. The extension arm guides the eruption of the permanent molar into the normal occlusal position.

If a succedaneous tooth is absent, extraction of the ankylosed molar with placement of a space maintainer is necessary for implant planning. The operator should be careful as the alveolar ridge decreases in width by 25% within 4 years after extraction of the retained lower primary second molars resulting in compromised restorative management with dental implants.

### **Extraction and orthodontic space closure**

If the succedaneous tooth is absent, extraction of the ankylosed primary molar followed by orthodontic closure of the space is recommended. It is a favorable treatment approach for arch alignment in case of crowding.

### **Restorative treatment**

If the infra-occluded molar has a sound crown without resorbed roots, it can be restored using composite resins and stainless steel crowns to maintain the occlusion and position of teeth.

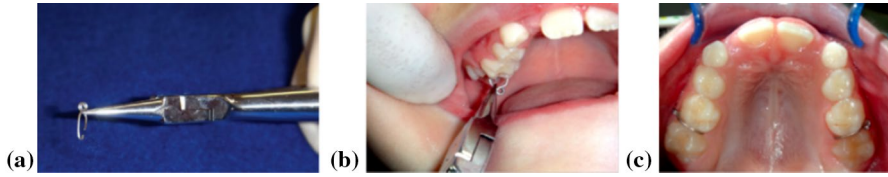### **Ectopic eruption of maxillary first permanent molars**

Ectopic eruption of the maxillary first permanent molar is a localized disturbance of eruption. It is characterized by eruption of the molar in a mesioangular path, leading to entrapment below the distal prominence of the crown of the maxillary second primary molar and causing atypical resorption of distobuccal root of the primary molar.

The aim of treatment of ectopically erupting permanent molars is prevention of continued space loss and premature loss of the second primary molar by uprighting the first permanent molar. Spontaneous correction of the eruption path of ectopically erupting first permanent molars can occur between 6 and 7 years of age if the dental and chronological ages correspond. The treatment modalities for de-impaction of ectopic permanent molars are:

### **Placement of separating spring, brass ligature wire or orthodontic elastic separator**

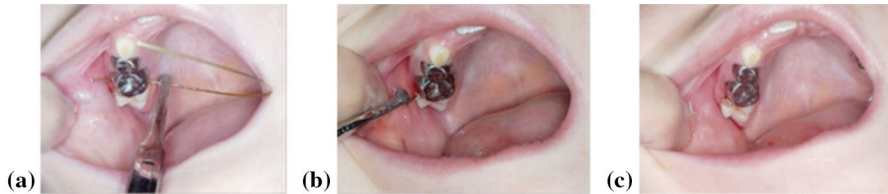Various materials can be used for creating space distal to the maxillary second primary molar for de-impaction of the first permanent molar.



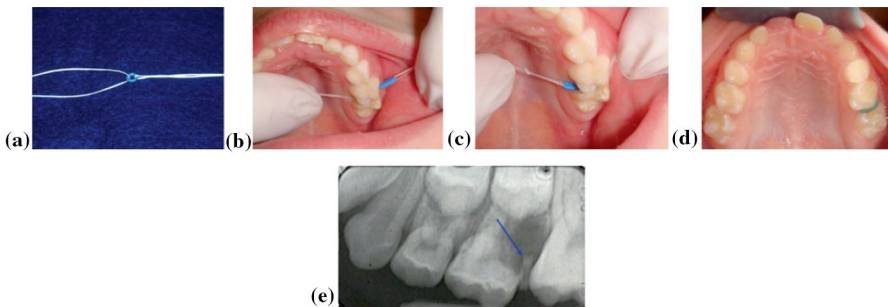
**Fig. 1** **a** Separating spring. **b** Placement of separating spring to de-impact maxillary first permanent molar. **c** De-impacted maxillary right and left first permanent molars with separating springs

**Separating spring** A separating spring can be placed between the second primary molar and the first permanent molar for de-impaction (Fig. 1).

**Brass ligature wire** For de-impaction, a brass ligature wire can also be placed between the second primary molar and the first permanent molar (Fig. 2). A Howe plier is used to twist the wire together. The direction of the twist is recorded followed by tucking the wire into the embrasure. Every 2–3 weeks, the wire is tightened till the de-impaction has taken place. The wire is then removed. For assessing the stability of the second primary molar and its ability to act as a space maintainer, periapical radiographs are used.



**Fig. 2** **a** Placement of brass wire between impacted maxillary right first permanent molar and maxillary second primary molar from palatal direction. **b** Cut brass wire twisted together. **c** Brass wire tucked into the embrasure



**Fig. 3** **a** Orthodontic elastic separator with floss. **b** Flossing the orthodontic elastic separator between impacted maxillary first permanent molar and second primary molar. **c** Floss and orthodontic elastic separator through contact. **d** Floss removed and orthodontic elastic separator in place. **e** Periapical radiograph revealing de-impacted maxillary first permanent molar with radiopaque orthodontic elastic separator still in place

**Orthodontic elastic separator** An orthodontic elastic separator is placed between the second primary molar and the first permanent molar using a waxed dental floss for de-impaction of the permanent molar (Fig. 3). The orthodontic elastic separator is better tolerated for separation than a separating spring or brass wire. After de-impaction, the elastic separator can be lost spontaneously or can require removal.

### Interproximal enamel reduction of the second primary molar

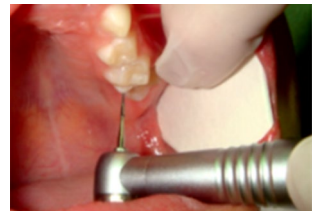For de-impaction of the first permanent molar, the interproximal enamel of the second primary molar can be reduced using a 169 L carbide bur in high speed (Fig. 4). To prevent inadvertent disking of the mesial aspect of the maxillary first permanent molar, placement of a wedge between the second primary molar and the first permanent molar is advised.

### Active appliance therapy

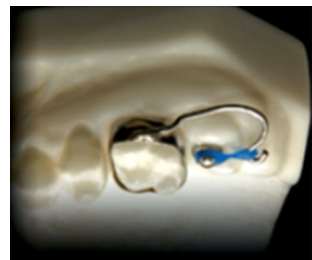
If de-impaction of the first permanent molar is not achieved with other less invasive methods, active appliance therapy should be used.

**Halterman appliance** The design of the Halterman appliance contains a mushroom-shaped stainless steel button that is bonded to the occlusal surface of the impacted first permanent molar (Fig. 5). A band with a soldered hook extends distally for cementation on the second primary molar. A chain elastic is inserted between the button and the hook for application of a distalizing force on the first permanent molar.

**Fig. 4** Disking the distal surface of maxillary second primary molar

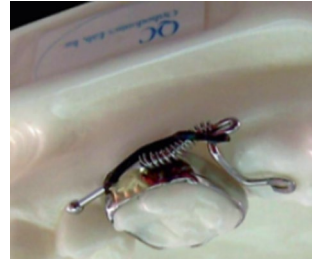

**Fig. 5** Halterman appliance (Courtesy of QC Orthodontics Lab)





**Fig. 6** Ectopic spring-loaded distalizer appliance (Courtesy of QC Orthodontics Lab)



**Ectopic spring-loaded distalizer** The function of the ectopic spring-loaded distalizer is similar to Halterman appliance. The appliance design is different and has no button like the Halterman appliance (Fig. 6). The ectopic spring-loaded distalizer contains an arm that is bonded to the buccal cusp of the first permanent molar. The appliance is fitted with a compressed and pre-activated coil. Till cementation of the appliance, the coil is held passive with an elastic chain that is removed before activation.

### Extraction of second primary molar and space maintenance

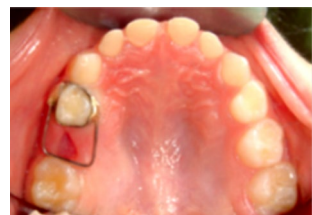To maintain space for the maxillary second premolar, the second primary molar is retained as long as possible. Extraction of the second primary molar is essential if it is symptomatic, mobile and diseased with an abscess or has advanced root resorption. Therefore, space maintenance with space maintainer appliances is necessary to prevent loss of space and ectopic eruption of the permanent molar.

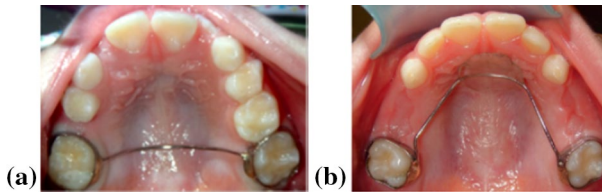
**Reverse band and loop space maintainer** A reverse band and loop space maintainer is utilized when the first permanent molar is incompletely erupted and cannot be banded. The first primary molar is banded with a loop that extends distally to the partially erupted first permanent molar (Fig. 7).

**Transpalatal or nance space maintainer** A transpalatal or nance space maintainer can be used for space maintenance when the first permanent molar erupts sufficiently to be fitted with an orthodontic band (Fig. 8).

**Distal shoe space maintainer** A distal shoe space maintainer is used if the second primary molar is extracted before eruption of the first permanent molar (Fig. 9).

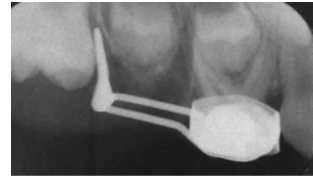
**Fig. 7** Reverse band and loop space maintainer to maintain space for maxillary second premolar





**Fig. 8** **a** Transpalatal appliance for premature unilateral loss of maxillary second primary molar. **b** Nance appliance for premature bilateral loss of maxillary second primary molars

**Fig. 9** Distal shoe appliance for premature loss of maxillary second primary molar and unerupted permanent molar



### **Ectopic eruption and impaction of maxillary permanent canines**

Displacement of permanent canines can occur in the maxillary arch. Maxillary permanent canines are the second most commonly impacted teeth. Continuous digital monitoring is advisable for early detection of displacement or impaction of permanent canines; as unerupted canines can change their position later during development.

The optimal time for treatment of ectopically erupted and impacted maxillary permanent canines is adolescence. The goal of the treatment is to upright and change the eruption path of the canine, preventing root resorption of the adjacent lateral incisor. The eruption path of the maxillary permanent canine can change spontaneously with a change in the environmental conditions.

The canine position can be confirmed using periapical or panoramic radiographic evaluation. A common technique for the diagnosis of palatally displaced canines is the Clark's rule that utilizes two periapical radiographs taken from two different views. For determining the location of the canines and identification of root resorption on the adjacent lateral incisors, cone beam computed tomography is a more diagnostic and reliable approach. The treatment modalities for correction of displaced or impacted maxillary permanent canines are:

### **Use of cervical headgear**

For maintenance of space in the maxillary arch leading to an improved intraosseous canine position, adjunctive use of a cervical headgear may be recommended.

## Rapid palatal expansion

Rapid palatal expansion or other orthodontic interventions are primarily used to correct anterior crowding by increasing the arch space. This can also facilitate change in the eruption path of the canine.

## Extraction of primary canines and first molars

Extractions of primary canines and first primary molars have a multitude of benefits in case of displaced or impacted permanent canines (Fig. 10).

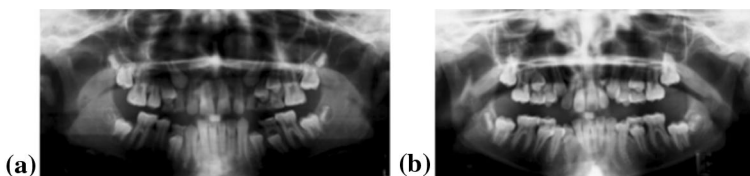
**Extraction of primary canines** Extraction of primary canines can result in improved positional changes and reduced eruption time of the permanent canines. In cases of palatally displaced permanent canines with primary canines obstructing the eruption path of permanent canines, timely interceptive extraction of the maxillary primary canine facilitates spontaneous eruption of the permanent canine.

**Extraction of primary first molars** Extraction of maxillary primary first molars, along with radiographic evidence of one-half root formation of the maxillary first premolar, can stimulate the eruption of the first premolar resulting in development of a guide for the eruption of the permanent canine.

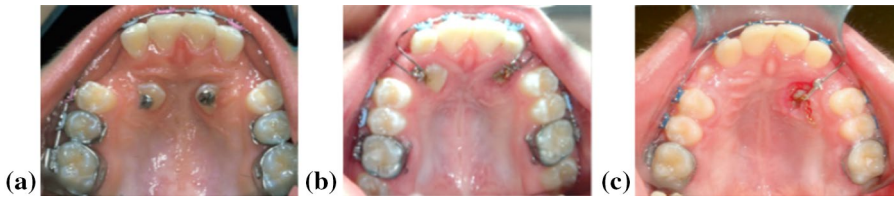## Surgical exposure of palatally impacted ectopic maxillary canines and orthodontic correction

For surgical exposure of palatally impacted maxillary permanent canines, two approaches can be used. Maintenance of good oral hygiene and compliance with wearing fixed orthodontic appliances for a long duration is required in both the methods.

**Closed exposure** In closed exposure, after the initial 6–9 months of alignment and space creation, the palatally impacted canine is surgically uncovered followed by



**Fig. 10** **a** Panoramic radiograph revealing ectopic eruption of maxillary right and left permanent canines and one-half root formation of the maxillary first premolars. **b** Panoramic radiograph revealing corrected orientation of maxillary permanent canines 13 months post-extraction of maxillary primary canines and first primary molars



**Fig. 11** **a** Auxiliary attachments on surgically exposed maxillary right and left permanent canines. **b** Ballista loops on surgically exposed maxillary right and left permanent canines (Courtesy of Dr. John F Buzzatto). **c** Gold chain on surgically exposed maxillary left permanent canine

bonding of an auxiliary attachment to the tooth. Traction forces are applied using ballista loops or a gold chain to drag the impacted maxillary permanent canine into the edentulous site (Fig. 11).

**Open exposure** In open exposure, the impacted canine is surgically uncovered before the initiation of orthodontic treatment during the late mixed dentition. Surgical uncovery of the canine includes:

- Raising a full thickness mucoperiosteal flap to expose the impacted canine.
- Removing all the bone surrounding the crown up to the cemento-enamel junction.
- Re-attaching the flap in place.
- Creating a hole in the flap.

Within 6–8 months, the impacted canine erupts spontaneously. After reaching the occlusal plane, a bracket is placed on the tooth for orthodontic movement and arch alignment.

### Dental transposition

Interchange in the position of two permanent teeth is known as dental transposition. The treatment for dental transposition includes:

#### Orthodontic correction

Orthodontic correction can be used to shift the transposed tooth to its correct position in the dental arch.

#### Reshaping after eruption

The transposed teeth can be reshaped after eruption for improved esthetics and to facilitate function.

## Extraction with orthodontic space closure

In case of severe dental transposition, the transposed teeth can be extracted and the arch can be aligned with orthodontic space closure.

## Further reading

1. Soxman JA, Soxman JA, Wunsch PB, Naberland CM Anomalies of the developing dentition, anomalies of tooth eruption. [https://doi.org/10.1007/978-3-030-03164-0\\_5](https://doi.org/10.1007/978-3-030-03164-0_5)
2. Kim SH, Cho YA, Nam OHN, Kim MS, Choi SC, Lee HS (2016) Complication after extraction of natal teeth with continued growth of a dental papilla. *Pediatr Dent* 38(7):E137–EE14
3. American Academy of Pediatric Dentistry (2017) Management of the developing dentition and occlusion in pediatric dentistry. *Pediatr Dent* 39(6):334–347
4. Tsolakis AI, Kalavritinos M, Bitsanis E (2018) Reliability of different methods for localization of displaced maxillary canines. *Am J Orthod Dentofac Orthop* 153:308–314
5. Neville BW, Damm DD, Allen CM, Chi AC (2016) Abnormalities of teeth. In: *Oral and maxillofacial pathology*, 4th edn. Elsevier, St. Louis, p 76

**Publisher's Note** Springer Nature remains neutral with regard to jurisdictional claims in published maps and institutional affiliations.