



# Case Report: Simultaneously Induced Neutropenia and Hemolysis After a Single Metamizole Dose

Raphael Allgaier<sup>1</sup> · Arne Kandulski<sup>2</sup> · Karsten Gülow<sup>2</sup> · Lars Maier<sup>1</sup> · Martina Müller<sup>2</sup> · Hauke Christian Tews<sup>2</sup>

Accepted: 22 February 2023 / Published online: 29 March 2023  
© The Author(s) 2023

## Abstract

**Background and objective** Metamizole is a non-opioid ampyrone sulfonate compound with potent analgesic, antipyretic, and spasmolytic effects. Agranulocytosis is a rare life-threatening complication of metamizole.

**Case** Here, we present the case of a 62-year-old patient who developed agranulocytosis as well as hemolysis after a single administration of metamizole.

**Conclusion** This case illustrates the inherent allergic potential of metamizole and its effects on different hematopoietic cell types.

## Key Points

Agranulocytosis and hemolysis occurred simultaneously as a result of the first and single administration of metamizole.

It is unclear which individual factors determine the extent of a potential allergic reaction.

Patients receiving metamizole for the first time may benefit from a close follow-up, in particular within the first few weeks.

## 1 Introduction

Metamizole is still one of the most used analgesics in outpatient and inpatient settings in Germany, whereas metamizole has been withdrawn from most major global markets

including France, Australia, Japan, Canada, the UK, and the USA [1–3]. Agranulocytosis caused by metamizole is a rare but serious complication [4]. This case report highlights the simultaneous occurrence of agranulocytosis and hemolysis in terms of an allergic reaction to metamizole.

## 2 Case

A 62-year-old patient, a retired office worker of German origin, presented for a scheduled revision of his transjugular intrahepatic portosystemic shunt (TIPS) in May 2022. The underlying disease was portal hypertension due to non-alcoholic steatohepatitis liver cirrhosis. The esophageal varices had progressed despite TIPS, so the patient was admitted for testing and revision of the TIPS. In addition, there was a known splenic vein thrombosis, which had been treated with a stent implantation and initiation of anticoagulation therapy in November 2018. Of clinical relevance, metabolic syndrome was present as a cardiovascular and liver risk factor and etiology of liver cirrhosis.

On admission, the patient was in a good general condition. Table 1 shows the medication on admission. An angiographic intervention including a percutaneous transluminal balloon angioplasty of the TIPS and a balloon percutaneous transluminal balloon angioplasty of the splenic vein stent were performed. Because of post-interventional abdominal pain, a single dose of metamizole 1 g was administered orally in the evening following TIPS revision and a balloon percutaneous transluminal balloon angioplasty of

✉ Raphael Allgaier  
Raphael.Allgaier@ukr.de

<sup>1</sup> Department of Internal Medicine II, Cardiology, University Medical Center Regensburg, Regensburg, Germany

<sup>2</sup> Department of Internal Medicine I, Gastroenterology, Hepatology, Endocrinology, Rheumatology and Infectious Diseases, University Medical Center Regensburg, Regensburg, Germany

**Table 1** Medication on admission

Drug	Dose	Schedule
Spironolactone	50 mg	1-0-0
Hydrochlorothiazide	25 mg	1-0-0
Ornithine aspartate	6 g	1-1-1
Lactulose	10 mL	1-1-1
Rifaximin	550 mg	1-0-1
Duloxetine	30 mg	1-0-0
Ramipril	5 mg	1-0-0
Ursodeoxycholic acid	250 mg	1-1-1
Apixaban	5 mg	1-0-1
Insulin glargin	units	0-0-0-16
Insulin lispro	units	5-6-6
Metformin	500 mg	1-0-1
Semaglutide	0.25 mg	1-0-0

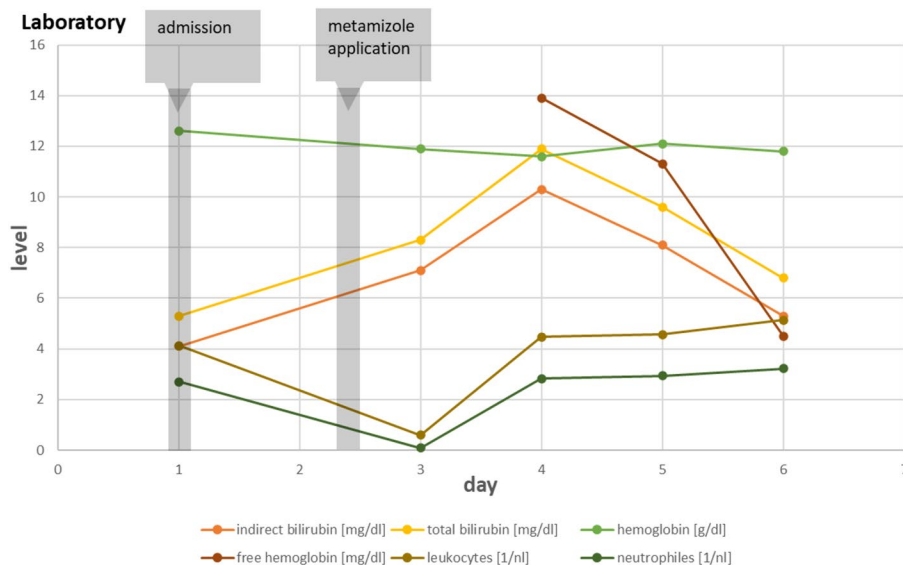
the splenic vein stent. Considering the medication history, this was generally the patient's first intake of metamizole. The following day, the blood count of the patient showed an agranulocytosis of 0.09/nL and an elevated indirect bilirubin of 10.3 mg/dL, with no increase of liver enzymes. A manual differential blood count ruled out neoplasia of the bone marrow, as no atypical cells were present. Individual protective reverse isolation and antibiotic prophylaxis for 3 days were performed as well as a single application of filgrastim (48 million units subcutaneously). Revisiting the medication history, there was no change in medication during the inpatient stay except for the single application of metamizole, the single administration of a local anesthetic (prilocaine 1% 10 mL) during the Sheldon catheterization, and the application of an iodine-based contrast medium (Cacique 300 120 mL) during angiography. Metformin was

discontinued 2 days before hospital admission. Anticoagulation was paused peri-interventionally (Fig. 1).

Further diagnostics were also performed regarding the elevated indirect bilirubin. Haptoglobin was significantly decreased, and free hemoglobin and lactate dehydrogenase were significantly increased as a diagnostic specification of intraluminal hemolysis. A repeated manual differential blood count revealed no evidence of schistocytes. No previous hematologic disease was present. With continued intact renal function and stable platelets, there was no evidence of microangiopathy. Extracorporeal procedures were not performed. Laboratory chemistry excluded glucose-6-phosphate dehydrogenase deficiency and paroxysmal nocturnal hemoglobinuria. Hemoglobin electrophoresis revealed no evidence of other hemoglobin disorders. Overall, there was no evidence of corpuscular hemolysis. There was also no blood transfusion. In addition, there was no hint of infectious hemolysis. Furthermore, there was no evidence of foreign travel in recent years. Reticulocytes were adequately elevated. The Coombs test was negative. In the setting of hemolysis, the hemoglobin titer decreased only slightly from 12.6 to 11.5 mg/dL. Symptoms of anemia or pectanginal symptoms were not present. In summary of all the findings, a diagnosis of metamizole-induced agranulocytosis with concomitant simultaneous hemolysis was established (Table 2).

At the beginning of therapy, there was a rapid appropriate increase in granulocytes and a decrease in bilirubin to baseline levels. Both cardiac and pulmonary functions were stable throughout. There was consistently no elevated body temperature and no symptoms of infection. Systemic inflammation levels showed a discrete increase at a low level. C-reactive protein increased from 5.5 to 12.2 mg/L. Because of the rapid improvement and normalization of the blood count with increasing granulocytes and significantly

**Fig. 1** Levels of blood cells and bilirubin over time and in context to a single administration of metamizole 1 g orally



**Table 2** Laboratory findings

	04.05.2022	06.05.2022	07.05.2022	08.05.2022	09.05.2022
Leukocytes (1/nL)	4.12	0.59	4.47	4.56	5.14
Neutrophils (1/nL)	2.70	0.09	2.82	2.93	3.22
Eosinophils (1/nL)	0.04	0.01	0.05	0.10	0.07
Basophils (1/nL)	0.03	<0.01	0.03	0.03	0.06
Lymphocytes (1/nL)	0.86	0.18	0.63	0.90	1.16
Platelets (1/nL)	144	119	110	110	131
Erythrocytes (1/pl)	4.06	3.88	3.90	3.94	3.82
Hemoglobin (g/dL)	12.6	11.9	11.6	12.1	11.8
Free hemoglobin (mg/dL)			13.9	11.3	4.5
Bilirubin total (mg/dL)	5.3	8.3	11.9	9.6	6.8
Direct bilirubin (mg/dL)	1.2	1.2	1.6	1.5	1.5
Indirect bilirubin (mg/dL)	4.1	7.1	10.3	9.3	5.2
Creatinine (mg/dL)	0.64	0.71	0.64	0.70	0.64
Urea (mg/dL)	38	40	31	31	30

reduced hemolysis parameters, the administration of intravenous immunoglobulins or steroids was not necessary. Next, computed tomography and post-interventional imaging of the TIPS as well as the splenic vein stent was performed. Here, good therapeutic success was documented.

### 3 Discussion

Metamizole can affect hematopoietic cells in terms of an allergic reaction [5–7]. This has been described particularly for granulocytes, but an analysis of 161 reports of metamizole-associated agranulocytosis failed to identify individual risk factors [8]. The cause of hemolysis in our patient case has been thoroughly investigated. Considering several exposures in his history without evidence of changes in his blood count, iodine-based contrast medium-induced agranulocytosis and hemolysis seemed implausibly. It is well known that the risk of an idiosyncratic allergic drug reaction varies with the treatment duration and most cases occur soon after a dose and are more common early after the first treatments [9–11]. Further, there are only very few cases in the available literature that show an association between an iodine-based contrast medium and the occurrence of agranulocytosis or hemolysis [12, 13].

Moreover, we assume that both agranulocytosis and hemolysis are due to the same drug and not two different drugs independently of each other triggered rare complications at the same time. The most relevant differential diagnosis was hemolysis following TIPS dilatation. Hemolysis occurs in 10–15% of cases after TIPS implantation. Therefore, it is conceivable that TIPS dilatation with consecutively altered hemodynamics may also be accompanied by hemolysis [14, 15]. The pathophysiological mechanisms of hemolysis upon TIPS implantation have not been clarified

in detail. In some cases, mechanical hemolysis due to TIPS surface and shear stress accompanied by the occurrence of schistocytes has been reported [15, 16]. However, Kuei et al. reported hemolysis after TIPS implantation without schistocytes. They hypothesized a collision injury of red blood cells of sufficient severity to induce erythrophagocytosis, in which damaged red blood cells are removed by the spleen or circulating phagocytes [17]. In the case described here, no schistocytes were detected in two manual differential blood counts. In addition, there was a rapid decrease in hemolysis parameters after discontinuation of metamizole. Free hemoglobin decreased to a normal level and bilirubin decreased to a baseline level 4 days later.

In reports of hemolysis after TIPS, there is generally a decrease in bilirubin after about 12 weeks [14, 15]. We studied hemolysis associated with (1) revision of TIPS, (2) the use of metamizole, and (3) a negative Coombs test. Given the half-life of metamizole of approximately 3 h, this was to be expected in the presence of a highly suspected drug-induced autoimmune hemolysis. In the context of a type 2 allergic reaction and drug-induced hemolysis, it has been described that hemolysis only occurs in the presence of the specific trigger [18]. The pathophysiology of agranulocytosis and the interaction between metamizole as well as its metabolites and blood as well as progenitor cells are not fully understood. Metamizole is largely metabolized gastrointestinally and hepatically when ingested. 4-Methylaminoantipyrine is the active and the main metabolite. In part, 4-methylaminoantipyrine is bound to plasma proteins. Metamizole and its metabolites may act as haptens on the surface of blood cells and lead to cell lysis after the binding of antibodies [19–22]. Further, in the presence of heme, a weak antioxidative defense, impairment of enzymes, or other highly oxidative compounds, 4-methylaminoantipyrine cytotoxicity is increased and facilitates the development of

neutropenia. Therefore, hemolysis may increase cytotoxicity owing to an increased presence of heme. Having regard to this link, in the presented case, hemolysis potentially contributed to the occurrence of neutropenia [22, 23]. In addition to an immunologically induced destruction of mature neutrophils, links between metamizole and bone marrow depression through the interaction with progenitor cells are described [21, 24]. An analysis of several case reports of agranulocytosis showed that, particularly in cases with a fatal outcome, there was concomitant bone marrow depression validated by bone marrow punctures [9]. In our case, we primarily assume an interaction between metamizole and mature blood cells considering the time course of the immediate development of agranulocytosis after metamizole administration and the increase of hemolysis parameters. Finally, the affection of progenitor cells cannot be clarified owing to the lack of a bone marrow puncture.

This case report presents simultaneous impairment of multiple blood cell lines due to administration of metamizole. Consistent with our findings, Saint-Cyr Sylvestre et al. reported on a 16-year-old African girl who developed a fatal outcome after administration of metamizole (4.5 g daily for 2 weeks) and consecutive agranulocytosis, thrombocytopenia, and hemolysis [25]. The more blood cell lines that are dysfunctional, the higher the clinical risk profile [9]. To date, it remains unclear which factors play a role in determining which blood cells are affected and to what extent in the allergic diathesis to metamizole. Some case reports refer to several days of exposure to metamizole and describe the involvement of only one hematopoietic cell line. Dosage does not appear to be critical [8, 26, 27]. The overall risk of agranulocytosis after metamizole was estimated by the large International Agranulocytosis and Aplastic Anemia (IAAA) study to be 0.5–15 per 1 million treatments over 1 week and the lethality rate of agranulocytosis was about 5–9% [28–30]. However, this analysis did not consider that drug history and the potential previous use of metamizole should be incorporated in the risk assessment. On the one hand, in patients who have been taking metamizole for a period of several months, there is quite a low risk of developing agranulocytosis. On the other hand, patients who take metamizole for the first time have the greatest risk, in particular during the first 2–4 weeks approximately [9, 26]. Thus, Klose et al. evaluated in patients with no prior intake of metamizole a risk of one case of agranulocytosis at about 1500 prescriptions in a case-control study with data from a large German health insurance fund. The observation period was from January 2011 to March 2013. Data regarding treatment duration and daily doses were not obtained [31]. Consistent with these findings, Hedenmalm et al. presented a similar risk assessment regarding agranulocytosis (one case at about 1600 prescriptions) in an analysis of 66 Swedish

case reports, but not all of the included case reports could rule out a previous intake of metamizole [9].

Therefore, critical use of metamizole in certain clinical situations may minimize the risk of allergic reactions. Making patients aware of the symptoms of agranulocytosis may help to recognize the complications more rapidly [32]. It is possible that serious complications could be avoided by performing routine control blood tests after the initial use of metamizole. However, routine venipuncture is likely to be difficult to perform on a day-to-day basis given the widespread use of metamizole in the outpatient setting [33]. Further complicating is the fact that the interval from metamizole application to hematologic complications varies greatly in the literature. An analysis of 1448 publications reported a median time of 13 days after metamizole use for agranulocytosis to occur, but some cases with a very short latency and the occurrence of agranulocytosis within 1 day of metamizole administration are also described [34, 35].

In conclusion and in our specific case, in addition to a type 2 allergic reaction, a type 1 allergic reaction should also be discussed. However, as this patient presented no symptoms such as urticaria, exanthema, dyspnea, or vomiting, we assume a type 2 allergic reaction in summary of the findings [36]. In our case, the complication was rapidly recognized, and appropriate measures were initiated. Fortunately, despite a transient neutrophil count of  $<0.01/\text{nL}$ , the patient was discharged after a full recovery [29].

## 4 Conclusions

This case report presents the simultaneous occurrence of neutropenia and hemolysis as a result of metamizole administration. Although metamizole-induced neutropenia with concomitant hemolysis occurs, the potentially life-threatening course requires an early diagnosis and close monitoring for complications. Currently, there are no known risk factors associated with a higher incidence of these adverse events.

## Declarations

**Funding** No sources of funding were received for the preparation of this article.

**Conflict of Interest** Raphael Allgaier, Arne Kandulski, Karsten Gülow, Lars Maier, Martina Müller, and Hauke Christian Tews have no conflicts of interest that are directly relevant to the content of this article.

**Ethics Approval** Not applicable.

**Consent to Participate** The patient's informed consent was obtained.

**Consent for Publication** The patient's informed consent was obtained.

**Data Availability** Not applicable.

**Code Availability** Not applicable.

**Author Contributions** RA wrote the manuscript with input from all authors and under the supervision of HCT. All authors contributed to the final manuscript.

**Open Access** This article is licensed under a Creative Commons Attribution-NonCommercial 4.0 International License, which permits any non-commercial use, sharing, adaptation, distribution and reproduction in any medium or format, as long as you give appropriate credit to the original author(s) and the source, provide a link to the Creative Commons licence, and indicate if changes were made. The images or other third party material in this article are included in the article's Creative Commons licence, unless indicated otherwise in a credit line to the material. If material is not included in the article's Creative Commons licence and your intended use is not permitted by statutory regulation or exceeds the permitted use, you will need to obtain permission directly from the copyright holder. To view a copy of this licence, visit <http://creativecommons.org/licenses/by-nc/4.0/>.

## References

- Lutz M. Metamizole (Dipyrone) and the liver: a review of the literature. *J Clin Pharmacol*. 2019;59(11):1433–42.
- Ramacciotti AS, Soares BGO, Atallah AN. WITHDRAWN: dipyrone for acute primary headaches. *Cochrane Database Syst Rev*. 2014;7: CD004842.
- Nikolova I, Petkova V, Tencheva J, Benbasat N, Voinikov J, Danchev N. Metamizole: a review profile of a well-known “forgotten” drug. Part II: clinical profile. *Biotechnol Biotechnol Equip*. 2013;27(2):3605–19.
- Huber M, Andersohn F, Sarganas G, Bronder E, Klimpel A, Thomae M, et al. Metamizole-induced agranulocytosis revisited: results from the prospective Berlin Case-Control Surveillance Study. *Eur J Clin Pharmacol*. 2015;71(2):219–27.
- Uzzaman A, Cho SH. Chapter 28: classification of hypersensitivity reactions. *Allergy Asthma Proc*. 2012;33(Suppl 1):96–9.
- Fernández GPL, Ibáñez CMF, López PE. Severe thrombocytopenia and agranulocytosis associated with metamizole. *Med Clin*. 2016;147(8):e43–4.
- Blanca-López N, Pérez-Sánchez N, Agúndez JA, García-Martín E, Torres MJ, Cornejo-García JA, et al. Allergic reactions to metamizole: immediate and delayed responses. *Int Arch Allergy Immunol*. 2016;169(4):223–30.
- Stammschulte T, Ludwig W-D, Mühlbauer B, Bronder E, Gundert-Remy U. Metamizole (dipyrone)-associated agranulocytosis: an analysis of German spontaneous reports 1990–2012. *Eur J Clin Pharmacol*. 2015;71(9):1129–38.
- Hedenmalm K, Spigset O. Agranulocytosis and other blood dyscrasias associated with dipyrone (metamizole). *Eur J Clin Pharmacol*. 2002;58(4):265–74.
- Guess HA. Behavior of the exposure odds ratio in a case-control study when the hazard function is not constant over time. *J Clin Epidemiol*. 1989;42(12):1179–84.
- Miettinen OS, Caro JJ. Principles of nonexperimental assessment of excess risk, with special reference to adverse drug reactions. *J Clin Epidemiol*. 1989;42(4):325–31.
- Hongo T, Nozaki S, Tsuchiya M, Inaba M, Takahashi K, Fujiwara T. Contrast medium-induced transient severe leukopenia. *Acute Med Surg*. 2018;5(2):185–8.
- Al Ghailani HH, Al Alawi AM, Al Hashim AH. Contrast media-induced immune hemolytic anemia. *Cureus*. 2021;13(4): e14522.
- Sanyal AJ, Freedman AM, Purdum PP, Shiffman ML, Luketic VA. The hematologic consequences of transjugular intrahepatic portosystemic shunts. *Hepatology*. 1996;23(1):32–9.
- Conn HO. Hemolysis after transjugular intrahepatic portosystemic shunting: the naked stent syndrome. *Hepatology*. 1996;23(1):177–81.
- García-Rebollo S, González-Reimers E, Santolaria-Fernández F, Diaz-Romero F, Rodríguez-Moreno F, Martínez-Riera A. Transient hemolytic anemia after transjugular intrahepatic portosystemic stent shunt. *HPB Surg*. 1996;9(4):249–51.
- Kuei A, Mikolajczyk AE, Niemeyer MM. Management of complications in IR: hemolytic anemia following stent-graft transjugular intrahepatic portosystemic shunt creation. *Semin Interv Radiol*. 2019;36(2):72.
- Garratty G. Drug-induced immune hemolytic anemia. *Hematology Am Soc Hematol Educ Program*; 2009. p. 73–9.
- Kenney B, Stack G. Drug-induced thrombocytopenia. *Arch Pathol Lab Med*. 2009;133(2):309–14.
- Ariza A, García-Martín E, Salas M, Montañez MI, Mayorga C, Blanca-Lopez N, et al. Pyrazolones metabolites are relevant for identifying selective anaphylaxis to metamizole. *Sci Rep*. 2016;6: 23845.
- García-Martínez JM, Fresno Vara JA, Lastres P, Bernabéu C, Betés PO, Martín-Pérez J. Effect of metamizol on promyelocytic and terminally differentiated granulocytic cells: comparative analysis with acetylsalicylic acid and diclofenac. *Biochem Pharmacol*. 2003;65(2):209–17.
- Rudin D, Schmutz M, Roos NJ, Bouitbir J, Krähenbühl S. Reactive metamizole metabolites enhance the toxicity of hemin on the ATP pool in HL60 cells by inhibition of glycolysis. *Biomedicines*. 2020;8(7):212.
- Radulovic I, Dogan B, Dohna-Schwake C, Schündeln MM, Siffert W, Möhlendick B. NAT2 polymorphisms as a cause of metamizole-induced agranulocytosis. *Pharmacogenet Genom*. 2021;31(6):140–3.
- Curtis BR. Drug-induced immune neutropenia/agranulocytosis. *Immunohematology*. 2014;30(2):95–101.
- Saint-Cyr Sylvestre PD, Clotaire ND, Emeraude NC, Kouakou B, Magloire CPS, Mamady D, et al. Fatal agranulocytosis associated with metamizole treatment in a 16-year-old girl. *Arch Case Rep*. 2019;3(1):35–7.
- Blaser LS, Tramonti A, Egger P, Haschke M, Krähenbühl S, Rätz Bravo AE. Hematological safety of metamizole: retrospective analysis of WHO and Swiss spontaneous safety reports. *Eur J Clin Pharmacol*. 2015;71(2):209–17.
- Andrade S, Bartels DB, Lange R, Sandford L, Gurwitz J. Safety of metamizole: a systematic review of the literature. *J Clin Pharm Ther*. 2016;41(5):459–77.
- Lampl C, Likar R. Metamizol: Wirkmechanismen, Interaktionen und Agranulozytoserisiko. *Schmerz*. 2014;28(6):584–90.
- Andrès E, Maloïsel F. Idiosyncratic drug-induced agranulocytosis or acute neutropenia. *Curr Opin Hematol*. 2008;15(1):15–21.
- Risks of agranulocytosis and aplastic anemia. A first report of their relation to drug use with special reference to analgesics: the International Agranulocytosis and Aplastic Anemia Study. *JAMA*. 1986;256(13):1749–57.
- Klose S, Pflock R, König IR, Linder R, Schwaninger M. Metamizole and the risk of drug-induced agranulocytosis and neutropenia in statutory health insurance data. *Naunyn Schmiedebergs Arch Pharmacol*. 2020;393(4):681–90.
- Andersohn F, Konzen C, Garbe E. Systematic review: agranulocytosis induced by nonchemotherapy drugs. *Ann Intern Med*. 2007;146(9):657–65.

33. Schinz K, Waldfahrer F, Wüst W, Iro H. Agranulozytose nach Metamizol-Einnahme: ein unterschätztes Risiko? *Laryngorhinootologie*. 2020;99(10):707–12.
34. Stamer UM, Gundert-Remy U, Biermann E, Erlenwein J, Meißner W, Wirz S, et al. Metamizol: Überlegungen zum Monitoring zur frühzeitigen Diagnose einer Agranulozytose. *Schmerz*. 2017;31(1):5–13.
35. Hoffmann F, Bantel C, Jobski K. Agranulocytosis attributed to metamizole: an analysis of spontaneous reports in EudraVigilance 1985–2017. *Basic Clin Pharmacol Toxicol*. 2020;126(2):116–25.
36. Castells M. Diagnosis and management of anaphylaxis in precision medicine. *J Allergy Clin Immunol*. 2017;140(2):321–33.