

Surgical and Endoscopic Options for Benign and Malignant Gastric Outlet Obstruction

Amie Miller · Steven Schwartzberg

Published online: 1 March 2014
© Springer Science + Business Media New York 2014

Abstract Gastric outlet obstruction (GOO) can be due to a variety of causes of both benign and malignant sources. As the etiology of GOO shifts from mostly benign to mostly malignant, treatment options have also evolved. Traditional options have only included surgery, but an increase in technology has seen the emergence of endoscopic alternatives. For benign disease, such as peptic ulcer disease, endoscopic balloon dilation has reduced the number of patients needing to undergo larger and more invasive surgical procedures. It has also proven successful in treating obstruction from stricture following bariatric surgery, but surgical revision or reversal remains the gold standard. Numerous surgical procedures have shown effectiveness when treating GOO, with new procedures constantly emerging. When malignancy is the cause, the procedural focus shifts from curative to palliative with the main focus being resumption of oral intake. Endoscopic stenting provides a viable alternative to gastro-jejunostomy, but due to problems with re-obstruction and stent migration, it should be reserved for patients with shorter life expectancies.

Keywords Gastric outlet obstruction · Pyloroplasty · Gastro-jejunostomy

Introduction

Gastric outlet obstruction (GOO) is defined as a spectrum of diseases that produces mechanical impedance to gastric emptying. The most common pathophysiology is intrinsic or extrinsic obstruction of the duodenum or pyloric channel, but the mechanism of obstruction depends on the underlying etiology [1]. Etiologies of GOO are often divided into two categories, mechanical and non-mechanical. Once non-mechanical causes, such as diabetic gastroparesis, have been ruled out, benign and malignant mechanical causes must be differentiated. Through the 1970s, benign disease was the most common, with studies reporting up to 91 % of cases were from benign rather than malignant causes [2]. With the discovery of H2 blockers and PPIs, there has been a change in ratio between benign and malignant causes of GOO. Recent studies have shown malignancy may account for as many as 60 % of cases [3], with peripancreatic malignancy the most common etiology and reported in 15–20 % [1]. The most common causes of benign obstruction are peptic ulcer disease (PUD) and corrosive ingestion, but NSAIDs, gastric polyps, pyloric stenosis and pancreatic pseudocysts have all been implicated (Table 1). While obstruction used to be the most common complication of PUD, it is now the least common at less than 5 %. On the other hand, in cases of ingestion of strong caustics, as many as 36–44 % of patients will develop GOO [4, 5].

Benign Gastric Outlet Obstruction

While surgery used to be the gold standard treatment for benign GOO, recent advancements in endoscopy have provided other treatment options. Prior to the 1980s, conservative medical treatments and surgery were the only

This article is part of the Topical Collection on *Acute Care Surgery*.

A. Miller (✉) · S. Schwartzberg
Department of Surgery, Cambridge Health Alliance-Harvard
Medical School, 1493 Cambridge St, Cambridge, MA 02139,
USA
e-mail: ammiller@challiance.org

S. Schwartzberg
e-mail: sswartzberg@challiance.org

Table 1 Etiology of benign gastric outlet obstruction

Peptic ulcer disease
Pyloric stenosis
Inflammatory disease
<i>Pancreatitis</i>
<i>Crohn's disease</i>
<i>Cholecystitis</i>
Caustic ingestion
Strictures/webs
Tumors
<i>Polyp</i>
<i>Lipoma</i>
<i>Adenoma</i>
Iatrogenic
<i>Post-surgical obstruction</i>
Other causes
<i>Pancreatic pseudocyst</i>
<i>Bouveret's syndrome</i>
<i>Infection</i>

treatment options. While some patients initially responded to medications, most eventually required some sort of surgical intervention. In 1982, Weiland et al. [6] conducted a retrospective review of 87 patients with GOO. All were treated initially with medications, but 56 % required operative intervention during the same hospital stay. On late follow-up, 98 % of patients with chronic PUD and 64 % with acute PUD ultimately required an operation. Additionally, Jaffin et al. [7] reviewed 69 patients who were admitted with GOO from 1970–1979; 81 % of cases were due to PUD. All were initially managed conservatively, but 62 % required surgical decompression during that hospital stay. An additional 20 % underwent an operation after a subsequent obstructive episode. Of the ten patients who did not have surgery, six died in the next 3 years, and three continued to have recurrent symptoms. Overall, 92 % of patients who lived for more than 3 years required surgery. With the invention of PPIs in 1989, treatment of PUD trended toward being non-surgical in nature. Shabbir et al. [8] using data from the turn of the century showed 83 % of patients placed on PPIs had complete resolution of pyloric peptic stenosis, with patients responding on average 9 days after initiation of treatment. While in the 1970s and early 1980s surgical intervention for benign GOO was very common, it is now infrequently needed, and the invention of PPIs has drastically increased the number of patients who can be treated with medical therapy alone.

In the mid 1980s, Benjamin et al. first described technical and clinical success using endoscopic balloon dilation (ED) [9]. Of the seven patients they reported who underwent balloon dilation, only one ended up requiring surgical

intervention. Since then, numerous reports have surfaced documenting the efficacy and safety of the procedure, but with mixed results. Initial success rates are reported from 16–100 %, with most being >80 % [10–16]. Follow-up ranged from 3 months to 10 years with symptoms eventually returning in 0–84 % [10–18]. If surgical intervention was required, it was usually for restenosis, continuation of symptoms, or perforation following dilation. Surgical intervention rates are reported to be 0–51 % [10–13, 17, 19]. Factors that increased the likelihood of eventual surgical intervention included more than two courses of dilation, younger age, longer duration of the treatment course, continued use of NSAIDs, pancreatitis-related GOO and corrosive strictures [10, 12, 14, 17]. While ED generally has good initial success rates, its high rate of restenosis is concerning.

Helicobacter pylori has also been implicated in the effectiveness of ED therapy. Lam et al. [20] prospectively treated 33 patients with benign GOO by ED. Antral biopsies showed 14 had *H. pylori* and 11 were *H. pylori* negative. All patients who were positive for *H. pylori* were treated for eradication after ED was performed. After a median follow-up of 24 months, there was a significant difference between the number of patients with *H. pylori* who developed further ulcer complications as opposed to those who were *H. pylori* negative (21.4 vs. 54.54 %, respectively). In a French study of 16 patients, all whom were *H. pylori* positive, 93.75 % underwent successful ED treatment after a follow-up of 13 months [21]. For those patients who are *H. pylori* positive, eradication of *H. pylori* may increase the success rate of endoscopic therapy and decrease the need for surgical intervention. However, if patients are found to be *H. pylori* negative, they should be counseled that a higher failure rate is expected.

Special Circumstances

An infrequent cause of benign GOO is obstruction from bariatric surgical procedures (Fig. 1), which include vertical banded gastroplasty (VBG), transected banded vertical gastric bypass (TBVBGP) and Roux-en-Y gastric bypass (RYGB). VBG used to be a common weight loss procedure, but due to its high complication and re-operative rates, it has fallen out of favor. GOO has been reported in as many as 8 % of patients undergoing VBG, with staple line leaks, inadequate weight loss and gastroesophageal reflux as additional complications [22]. Two different surgical procedures have been described to relieve the obstruction from a failed VBG, RYGB and VBG reversal via a gastro-gastrostomy. A retrospective review of 34 patients who underwent a VBG that ultimately required revision compared laparoscopic VBG reversal with open

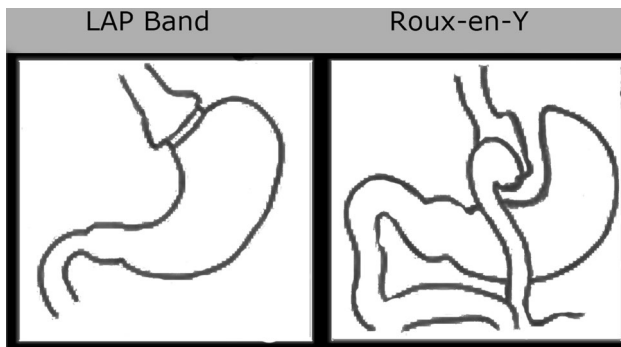


Fig. 1 Bariatric surgical procedures

and laparoscopic RYGB [23]. While there was no difference in complication rates, patients who had the RYGB procedure had a significant decrease in BMI 1–2 years postoperatively, while VBG reversal patients had a significant increase. For those VBG reversal patients, this meant going from an average BMI in the moderately obese range (31.9 ± 4.8) to one in the morbidly obese range (48.6 ± 12.2). If weight loss is still the goal, RYGB appears to be the better option.

VBG is not the only bariatric procedure to have problems. In a review of 2,949 patients undergoing TBVBGP, band erosion was documented in 48 patients (1.63 %), and 17 (36.42 %) of them presented with GOO [24]; 54.17 % of those with band erosion then required subsequent surgical intervention to relieve the obstruction and remove the eroded band. Multiple studies have reported success in removing the eroded band laparoscopically through a gastrostomy in the body of the stomach [25, 26]. In our experience, after accessing the stomach laparoscopically, the band may be simply cut to allow expansion of the stenotic channel. Figure 2 shows stenosis from an eroded Lap-Band.

While RYGB seems to be an effective procedure to relieve obstruction from other failed bariatric surgeries, it too can cause obstruction. Go et al. [27] reviewed 562 patients who underwent RYGB during their 2-year study period. Thirty-eight patients (6.8 %) developed stomal stenosis, an average of 7.7 weeks postoperatively. All underwent ED as treatment, requiring on average 2.1 dilations. All but two of the dilations were successful and relieved the obstruction (95 %). One patient failed dilation and another sustained complications, both requiring surgical intervention. Another series examined 28 patients with GOO after VBG ($n = 9$) and RYGB ($n = 19$) [28]; 30 % of the patients with previous VBG had relief after one dilation, while 42 % of patients with previous RYGB experienced relief. However, 28.5 % still required eventual surgical intervention. While more research is needed, endoscopic dilation may be a feasible alternative to surgical intervention for bariatric surgery stenosis.

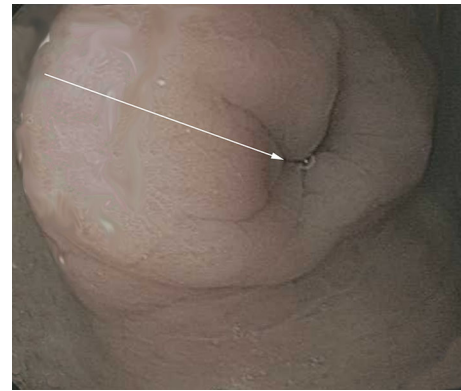


Fig. 2 Stenosis from an eroded Lap-Band

Surgical Techniques

Numerous surgical techniques over the years have been described to treat GOO. Finney, Jaboulay or Heineke-Mikulicz pyloroplasty, antrectomy without or without vagotomy, or gastro-jejunostomy techniques have all been routinely described. In a prospective study of 90 patients with GOO secondary to duodenal ulcer, subjects were randomly assigned to three surgical groups: highly selective vagotomy (HSV) + gastro-jejunostomy (GJ), HSV + Jaboulay gastro-duodenostomy or selective vagotomy (SV) + antrectomy. No differences were found in the postoperative courses, but one patient in the HSV + Jaboulay gastro-duodenostomy group died from acute pancreatitis. After a mean follow-up time of 90 months, the clinical state of the patients was graded using the Visick scale. The Visick scale subjectively classifies the severity of GERD by the patients' reported symptoms, on a scale of 1–4, with 1 (no complaints) being the least severe and 4 (complaints not decreased by surgery) the most severe. In the study by Csendes et al. [29], there were significantly better results after HSV + GJ (80 % Visick I) than after HSV + Jaboulay gastro-duodenostomy (70 % Visick I), but not after SV + antrectomy (75 % Visick I). They concluded that HSV + GJ was the treatment of choice. Tsai et al. [30] examined the same surgical procedures, focusing on the outcomes of elderly patients with benign obstructing GOO. Forty-seven patients were studied over the time period of 2000–2008. Fifteen of the patients were considered elderly, 32 young, and they underwent Finney or Jaboulay pyloroplasty ($n = 26$), antrectomy ($n = 13$) or GJ ($n = 8$). The mean hospital stay was 14.9 days with a modest correlation between age and length of stay ($p = 0.04$, $r = 0.294$). There was no increase in morbidity or mortality in the elderly population. While elderly patients did appear to have an increased length of stay, morbidity was not different no matter which surgical procedure they underwent. While multiple surgical procedures

appear to be effective, no single procedure has been proven to be the treatment of choice.

Malignant Gastric Outlet Obstruction

When malignancy is of concern, or verified, surgical options can be curative or palliative. Traditionally, an open GJ was the treatment of choice, but with the advent of laparoscopic surgery, laparoscopic GJ has become the gold standard (Fig. 3). Multiple studies have shown an advantage of laparoscopic GJ over open. In one series, there was no difference in the operating time or number of patients receiving blood transfusions, but laparoscopic GJ was statistically better for decreased need for opiate analgesia, hospital stay, IV hydration requirement and morbidity [31]. A separate study also found a significant reduction in length of hospital stay with laparoscopic GJ as well as decreased intraoperative blood loss [32]. Choi found that open GJ caused more immune suppression than laparoscopic GJ, with increased levels of serum ESR, TNF- α and IL-6 [33]. It is now widely accepted that laparoscopic GJ has clear advantages over open GJ when it is technically feasible.

Recently, new surgical procedures have emerged in the treatment of malignant GOO (Fig. 4). Two separate series have described success with using a partial stomach-partitioning gastro-jejunosotomy (PSPG). Arrangoiz et al. [34] performed PSPG in 55 patients with metastatic tumors causing GOO. They noted good success, with 0 % mortality and 16.4 % complication rates. The median survival of patients was 9 months, with 95 % still tolerating an enteral diet 8 months postoperatively. Eguchi et al. [35] reported PSPG in 18 patients with a similar complication

rate, 17 %. Their patients had a mean time to oral intake of 4.5 days with a mean duration of 133 days. A Japanese group developed a new technique called the modified Devine exclusion with vertical stomach reconstruction (MDVSR) [36]. The procedure involves laparoscopically transecting the stomach, vertically stretching the proximal portion and then re-resecting horizontally with a stapler (Fig. 5). A loop of jejunum was then brought up to the pouch and anastomosed in a horizontal side-to-side fashion. They have reported great success with this technique when comparing it to conventional gastrojejunostomy, and none of the patients who underwent MDVSR had recurrence of GOO. Additionally, hospital stay, time to oral intake, and need for NG decompression were all reduced in the MDVSR group, while survival was increased. While both techniques shows promise, more data is needed.

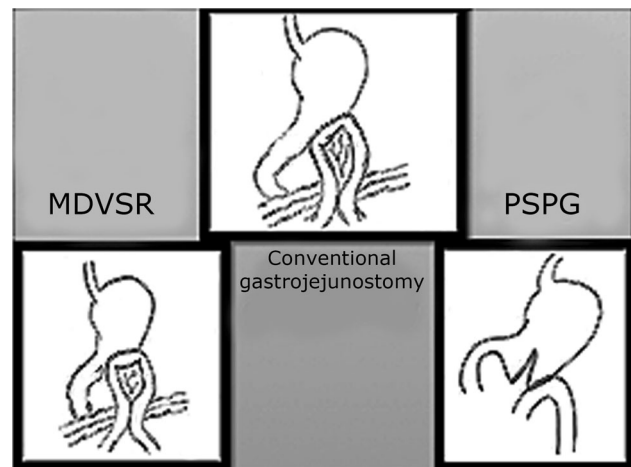


Fig. 4 Conventional GJ versus modified devine exclusion and partial stomach partitioning gastrojejunostomy

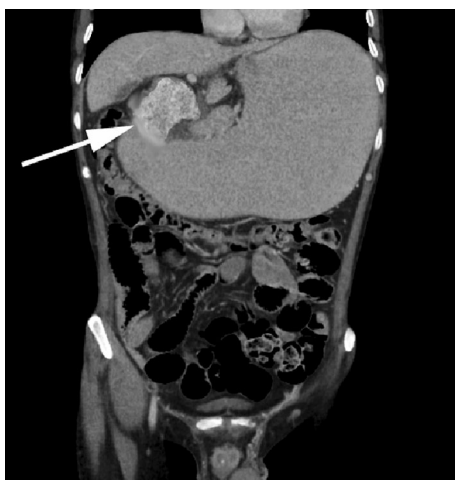


Fig. 3 Malignant gastric outlet obstruction from gastric adenocarcinoma

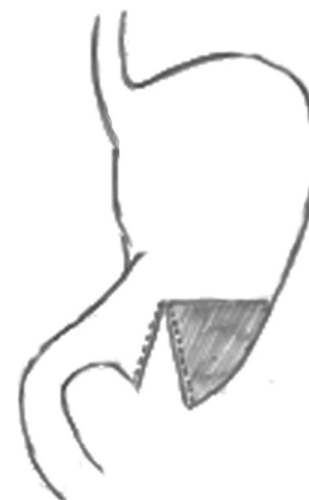

Fig. 5 MDVSR showing shaded resection portion

Emerging Technologies

Expandable metal stents have been approved for use in treating malignant disease causing obstruction throughout the GI tract. They are made of different metal alloys, come in a variety of sizes and shapes, and may be covered or uncovered. Gastro-duodenal stents have emerged as a safe and effective alternative to surgical therapy. Technical and clinical success rates have proven to be high at 89–98 % and 85.5–89 %, respectively [37–40]. However, the procedure is not without complications. A large review study by Dormann et al. [38] identified 606 patients who underwent endoscopic stent placement. While there were no mortalities, severe complications such as bleeding and perforation occurred in 1.2 %, stent migration in 5 % and re-obstruction in 18 %. Mansoor et al. [39] described similar rates of stent-related complications, 14 %, including blockage and migration. Another study by Cho et al. [40] found much higher re-obstruction rates at 31 %, with covered stents and chemotherapy after stent placement significant prognostic factors for stent patency.

Covered stents were designed with a membrane within the mesh wall to prevent ingrowth of tumor and thus obstruction of the stent [41]. Autopsies of human corpses that have had previous uncovered stents placed have shown incorporation of the stent into the tumor itself, causing pressure necrosis. Theoretically, covered stents are designed not to embed into the surrounding tissue, and while they may have lower rates of re-obstruction, it may result in higher migration rates. Woo et al. showed evidence of this after analyzing 70 patients with covered ($n = 24$) and uncovered ($n = 46$) stents [42]. While technical and clinical success rates were similar, the covered group had a statistically higher complication rate (62.5 vs. 34.8 %, respectively) and was primarily attributed to a higher migration rate (20.8 vs. 0 %). While not statistically significant, the patency rate tended to be lower for covered stents (13.7 + 8.6 weeks) than for uncovered stents (not reached). Maetani et al. [43] produced contrary evidence in a randomized trial of covered versus uncovered self-expandable stents. Both groups had a technical success rate of 100 % and similar clinical success rates. While there was no statistical difference between patency rates, covered stents had less frequent rates of dysfunction, and recurrence of obstructive symptoms was higher in the uncovered group. Patient survival did not differ between the two groups. Larger prospective studies would be useful in determining the benefits of covered versus uncovered stents.

Given the reported success of endoscopic stent placement, numerous studies have been published comparing it to traditional surgical intervention. Most studies agree that stenting

provides the following advantages over laparoscopic or open gastro-jejunostomy: shorter operative time, shorter hospital stay and decreased time to oral intake [44–52]. However, they almost universally report decreased patency of stents with higher rates of recurrent obstruction and need for re-intervention [46••, 49, 50, 53]. There have been mixed reports on the technical and clinical success rates, cost of procedure and complication rates. More commonly, studies found no difference between technical and clinical success rates [49–51, 53], but in a meta-analysis of 307 procedures by Hosono et al. [45], clinical success was higher in the stenting group. A recent 10-year retrospective study of stenting versus GJ by Khashab et al. [46••] found statistically higher rates of technical success in the GJ group (96 vs. 99 %). The same group also found a statistical increase in the cost of stenting procedures compared to GJ when stent reintervention procedures were included (\$34,250 vs. \$27,599). A retrospective study using the Medicare database by Roy et al. [47] previously reported stenting to be a cheaper procedure than GJ (\$15,366 vs. \$27,391). However, re-intervention stenting procedures were not included when calculating costs. Complication rates are also widely debated. Both impact, major vs. minor, and timing, early versus late, have been studied. Mixed data have shown both no difference in early minor and major complications [49, 50, 53] and a decrease in time to late major complications in the stenting group [49, 53]. Perhaps the most important statistic for patients is the length of post-procedure survival. Thirty-day survival has been reported as both no difference [45, 48] and decreased for the stenting group [44]. However, mean survival seems to favor the GJ group over the stenting group (90–293 vs. 65–189 days) [50, 52, 53]. Given the higher rates of re-intervention for recurrent obstruction, palliative stenting may best be reserved for patients with shorter expected survival times.

Conclusions

Gastric outlet obstruction is a phenomenon caused by a variety of factors. For benign causes, such as PUD or post-bariatric surgery stenosis, ED may be a viable alternative to traditional surgical treatment. However, for patients that are *H. pylori* negative or have required multiple dilations, surgical GJ appears to be the treatment of choice. Multiple surgical procedures have been used to treat GOO successfully, and new procedures continue to emerge. When malignancy is the cause of GOO, the procedural goal becomes palliation and resumption of oral intake. Endoscopic stenting is a reasonable alternative to laparoscopic or open GJ, but is better reserved for patients who are very poor surgical candidates or have short expected survival times.

Compliance with Ethics Guidelines

Conflict of Interest Amie Miller and Steven Schwaitzberg declare that they have no conflict of interest.

Human and Animal Rights and Informed Consent This article does not contain any studies with human or animal subjects performed by any of the authors.

References

Recently published papers of particular interest have been highlighted as:

•• Of major importance

- Appasani S, Kochhar S, Nagi B, Gupta V, Kochhar R. Benign gastric outlet obstruction—spectrum and management. *Trop Neurogastroenterol.* 2001;32(4):259–66.
- Goldstein H, Boyle JD. The saline load test—a bedside evaluation of gastric retention. *Gastroenterology.* 1965;49:375–80.
- Shone DN, Nikoomanesh P, Smith-Meek MM, Bender JS. Malignancy is the most common cause of gastric outlet obstruction in the era of H2 blockers. *Am J Gastroenterol.* 1995;90:1769–70.
- Zarger SA, Kochhar R, Nagi B, Mehta S, Mehta SK. Ingestion of corrosive acids. Spectrum of injury to upper gastrointestinal tract and natural history. *Gastroenterology.* 1989;97:702–7.
- Zarger SA, Kochhar R, Nagi B, Mehta S, Mehta SK. Ingestion of strong corrosive alkalis: spectrum of injury to upper gastrointestinal tract and natural history. *Am J Gastroenterol.* 1992;87:337–41.
- Weiland D, Dunn DH, Humphrey EW, Schwartz ML. Gastric outlet obstruction in peptic ulcer disease: an indication for surgery. *Am J Surg.* 1982;143:90–3.
- Jaffin BW, Kaye MD. The prognosis of gastric outlet obstruction. *Ann Surg.* 1985;201(2):176–9.
- Shabbir J, Durrani S, Ridgway PF, Mealy K. Proton pump inhibition is a feasible primary alternative to surgery and balloon dilatation in adult peptic pyloric stenosis (APS): report of six consecutive cases. *Ann R Coll Surg Engl.* 2006;88(2):174–5.
- Kochhar R, Kochhar S. Endoscopic balloon dilation for benign gastric outlet obstruction in adults. *World J Gastrointest Endosc.* 2010;2(1):29–35.
- Boylan JJ, Gradzka MI. Long-term results of endoscopic balloon dilatation for gastric outlet obstruction. *Dig Dis Sci.* 1999;44(9):1883–6.
- Cherian PT, Cherian S, Singh P. Long-term follow-up of patients with gastric outlet obstruction related to peptic ulcer disease treated with endoscopic balloon dilatation and drug therapy. *Gastrointest Endosc.* 2007;66(3):491–7.
- Rana SS, Bhasin DK, Chandail VS, Gupta R, Nada R, Kang M, Nagi B, Singh R, Singh K. Endoscopic balloon dilatation without fluoroscopy for treating gastric outlet obstruction because of benign etiologies. *Surg Endosc.* 2011;25(5):1579–84.
- Lau JY, Chung SC, Sung JJ, Chan AC, Ng EK, Suen RC, Li AK. Through-the-scope balloon dilation for pyloric stenosis: long term results. *Gastrointest Endosc.* 1996;43:98–101.
- Solt J, Bajor J, Szabó M, Horváth OP. Long-term results of balloon catheter dilation for benign gastric outlet stenosis. *Endoscopy.* 2003;35:490–5.
- Misra SP, Dwivedi M. Long-term follow-up of patients undergoing balloon dilation for benign pyloric stenoses. *Endoscopy.* 1996;28:552–4.
- Kuwada SK, Alexander GL. Long-term outcome of endoscopic dilation of nonmalignant pyloric stenosis. *Gastrointest Endosc.* 1995;41:15–7.
- Peng CL, Lin HJ, Lo WC, Lai CR, Guo WS, Lee SD. Characteristics of patients with benign gastric outlet obstruction requiring surgery after endoscopic balloon dilation. *Am J Gastroenterol.* 1996;91:987–90.
- Kozarek RA, Botoman VA, Patterson DJ. Long-term follow-up in patients who have undergone balloon dilation for gastric outlet obstruction. *Gastrointest Endosc.* 1990;36:558–61.
- DiSario JA, Fennerty MB, Tietze CC, Hutson WR, Burt RW. Endoscopic balloon dilation for ulcer-induced gastric outlet obstruction. *Am J Gastroenterol.* 1994;89:868–71.
- Lam YH, Lau JY, Fung TM, Ng EK, Wong SK, Sung JJ. Endoscopic balloon dilation for benign gastric outlet obstruction with or without *Helicobacter pylori* infection. *Gastrointest Endosc.* 2004;60:229–33.
- Cheikh I, Younes R, Said Y, Chaabouni H, Chebbi F, Ben Ammar A. Peptic pyloroduodenal strictures treated by endoscopic balloon dilation and eradication of *Helicobacter pylori*. Results of a prospective study. *Tunis Med.* 2003;81(4):258–63.
- Nocca D, Aggarwal R, Blanc P, Gallix B, Di Mauro GL, Millat B, des De Seguin Hons C, Deneve E, Rodier JG, Tincani G, Pierredon MA, Fabre JM. Laparoscopic vertical banded gastroplasty. A multicenter prospective study of 200 procedures. *Surg Endosc.* 2007;21(6):870–4.
- Tevis S, Garren M, Gould J. Revisional surgery for failed vertical-banded gastroplasty. *Obes Surg.* 2011;21:1220–4.
- Fobi M, Lee H, Igwe D, Felahy B, James E, Stanczyk M, Fobi N. Band erosion: incidence, etiology, management and outcome after banded vertical gastric bypass. *Obes Surg.* 2011;11:1–9.
- Abu-abeid S, Szold A. Laparoscopic management of lap-band erosion. *Obes Surg.* 2001;11(1):87–9.
- Basa N, Dutson E, Lewis C, Derezin M, Han S, Mehran A. Laparoscopic transgastric removal of eroded adjustable band: a novel approach. *Surg Obes Relat Dis.* 2008;4:194–7.
- Go MR, Muscarella P, Needleman BJ, Cook CH, Melvin WS. Endoscopic management of stomal stenosis after Roux-en-Y gastric bypass. *Surg Endosc.* 2004;18(1):56–9.
- Vance PL, delange EE, Shaffer HA, Schirmer B. Gastric outlet obstruction following surgery for morbid obesity of fluoroscopically guided balloon dilation. *Radiology.* 2002;222(1):70–2.
- Csendes A, Maluenda F, Braghetto I, Schutte H, Burdiles P, Diaz JC. Prospective randomized study comparing three surgical techniques for the treatment of gastric outlet obstruction secondary to duodenal ulcer. *Am J Surg.* 1993;166(1):45.
- Tsai CH, Liou GJ, Liu CL, Pan JS, Lee JJ, Cheng SP, Liu TP. Surgical management of benign gastric outlet obstruction in the elderly. *Hepatogastroenterology.* 2012;59(117):1643–6.
- Al-Rashedy M, Dadibhai M, Shareif A, Khandelwal MI, Ballester P, Abid G, McCloy RF, Ammori BJ. Laparoscopic gastric bypass for gastric outlet obstruction is associated with smoother, faster recovery and shorter hospital stay compared with open surgery. *J Hepatobiliary Pancreat Surg.* 2005;12(6):474–8.
- Bergamaschi R, Marvik R, Thoresen JE, Ystgaard B, Johnsen G, Myrvold HE. Open versus laparoscopic gastrojejunostomy for palliation in advanced pancreatic cancer. *Surg Laparosc Endosc.* 1998;8(2):92–6.
- Choi YB. Laparoscopic gastrojejunostomy for palliation of gastric outlet obstruction in unresectable gastric cancer. *Surg Endosc.* 2002;169(11):1620–6.
- Arrangoiz R, Papavasiliou P, Singla S, Siripurapu V, Watson JC, Hoffman JP, Farma JM. Partial stomach-partitioning gastrojejunostomy and the success of this procedure in terms of palliation. *Am J Surg.* 2013;206(3):333–9.

35. Eguchi H, Yada K, Shibata K, Matsumoto T, Etoh T, Yasuda K, Inomata M, Shiraiishi N, Ohta M, Kitano S. Laparoscopic stomach-partitioning gastrojejunostomy is an effective palliative procedure to improve quality of life in patients with malignant gastroduodenal outlet obstruction. *Asian J Endosc Surg*. 2012;5(4):153–6.
36. Oida T, Mimatsu K, Kawasaki A, Kano H, Kuboi Y, Amano S. Modified devine exclusion with vertical stomach reconstruction for gastric outlet obstruction: a novel technique. *J Gastrointest Surg*. 2009;13(7):1226–32.
37. Van den Berg MW, Haijink S, Fockens P, Vleggaar FP, Dijkgraaf MGW, Siersma PD. First data on the evolution duodenal stent for palliative outlet obstruction (DUOLUTION study): a prospective trial. *Endoscopy*. 2013;45(3):174–81.
38. Dormann A, Meisner S, Verin N, Wenk Lang A. Self-expanding metal stents for gastroduodenal malignancies; systematic review of their clinical effectiveness. *Endoscopy*. 2004;36(6):543–50.
39. Mansoor H, Yusuf M. Outcomes of endoscopic pyloric stenting in malignant gastric outlet obstruction: a retrospective study. *BMC Res Notes*. 2013;6:280.
40. Cho YK. Clinical outcome of self-expandable metal stent and prognostic factors for stent patency in gastric outlet obstruction caused by gastric cancer. *Dig Dis Sci*. 2010;55(3):668–74.
41. Baron T. Expandable metal stents for the treatment of cancerous obstruction of the gastrointestinal tract. *New Engl J Med*. 2001;344(22):1681–7.
42. Woo SM, Kim DH, Lee WJ, Park KW, Park SJ, Han SS, Kim TH, Koh YH, Kim HB, Hong EK. Comparison of uncovered and covered stents for the treatment of malignant duodenal obstruction caused by pancreaticobiliary cancer. *Surg Endosc*. 2013;27(6):2031–9.
43. Maetani I, Mizumoto Y, Shigoka H, Omuta S, Saito M, Tokuhisa J, Morizane T. Placement of a triple-layered covered versus uncovered metallic stent for palliation of malignant gastric outlet obstruction: a multicenter randomized trial. *Dig Endosc*. 2013. doi:10.1111/den.12117.
44. Del Piano M, Ballare M, Montino F, Todesco A, Orsello M, Magnani C, Garello E. Endoscopy or surgery for malignant GI outlet obstruction? *Gastrointest Endosc*. 2005;61(3):421–6.
45. Hosono S, Ohtani H, Arimoto Y, Kanamiya Y. Endoscopic stenting versus surgical gastroenterostomy for palliation of malignant gastroduodenal obstruction: a meta-analysis. *J Gastroenterol*. 2007;42(4):283–90.
46. •• Khashab M, Alawad AS, Shin EJ, Kim K, Bourdel N, Singh VK, Lennon AM, Hutfless S, Sharaiha RZ, Amateau S, Okolo PI, Makary MA, Wolfgang C, Canto MI, Kalloo AN. Enteral stenting versus gastrojejunostomy for palliation of malignant gastric outlet obstruction. *Surg Endosc*. 2013;27(6):2068–75. *Very recent large, 10 year retrospective study of gastrojejunostomy versus endoscopic stenting for malignant gastric outlet obstruction*.
47. Roy A, Kim M, Christein J, Varadarajulu S. Stenting versus gastrojejunostomy for management of malignant gastric outlet obstruction: comparison of clinical outcomes and costs. *Surg Endosc*. 2012;26(11):3114–9.
48. Ly J, O'Grady G, Mittal A, Plank L, Windsor JA. A systematic review of methods to palliate malignant gastric outlet obstruction. *Surg Endosc*. 2010;24(2):290–7.
49. Jeurnink SM, Steyerberg EW, Hof GV, Van Eijck CH, Kuipers EJ, Siersema PD. Gastrojejunostomy versus stent placement in patients with malignant gastric outlet obstruction: a comparison in 95 patients. *J Surg Oncol*. 2007;96(5):389–96.
50. Jeurnink SM, Van Eijck CH, Steyerberg EW, Kuipers EJ, Siersema PD. Stent versus gastrojejunostomy for the palliation of gastric outlet obstruction: a systematic review. *BMC Gastroenterol*. 2007;8(7):18.
51. Zheng B, Wang X, Ma B, Tian J, Jiang L, Yang K. Endoscopic stenting versus gastrojejunostomy for palliation of malignant gastric outlet obstruction. *Dig Endosc*. 2012;24(2):71–8.
52. Maetani I, Akatsuka S, Ikeda M, Tada T, Ukita T, Nakamura Y, Nagao J, Sakai Y. Self-expandable metallic stent placement for palliation in gastric outlet obstructions caused by gastric cancer: a comparison with surgical gastrojejunostomy. *J Gastroenterol*. 2005;40(10):932–7.
53. No JH, Kim SW, Lim CH, Kim JS, Cho YK, Park JM, Lee IS, Choi MG, Choi KY. Long-term outcome of palliative therapy for gastric outlet obstruction caused by unresectable gastric cancer in patients with good performance status: endoscopic stenting versus surgery. *Gastrointest Endosc*. 2013;78(1):55–62.