



# Managing Post-traumatic Olfactory Disorders

Iordanis Konstantinidis<sup>1</sup>

Accepted: 29 September 2022 / Published online: 12 October 2022  
© The Author(s) 2022

## Abstract

**Purpose of Review** This study aims to summarize and critically review recent literature on management of post-traumatic olfactory dysfunction (PTOD) with emphasis on the diagnostic procedure and treatment options.

**Recent Findings** Magnetic resonance imaging and olfactory testing are the basis of the diagnostic procedure. Time of diagnosis is critical as the most improvement occurs within the first year after trauma. Olfactory training and oral steroids seem to be a relatively evidence-based therapeutic option but with non-optimal results. Surgery has a limited place in the management of PTOD. Promising future options could be the development of olfactory implants and transplantation of olfactory epithelium or stem cells.

**Summary** PTOD management is challenging as it has several pathogenetic mechanisms and relatively poor prognosis. Patients with olfactory impairment and head trauma have diminished quality of life, and increased risk for harmful events and development of depression. Thus, clinicians should not only focus to therapeutic options but equally to appropriate counseling to their patients in order to decrease risks of personal injury and improve their daily life.

**Keywords** Post-traumatic · Brain injury · Olfactory training · Steroids · Olfactory loss

## Introduction

Post-traumatic olfactory dysfunction (PTOD) along with post-infectious olfactory dysfunction (PIOD) and rhinosinusitis are the most common olfactory disorders in smell and taste special clinics. Its incidence varies with a range from 5 to 30% depending on the source of the data [1–3]. Often, this clinical entity remains undiagnosed and underestimated. This is because it includes a wide range of patients' profiles from people with mild injuries and mild olfactory dysfunction, which may run undetected, to people with multiple severe injuries where olfactory loss is not a priority for both patients and clinicians.

PTOD patients form a very inhomogeneous patients' group as a result of the different trauma mechanisms, different severity levels regarding hospital stay, olfactory

dysfunction (OD), co-morbidities etc., and different location of the olfactory system lesions. This makes every case of PTOD almost unique especially if we consider the psychological impact of trauma itself and/or the psychological consequences due to olfactory loss. The management of olfactory disorders due to trauma is a challenging procedure requiring in some cases a multidisciplinary approach.

## Pathophysiology

Understanding of the pathogenetic mechanisms of PTOD is crucial in order to properly plan a therapeutic strategy.

The mechanisms described are mainly four:

1. Conductive loss of olfactory function due to nasal airway blockage toward olfactory cleft (rare). Decreased nasal airstream toward the olfactory cleft can be resulted in nasal septum fractures, nasal septum hematoma, nasoethmoidal complex fractures, and more complex fractures such as Le Fort. In addition, secondary sinusitis can be developed due to abovementioned traumas leading to mucosal edema and inflammation obstructing the olfactory cleft [3, 4].

---

This article is part of the Topical Collection on *RHINOLOGY: Taste and Smell Disorders*

✉ Iordanis Konstantinidis  
jordan\_orl@hotmail.com

<sup>1</sup> 2nd Academic ORL Department, Papageorgiou Hospital, Aristotle University, Thessaloniki, Greece

2. Sensorineural loss due to olfactory nerve filament damage. Olfactory filaments can be directly damaged by fractures of skull base and indirectly by antero-posterior movement of the brain against the skull base, the so-called coup-contrecoup injuries. This type of injury can result in shearing and/or stretching of the olfactory filaments. In the latter case, edema of the filaments and collapse of the blood supply from the branches of anterior ethmoidal artery can lead to subsequent ischemia and axonal degeneration [3–5].
3. Sensorineural loss due to central brain lesions. Injury to any part of central component of the olfactory system can lead to OD. The injury's severity varies from brain edema to hematoma and contusion. Lesions in olfactory bulb, frontal lobe, and temporal lobe have the higher correlation with OD [3–6].
4. Sensorineural loss due to superficial siderosis (rare). Superficial siderosis of the central nervous system (CNS) is a rare condition causing OD as a late complication of brain trauma. It is caused by deposition of hemosiderin in the superficial layers of the CNS due to repeated chronic subarachnoid or intraventricular hemorrhage. This leads to an intracranial iron overload which is toxic for the olfactory nerves [7].

In clinical practice, physicians should keep in mind that the above-described mechanisms (Fig. 1) can be combined. Considering that medications given for the traumatic brain injury can possibly have a negative impact on olfaction (e.g., anticonvulsants), our diagnostic workup should be detailed and focused on the pathogenetic mechanisms.

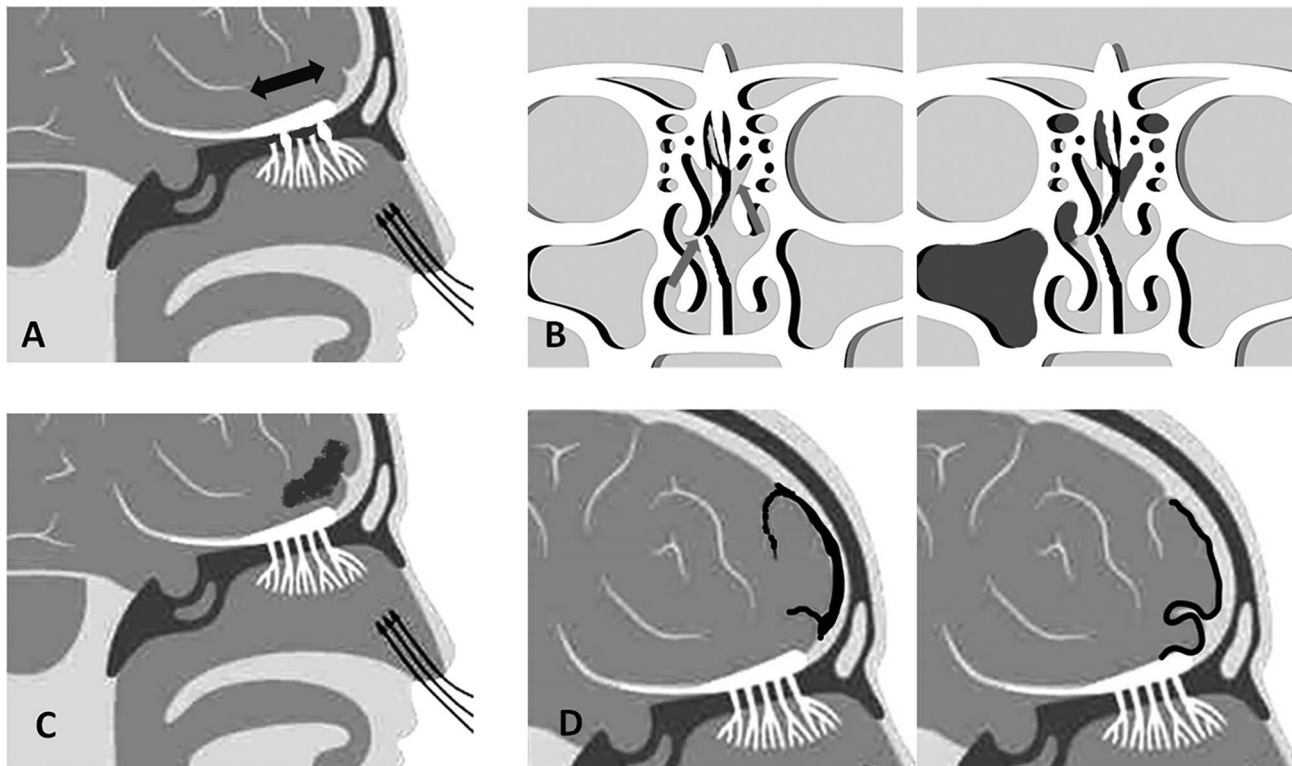
## Diagnosis

### History

A detailed history of the OD can provide significant information regarding the prognosis of a patient. The age seems to be a significant prognostic factor of recovery as younger patients present better olfactory test results [1, 8, 9].

The duration of OD is critical, as in the majority of studies the first year after trauma is the period of time where most of the recovery occurs with gradual decrease during the second year and a plateau of recovery likelihood within the next years with a very low possibility for further improvement [8–11].

Questions about the mechanism of trauma could help in the better understanding of patients' complaints



**Fig. 1** The four pathogenetic mechanisms of PTOD in schematic drawing. **A** Shearing or stretching of olfactory filaments (bidirectional arrow indicates the movement of brain against skull base in coup-contra coup injuries). **B** Conductive loss (left side) due to disturbed airstream

toward olfactory cleft (arrows) and/or (right side) secondary sinusitis blocking the olfactory cleft. **C** Central brain lesions. **D** Subarachnoid (left side) and subcortical (right side) brain siderosis (black areas indicate the areas of hemosiderin deposits)

especially in the absence of imaging findings. For example, the antero-posterior movement of the brain in relation to the skull base is commonly seen following motor vehicle accidents or ground-level falls to the occipital area. A cadaveric study indicated that frontal lobe retraction in a posterior direction from the olfactory bulb, regardless of angle from the skull base, is associated with high risk of olfactory nerve damage [12]. In addition, previous studies showed that an occipital injury is more likely to cause olfactory dysfunction than a frontal one [13, 14].

Subjective ratings of OD are always useful as they describe the degree of patients' complaints; however, these should always be accompanied by olfactory testing. Severity of the OD is also a prognostic factor and anosmia or hyposmia diagnosis should be mainly based on psychophysical testing as there is a discrepancy between test results and subjective ratings.

Patients should be asked to report other pre-existing olfactory deficits such as aging, neurodegenerative disorders, PIOD, rhinosinusitis, and medications. In addition, history of previous nasal surgery and head-and-neck radiotherapy should be taken into account as nasal mucosa dysfunction and scarring may have an additional negative effect.

Complaints of a metallic taste or of a clear rhinorrhea, symptoms which are suggestive of fractures at the anterior skull base, are important as they are highly related with OD [15].

History of hospitalization in an intensive care unit and peri-traumatic amnesia are indicators of more severe injury of the olfactory system [16]. In a study by Green et al., patients with amnesia lasting > 10 days had a six times higher possibility to have OD than patients without amnesia [17].

Traumatic brain injury (TBI) is associated with an increased risk of depressive symptoms [18]. In addition, OD regardless of the presence of TBI may lead to similar symptoms [19, 20]. A more recent study showed that about one-fourth to one-third of patients who lost their sense of smell showed depressive symptoms [21]. In conclusion, this relationship between OD, TBI, and depression creates a significant pool of patients requiring psychological assessment.

Finally, questions regarding other sensory systems should complete our history, as PTOD has been related with hearing loss (41%), tinnitus (22%), dizziness (14%), and visual disturbances (3%) [3, 22].

Specifically, late onset of hearing loss followed by anosmia even years after a head trauma should raise a suspicion of superficial siderosis as acoustic nerves are very sensitive to hemoglobin metabolic products and requires further investigation with an MRI [7].

## Physical Examination

Palpation of the face can help in the detection of nasal and more complex facial fractures. Bruising around the eyes (raccoon eyes) and the mastoid area (Battle's sign) are suggestive of skull base fractures [23]. Nasal endoscopy is mandatory as it can reveal a septal fracture, hematoma, evidence of sinusitis, and any other source of potential nasal blockage toward the olfactory cleft.

## Psychophysics

As subjective ratings of olfactory function are not reliable, diagnostic procedure should always include measurements of OD by means of psychophysical testing. Many tests are available, with the most widely used being the UPSIT test and the Sniffin' Sticks test. Both tests have large normative data and can distinguish hyposmia and anosmia with high specificity and sensitivity [24, 25]. Incidence rate for anosmia after TBI is relatively high and is highly correlated with the severity of the trauma [11].

Unfortunately, such tests do not exist for the assessment of qualitative disorders such as parosmia and phantosmia. Recently, a new test method developed the so-called Sniffin' Sticks Parosmia Test (SSParoT) which measures qualitative disorders based on the odors of the Sniffin' Sticks Identification subtest [26]. The test uses hedonic estimates of two oppositely valenced odors (pleasant and unpleasant) to assess hedonic range and direction. However, although initial results seem promising, the test needs further validation in large cohorts.

## Imaging

Imaging is mandatory in the diagnostic procedure of PTOD. Unfortunately, in multi-injured patients, often their initial imaging has not the optimal characteristics to assess properly the olfactory system or the neighboring structures. In such cases where initial scans are suggestive of injury but inconclusive, imaging dedicated to the olfactory areas of interest is indicated. High-resolution CT scan (thin-cut < 1 mm) without intravenous contrast for the assessment of anterior skull base, nasal cavities, and paranasal sinuses is the modality of choice [27].

Skull base fractures can be seen on a CT scan (fracture lines at the frontal, ethmoid, sphenoid, temporal, and occipital bone) or be highly suspected if post-traumatic fluid is observed in the mastoid or intracranial air is located adjacent to the skull base. A CT scan can also diagnose contusion of the brain detecting cortical lesions, and/or subarachnoid or intraventricular hemorrhage [27, 28].

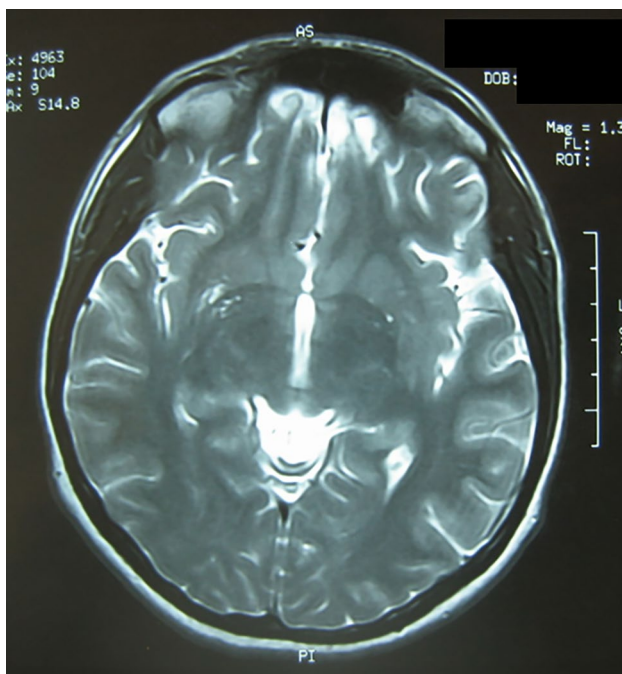
The assessment should always be completed with a magnetic resonance imaging (MRI) as it can demonstrate better

the entire olfactory system providing information regarding (1) the olfactory mucosa inflammation and the presence of mucosal inflammation in sinonasal cavities, (2) the integrity of olfactory bulbs (OBs) and orbitofrontal cortex (OFC) area, and (3) subtle cerebral lesions including intraparenchymal hematomas or contusion (Fig. 2) [29].

A basic MRI assessment should include 2-mm-thick T2-weighted images in fast spin echo (FSE) mode in the coronal plane as it provides the best anatomical olfactory tract overview, detection of parenchymal lesions, and can be used for OB volumetry. The examination covers all brain areas for detection of parenchymal contusions. In addition, both fluid-attenuated inversion recovery (FLAIR) sequence and hemosiderin-sensitive T2 sequence can be performed for this purpose.

A large body of the literature exist showing that OB volumes correlate with olfactory function [30, 31]. In T2-weighted FSE images, hypointense OBs surrounded by bright cerebrospinal fluid (CSF) are well seen within olfactory grooves and can be measured. OB volume measurements can be performed by means of special software providing significant information regarding prognosis. Specifically, a volume at baseline assessment of  $> 40$  cm is considered as a good prognostic factor [32••].

Recent data add the shape of OB as another factor of diagnostic value in PTOD patients' assessment. Yan et al. showed that an irregular OB shape was significantly more often observed in PTOD [33].



**Fig. 2** MRI of a 27-year-old female patient with anosmia after a car accident and frontal impact. Bilateral hemorrhagic regions in OFC areas can be seen

Finally, MRI is the only imaging modality to diagnose the rare condition of superficial siderosis with high sensitivity and specificity. T2-weighted sequences are exquisitely sensitive, presenting a well-defined hypointense rim that delineates usually most of the brain stem, cerebellum, some of the lower cranial nerves, and the fronto-polar, fronto-basal, and temporo-polar subarachnoid spaces [7].

## Malingering

The detection of malingerers is a crucial part of evaluation of PTOD patients as quite often they are involved in litigations with financial claims and/or application for invalidity pension due to injury. In general, malingerers tend to not report or decrease the number and intensity of symptoms related with concomitant nasal pathology giving a leading history toward OD due to craniofacial trauma [34].

During psychophysical testing, malingerers try to have a result close to 0 as they believe that this way it is clearer that there is no residual olfactory function [35]. Patients with an extremely low score in psychophysical test and application for a consultation which will be used in legal issues should be suspected for malingering. This is because the forced choice nature of the most widely used tests allows even anosmic patients to have a certain number of correct answers after random guesses. In addition, the examiner can use additional trigeminal stimulants or focused on the items with strong trigeminal component to indicate whether or not the patient can identify them. Again, patients trying to maximize their OD may report that they are unable to identify trigeminal stimulants, although their trigeminal system is intact.

However, a medical consultation cannot rely only on psychophysical tests as they are based on patients' subjective response. The above-described findings in a psychophysical test are only suggestive of malingering and although they raise a suspicion for the examiner, they are not an objective proof of it.

Additional information can be obtained by imaging assessment. Absence of facial fractures and brain lesions in areas like frontal and temporal lobes and olfactory bulbs decrease significantly the possibility of anosmia. A scoring system of MRI has been developed predicting anosmia with a relatively high accuracy based on bilaterality of brain lesions, specific location of lesions, and patient's age [36].

Objective methods to detect residual olfactory function like electro-olfactogram (EOG) and event-related potentials of the brain exist and have the ability to show activation of the olfactory system after stimulation with odorants, without patient's response [37, 38]. However, these methods are available in a few centers and present certain limitations. They require complex and usually expensive equipment and a considerable subject cooperation as a patient should be



sitting very still during a recording session. Thus, even these methods are vulnerable to malingering.

Despite all the above methods to detect malingering, a medical consultation cannot be based strictly in any kind of measurement. It should reflect the general feeling of the examiner who spent time with the patient and knows the way of answering, his or her reactions during testing, and even the face reactions when a bad or strong trigeminal odor was presented.

## Treatment

### Steroids

The anti-inflammatory effect of steroids has been shown in animal studies where an improved neuronal recovery was found following olfactory nerve transection [39•]. Steroids suppressed the inflammatory reaction and reduced the glial scar formation. Scar tissue formation creates a barrier between regenerated olfactory neurons and the olfactory bulb preventing their reconnection.

In Fujii et al.'s study, patients with an early steroid treatment with intranasal injection had higher olfactory improvement [40]. In addition, patients with olfactory improvement were significantly younger than those who remained unchanged. This observation might be related to an age-related decreased proliferation of olfactory neurons. Aging can also indirectly affect the recovery via a reduced resistance of olfactory mucosa to inflammatory effects and/or reduced adrenergic innervation of the microscopic vasculature around the olfactory bulb and mucosa.

The use of nasal steroids is a common practice by clinicians in the treatment of olfactory loss, regardless of etiology. The literature which is in support of their use is mainly based on results coming from CRS-related OD [41, 42]. In non-CRS-related OD, evidence is limited and non-conclusive. There is a lack of high-quality studies proving efficacy of either topical or oral steroids for sensorineural OD, with only one level 1 evidence study suggesting their use [43]. For topical steroids, this may be related to the difficulty to apply steroids properly in the olfactory cleft.

Most of the evidence regarding the beneficial effect of steroids on olfaction comes from studies with oral steroids [44, 45]. However, the positive response of some patients to systemic treatment could be due to a pre-existing inflammatory background in their nasal cavities.

Recent research provided evidence that olfactory gene expression may also be influenced by this systemic therapy [46]. Unfortunately, the existing studies do not provide strong evidence on the positive effect of steroid treatment on PTOD. However, it seems reasonable to prescribe a course of oral steroids in patients with a short history of the disease

or inflammatory background in the upper airway. This treatment, if chosen, should be given after a thorough discussion with the patient about its potential adverse effects.

### Olfactory Training

Previous meta-analyses provided data establishing olfactory training as a treatment option on OD as it has a significant beneficial effect [47, 48]. Specifically, for trauma cases, a recent meta-analysis demonstrated that 36.31% of post-traumatic patients achieved significant improvement after olfactory training within 8 months [49]. Compared to the percentage of spontaneous recovery within 74 months of follow-up, patients with PTOD receiving olfactory training seem to have a relatively higher recovery rate within a short-term treatment duration. However, clinicians should inform patients that PTOD responds better to olfactory training and had higher rates of olfactory improvement compared with PTOD. Although olfactory training is a choice of treatment for olfactory disorders due to head trauma, the recovery rate is relatively low.

Olfactory training combined with local or systematic steroid has been used by several authors for the treatment of PTOD [50, 51]. The percentage of patients with combined treatment and improvement was between 33 and 50%, which is higher than that in patients following only olfactory training. However, the positive effect of steroids always raises questions about how much reflects an improvement of concomitant inflammation or acts on olfactory neurons directly.

Hummel et al. showed by means of EOG from olfactory epithelium that patients following olfactory training had higher recordings, suggesting a peripheral effect of olfactory training in the olfactory system [52•]. Other authors showed central effects of olfactory training with increased cortical thickness in olfactory processing areas of the brain. Specifically, for PTOD, further studies suggested that the benefit in this group could be due to central functional changes rather than peripheral [53, 54]. Considering that PTOD includes a variety of patients with peripheral and central lesions, the positive effect of olfactory training in both ways (central and peripheral) makes it a very suitable treatment option.

### Surgery

Surgery can be offered at an acute setting when a septal hematoma or a fractured septum with open trauma occurs and requires immediate reconstruction. At the second stage, rhinosinusitis due to blocked sinuses as a consequence of the trauma can lead to OD. This dysfunction may be a result of olfactory cleft obstruction due to edema and inflamed mucosa (conductive loss) and/or inflammatory gradual destruction of the structure and function of olfactory epithelium [55]. When conservative treatment with steroids

and antibiotics fails, then endoscopic sinus surgery is the option of choice as it benefits olfaction by controlling the underlying disease through better ventilation of the paranasal sinuses and easier application of topical therapies [56].

In addition, there is evidence that operations like septoplasty and septorhinoplasty at the second stage after trauma may improve olfactory function by facilitating airflow toward the olfactory cleft and local application of medications [57].

Finally, a limited number of patients with intense parosmias or phantosmias unresponsive to conservative treatment and significant impact on their quality of life may be candidates for endoscopic surgical removal of the olfactory epithelium.

Persistent parosmia or phantosmia may be initially treated by local application of cocaine or xylocaine in the olfactory cleft [58]. This can be diagnostic, detecting the most affected side, and therapeutic. Anesthetizing the olfactory mucosa provides symptom-free intervals helping patients at this time to enrich their diet and food intake. However, this effect lasts for a short period of time and needs repeated application. In case of conservative treatment failure, then options like surgery on the olfactory cleft may be offered.

This kind of surgery has been shown to be effective to manage phantosmia in some small case series [59, 60]. However, before such a decision, a surgeon should extensively explain to the patient the risks associated with surgical removal of olfactory epithelium (e.g., CSF leak) and the potential benefits.

## Other Treatment Options

A study by Jiang et al. showed a promising effect of zinc gluconate in the treatment of PTOD including 35 patients receiving only zinc and a recovery rate of 25%, and a group of 39 patients having combined treatment of zinc and steroids and a recovery rate of 28% [61]. The hypothesis behind this was that zinc may be effective in regenerating olfactory receptor cells [62]. However, olfactory bulb volumes did not improve in zinc groups and no further data from other authors confirmed the above results.

Vitamin A seems to be involved in the regeneration of olfactory receptor neurons. There is evidence that local application of vitamin A (10,000 IU per day) when combined with olfactory training had better improvement compared with training alone in patients with PIOD [63]. Although this was not the case in PTOD patients, the fact that discrimination score showed significant improvement indicates that topical application of vitamin A deserves further attention as a therapeutic option.

Recent research studied in animals the use of N-acetylcysteine (100 mg/kg twice a day) after acute olfactory

neuronal injury, providing promising results [64]. The authors found a neuroprotective effect of N-acetylcysteine, with significant decrease in apoptosis of olfactory neurons in the treatment group.

Yan et al. reported a multicentric, prospective, randomized controlled trial of 110 patients undergoing transphenoidal surgery and found omega-3 supplementation to be protective against olfactory loss [65]. Although this study is on patients suffering from skull base tumors, the surgery required resembles a peripheral trauma of the olfactory system and needs further attention.

Oral administration of theophylline has demonstrated some improvements in olfaction. This may be a result of increased levels of cyclic adenosine monophosphate and cyclic guanosine monophosphate in nasal secretions, which are lower in hyposmic patients [66]. However, in this study, the authors, although included PTOD patients, did not report their results according to different etiologies of OD.

## Counseling

Patients with OD face problems in their everyday life that affect significantly their quality of life. The loss of smell can alter their nutritional status as patients tend to reject foods with unpleasant odors. In addition, the enjoyment of food that patients continue to eat is impaired. The role of the physician is to broaden the spectrum of diet and to make food more interesting in terms of enjoyment. Combination of foods with different colors, texture, and temperature can help in this direction. Addition of spices can trigger trigeminal nerve giving an extra flavor in patients' food.

OD also has an impact on interpersonal relations. Many patients are insecure about their personal hygiene, avoiding friends and sexual partners [19, 21]. Thus, psychological aid in certain cases seems mandatory.

Safety in everyday life is a very important issue especially for patients who live alone. The danger of a fire is relatively high and gas detectors are mandatory as 45% of anosmic patients had at least one cooking-related hazardous event [67]. Labeling of foods and special attention to expiry dates can help to avoid eating spoiled food.

## Future Directions

### Stem Cells

Cell-based therapy may have a potential role for the treatment of OD [68]. Recently, an animal study in rodents by Kurtenbach et al. showed a positive effect of olfactory stem cell treatment [69]. Specifically, the treatment led to the development of olfactory neurons in the OE, with the projection of their axons connected into the OB. Although the

available data are coming from animal models, study results like this where transplantation of tissue-specific stem cells resulted in a possible functional restoration of the olfactory epithelium are really promising. However, this kind of treatment may have a potential role in post-traumatic cases without central lesions as it targets the periphery of the olfactory system and the connection between OE and OB. Future studies have to face challenges regarding the safety of these treatment options, particularly with regard to potential of carcinogenesis.

### Olfactory Epithelium Transplantation

There were also efforts to transplant olfactory mucosa in different locations of the CNS including the OB. Since 1983, animal studies showed that olfactory mucosa of neonatal rats can be transplanted in the brain cortex and the fourth ventricle with the neurogenesis remaining despite the ectopic position of the mucosa [70].

Olfactory mucosa could also be transplanted into the OB with a relatively high survival rate (83%) and integrity of its structure [71]. However, functional synapses with the bulb could not be demonstrated. Overall, it has been shown that olfactory mucosa can be transplanted in various parts of the cortex as well including the fourth ventricle and the OB.

Although olfactory mucosa implants survived in different brain locations, the lack of functional connectivity does not currently provide convincing evidence for future treatment of post-traumatic cases with central brain lesions.

### Implants

According to Besser et al., approximately one-third of patients in their study considered an olfactory implant as a therapeutic option [72]. Suitable candidates for it could be selected patients with a high degree of complaints and failure of conventional methods of olfactory rehabilitation, relatively low olfactory test scores, and people with professions requiring olfactory function (e.g., chefs, wine tasters, etc.). Animal studies showed that direct stimulation of the OB can reproduce spatial patterns of odorant-induced neuronal activity [73]. In humans, both subdural and transthemoid electrical stimulation of the OB could induce perception of smell [74]. There are currently described surgical techniques in cadavers for olfactory implantation in humans in order to avoid a transcranial approach [75]. An olfactory implant could be a solution for PTOD patients with integrity of OBs, for example, complete shearing of the olfactory filaments at the skull base. Olfactory implantation undoubtedly deserves more research efforts first to produce a feasible electrode array and then to find out the way to place it along the OB safely.

### Conclusions

PTOD includes an inhomogeneous group of patients with a variety of injuries involving the periphery and the central compartments of the olfactory system. Diagnosis should be based on focused history, olfactory testing, and imaging (CT scan and MRI). Treatment options are limited with olfactory training and steroids being the more effective. Prognosis is still relatively low depending on the severity of injury with recovery occurring mainly during the first year post-trauma. However, cases of late improvement exist and clinicians should encourage patients to follow their treatment scheme regardless of the timing of the baseline assessment.

**Funding** Open access funding provided by HEAL-Link Greece.

### Declarations

**Conflict of Interest** The author declares no competing interests.

**Human and Animal Rights and Informed Consent** The studies relevant to this review that were performed by the author have been approved by the Aristotle University Review Board and have been performed in accordance with the ethical standards as laid down in the Declaration of Helsinki and its later amendments or comparable ethical standards.

**Open Access** This article is licensed under a Creative Commons Attribution 4.0 International License, which permits use, sharing, adaptation, distribution and reproduction in any medium or format, as long as you give appropriate credit to the original author(s) and the source, provide a link to the Creative Commons licence, and indicate if changes were made. The images or other third party material in this article are included in the article's Creative Commons licence, unless indicated otherwise in a credit line to the material. If material is not included in the article's Creative Commons licence and your intended use is not permitted by statutory regulation or exceeds the permitted use, you will need to obtain permission directly from the copyright holder. To view a copy of this licence, visit <http://creativecommons.org/licenses/by/4.0/>.

### References

Papers of particular interest, published recently, have been highlighted as:

- Of importance
- Of major importance

1. Bratt M, Skandsen T, Hummel T, Moen KG, Vik A, Nordgård S, Helvik AS. Frequency and prognostic factors of olfactory dysfunction after traumatic brain injury. *Brain Inj.* 2018;32(8):1021–7. <https://doi.org/10.1080/02699052.2018.1469043>.
2. Fonteyn S, Huart C, Deggouj N, Collet S, Eloy P, Rombaux P. Non-sinonasal-related olfactory dysfunction: a cohort of 496 patients. *Eur Ann Otorhinolaryngol Head Neck Dis.* 2014;131(2):87–91. <https://doi.org/10.1016/j.anorl.2013.03.006>.
3. Howell J, Costanzo RM, Reiter ER. Head trauma and olfactory function. *World J Otorhinolaryngol Head Neck Surg.* 2018;14(1):39–45. <https://doi.org/10.1016/j.wjorl.2018.02.001>.

4. Coelho DH, Costanzo RM. Posttraumatic olfactory dysfunction. *Auris Nasus Larynx*. 2016;43(2):137–43. <https://doi.org/10.1016/j.anl.2015.08.006>.
5. Logan M, Kapoor S, Peterson L, Oliveira M, Han DY. Mechanism of olfactory deficit in neurotrauma and its related affective distress: a narrative review. *World J Psychiatry*. 2021 Dec 19;11(12):1259–1266. <https://doi.org/10.5498/wjp.v11.i12.1259>.
6. Marin C, Langdon C, Alobid I, Mullol J. Olfactory dysfunction in traumatic brain injury: the role of neurogenesis. *Curr Allergy Asthma Rep*. 2020;9(20):55. <https://doi.org/10.1007/s11882-020-00949-x>.
7. Vadalà R, Giugni E, Pezzella FR, Sabatini U, Bastianello S. Progressive sensorineural hearing loss, ataxia and anosmia as manifestation of superficial siderosis in post traumatic brain injury. *Neurol Sci*. 2013;34(7):1259–62. <https://doi.org/10.1007/s10072-012-1208-5>.
8. Reden J, Mueller A, Mueller C, Konstantinidis I, Frasnelli J, Landis BN, Hummel T. Recovery of olfactory function following closed head injury or infections of the upper respiratory tract. *Arch Otolaryngol Head Neck Surg*. 2006;132(3):265–9. <https://doi.org/10.1001/archotol.132.3.265>.
9. Welge-Lüssen A, Hilgenfeld A, Meusel T, Hummel T. Long-term follow-up of posttraumatic olfactory disorders. *Rhinology*. 2012;50(1):67–72. <https://doi.org/10.4193/Rhino11.141>.
10. AbdelBari Mattar M, El Adle H. Prognostic factors for olfactory dysfunction in adult mild head trauma. *World Neurosurg*. 2020;141:e545–52. <https://doi.org/10.1016/j.wneu.2020.05.232>.
11. Gudziol V, Hoenck I, Landis B, Podlesek D, Bayn M, Hummel T. The impact and prospect of traumatic brain injury on olfactory function: a cross-sectional and prospective study. *Eur Arch Otorhinolaryngol*. 2014;271(6):1533–40. <https://doi.org/10.1007/s00405-013-2687-6>.
12. Tomii M. Strength testing of the human olfactory nerve at the frontal skull base. *Neurosurg Rev*. 2012;35(4):555–60; discussion 560–1. <https://doi.org/10.1007/s10143-012-0378-1>.
13. Doty RL, Yousem DM, Pham LT, Kreshak AA, Geckle R, Lee WW. Olfactory dysfunction in patients with head trauma. *Arch Neurol*. 1997;54:1131e1140.
14. Zusho H. Posttraumatic anosmia. *Arch Otolaryngol*. 1982;108:90e92.
15. Gudziol V, Marschke T, Reden J, Hummel T. Impact of anterior skull base fracture on lateralized olfactory function. *Rhinology*. 2020;58(1):45–50. <https://doi.org/10.4193/Rhin18.092>.
16. Konstantinidis I, Tsakiridou E, Bekiaridou P, Kazantzidou C, Konstantinidis J. Use of olfactory training in post-traumatic and postinfectious olfactory dysfunction. *Laryngoscope*. 2013;123(12):E85–90. <https://doi.org/10.1002/lary.24390>.
17. Green P, Rohling ML, Iverson GL, Gervais RO. Relationships between olfactory discrimination and head injury severity. *Brain Inj*. 2003;17(6):479–96. <https://doi.org/10.1080/0269905031000070242>.
18. Logan M, Kapoor S, Peterson L, Oliveira M, Han DY. Mechanism of olfactory deficit in neurotrauma and its related affective distress: a narrative review. *World J Psychiatry*. 2021;11(12):1259–66. <https://doi.org/10.5498/wjp.v11.i12.1259>.
19. Kamrava SK, Tavakol Z, Talebi A, Farhadi M, Jalessi M, Hosseini SF, Amini E, Chen B, Hummel T, Alizadeh R. A study of depression, partnership and sexual satisfaction in patients with post-traumatic olfactory disorders. *Sci Rep*. 2021;11(1):20218. <https://doi.org/10.1038/s41598-021-99627-9>.
20. Sabiniewicz A, Hoffmann L, Haehner A, Hummel T. Symptoms of depression change with olfactory function. *Sci Rep*. 2022;12(1):5656. <https://doi.org/10.1038/s41598-022-09650-7>.
21. Croy I, Nordin S, Hummel T. Olfactory disorders and quality of life—an updated review. *Chem Senses*. 2014;39(3):185–94. <https://doi.org/10.1093/chemse/bjt072>.
22. Costanzo RM, Reiter RJ, Yelverton JC. Smell and taste. In: Zasler ND, Katz DI, Zafonte RD, eds. *Brain injury medicine: principles and practice*. New York, NY: Demos; 2012:794e808.
23. Bächli H, Leiggenger C, Gawelin P, Audigé L, Enblad P, Zeilhofer HF, Hirsch J, Buitrago-Téllez C. Skull base and maxillofacial fractures: two centre study with correlation of clinical findings with a comprehensive craniofacial classification system. *J Craniomaxillofac Surg*. 2009;37(6):305–11. <https://doi.org/10.1016/j.jcms.2009.01.008>.
24. Oleszkiewicz A, Schriever VA, Croy I, Hähner A, Hummel T. Updated Sniffin' Sticks normative data based on an extended sample of 9139 subjects. *Eur Arch Otorhinolaryngol*. 2019;276(3):719–28. <https://doi.org/10.1007/s00405-018-5248-1>.
25. Doty RL, Frye RE, Agrawal U. Internal consistency reliability of the fractionated and whole University of Pennsylvania Smell Identification Test. *Percept Psychophys*. 1989;45(5):381–4. <https://doi.org/10.3758/bf03210709>.
26. Liu DT, Welge-Lüssen A, Besser G, Mueller CA, Renner B. Assessment of odor hedonic perception: the Sniffin' Sticks parosmia test (SSParoT). *Sci Rep*. 2020;10(1):18019. <https://doi.org/10.1038/s41598-020-74967-0>.
27. Dreizin D, Sakai O, Champ K, Gandhi D, Aarabi B, Nam AJ, Morales RE, Eisenman DJ. CT of skull base fractures: classification systems, complications, and management. *Radiographics*. 2021;41(3):762–82. <https://doi.org/10.1148/rg.2021200189>.
28. Faried A, Halim D, Widjaya IA, Badri RF, Sulaiman SF, Arifin MZ. Correlation between the skull base fracture and the incidence of intracranial hemorrhage in patients with traumatic brain injury. *Chin J Traumatol*. 2019;22(5):286–9. <https://doi.org/10.1016/j.cjtee.2019.05.006>.
29. Lötsch J, Ultsch A, Eckhardt M, Huart C, Rombaux P, Hummel T. Brain lesion-pattern analysis in patients with olfactory dysfunctions following head trauma. *Neuroimage Clin*. 2016;21(11):99–105. <https://doi.org/10.1016/j.nicl.2016.01.011>.
30. Buschhüter D, Smitka M, Puschmann S, Gerber JC, Witt M, Abolmaali ND, Hummel T. Correlation between olfactory bulb volume and olfactory function. *Neuroimage*. 2008;42:498–502. <https://doi.org/10.1016/j.neuroimage.2008.05.004>.
31. Mazal PP, Haehner A, Hummel T. Relation of the volume of the olfactory bulb to psychophysical measures of olfactory function. *Eur Arch Oto-Rhino-Laryngol*. 2016;273:1–7. <https://doi.org/10.1007/s00405-014-3325-7>.
32. Rombaux P, Huart C, Deggouj N, Duprez T, Hummel T. Prognostic value of olfactory bulb volume measurement for recovery in postinfectious and posttraumatic olfactory loss. *Otolaryngol Head Neck Surg*. 2012;147(6):1136–41. <https://doi.org/10.1177/0194599812459704>. **This study confirms the value of measuring the size of olfactory bulb in smell disorders and provides data regarding its prognostic value.**
33. Yan X, Joshi A, Zang Y, Assunção F, Fernandes HM, Hummel T. The shape of the olfactory bulb predicts olfactory function. *Brain Sci*. 2022;18;12(2):128. <https://doi.org/10.3390/brainsci12020128>.
34. Doty RL. Psychophysical testing of smell and taste function. *Handb Clin Neurol*. 2019;164:229–46. <https://doi.org/10.1016/B978-0-444-63855-7.00015-0>.
35. Doty RL, Crastnopol B. Correlates of chemosensory malingering. *Laryngoscope*. 2010;120(4):707–11. <https://doi.org/10.1002/lary.20827>.
36. Lötsch J, Reither N, Bogdanov V, Hähner A, Ultsch A, Hill K, Hummel T. A brain-lesion pattern based algorithm for the diagnosis of posttraumatic olfactory loss. *Rhinology*. 2015;53(4):365–70. <https://doi.org/10.4193/Rhino15.010>.
37. Mignot C, Schunke A, Sinding C, Hummel T. Olfactory adaptation: recordings from the human olfactory epithelium. *Eur Arch Otorhinolaryngol*. 2022;279(7):3503–10. <https://doi.org/10.1007/s00405-021-07170-0>.



38. Arpaia P, Cataldo A, Crisculo S, De Benedetto E, Masciullo A, Schiavoni R. Assessment and scientific progresses in the analysis of olfactory evoked potentials. *Bioengineering (Basel)*. 2022;9(6):252. <https://doi.org/10.3390/bioengineering9060252>.
39. Kobayashi M, Costanzo RM. Olfactory nerve recovery following mild and severe injury and the efficacy of dexamethasone treatment. *Chem Senses*. 2009;34(7):573–80. <https://doi.org/10.1093/chemse/bjp038>. **This article contains experimental data from histological sections in mice proving the effect of dexamethasone to olfactory nerve injury.**
40. Fujii M, Fukazawa K, Takayasu S, Sakagami M. Olfactory dysfunction in patients with head trauma. *Auris Nasus Larynx*. 2002;29(1):35–40. [https://doi.org/10.1016/s0385-8146\(01\)00118-3](https://doi.org/10.1016/s0385-8146(01)00118-3).
41. Alobid I, Benítez P, Cardelús S et al. Oral plus nasal corticosteroids improve smell, nasal congestion, and inflammation in sinonasal polyposis. *Laryngoscope*. 2014;124(1):50–6. <https://doi.org/10.1002/lary.24330>
42. Chong LY, Head K, Hopkins C, Philpott C, Schilder AGM, Burton MJ. Intranasal steroids versus placebo or no intervention for chronic rhinosinusitis. *Cochrane Database Syst Rev*. 2016;4(4):CD011996. <https://doi.org/10.1002/14651858.CD011996.pub2>.
43. Yan CH, Overdevest JB, Patel ZM. Therapeutic use of steroids in non-chronic rhinosinusitis olfactory dysfunction: a systematic evidence-based review with recommendations. *Int Forum Allergy Rhinol*. 2019;9(2):165–76. <https://doi.org/10.1002/alar.22240>.
44. Schriever VA, Merkonidis C, Gupta N, Hummel C, Hummel T. Treatment of smell loss with systemic methylprednisolone. *Rhinology*. 2012;50(3):284–9. <https://doi.org/10.4193/Rhino11.207>.
45. Jiang RS, Wu SH, Liang KL, Shiao JY, Hsin CH, Su MC. Steroid treatment of posttraumatic anosmia. *Eur Arch Otorhinolaryngol*. 2010;267(10):1563–7. <https://doi.org/10.1007/s00405-010-1240-0>.
46. Tian J, Pinto JM, Xin Y, et al. Dexamethasone affects mouse olfactory mucosa gene expression and attenuates genes related to neurite outgrowth. *International Forum of Allergy and Rhinology*. 2015;5(10):907–18. <https://doi.org/10.1002/alar.21586>.
47. Sorokowska A, Drechsler E, Karwowski M, Hummel T. Effects of olfactory training: a meta-analysis. *Rhinology*. 2017;55(1):17–26. <https://doi.org/10.4193/Rhino16.195>.
48. Kattar N, Do TM, Unis GD, Migneron MR, Thomas AJ, McCoul ED. Olfactory training for postviral olfactory dysfunction: systematic review and meta-analysis. *Otolaryngol Head Neck Surg*. 2021;164(2):244–54. <https://doi.org/10.1177/0194599820943550>.
49. Huang T, Wei Y, Wu D. Effects of olfactory training on posttraumatic olfactory dysfunction: a systematic review and meta-analysis. *Int Forum Allergy Rhinol*. 2021;11(7):1102–12. <https://doi.org/10.1002/alar.22758>.
50. Nguyen TP, Patel ZM. Budesonide irrigation with olfactory training improves outcomes compared with olfactory training alone in patients with olfactory loss. *Int Forum Allergy Rhinol*. 2018;8:977–81.
51. Bratt M, Moen KG, Nordgård S, Helvik AS, Skandsen T. Treatment of posttraumatic olfactory dysfunction with corticosteroids and olfactory training. *Acta Otolaryngol*. 2020;140:761–7.
52. Hummel T, Stupka G, Haehner A, Poletti SC. Olfactory training changes electrophysiological responses at the level of the olfactory epithelium. *Rhinology*. 2018;56(4):330–335. <https://doi.org/10.4193/Rhino17.163>. **This study provides evidence that olfactory training has an effect in the peripheral olfactory system and not only in central processes.**
53. Aïn Al S, Poupon D, Héту S, Mercier N, Stefener J, Frasnelli J. Smell training improves olfactory function and alters brain structure. *Neuroimage*. 2019;189:45–54. <https://doi.org/10.1016/j.neuroimage.2019.01.008>.
54. Pellegrino R, Han P, Reither N, Hummel T. Effectiveness of olfactory training on different severities of posttraumatic loss of smell. *Laryngoscope*. 2019;129(8):1737–43. <https://doi.org/10.1002/lary.27832>.
55. Konstantinidis I, Witt M, Kaidoglou K, Constantinidis J, Gudziol V. Olfactory mucosa in nasal polyposis: implications for FESS outcome. *Rhinology*. 2010;48(1):47–53. <https://doi.org/10.4193/Rhin09.102>.
56. Zhao R, Chen K, Tang Y. Olfactory changes after endoscopic sinus surgery for chronic rhinosinusitis: a meta-analysis. *Clin Otolaryngol*. 2021;46(1):41–51. <https://doi.org/10.1111/coa.13639>.
57. Grabosky A, Mackers P, Langdon C, Alobid I. Change in olfactory function after septoplasty. A systematic review and meta-analysis. *Rhinology*. 2021;59(2):144–50. <https://doi.org/10.4193/Rhin20.252>.
58. Leopold DA, Hornung DE. Olfactory cocainization is not an effective long-term treatment for phantosmia. *Chem Senses*. 2013;38(9):803–6. <https://doi.org/10.1093/chemse/bjt047>.
59. Leopold DA, Loechl TA, Schwob JE. Long-term follow-up of surgically treated phantosmia. *Arch Otolaryngol Head Neck Surg*. 2002;128(6):642–7. <https://doi.org/10.1001/archotol.128.6.642>.
60. Morrissey DK, Pratap U, Brown C, Wormald PJ. The role of surgery in the management of phantosmia. *Laryngoscope*. 2016;126(3):575–8. <https://doi.org/10.1002/lary.25647>.
61. Jiang RS, Twu CW, Liang KL. Treatment of traumatic anosmia. *Otolaryngol-Head Neck Surg*. 2015;152(5):954–8. <https://doi.org/10.1177/0194599815571272>.
62. Aiba T, Sugiura M, Mori J, Matsumoto K, Tomiyama K, Okuda F, Nakai Y. Effect of zinc sulfate on sensorineural olfactory disorder. *Acta Otolaryngol Suppl*. 1998;538:202–4. <https://doi.org/10.1080/00016489850182936>.
63. Hummel T, Whitcroft KL, Rueter G, Haehner A. Intranasal vitamin A is beneficial in post-infectious olfactory loss. *Eur Arch Otorhinolaryngol*. 2017;274(7):2819–25. <https://doi.org/10.1007/s00405-017-4576-x>.
64. Goncalves S, Goldstein BJ. Acute N-acetylcysteine administration ameliorates loss of olfactory neurons following experimental injury in vivo. *Anat Rec (Hoboken)*. 2020;303(3):626–33. <https://doi.org/10.1002/ar.24066>.
65. Yan CH, Rathor A, Krook K, Ma Y, Rotella MR, Dodd RL, Hwang PH, Nayak JV, Oyesiku NM, DelGaudio JM, Levy JM, Wise J, Wise SK, Patel ZM. Effect of omega-3 supplementation in patients with smell dysfunction following endoscopic sellar and parasellar tumor resection: a multicenter prospective randomized controlled trial. *Neurosurgery*. 2020;87(2):E91–8. <https://doi.org/10.1093/neuros/nyz559>.
66. Henkin RI, Velicu I, Schmidt L. An open-label controlled trial of theophylline for treatment of patients with hyposmia. *Am J Med Sci*. 2009;337:396–406. <https://doi.org/10.1097/MAJ.0b013e3181914a97>.
67. Santos DV, Reiter ER, DiNardo LJ, Costanzo RM. Hazardous events associated with impaired olfactory function. *Arch Otolaryngol Head Neck Surg*. 2004;130(3):317–9. <https://doi.org/10.1001/archotol.130.3.317>.
68. Marin C, Langdon C, Alobid I, Mullol J. Olfactory dysfunction in traumatic brain injury: the role of neurogenesis. *Curr Allergy Asthma Rep*. 2020;20(10):55. <https://doi.org/10.1007/s11882-020-00949-x>.
69. Kurtenbach S, Goss GM, Goncalves S, Choi R, Hare JM, Chaudhari N, Goldstein BJ. Cell-based therapy restores olfactory function in an inducible model of hyposmia. *Stem Cell Reports*. 2019;12(6):1354–65. <https://doi.org/10.1016/j.stemcr.2019.05.001>.
70. Morrison EE, Graziadei PP. Transplants of olfactory mucosa in the rat brain I. A light microscopic study of transplant organization. *Brain Res*. 1983;279(1–2):241–5. [https://doi.org/10.1016/0006-8993\(83\)90184-1](https://doi.org/10.1016/0006-8993(83)90184-1).

71. Costanzo RM, Yagi S. Olfactory epithelial transplantation: possible mechanism for restoration of smell. *Curr Opin Otolaryngol Head Neck Surg.* 2011;19(1):54–7. <https://doi.org/10.1097/MOO.0b013e328341e242>.
72. Besser G, Liu DT, Renner B, Hummel T, Mueller CA. Olfactory implant: demand for a future treatment option in patients with olfactory dysfunction. *Laryngoscope.* 2019;129(2):312–6. <https://doi.org/10.1002/lary.27476>.
73. Zhang G, Zhang JH, Feng J, Li Q, Wu X, Qin X. Electrical stimulation of olfactory bulb downregulates RGMA expression after ischemia/reperfusion injury in rats. *Brain Res Bull.* 2011;86(3–4):254–61. <https://doi.org/10.1016/j.brainresbull.2011.08.002>.
74. Holbrook EH, Puram SV, See RB, Tripp AG, Nair DG. Induction of smell through transetmoid electrical stimulation of the olfactory bulb. *Int Forum Allergy Rhinol.* 2019;9(2):158–64. <https://doi.org/10.1002/ialr.22237>.
75. Benkhatar H, Loubieres C, Kada AR, De Malherbe M, Meunier N. Midline olfactory implantation: a cadaveric study of endoscopic transseptal transcribriform approach. *Rhinology.* 2022;60(2):145–7. <https://doi.org/10.4193/Rhin21.376>.

**Publisher's Note** Springer Nature remains neutral with regard to jurisdictional claims in published maps and institutional affiliations.