

A Move to Conservatism in Pediatric Urology

Hemal Kodikara¹ · Aurore Bouty¹ · Mike O'Brien¹ · Yves Heloury¹

Published online: 10 July 2017
© Springer Science + Business Media New York 2017

Abstract

Purpose of Review To define the evidence on the move to conservative treatment in four areas of pediatric urology: laparoscopic ureteric clipping in non-functioning duplex kidney, management of multicystic dysplastic kidney (MCDK), intravesical botulinum toxin injection in detrusor over activity, and risk stratification of gonadal tumors in disorders of sexual development.

Recent Findings Laparoscopic ureteric clipping has been validated in one preliminary study. Lesser investigation and non-operative management of MCDK has been validated. An increasing body of evidence showing botulinum toxin injection can effectively treat detrusor over activity and reduce the need for bladder augmentation. New data on testicular biopsy can now identify patients at risk of germ cell tumor and reduce need for gonadectomy.

Summary Pediatric urology is shifting to less invasive management in a number of common conditions.

Keywords Minimally invasive surgery · Ureteric clipping · Multicystic dysplastic kidney · Botulinum toxin · Testicular biopsy · Disorders of sexual development

Introduction

Recently, there has been an increasing shift to seek out less invasive solutions to conditions previously treated by open

surgery. Pediatric urology is no different and this is demonstrated by the pendulum swing in the last 20 years to conservative management in patients with vesicoureteric reflux, many of whom would previously have undergone open ureteric reimplantation. In addition, more recently, there are a number of other areas of pediatric urology where conditions previously treated with open surgery have newer, less invasive treatment options. The following review will focus on four areas which typify this change in thinking in the last 5 years.

Laparoscopic Ureteral Ligation for Non-Functioning Upper Pole Moiety

Traditionally, non-functioning upper pole moieties of a duplex system have been treated by open surgery in the form of upper pole heminephrectomy. With the advent of laparoscopic and retroperitoneoscopic methods, there has been improved post-operative pain and cosmetic satisfaction. Nevertheless, upper pole heminephrectomy is not without complication such as urinoma or the rare but catastrophic loss of the lower moiety in up to 5% [1]. Additionally, there is an increasing pool of evidence from the adult renal transplant literature where large numbers of patients have undergone ureteric ligation of their native kidney ureter during transplantation with a very low complication rate over a long follow-up period [2]. Therefore, a novel technique of laparoscopic ureteric ligation in nine girls with non-functioning upper pole moieties with ureteric ectopia who presented with incontinence has been recently described. This procedure rendered all patients dry with no significant complication [3••]. The technique involved initial cystoscopic catheterisation of the lower moiety ureter for future identification during laparoscopy. At laparoscopy the ectopic ureter was dissected free and clipped (2 clips) at the level of crossing of the iliac vessels. Potential concern

This article is part of the Topical Collection on *Surgical*

✉ Hemal Kodikara
Hemal.Kodikara@rch.org.au

¹ Department of Urology, Royal Children's Hospital, Parkville, Melbourne 3052, Australia

regarding leaving an obstructed system in situ did not lead to any complications during the 27-month follow-up in this small group. While the evidence is currently limited, laparoscopic ureteric ligation for non-functioning upper pole moiety of a duplex system shows promise as a simple, effective, minimally invasive technique which avoids the possible complications seen with existing techniques of heminephrectomy.

Management of Multicystic Dysplastic Kidney

Multicystic dysplastic kidney (MCDK) is one of the most commonly identified congenital urinary tract malformations with an incidence of around 1/4000 live births [4]. It is characterized by multiple non-communicating renal cysts separated by dysplastic parenchyma. Bilateral MCDK can lead to fetal loss secondary to oligohydramnios and end-stage renal failure postnatally [5]. The outcome for unilateral disease is excellent as renal function is maintained by the contralateral normal kidney. Nevertheless, MCDK is associated with other structural and functional renal tract abnormalities at a rate of 5–43% and is a common finding in some major genetic conditions [5]. There has been a longstanding controversy regarding the treatment of unilateral asymptomatic MCDK and in the last 5–10 years there has been a change in both the diagnosis/investigation and the management of these lesions.

Diagnosis and Investigation

Traditionally, infants with suspected MCDK on antenatal imaging underwent postnatal renal ultrasound scan and confirmatory nuclear medicine scanning to confirm the diagnosis. The nuclear medicine scan was used to eliminate the possibility of a potential treatable obstructive uropathy (such as a severe pelviureteric junction obstruction with preserved renal function) masquerading as an MCDK. A recent study has questioned the need for this nuclear medicine study with its associated time, cost, and radiation exposure given the progression of modern high resolution ultrasound [6••]. They reviewed 84 patients who underwent renal ultrasound scanning and were diagnosed with a MCDK and compared this to the nuclear medicine that these patients underwent, noting a 100% corroboration. They concluded that a confirmatory nuclear medicine study is now no longer mandatory to confirm the diagnosis of MCDK if the ultrasound findings are typical. In the past a micturating cystourethrogram (MCUG) was also used routinely to evaluate for contralateral vesicoureteric reflux (VUR) patients with MCDK. Recently however this practice has been challenged given the VUR in these patients has been shown to be of low grade, with a high rate of spontaneous resolution and that asymptomatic VUR does not need active medical or surgical treatment. One study evaluated 61 infants with unilateral MCDK who had a normal contralateral

urinary tract on two successive neonatal renal ultrasound scans [7]. Among them, only 4 of 61 (7%) infants had low-grade VUR on MCUG that resolved spontaneously before 2 years of age. They concluded that the practice of routine MCUG can be abandoned and reserved for patients with structural renal tract abnormality or symptomatic patients (febrile urinary tract infection).

Management

In the past asymptomatic MCDK were routine removed surgically by either an open, laparoscopic or retroperitoneoscopic technique with relatively low morbidity. However increasingly, a nonoperative approach has gained popularity for asymptomatic MCDK avoiding the surgical and anesthetic risks of the procedure with no increase in associated complications related to the MCDK. Historically, asymptomatic MCDK were removed for two main justifications: the potential complication of hypertension and the suspected risk of malignancy [8]. However, large studies have shown a very low risk of hypertension with a systematic review showing only 6/1115 patients with MCDK developing hypertension, a rate comparable to the baseline population rate [9]. Similarly the risk of Wilms tumor, which was based on anecdotal case reports of Wilms tumor associated with MCDK, has more recently been quantified in the National Wilms Tumor Study Pathology Center at only approximately 1:2000 [10]. In addition, no Wilms tumors were found in a study of 1041 children with unilateral MCDK treated conservatively [11]. In fact, one recent study has affirmed the known high involution rate of MCDK (50% at 10 years of age) and advocated for a very limited follow-up of these lesions. This cost effective regimen they propose consists of a renal tract ultrasound at 1 year (and no further imaging if decreasing in size) followed by primary care monitoring of blood pressure annually [12••].

Use of Intravesical Botulinum Toxin

Detrusor over activity is a common presentation in both neurogenic and non-neurogenic patients attending pediatric urology outpatient departments and is notoriously difficult to treat. While the majority of non-neurogenic cases can be treated initially with bladder rehabilitation and antimuscarinic therapy, treatment side effects or failure occurs in a significant proportion of patients. Botulinum toxin is a two-chain polypeptide neurotoxin protein produced by the bacteria *Clostridium botulinum*. There are eight subtypes of botulinum neurotoxins with subtype A and B used clinically for a range of indications such as spastic muscular disorders and cosmetic use [13]. Botulinum toxin blocks muscular contractions by inhibiting the presynaptic release of acetylcholine at neuromuscular junctions.

Use in Neurogenic Bladder

The use of injected (cystoscopic) intravesical botulinum toxin A was first described in the year 2000 in a cohort of paraplegic adult patients with neurogenic bladder. This group, with severe detrusor over activity and who were performing clean intermittent catheterization achieved major improvements in urinary incontinence and urodynamic parameters following the treatment [14]. The landmark pediatric study from 2002 described 17 patients with neurogenic bladder who underwent injection of 85–300 U of botulinum toxin A. Following treatment they found increased maximal bladder capacity by 56.5%, from 137.53 to 215.25 mL ($p < 0.005$) and decreased maximal detrusor pressure by 32.6% ($p < 0.005$) [15]. This effect lasted up to 6 months. An additional benefit of the use of botulinum toxin A injection in patients with neurogenic bladder is that the treatment has a modest beneficial effect on bladder compliance and other urodynamic parameters. One study of 17 patients with neurogenic bladder who underwent injection of botulinum toxin A showed bladder volume changed from 380 ± 148 ml to 453 ± 147 ($p = 0.078$) and maximal detrusor pressure decreased from 45 ± 31 to 32 ± 21 cmH₂O ($p = 0.030$) postinjection [16]. Therefore, the treatment may be used in patients with moderately unsafe bladders who have failed conservative treatment with antimuscarinic treatment. In some patients with a moderately hypocompliant bladder, treatment with botulinum toxin may be sufficient to ensure a safe system. For many children with hypocompliant bladders it would be a temporizing procedure prior to bladder augmentation. While the need for augmentation may not be eliminated permanently, the potential long term complications of stone formation, metabolic disturbances and malignancy risk can be delayed. One study stated that 14/17 children with neurogenic bladder who were candidates for bladder augmentation and underwent a program of injections, avoided surgical reconstruction by way of improved bladder capacity and compliance over the 4 year study period. [17••].

Use in Non-Neurogenic Bladder

The treatment also has a major benefit in non-neurogenic detrusor over activity with one study noting a significant improvement in both clinical and urodynamic parameters in 8 children who underwent a single injection with a mean of 7.75 daytime urinary incontinence episodes per week before the injections versus 3 after the procedure ($p = 0.04$). The effect was also long lasting (1 year) with no report of urinary retention or allergic reaction [18•]. The long-term benefit of the treatment has been verified in a further study which followed 53 children over a 10-year period who had multiple injections (up to 11) with a significant and persistent improvement in symptoms seen [19•].

Dosing and Side Effects

There remains outstanding questions in relation to the optimum dosing in pediatric patients with their being no standardized dosing or injection frequency with a suggested dosing regimen of 10 U per kg with studies using anywhere from 50 to 500 U [20]. Generally for non-neurogenic bladder a dosing of between 100 and 200 U is considered appropriate and for neurogenic bladder patients 200–300 U with some studies showing an increasing benefit with these increased doses [17••]. Side effects of the treatment are minimal and occur rarely. The most frequent include urinary retention and procedure related urinary tract infection (7–20%) with no reports of major local or systemic adverse reactions [21]. In addition, there are the practical, legal and ethical implications of using a medication which is not yet licensed widely for this indication in children.

Prophylactic Gonadectomy for Germ Cell Tumors

A number of conditions are associated with increased risk for germ cell tumors in children, namely, cryptorchidism and in association with disorders of sexual development (DSD). Traditionally a liberal policy of gonadectomy was undertaken for at risk patients given the consequence of a missed diagnosis, the lack of evidence and guidelines for gonadectomy in these. Increasingly however, through advances in these techniques, these patients can be accurately risk stratified thus significantly reducing the number of gonadectomies in these patients.

Disorders of Sexual Development

Disorders of sexual development result due to defects of fetal sexual differentiation. These have major physical and psychological implications for the child and for the pediatric urologist a major consideration is the management of the gonads in the children at risk of gonadal tumor development. Type 2 germ cell tumors result from fetal germ cells and can be further subdivided into two groups: seminoma/dysgerminoma and non-seminoma (embryonal carcinoma, yolk sac tumor, choriocarcinoma, and teratoma) [22]. In general, conditions with gonadal dysgenesis (i.e., conditions with defective testicularization) have a higher risk of tumorigenesis compared to conditions with abnormal androgen synthesis or action [23].

Cryptorchidism

Undescended testes are the most common congenital abnormality of the male genitalia with an incidence of 1–2% at 1 year of age [24]. Ideally, orchidopexy will be performed between the ages of 6 to 18 months in order to prevent

Table 1 Risk of germ cell tumor by condition (adapted from [23])

Risk	DSD subtype	Tumor risk %
High	Gonadal dysgenesis (intraabdominal)	15–35
	Denys-Drash syndrome	40
	Partial androgen insensitivity syndrome (inguinal/abdominal)	50
Intermediate	Turner Syndrome (+Y)	12
	PAIS (scrotal gonad)	Unknown
	Gonadal dysgenesis (scrotal)	Unknown
Low	17 beta-hydroxysteroid	28
	Complete androgen insensitivity syndrome	0.8–2
	Ovotesticular DSD	2.6–3
Nil	Turner (–Y)	1
	5 alpha reductase deficiency Leydig cell hypoplasia	0

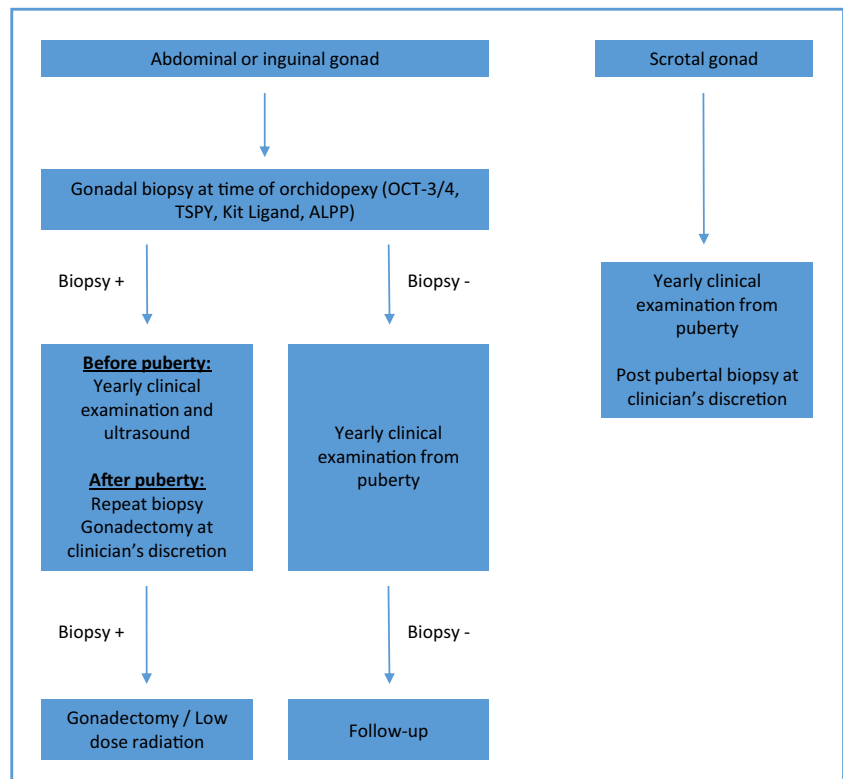
deterioration in germ cells that occurs with delayed orchidopexy. Delayed orchidopexy for UDT is associated with an increased risk of testicular cancer. One large cohort study of 16,983 orchidopexies showed a relative risk of testicular cancer versus the general population of 5.40 vs 2.23 in patients who underwent orchidopexy at age 13 or above compared with those who underwent surgery before 13 years [25].

Even recent papers have recommended a policy of orchidectomy for patients with post-pubertal cryptorchidism [26]. Now, testicular biopsy as described below can allow accurate risk stratification of these patients allowing preservation of the gonads in many cases.

Testicular Biopsy

The risk of germ cell tumor is directly correlated to a specific region of the Y chromosome named the gonadoblastoma locus [22]. The TSPY gene located in this region encodes testis-specific Y-encoded protein (TSPY) which has been reported to promote germ cell tumor development in gonadal dysgenesis. Carcinoma in situ (CIS) and gonadoblastoma are both precursors of type II germ cell tumors and their development depends on the level of testicularisation of the gonad [27••]. CIS tends to occur when the testes are differentiated (SOX 9 mediated) and gonadoblastoma arises in undifferentiated gonadal tissue (cells expressing FOXL2) in the phenotypically female. Untreated CIS progress to germ cell tumors in nearly all cases after puberty and gonadoblastoma undergoes malignant transformation in a significant proportion of patients. CIS and gonadoblastoma can be diagnosed histologically and immunohistochemically as they express Octamer-binding transcription factor 3/4 (OCT-3/4). OCT-3/4 and TSPY are

Fig. 1 Gonadal management algorithm for prepubertal boys (male phenotype) with 46 XY disorders of sexual development (DSD) (adapted from [28••])



the two best diagnostic markers of premalignant germ cell tumor lesions [28••]. Due to overlap in positive OCT-3/4 staining in both true neoplastic germ cells and germ cells with delayed maturation in the infant age group, only after the age of 2 years is a positive OCT-3/4 staining highly suspicious of CIS. Other specific factors that can be used are alkaline phosphatase placental type (ALPP) and stem cell factor (SCF)/kit ligand which are detected in preinvasive testicular tumors and neoplastic germ cells, respectively [28••].

Development of Gonadal Tumor and Timing of Gonadectomy

The priority in management of these patients is preservation of endocrine function where possible and early prediction and management of tumor risk. The two key risk factors for tumorigenesis in these patients are the presence of Y chromosomal material and abnormal location of the gonad (abdominal or inguinal). The age of tumor development depends on the etiology of the DSD. The risk is highest in patients with 46,XY gonadal dysgenesis (15–60%) while it is lowest in patients with complete androgen insensitivity, five alpha reductase deficiency and ovotesticular DSD (<5%) [23]. This is described in Table 1.

An algorithm for the use of testicular biopsy in patients with 46, XY DSD and a male phenotype at risk of gonadal malignancy is detailed in Fig. 1 [28••]. It is clear that the scrotal gonad is at low risk of tumor and therefore a single gonadal biopsy after puberty would be sufficient to define risk. In general, there is limited utility of gonadal biopsy to assess the risk of tumorigenesis in patients with female or ambiguous phenotypes as the risk of malignancy is generally high and therefore the threshold for gonadectomy is much lower.

Conclusion

This review has used four examples of conditions seen in pediatric urology where there is a move to novel or less invasive management policies. The advent and increased uptake of minimally invasive surgery has revolutionized many areas of surgery. Laparoscopic ureteric ligation, its most minimally invasive form, has the potential to redefine the treatment of nonfunctioning upper moieties in duplex kidneys. The move toward nonoperative management of asymptomatic MCDK has strengthened with further evidence demonstrating that previous invasive investigative modalities can be abandoned and unnecessary follow-up reduced. In the use of intravesical injection of botulinum toxin A, the novel use of an existing medication has meant the avoidance of many significant and long-term complications of radical surgery in neurogenic bladder patients, and a convenient, effective solution in the

common problem of non-neurogenic detrusor over activity. And finally the development of newer and accurate molecular biologic techniques predictive of future malignancy has allowed better risk stratification in patients at risk of germ cell tumors allowing preservation of gonads in patients who previously would have undergone gonadectomy.

It is likely that as a result of the increased uptake of these varied strategies and also with patients and families increasing demand for less invasive procedures, that this move to conservatism to address these and other common disorders seen in pediatric urology will only get stronger.

Compliance of Ethical Standards

Conflict of Interest Hemal Kodikara, Aurore Bouty, Mike O'Brien, and Yves Heloury each declare no conflict of interest.

Human and Animal Rights and Informed Consent This article does not contain any studies with human or animal subjects performed by any of the authors.

References

Papers of particular interest, published recently, have been highlighted as:

- Of importance
 - Of major importance
1. Jayram G, Roberts J, Hernandez A, Heloury Y, Manoharan S, Godbole P, LeClair M, Mushtaq I, Gundeti MS. Outcomes and fate of the remnant moiety following laparoscopic heminephrectomy for duplex kidney: a multicenter review. *J Pediatr Urol.* 2011;7(3): 272–5.
 2. Gallentine ML, Wright Jr FH. Ligation of the native ureter in renal transplantation. *J Urol.* 2002;167(1):29–30.
 - 3•• Romao RL, Figueroa V, Salle JL, Koyle MA, Bägli DJ, Lorenzo AJ. Laparoscopic ureteral ligation (clipping): a novel, simple procedure for pediatric urinary incontinence due to ectopic ureters associated with non-functioning upper pole renal moieties. *J Pediatr Urol.* 2014;10(6):1089–94. **This is the defining publication on the technique of laparoscopic ureteric ligation in the setting of upper pole moieties in children.**
 4. Feldenberg LR, Siegel NJ. Clinical course and outcome for children with multicystic dysplastic kidneys. *Pediatr Nephrol.* 2000;14: 1098–101.
 5. Rudnik-Schoneborn S, John U, Deget F, Ehrich JH, Misselwitz J, Zerres K. Clinical features of unilateral multicystic renal dysplasia in children. *Eur J Pediatr.* 1998;157:666–72.
 - 6•• Whittam BM, Calaway A, Szymanski KM, Carroll AE, Misseri R, Kaefer M, Rink RC, Kamazyn B, Cain MP. Ultrasound diagnosis of multicystic dysplastic kidney: is a confirmatory nuclear medicine scan necessary? *J Pediatr Urol.* 2014;10(6):1059–62. **This study validates the use of ultrasound alone to confirm the diagnosis of multicystic dysplastic kidney.**
 7. Ismaili K, Avni FE, Alexander M, Schulman C, Collier F, Hall M. Routine voiding cystourethrography is of no value in neonates with unilateral multicystic dysplastic kidney. *J Pediatr.* 2005;146(6): 759–63.

8. Hains DS, Bates CM, Ingraham S, Schwaderer AL. Management and etiology of the unilateral multicystic dysplastic kidney: a review. *Pediatr Nephrol.* 2009;24(2):233–41.
9. Narchi H. Risk of hypertension with multicystic kidney disease: a systematic review. *Arch Dis Child.* 2005;90(9):921–4.
10. Homsy YL, Anderson JH, Oudjhane K, Wilms RP. Tumor and multicystic dysplastic kidney disease. *J Urol.* 1997;158(6):2256–9.
11. Narchi H. Risk of Wilms' tumour with multicystic kidney disease: a systematic review. *Arch Dis Child.* 2005;90(2):147–9.
12. Eickmeyer AB, Casanova NF, He C, Smith EA, Wan J, Bloom DA, Dillman JR. The natural history of the multicystic dysplastic kidney—is limited follow-up warranted? *J Pediatr Urol.* 2014;10(4):655–61. **This study proposes a follow-up algorithm for multicystic dysplastic kidney involving a much reduced burden on ultrasound and tertiary service follow-up without complication.**
13. Hsieh PF, Chiu HC, Chen KC, Chang CH, Chou EC. Botulinum toxin A for the treatment of overactive bladder. *Toxins (Basel).* 2016;8(3).
14. Schurch B, Stöhrer M, Kramer G, Schmid DM, Gaul G, Hauri D. Botulinum-A toxin for treating detrusor hyperreflexia in spinal cord injured patients: a new alternative to anticholinergic drugs? Preliminary results *J Urol* 2000;164(3 Pt 1):692–697.
15. Schulte-Baukloh H, Michael T, Schobert J, Stolze T, Knispel HH. Efficacy of botulinum-a toxin in children with detrusor hyperreflexia due to myelomeningocele: preliminary results. *Urology.* 2002;59(3):325–7. discussion 327-8
16. Kask M, Rintala R, Taskinen S. Effect of onabotulinumtoxinA treatment on symptoms and urodynamic findings in pediatric neurogenic bladder. *J Pediatr Urol.* 2014;10(2):280–3.
17. Figueroa V, Romao R, Pippi Salle JL, Koyle MA, Braga LH, Bägli DJ, Lorenzo AJ. Single-center experience with botulinum toxin endoscopic detrusor injection for the treatment of congenital neuropathic bladder in children: effect of dose adjustment, multiple injections, and avoidance of reconstructive procedures. *J Pediatr Urol.* 2014;10(2):368–73. **This important study highlights the improvement in symptoms and urodynamic parameters in patients with neurogenic bladder and also a cohort of patients that avoided surgical reconstruction as a result.**
18. Léon P, Jolly C, Binet A, Fiquet C, Vilette C, Lefebvre F, Bouché-Pillon-Persyn MA, Poli-Mérol ML. Botulinum toxin injections in the management of non-neurogenic overactive bladders in children. *J Pediatr Surg.* 2014;49(9):1424–8. **This paper details the significant improvement in day and night incontinence and urodynamic parameters in non-neurogenic bladder.**
19. Greer T, Abbott J, Breytenbach W, McGuane D, Barker A, Khosa J, Samnakay N. Ten years of experience with intravesical and intrasphincteric onabotulinumtoxinA in children. *J Pediatr Urol.* 2016;12(2):94.e1–6. **This report highlights the long-term benefit obtained from botulinum toxin in both neurogenic and non-neurogenic bladder.**
20. Nitii V. Botulinum toxin for the treatment of idiopathic and neurogenic overactive bladder: state of the art *Rev Urol.* 2006 Fall; 8(4): 198–208
21. Gamé X, Mouracade P, Chartier-Kastler E, Viehweger E, Moog R, Amarenco G, Denys P, De Seze M, Haab F, Karsenty G, Kerdraon J, Perrouin-Verbe B, Ruffion A, Soler JM, Saussine C. Botulinum toxin-A (Botox) intradetrusor injections in children with neurogenic detrusor overactivity/neurogenic overactive bladder: a systematic literature review. *J Pediatr Urol.* 2009;5(3):156–64.
22. Looijenga LH, Hersmus R, de Leeuw BH, Stoop H, Cools M, Oosterhuis JW, Drop SL, Wolffebutel KP. Gonadal tumours and DSD. *Best Pract Res Clin Endocrinol Metab.* 2010;24(2):291–310.
23. Lee PA, Houk CP, Ahmed SF, Hughes IA; International Consensus Conference on Intersex organized by the Lawson Wilkins Pediatric Endocrine Society and the European Society for Pediatric Endocrinology. Consensus statement on management of intersex disorders. *Pediatrics* 2006;118(2):e488–e500.
24. Virtanen HE, Bjerknes R, Cortes D, Jørgensen N, Rajpert-De Meyts E, Thorsson AV, Thorup J, Main KM. Cryptorchidism: classification, prevalence and long-term consequences. *Acta Paediatr.* 2007;96(5):611–6.
25. Pettersson A, Richiardi L, Nordenskjöld A, Kaijser M, Akre O. Age at surgery for undescended testis and risk of testicular cancer. *N Engl J Med.* 2007;356(18):1835–41.
26. Chung JM, Lee SD individualized treatment guidelines for Postpubertal cryptorchidism. *World J Mens Health.* 2015;33(3): 161–6.
27. Abacı A, Çatlı G, Berberoğlu M. Gonadal malignancy risk and prophylactic gonadectomy in disorders of sexual development. *Pediatr Endocrinol Metab.* 2015;28(9–10):1019–27. **Broad review of recent data on malignancy risk in DSD and timing of gonadectomy.**
28. Faure A, Bouty A, O'Brien M, Thorup J, Hutson J, Heloury Y. Testicular biopsy in prepubertal boys: a worthwhile minor surgical procedure? *Nat Rev Urol.* 2016;13(3):141–50. **This review details the histochemical markers used in testicular biopsy to stratify risk for germ cell tumours.**