

Malignant Rhabdoid Tumor of Kidney and Brain in an Infant

DEEPTI SHUKLA, *ADITYA PRADHAN, MUKESH BHARDWAJ AND VEENA MALHOTRA

From the Departments of Histopathology and *Urology, BLK Hospital, Pusa Road, New Delhi, India.

Correspondence to:

Dr Veena Malhotra, Histopathology
Department, BLK Hospital, Pusa Road, New
Delhi, India.

veena.malhotra@blkhospital.com

Received: June 24, 2014;

Initial review: July 31, 2014;

Accepted: October 09, 2014.

Background: Malignant rhabdoid tumors of kidney are associated with atypical teratoid rhabdoid tumors of brain, both being characterized genetically by deletion/ mutation of SMAR CBI/ INI gene. **Case characteristics:** 6-month-old male presented with a brain tumor and was subsequently found to have malignant rhabdoid tumor of kidney. **Interventions:** Surgical resection of brain tumor followed by chemotherapy and subsequently resection of renal tumor. **Outcome:** Child died seven months after initial presentation. **Message:** Children presenting with embryonal brain tumor, should be investigated for renal tumors and *vice versa*.

Keywords: Hematuria, Kidney, Mutation, Tumor

Malignant rhabdoid tumor of kidney is highly aggressive tumor of infancy and childhood. Concomitant brain tumor is present in almost 21% of patients [1]. These tumors are characterized genetically by deletion/ mutation of *SMARCB1/INI* gene located on chromosome 22q 11.2 [1]. We describe a case of malignant rhabdoid tumor of kidney, who first presented as posterior fossa brain tumor. Renal tumor was diagnosed only when the child developed hematuria.

CASE REPORT

A 6-month-old male child presented with history of vomiting and increasing head size. Computerized tomography (CT) and Magnetic resonance imaging (MRI) revealed a large heterogeneously enhancing solid, cystic space occupying lesion with perilesional edema and obstructive hydrocephalus. Ventriculoperitoneal shunt was done followed by subtotal gross total excision of the tumor. Histopathological examination revealed a neoplasm made up of sheets of round, oval and spindle shaped cells. Cells had hyperchromatic nucleus and moderate amount of lightly stained cytoplasm. Nuclear pleomorphism and brisk mitosis was seen (**Fig. 1**). Typical rhabdoid cells were not seen. Tumor cells showed positive staining for vimentin, Epithelial Membrane Antigen (EMA) and Synaptophysin. They were negative for Glial fibrillary acidic protein. A diagnosis of high grade malignant embryonal tumor was given.

Patient received four cycles of chemotherapy (Cisplatin, Cyclophosphamide, Bleomycin and Etoposide). Post four cycles of chemotherapy, MRI brain showed progressive disease. Thereafter he received two cycles of 2nd line chemotherapy with Vinblastin plus ifosfamide plus cisplatin (VELP) regimen. Subsequently child developed hematuria. Contrast enhanced computerized tomography abdomen and chest showed a

large heterogeneous mass in the right kidney. Radical nephrectomy was done after 6 months of initial presentation.

Right kidney measured 8×6.5×5.5 cm. Cut surface showed a tumor replacing almost the entire kidney. Areas of hemorrhage and necrosis were present. No capsular breach was seen. Microscopic examination showed sheets of cells with nucleus showing central nucleolus and eosinophilic cytoplasm. Mitosis and apoptosis was seen (**Fig. 1**). Areas of haemorrhage and necrosis were present. Lymphatic invasion was seen. Tumor cells showed positive staining with vimentin and EMA. Staining with INI-1 on renal as well as earlier received CNS tumor showed absence of nuclear staining.

Diagnosis of malignant rhabdoid tumor of kidney was made. In view of INI-1 negative staining in the CNS tumor as well, the CNS tumor was also considered as atypical teratoid rhabdoid tumor (AT/RT). As patient had already been treated with chemotherapy, patient was counseled regarding the prognosis and managed by supportive measures. Patient succumbed to his illness after one month of radical nephrectomy.

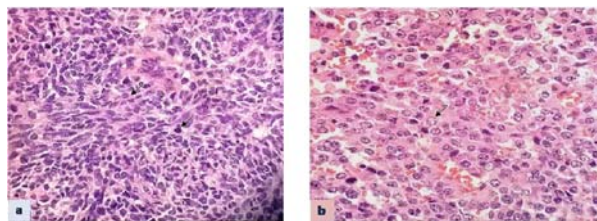


FIG. 1 Brain tumor showing medium sized round to oval tumor cells with hyper chromatic nucleus, moderate amount of cytoplasm and mitosis (arrow) H&E, x600 (a); and Kidney tumor showing sheets of cells with nucleus showing nucleolus and eosinophilic cytoplasm (arrow) H&E, x 600 (b). (See website for color image).

DISCUSSION

The exact cell type of derivation of Rhabdoid tumor of kidney still remains unknown. Possible origin from primitive cells located in renal medulla has been considered [2]. Rhabdoid tumor of kidney is made up of cells arranged as diffuse sheets or as alveolar or trabecular pattern. Extra renal rhabdoid tumors are being increasingly recognized [3].

Our case initially presented as CNS tumor. As rhabdoid cells were not well-defined in the tumor, it was diagnosed as high grade malignant embryonal tumor. Renal tumor was diagnosed only when the child developed hematuria. In an infant or very young child presenting with CNS tumor of ill-defined morphology, diagnosis of AT/RT should be considered as rhabdoid cells may not be seen in all AT/RT tumors. Staining with INI-1 helps in differentiating this tumor from other poorly differentiated tumors such as primitive neuroectodermal tumor. An evaluation for simultaneous presence of renal tumor should be done in view of association of renal and CNS tumor. On the other hand in children presenting with malignant rhabdoid tumor of kidney, brain CT scan for CNS tumor should be mandatory.

The gene mutated or deleted in malignant rhabdoid tumor of kidney is *SMARCB1* gene, also referred as *SNF5* or *INI-1* or *BAF47* [4]. Inactivation of both copies of gene leads to loss of protein expression in the nucleus, which can be detected by immunohistochemistry for INI-1. Absence of INI-1 is quite specific for AT/RT brain and malignant rhabdoid tumors of kidney. Besides this soft tissue epithelioid sarcomas, renal medullary tumors, few peripheral nerve sheath tumors and familial schwannomatosis can show absence of nuclear staining [4]. However, these tumors can be differentiated from malignant rhabdoid tumors on morphology. Strong correlation is seen between loss of INI immunostaining and presence of INI-1 mutation [5]. Malignant rhabdoid tumors express many stem cell associated transcription factors [6].

Histone deacetylase inhibitor, romidepsin restores *CDKN1C* in rhabdoid tumor cells and may help in treatment [7]. Pharmacological inhibition of fibroblastic growth factor receptors FGFRs has been proposed as potential novel therapy for malignant rhabdoid tumors [8]. Drugs which target cell cycle or epigenetic genes and targeted therapy specific for rhabdoid tumor subset molecular profiles may also be useful in treatment of rhabdoid tumors [9].

Rhabdoid tumors can occur sporadically or as part of hereditary cancer syndrome known as Rhabdoid Tumor Predisposition Syndrome. Prognosis of malignant rhabdoid tumor of kidney is related to age at the time of diagnosis and stage of disease and not to the location of tumor [1]. Survival at 4 years for infants under 6 months at the age of diagnosis was 8.8% in comparison 41.1% survival for children with age at diagnosis of 2 years [1].

Thus infants and very young children presenting with kidney tumors should be investigated for synchronous presence of brain tumor or *vice versa*.

Contributors: DS: Histopathology diagnosis of brain tumor; AP: Surgical resection of kidney tumor; MB: Grossing of specimen and preparation of manuscript; VM: Diagnosis of brain and kidney tumor and preparation of manuscript.

Funding: None; *Competing interests:* None stated.

REFERENCES

- Tomlinson GE, Breslow NE, Dome J, Guthrie KA, Norkool P, Li S, *et al.* Rhabdoid tumor of the kidney in National Wilms tumor study: Age at diagnosis as a prognostic factor. *J Clin Oncol.* 2005;23:7641-5.
- Juan Rosai. Urinary tract In: Rosai and Ackerman's Surgical Pathology, 9th edition Mosby St. Louis. Missouri, 2004. p. 1250-51.
- Garces-Inigio EF, Leung R, Sebire NJ, McHugh K. Extrarenal rhabdoid tumors outside the central nervous system in infancy. *Pediatr Radiol.* 2009;39:817-22.
- Robert CW, Biegel JA. The role of SMARCB1/INI1 in the development of rhabdoid tumor. *Cancer Biol Ther.* 2009;8:412-6.
- Wu X, Dagar V, Algar E, Muscat A, Bandopadhyay P, Ashley D, *et al.* Rhabdoid tumor: a malignancy of early childhood with variable primary site, histology and clinical behavior. *Pathology.* 2008;40:664-70.
- Deisch J, Raisanen J, Rakheja D. Immunohistochemical expression of embryonic stem cell markers in malignant rhabdoid tumors. *Pediatr Dev Pathol.* 2011;14:353-9.
- Algar EM, Muscat A, Dagar V, Rickert C, Chow CW, Biegel JA, *et al.* Imprinted CDKN1C is a tumor suppressor in rhabdoid tumor and activated by restoration of SMARCB1 and histone deacetylase inhibitors. *PLoS One.* 2009;4:e4482.
- Wohrle S, Weiss A, Ito M, Kauffman A, Murakami M, Jagani Z, *et al.* Fibroblast growth factor receptors as novel therapeutic targets in SNF5- detected malignant rhabdoid tumors. *PLOS One.* 2013;8:e77652.
- Brisks DK, Donson AM, Patel PR, Sufit A, Algar EM, Dunham C, *et al.* Pedratic rhabdoid tumors of kidney and brain show many differences in gene expression but share dysregulation of cell cycle and epigenetic effector genes. *Pediatr Blood Cancer.* 2013;60:1095-102.