


Current status of laparoscopic colorectal surgery in the emergency setting

Ferdinando Agresta¹  · Alberto Arezzo² · Marco Ettore Allaix² · Simone Arolfo² · Gabriele Anania³

Received: 17 October 2015 / Accepted: 28 February 2016 / Published online: 25 March 2016
© Italian Society of Surgery (SIC) 2016

Abstract Laparoscopic surgery has become well established in the management of both benign as malignant colorectal disease. However there has not been the same enthusiasm for the use of laparoscopy in emergency colorectal surgery. We have critically review the indications and the results of the laparoscopic approach for the treatment of acute colorectal disease. A systemic review based on comprehensive Literature research was made on Pubmed with the primary objective to identify all clinical relevant randomized controlled trials (RCT). However, other reports, population based outcomes studies, case series and case reports were also included. Cross-link control was than performed with Google Scholar and Cochrane library databases. We have reviewed the last years' evident literature about this last topic and the results reported , although mainly early, controversial and focused on the short term, enabled us to generally conclude that in a proper setting, laparoscopic colorectal emergency surgery is feasible, effective, safe and beneficial for patients to be a part of a common surgical practice, as long as adequate training is obtained and proper preparation observed when more advanced procedures are attempted in critically patients.

Keywords Laparoscopy · Colon diseases · Emergency

✉ Ferdinando Agresta
fagresta@libero.it

¹ Department of General Surgery, ULSS19 del Veneto, Adria, RO, Italy

² Department of Surgical Sciences, University of Torino, Turin, Italy

³ Department of Surgical Sciences, University of Ferrara School of Medicine, Ferrara, Italy

Introduction

Laparoscopy has greatly improved surgical outcomes in many areas of abdominal surgery. Laparoscopic cholecystectomy and antireflux surgery have become the gold standard procedures, virtually replacing their open counterparts [1]. Other procedures, specifically laparoscopic emergency ones, have not enjoyed similar universal acceptance. The reason for this are many: a steep learning curve, uncertainty about the procedure's effectiveness for all the pathology and patients, long operating time, and lack of tactile feedback, among others [2, 3].

Laparoscopic surgery has become well established in the management of both benign as malignant colorectal disease. However there has not been the same enthusiasm for the use of laparoscopy in emergency colorectal surgery [4, 5].

The aim of this paper is to critically review the indications and the results of the laparoscopic approach for the treatment of acute colorectal disease, according to the newest evidences.

Literature searches and appraisal The primary objective of the search was to identify all clinical relevant randomized controlled trials (RCT). However, other reports, population based outcomes studies, case series and case reports were also included. Studies containing severe methodological flaws were downgraded. For each intervention, the validity and homogeneity of study results, effect sizes, safety and economic consequences were considered.

A systemic review based on comprehensive Literature research was made on Pubmed.

Limits Activated: Humans, Clinical Trial, Meta-Analysis, Practice Guideline, Randomized Controlled Trial, Review, English, All Adult: 19+ years, published in the last 15 years.

Search details: [((“laparoscopy”[MeSH Terms] OR “laparoscopic”[All Fields]) AND (“condition-specific key word”[MeSH Terms] OR “condition-specific key word”[All Fields])) AND (“humans”[MeSH Terms] AND (Clinical Trial[ptyp] OR Meta-Analysis[ptyp] OR Practice Guideline[ptyp] OR Randomized Controlled Trial[ptyp] OR Review[ptyp])) AND English[lang] AND “adult”[MeSH Terms] AND “2000/1/1”[PDat]: “2015/10/1”[PDat]]].

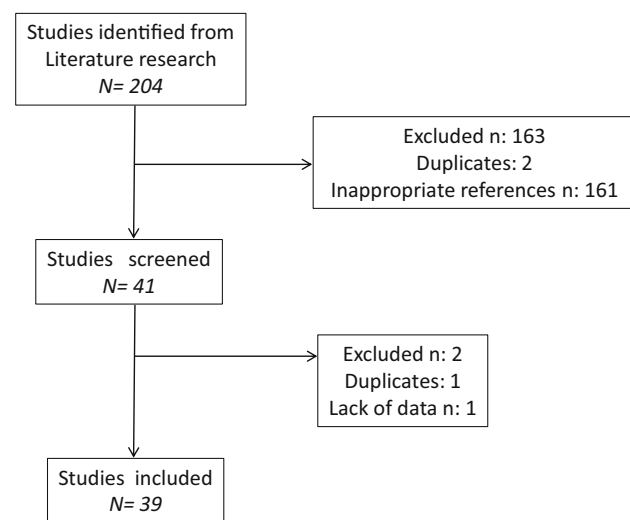
After that, limits regarding language, age, publication date and study type were removed, and full texts from all the abstracts were used based on specific criteria. The papers have been selected and classified on the basis of highest level of evidence, design of the study, and most recent publication.

Cross-link control was performed with Google Scholar and Cochrane library databases. In Fig. 1 is reported the Flowchart of search strategy.

Acute colon obstruction

About 30 % of patients with colorectal cancer present with acute colon obstruction requiring an emergent treatment [4, 5]. There are several surgical options and the choice among these options depends on several factors: tumor location, clinical condition, surgeon expertise and intraoperative surgical findings postoperative anastomotic leakage [6].

Acute colon obstruction is considered by many an absolute contraindication to the laparoscopic approach. As a consequence, this surgery is mainly performed by an open approach and is associated with significant peri-operative mortality, postoperative morbidity and impaired quality of life [7].



Flowchart of search strategy

Fig. 1 Flowchart of search strategy

However, the progressive diffusion of the laparoscopic approach to both benign and malignant colorectal diseases and the development of endoluminal stenting is challenging this practice.

Laparoscopic right hemicolectomy

Data about emergent laparoscopic right hemicolectomy for obstructing right-sided colon cancer are lacking [8]. It has been basically proposed with consistency only by the group of the Prince of Wales Hospital, Hong Kong, so far. Here first Ng, then Li proposed several retrospective series of laparoscopic emergent procedures compared to larger series of open procedures. They first reported about 7 cases, later of 43 cases showing less morbidity, faster recovery and reduced blood loss with an acceptable lymph node yield [9, 10]. In a more recent and much larger series Li could not confirm any difference in intra- and post-operative complications if not a significantly increased procedure time in the laparoscopic group [11].

The interpretation of the results of these studies is limited by their retrospective nature, the small sample size, and the lack of long-term oncologic outcomes.

Laparoscopic left hemicolectomy

More literature is available for emergent laparoscopy of malignant obstruction of the left colon [4–7]. While Hartmann’s operation with the formation of an end colostomy is still the most frequently performed procedure in open surgery, more often primary anastomosis with a defunctioning stoma is performed still in open surgery fashion [5, 6]. The endoscopic positioning of a colonic stent to solve obstruction and allow a “bridge” to elective surgery strategy still struggles to establish, despite this would seem to allow an elective laparoscopic approach [12]. This because while colonic stenting offers advantages over emergency surgery in terms of increase in successful primary anastomosis, reduction of stoma creation, infections and overall complications it requires a certain expertise which is difficult to have available 24/7 [13]. Moreover it does not improve preoperative mortality and even long-term survival. In fact, there are still important concerns regarding risk of tumor cell spreading which might be responsible of a worse oncologic outcome [14]. Furthermore laparoscopy following elective surgery is offered to less than a quarter of patients [13, 14].

Based on the little evidence currently available, the European Society for Gastrointestinal Endoscopy has recently published new guidelines for the use of SEMS for obstructing colonic and extracolonic cancer [15, 16], that can be summarized in the following four recommendations:

- Prophylactic colonic metal stent placement is not recommended and should be reserved for symptomatic patients with imaging evidence of obstruction;
- Colonic metal stent placement as a bridge to elective surgery is not recommended
- Colonic metal stent placement is an alternative to emergency surgery only in case of increased risk of postoperative mortality
- Colonic metal stent placement is recommended as the preferred treatment for palliation.

The results of two ongoing RCTs comparing SEMS as “bridge to surgery” and emergency surgery for left-sided colonic malignant obstruction are expected to better clarify the oncologic impact of this minimally invasive strategy: the Colorectal Stent Trial (CreST) [17], and the ESCO trial [18]. Both studies have closed recruitment recently and publication of results is now awaited.

Iatrogenic perforations

Early recognition of perforation during diagnostic or therapeutic endoscopy allows immediate repair of the defect endoscopically if feasible [19]. For those non recognized immediately or failed to repair, emergency surgery is mandatory and may be approached laparoscopically. The options include a laparoscopic lavage and drainage, eventual defunctioning stoma, or a segmental resection with or without primary anastomosis [20].

Evidence of advantages of laparoscopy is scarce. It relies mainly on a study in which 11 patients with iatrogenic perforation were operated on laparoscopically and compared to 7 patients operated by open surgery [21], showing less overall morbidity and shorter hospital stay in the laparoscopic group.

Inflammatory bowel disease

While laparoscopic elective surgery showed benefits in the management of both ulcerative colitis and Crohn’s disease of the colon, compared to open surgery [22], in the emergency setting, the advantages of laparoscopy over open surgery are not so evident due to the limited data available. Based on the evidence of case-matched studies with few cases in each series, a limited advantage in terms of overall morbidity may be observed. Some of the studies are also difficult to analyze for the differences between the two groups compared: Nash compared a majority of patients in the laparoscopic group with toxic colitis whereas in the open group there were more patients with obstruction and perforation [23], Watanabe included in the laparoscopic

group also hand-assisted procedures [24]. Some studies show similar complication rates and morbidity between open and laparoscopic surgery [25]. Only Seshadri found significantly fewer peri-operative complications in the laparoscopic group [26].

Acute diverticulitis

The Hinchey classification is the most common grading system used for the classification and treatment of complicated diverticulitis [27]. While Hinchey grade I and II patients are successfully managed in most cases by conservative treatment, surgery is needed in the presence of peritonitis secondary to perforated diverticulitis (grade III and IV according to Hinchey classification).

The traditional surgical treatment of Hinchey III and IV patients includes open sigmoid colon resection with end colostomy and left hemicolectomy with primary anastomosis with or without diverting stoma. Early postoperative mortality rates is about 10–20 % after both sigmoid resection and end colostomy and resection and primary anastomosis. In addition, up to 70 % of patients undergoing non-restorative resection do not have their colostomy reversed and when it is reversed the anastomotic leakage reported in the literature is as high as 14 % [28, 29].

In 1996, a minimally invasive approach to patients with Hinchey III diverticulitis based on intravenous antibiotics and laparoscopic peritoneal lavage was proposed to avoid urgent resective surgery, and stoma creation including their high morbidity and mortality [30]. The rationale was that “in the vast majority of patients with generalized peritonitis secondary to perforated diverticular disease, there is no evidence of fecal contamination, and the perforation is already sealed or cannot be found at surgery” [31].

Since 2008, when the first “positive” large multicenter prospective study about laparoscopic peritoneal lavage was published by Myers in [32], several papers have been published about the topic. Cirocchi [33] recently published a systematic review of those studies aiming to evaluate the outcomes, of this minimally invasive strategy, primarily the success rate of laparoscopic peritoneal lavage. This was defined as the rate of patients alive without surgical treatment for a recurrent episode of diverticulitis or complication from diverticular disease. Of the 19 articles published between 1996 and 2013, 10 were cohort studies, 8 case series, and 1 controlled clinical trial for a total of 871 patients analyzed with up to 96 months of follow-up. The success rate of laparoscopic peritoneal lavage was 24.3 %. The overall conversion rate for Hinchey III and Hinchey IV patients was 1 and 45 %, respectively. The 30-day postoperative mortality rate was 2.9 % as a result of multiple organ failure for sepsis and pulmonary embolism. The

30 day postoperative reintervention (surgery or percutaneous drainage) rate was 3.8 %: most common causes were sepsis from generalized peritonitis or intra-abdominal abscess and colonic fistula. The hospital readmission rate after the laparoscopic peritoneal lavage was 3.4 %: main reasons were recurrent diverticular phlegmon, generalized peritonitis, colo-vesical fistula, missing colon cancer, inflammatory colonic stenosis and pelvic abscess. A reintervention (colon resection or percutaneous drainage) was necessary in 19 (63.3 %) of the 30 patients readmitted to the hospital. Elective laparoscopic sigmoid resection was performed in 35.8 % of patients. The timing of the laparoscopic procedure varied greatly, ranging from 2 weeks to 21 months from the laparoscopic peritoneal lavage. In this group of patients, the conversion rate to open surgery 4.2 %. It has to be pointed out that the technique of laparoscopic lavage is not yet standardized so that there was a vast heterogeneity among the included studies, even in considering the criteria for a further routine sigmoidectomy after resolution of the acute phase.

Four RCTs have been initiated to better define the role of laparoscopic peritoneal lavage in patients with purulent peritonitis secondary to perforated diverticulitis. A few months ago, short-term results of the DILALA trial were published showing feasibility and safety of laparoscopic lavage as treatment for patients with Hinchey III diverticulitis [34]. A total of 83 patients with purulent peritonitis were randomized. Some 39 patients undergoing laparoscopic peritoneal lavage and 36 treated by an Hartmann procedure were available for analysis. Similar early postoperative morbidity and mortality rates were found in the two groups. Patients undergoing laparoscopic lavage had a shorter operative time, and shorter hospital stay. On the other side, concerns have been risen about the use of laparoscopic lavage even in selected patients after results of the LADIES trial were presented. This was the largest study on peritoneal lavage designed. Patients with purulent peritonitis were randomized to laparoscopic lavage and drainage, sigmoidectomy with primary anastomosis and sigmoidectomy with end colostomy in a 2:1:1 ratio. Recruitment was stopped early for the laparoscopic lavage and drainage arm due to safety issues, while the two other arms are still continuing the recruitment [35]. On the same way are the early results of the SCANDIV trials: among patients with likely perforated diverticulitis and undergoing emergency surgery, the use of laparoscopic lavage vs primary resection did not reduce severe postoperative complications and led to worse outcomes in secondary end points. These findings do not support laparoscopic lavage for treatment of perforated diverticulitis [36].

The last still ongoing trial is LAPLAND: its results is needed with the hope to more clearly establish the role of laparoscopic peritoneal lavage in the treatment of patients with purulent peritonitis secondary to acute perforated diverticulitis [37].

The most obvious advantage advocated by the supporters of this technique consists in the avoidance of a large laparotomy and derivative procedures, thus, reducing their consequent complications. Also a reduction of postoperative pain and the subsequent use of analgesics, a lowering of surgical site infections, a potential reduction of the rate of incisional hernias, and an amelioration in postoperative disability should be considered. In addition, the recurrence rate of acute diverticulitis' hantacks requiring hospitalization is low, and in most patients there is no need for a deferred colonic resection. Whenever an elective colonic resection is indicated, laparoscopic peritoneal lavage reduces adhesions, therefore, facilitating the laparoscopic approach [33, 38].

According to the controversial evidence currently available in the literature, laparoscopic peritoneal lavage should be considered an option for the treatment of purulent peritonitis secondary to perforated diverticulitis. In addition, the laparoscopic exploration of the peritoneal cavity helps categorize patients and better plan the surgical approach. However, the quality of evidence is still quite low; therefore, despite promising results, it seems too early to recommend the routine use of laparoscopic peritoneal lavage in clinical practice. As stated by the American Society of Colon and Rectal Surgeons (ASCRS) [39], “the poor quality of the existing literature on peritoneal lavage in aggregate and the inherent selection bias in the literature are major obstacles in advocating the widespread adoption of the laparoscopic lavage; the safety of lavage for purulent or fecal peritonitis has not been proven or disproven by the published studies to date”.

The low reversal rate of Hartmann's procedure is well known. In order to improve the permanent stoma rate, different approaches were proposed. Two RCTs appeared recently, comparing left colon resection with primary anastomosis and loop ileostomy) or non-restorative colon resection (left colon resection with end colostomy). Although both with an insufficient sample size, and with only few cases treated laparoscopically in only one study, both studies could demonstrate a significantly higher stoma reversal rate after primary anastomosis versus non-restorative resection [40, 41]. In truth both studies showed some flaws. Binda had planned a sample size of 600 patients and was forced to close the study after 9 years and only 90 patients recruited for the difficulty to enroll cases. On the contrary, Oberkofler closed the study prematurely for the evidence at an interim report of a significant better performance of the primary anastomosis group over the other mainly in terms of stoma reversal, although the sample size was calculated on the complications rate. It is known that trials stopped early with small numbers are at risk for overestimating any observed treatment effect. It is hard to know how premature termination affected

outcomes because it may have occurred at a time when the desired outcome was temporarily favored. In fact, based on the primary endpoint set as the total complications, this trial demonstrated no benefit of primary anastomosis over Hartmann's procedure. However much larger randomized controlled trials with strict eligibility criteria and randomization are required to answer this question.

Conclusion

With rapidly advancing technology and a greater number of trained surgeons, use of laparoscopy is emerging as the gold standard in the elective setting. More recently, surgeons are now attempting to take on the challenge of more complex interventions including emergency laparoscopic colorectal surgery.

We have reviewed the last years' evident literature about this last topic and the results reported, although mainly early, controversial and focused on the short term, enabled us to generally conclude that in a proper setting, laparoscopic colorectal emergency surgery is feasible, effective, safe and beneficial for patients to be a part of a common surgical practice, as long as adequate training is obtained and proper preparation observed when more advanced procedures are attempted in critically patients.

However, every surgeon has to decide the best approach according to a personal evaluation of his own experience, the particular clinical situation (selection of an appropriate case is important especially in the early part of any learning curve), his proficiency (and the experience of his team) with the various techniques and the specific organizational setting in which he is working. Early conversion is preferable where technical problems are anticipated. A low threshold for conversion carries only minor disadvantages for the patient.

Last but not least, Laparoscopy must not be used as an alternative to good clinical judgment.

Compliance with ethical standards

Conflict of interest All authors declare that they have no conflict of interest.

Ethical approval All procedures in our paper were in accordance with the ethical standards of the institutional as well as national research committee and with the 1964 Helsinki declaration and its later amendments.

Research involving human participants and/or animals This article does not contain any studies with human participants or animals performed by any of the authors.

Informed consent For this type of study formal consent is not required.

References

1. Agresta F, Campanile FC, Vettoreto N, Silecchia G, Bergamini C, Maida P, Lombardi P, Narilli P, Marchi D, Carrara A, Esposito MG, Fiume S, Miranda G, Barlera S, Davoli M, The Italian Surgical Societies Working Group (2015) Laparoscopic cholecystectomy: consensus conference-based guidelines. *Langenbecks Arch Surg* 400(4):429–453
2. Agresta F, Ansaloni L, Baiocchi GL, Bergamini C, Campanile FC, Carlucci M, Cocorullo G, Corradi A, Franzato B, Lupo M, Mandalà V, Mirabella A, Pernazza G, Piccoli M, Staudacher C, Vettoreto N, Zago M, Lettieri E, Levati A, Pietrini D, Scaglione M, De Masi S, De Placido G, Francucci M, Rasi M, Fingerhut A, Uranius S, Garattini S (2012) Laparoscopic approach to acute abdomen from the Consensus Development Conference of the Società Italiana di Chirurgia Endoscopica e nuove tecnologie (SICE), Associazione Chirurghi Ospedalieri Italiani (ACOI), Società Italiana di Chirurgia (SIC), Società Italiana di Chirurgia d'Urgenza e del Trauma (SICUT), Società Italiana di Chirurgia nell'Ospedalità Privata (SICOP), and the European Association for Endoscopic Surgery (EAES). *Surg Endosc* 26(8):2134–2164
3. Sauerland S, Agresta F, Bergamaschi R, Borzellino G, Budzynski A, Champault G, Fingerhut A, Isla A, Johansson M, Lunderoff P, Navez B, Saad S, Neugebauer EA (2006) Laparoscopy for abdominal emergencies: evidence-based guidelines of the European Association for Endoscopic Surgery. *Surg Endosc* 20(1):14–29
4. Chand M, Siddiqui MR, Gupta A, Rasheed S, Tekkis P, Parvaiz A, Mirnezami AH, Qureshi T (2014) Systematic review of emergent laparoscopic colorectal surgery for benign and malignant disease. *World J Gastroenterol* 20(45):16956–16963
5. Harji DP, Griffiths B, Burke D, Sagar PM (2014) Systematic review of emergency laparoscopic colorectal resection. *Br J Surg* 101(1):e126–e133
6. Frago R, Ramirez E, Millan M, Kreisler E, del Valle E, Biondo S (2014) Current management of acute malignant large bowel obstruction: a systematic review. *Am J Surg* 207:127–138
7. De Salvo GL, Gava C, Pucciarelli S, Lise M (2004) Curative surgery for obstruction from primary left colorectal carcinoma: primary or staged resection? *Cochrane Database Syst Rev* 2:CD002101
8. Arezzo A, Passera R, Ferri V, Gonella F, Cirocchi R, Morino M (2015) Laparoscopic right colectomy reduces short-term mortality and morbidity. Results of a systematic review and meta-analysis. *Int J Colorectal Dis* [Epub ahead of print]
9. Ng SS, Yiu RY, Li JC, Lee JF, Leung KL (2006) Emergency laparoscopically assisted right hemicolectomy for obstructing right-sided colon carcinoma. *J Laparoendosc Adv Surg Tech A* 16:350–354
10. Ng SS, Lee JF, Yiu RY, Li JC, Leung WW, Leung KL (2008) Emergency laparoscopic-assisted versus open right hemicolectomy for obstructing right-sided colonic carcinoma: a comparative study of short-term clinical outcomes. *World J Surg* 32:454–458
11. Li JC, Hon SS, Ng SS, Lee JF, Leung WW, Leung KL (2011) Emergency laparoscopic-assisted right hemicolectomy: can we achieve outcomes similar to elective operation? *J Laparoendosc Adv Surg Tech A* 21:701–704
12. Huang X, Lv B, Zhang S, Meng L (2014) Preoperative colonic stents versus emergency surgery for acute left-sided malignant colonic obstruction: a meta-analysis. *J Gastrointest Surg* 18:584–591
13. De Ceglie A, Filiberti R, Baron TH, Ceppi M, Conio M (2013) A meta-analysis of endoscopic stenting as bridge to surgery versus

- emergency surgery for left-sided colorectal cancer obstruction. *Crit Rev Oncol Hematol* 88(2):387–403
14. Sabbagh C, Browet F, Diouf M, Cosse C, Brehant O, Bartoli E, Mauvais F, Chauffert B, Dupas JL, Nguyen-Khac E, Regimbeau JM (2013) Is stenting as “a bridge to surgery” an oncologically safe strategy for the management of acute, left-sided, malignant, colonic obstruction? A comparative study with a propensity score analysis. *Ann Surg* 258:107–115
 15. van Hooft JE, van Halsema EE, Vanbiervliet G, Beets-Tan RG, DeWitt JM, Donnellan F, Dumonceau JM, Glynne-Jones RG, Hassan C, Jiménez-Perez J, Meisner S, Muthusamy VR, Parker MC, Regimbeau JM, Sabbagh C, Sagar J, Tanis PJ, Vandervoort J, Webster GJ, Manes G, Barthet MA, Repici A, European Society of Gastrointestinal Endoscopy (2014) Self-expandable metal stents for obstructing colonic and extracolonic cancer: European Society of Gastrointestinal Endoscopy (ESGE) Clinical Guideline. *Endoscopy* 46(11):990–1053
 16. van Hooft JE, van Halsema EE, Vanbiervliet G, Beets-Tan RG, DeWitt JM, Donnellan F, Dumonceau JM, Glynne-Jones RG, Hassan C, Jiménez-Perez J, Meisner S, Muthusamy VR, Parker MC, Regimbeau JM, Sabbagh C, Sagar J, Tanis PJ, Vandervoort J, Webster GJ, Manes G, Barthet MA, Repici A, European Society of Gastrointestinal Endoscopy (ESGE) (2014) Self-expandable metal stents for obstructing colonic and extracolonic cancer: European Society of Gastrointestinal Endoscopy (ESGE) Clinical Guideline. *Gastrointest Endosc* 80(5):747–61.e1–75
 17. Group CCCS (2009) The role of endoluminal stenting in the acute management of obstructing colorectal cancer. Available from <http://www.birmingham.ac.uk/Documents/college-mds/trials/bctu/crest/CRESTProtocolv2116072009.pdf>
 18. Enteral Stents for Colonic Obstruction (ESCO) (2016) Available from: <http://clinicaltrials.gov/ct2/show/NCT00591695>
 19. Boumitri C, Kumta NA, Patel M, Kahaleh M (2015) Closing perforations and postperforation management in endoscopy: duodenal, biliary, and colorectal. *Gastrointest Endosc Clin N Am* 25(1):47–54
 20. Agresta F, Michelet I, Mainente P, Bedin N (2000) Laparoscopic management of colonoscopic perforations. *Surg Endosc* 14(6):592–593
 21. Bleier JI, Moon V, Feingold D, Whelan RL, Arnell T, Sonoda T, Milsom JW, Lee SW (2008) Initial repair of iatrogenic colon perforation using laparoscopic methods. *Surg Endosc* 22:646–649
 22. Wu XJ, He XS, Zhou XY, Ke J, Lan P (2010) The role of laparoscopic surgery for ulcerative colitis: systematic review with meta-analysis. *Int J Colorectal Dis* 25:949–957
 23. Nash GM, Bleier J, Milsom JW, Trencheva K, Sonoda T, Lee SW (2010) Minimally invasive surgery is safe and effective for urgent and emergent colectomy. *Colorectal Dis* 12:480–484
 24. Watanabe K, Funayama Y, Fukushima K, Shibata C, Taka-hashiki K, Sasaki I (2009) Hand-assisted laparoscopic vs. open subtotal colectomy for severe ulcerative colitis. *Dis Colon Rectum* 52:640–645
 25. Marcello PW, Milsom JW, Wong SK, Brady K, Goormastic M, Fazio VW (2001) Laparoscopic total colectomy for acute colitis: a case-control study. *Dis Colon Rectum* 44:1441–1445
 26. Seshadri PA, Poulin EC, Schlachta CM, Cadeddu MO, Mamazza J (2001) Does a laparoscopic approach to total abdominal colectomy and proctocolectomy offer advantages? *Surg Endosc* 15:837–842
 27. Hinchey EJ, Schaal PG, Richards GK (1978) Treatment of perforated diverticular disease of the colon. *Adv Surg* 12:85–109
 28. Toorenvliet BR, Swank H, Schoones JW, Hamming JF, Bemelman WA (2010) Laparoscopic peritoneal lavage for perforated colonic diverticulitis: a systematic review. *Colorectal Dis* 12:862–867
 29. Salem L, Flum DR (2004) Primary anastomosis or Hartmann’s procedure for patients with diverticular peritonitis? A systematic review. *Dis Colon Rectum* 47:1953–1964
 30. O’Sullivan GC, Murphy D, O’Brien MG, Ireland A (1996) Laparoscopic management of generalized peritonitis due to perforated colonic diverticula. *Am J Surg* 171:432–434
 31. Krukowski ZH, Matheson NA (1988) Acute diverticulitis. *Rec Adv Surg* 13:125–141
 32. Myers E, Hurley M, O’Sullivan GC, Kavanagh D, Wilson I, Winter DC (2008) Laparoscopic peritoneal lavage for generalized peritonitis due to perforated diverticulitis. *Br J Surg* 95:97–101
 33. Cirocchi R, Trastulli S, Vettoretto N, Milani D, Cavaliere D, Renzi C, Adamenko O, Desiderio J, Burattini MF, Parisi A, Arezzo A, Fingerhut A (2015) Laparoscopic peritoneal lavage: a definitive treatment for diverticular peritonitis or a “bridge” to elective laparoscopic sigmoidectomy?: a systematic review. *Medicine (Baltimore)* 94(1):e334
 34. Angenete E, Thornell A, Burcharth J, Pommergaard HC, Skullman S, Bisgaard T, Jess P, Läckberg Z, Matthiessen P, Heath J, Rosenberg J, Haglund E (2014) Laparoscopic lavage is feasible and safe for the treatment of perforated diverticulitis with purulent peritonitis: the first results from the randomized controlled trial DILALA. *Ann Surg* [Epub ahead of print]
 35. Vennix S, Musters GD, Mulder IM, Swank HA, Consten EC, Belgers EH, van Geloven AA, Gerhards MF, Govaert MJ, van Grevenstein WM, Hoofwijk AG, Kruyt PM, Nienhuijs SW, Boermeester MA, Vermeulen J, van Dieren S, Lange JF, Bemelman WA; Ladies trial collaborators (2015) Laparoscopic peritoneal lavage or sigmoidectomy for perforated diverticulitis with purulent peritonitis: a multicentre, parallel-group, randomised, open-label trial. *Lancet*. doi:10.1016/S0140-6736(15)61168-0. [Epub ahead of print]
 36. Schultz JK, Yaqub S, Wallon C, Bleicic L, Forsmo HM, Folkesson J, Buchwald P, Körner H, Dahl FA, Øresland T, SCANDIV Study Group (2015) Laparoscopic lavage vs primary resection for acute perforated diverticulitis: the SCANDIV randomized clinical trial. *JAMA* 314(13):1364–1375
 37. Winter DC (2009) LapLAND laparoscopic lavage for acute non-faeculant diverticulitis. Available at: <http://clinicaltrials.gov/ct2/show/NCT01019239>
 38. Sorrentino M, Brizzolari M, Scarpa E, Malisan D, Bruschi F, Bertozzi S, Bernardi S, Petri R (2015) Laparoscopic peritoneal lavage for perforated colonic diverticulitis: a definitive treatment? Retrospective analysis of 63 cases. *Tech Coloproctol* 19(2):105–110
 39. Feingold D, Steele SR, Lee S, Kaiser A, Boushey R, Buie WD, Rafferty JF (2014) Practice parameters for the treatment of sigmoid diverticulitis. *Dis Colon Rectum* 57:284–294
 40. Binda GA, Karas JR, Serventi A, Sokmen S, Amato A, Hydo L, Bergamaschi R, Study Group on Diverticulitis (2012) Primary anastomosis vs non-restorative resection for perforated diverticulitis with peritonitis: a prematurely terminated randomized controlled trial. *Colorectal Dis* 14(11):1403–1410
 41. Oberkofler CE, Rickenbacher A, Raptis DA, Lehmann K, Villiger P, Buchli C, Grieder F, Gelpke H, Decurtins M, Tempia-Caliera AA, Demartines N, Hahnloser D, Clavien PA, Breitenstein S (2012) A multicenter randomized clinical trial of primary anastomosis or Hartmann’s procedure for perforated left colonic diverticulitis with purulent or fecal peritonitis. *Ann Surg* 256(5):819–826