

Morphological and Ultrastructural Changes in Human Endometrium Following Low-Dose Levonorgestrel Contraceptive Intrauterine Systems (LNG-IUS-12) 13.5 mg

Chai Minghan · Su Shili · Dong Baihua

Received: 13 July 2014 / Accepted: 16 September 2014 / Published online: 29 October 2014
© Federation of Obstetric & Gynecological Societies of India 2014

About the Author

Dr. Minghan Chai is a Obstetrician and Gynecologist in Qilu Hospital, Shandong University. She will get the degree of master in July 2015. Her major research direction is fertility regulation.



Abstract

Objective To study the effect of low-dose levonorgestrel contraceptive intrauterine systems (LNG-IUS-12) on endometrial morphology and ultrastructure.

Methods Twenty seven women who desired contraception were inserted LNG-IUS-12. Endometrial biopsies were collected during the late proliferative phase of the cycle before (control) and after the use of the LNG-IUS for 36 months. The changes of morphology and ultrastructure of endometrium tissue were observed by light microscope and transmission electron microscope.

Results After 36 months of use, the endometrial gland reduced in number and some were atrophic. A decidual change of stroma was present. Electronic microscopy demonstrated the presence of low columnar, karyopyknosis, and

chromatin margination in the glandular epithelial cell. Some vacuolar degeneration in partial mitochondria and rough endoplasmic reticulum presented light extension. Changes could be concluded as cell inhibition of proliferation.

Conclusions The low-dose levonorgestrel-releasing intrauterine systems has a suppressive effect on endometrium that is similar to LNG-IUS.

Keywords

Low-dose levonorgestrel-releasing intrauterine systems (LNG-IUS-12) · Light microscope · Transmission electron microscope (TEM)

Introduction

The levonorgestrel-releasing intrauterine systems (LNG-IUS) is a highly effective contraceptive method with few adverse effects. It comprises a T-shaped plastic frame, with a cylinder of the synthetic progestogen levonorgestrel

Chai M., Obstetrician and Gynecologist · Su S. · Dong B. (✉)
Department of Gynecology and Obstetrics, Qilu Hospital,
Shandong University, 107#, West Wenhua Road, Jinan 250012,
China
e-mail: baihuadong@hotmail.com

(52 mg), enclosed in a silastic sleeve allowing the controlled slow release of 20 µg daily of hormone into the uterine cavity. LNG from this system lead to obvious and profound effects on endometrial morphology and function atrophy of gland and changes in vascular morphology, an extensive decidualization of the stroma, increased stromal inflammatory reaction and dilation of capillaries, occasionally accompanied by thrombosis [1, 2]. Moreover, the change of the uterine environment brings efficient contraception. For one thing, an altered cervical mucus from LNG that acts as a barrier to sperm migration, plus the endometrial atrophy that prevents sperm-egg binding were the main mechanism of contraception [3]. For another, the down-regulation of ER and PR in glands and stroma of the endometrium can inhibit cellular proliferation, and embryo implantation can thus be interrupted [4]. Besides, it exerts effects on endometrium that bring some therapeutical benefits. From the extensive conventional research, we know the LNG-IUS delivered LNG into the uterine cavity at a steady rate, has provided effects in the field of non-contraceptive, including treatment of heavy menstrual blood loss, alleviation of dysmenorrhea associated with endometriosis, adenomyosis, and endometrial protection in hormone replacement therapy (HRT) [5–7]. Xu et al. [8] indicated that high concentrations of LNG suppressed the proliferation of uterine leiomyoma cells and promoted cell apoptosis. Furthermore, preliminary clinical studies suggest the LNG-IUS as a means of reducing endometrial pathology associated with tamoxifen patients with endometrial carcinoma [9].

All the benefits mentioned above mainly result from the constant release of LNG directly into the uterine cavity causing local effects. Thus, we have not determined whether the reduction of LNG could have the same effect on endometrium of healthy women, especially in the changes in morphology and ultrastructure.

The purpose of present research was to study the effect of low-dose LNG-IUS on endometrium, which contains a reservoir of 13.5 mg of LNG with continuous release of the LNG at the rate of 12 µg/24 h into uterus cavity and has a life span of 3 years. We aimed to study the changes of morphology and ultrastructure of endometrium after the insertion of the low-dose LNG-IUS (LNG-IUS-12) in normal women.

Materials and Methods

This retrospective cohort study was carried out in Qilu hospital (Shandong University, People's Republic of China) from April 2009 to May 2013. All subjects signed an informed consent, and Institutional Review Board approval was obtained by the Ethics Committee of Qilu Hospital.

Twenty seven healthy women who wished to use contraception were admitted to the study and agreed to the insertion of LNG-IUS-12 (Bayer Schering Oy, Finland). Subjects with known or suspected pregnancy, uterine malformation, or any other chronic disease and thromboembolic phenomena were excluded; women with a history of pelvic inflammatory disease within the last 3 months, and those at risk or with a previous history of sexually transmitted infections were also excluded from the study.

The endometrial biopsies were taken from the baseline pre-LNG-IUS-12 and after 36-months inserted phase. The specimens were fixed in 10 % formalin and embedded in paraffin. Paraffin sections were routinely stained with hematoxylin and eosin for observation of endometrial morphology.

The changes of ultrastructure of endometrium were observed by transmission electron microscope: fresh tissue were washed with phosphate buffered saline (PBS), and then fixed by 2.5 % glutaric dialdehydes and 1 % perosmic oxide for the observation of endometrial ultrastructure changes under a transmission electron microscope.

Results

Twenty seven participants were fitted with the LNG-IUS-12 during the follow-up. Two left due to expulsion of the device for irregular bleeding; one case dropped out in 3 months; and one patient never returned for a study visit after insertion. Twenty three participants completed 36 months of observation. In our study, no pregnancies occurred, and no cases of pelvic inflammatory disease occurred.

Patient Characteristics

The mean age of the 27 participants at admission was 35 years. All participants were married. The mean numbers of pregnancies and births were two and one, respectively. And the mean body mass index (BMI) was 21.9 kg/m² (SD = 2.4; range 18.8–27.2 kg/m²).

General Light Microscopic Changes

No biopsy could be obtained in three cases because of endometrial atrophy. After the insertion of a LNG-IUS-12 for 3 years, the endometrium was thin and atrophic; the number of glands decreased and the epithelial cells were flat; the stroma became decidualized. Compared to the biopsies with non-insertion of IUS, the stromal inflammatory reaction was increased, including the infiltration of leukocytes, lymphocytes, phagocytes, and plasma cells. The capillaries were dilated, occasionally accompanied by thrombosis (Fig. 1).

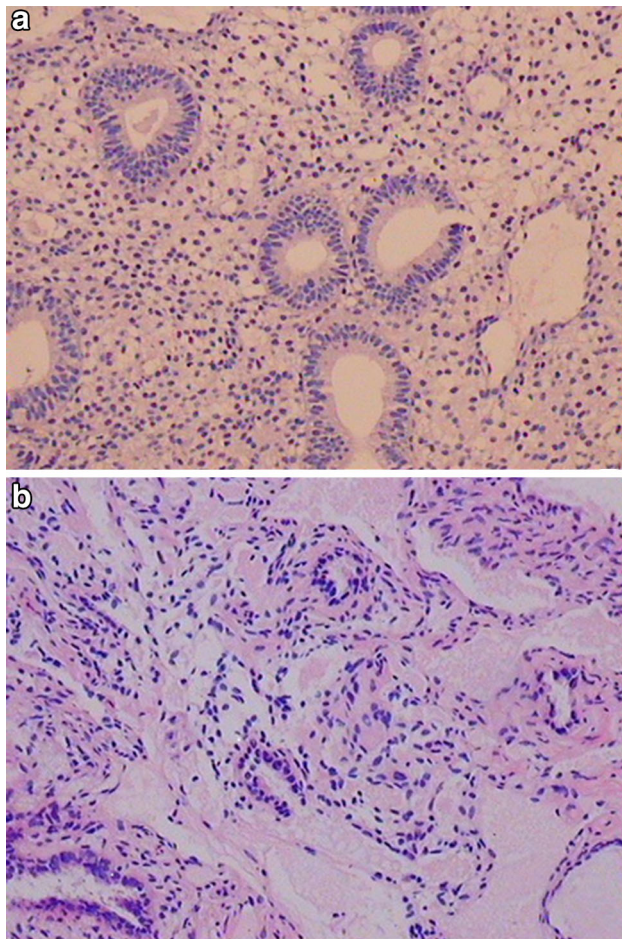


Fig. 1 **a** Normal endometrial proliferative phase before LNG-IUS-12 insertion, (HE $\times 40$). **b** Decrease in the number of glands, and some of its atrophic, decidualized stroma after insertion of LNG-IUS-12, (HE $\times 40$)

The Ultrastructural Changes of Endometrium

We found low columnar glandular epithelial cells. The nucleus has been divided into several fragments that was similar to apoptotic bodies, and the chromatin has condensed into a higher electron density of briquette. Chromatin margination and concentration are seen in groups situated at the edge of the nuclear membrane, which present a trend of apoptosis. The cytoplasm is dense, and the organelles are more tightly packed. The rough-surfaced endoplasmic reticulum expanded lightly. Some mitochondria became irregularly swollen and displayed vacuolar degeneration, their edges fractured and became fuzzy. Moreover, a variety of granular inclusion bodies and nuclear membrane-like structures are scattered in cytoplasm. The phenomenon could be concluded as cell denaturalization and inhibition of proliferation (Fig. 2).

Discussion

The LNG-IUS-12 has been developed by Bayer Health care, which consists of a T-shaped polyethylene frame (28 \times 30 mm) with a levonorgestrel (LNG) containing reservoir around its vertical stem and contains 13.5 mg of LNG. It releases 12 $\mu\text{g}/24$ h LNG into uterus cavity and has a life span of 3 years. In this study, the morphological changes of endometrium that is atrophic and inactive were similar to LNG-IUS-20 [1, 2, 10]. 12 μg of LNG per day proved to be effective in producing the suppression characterized by glandular atrophy and decidualization of stroma. Endometrial glands decreased in number and distribution, some glands were atrophic and the epithelial cells were flat; a decidual change of partial stroma with inflammatory reaction was found. Moreover, relevant article identified that the endometrial changes relied on the LNG are related with apoptosis [11]. Likewise, glandular cell atrophy and obvious karyopyknosis were showed in ultrastructural changes; chromatin concentration and margination were seen in LNG-IUS group situated at the edge of the nuclear membrane that present a state of cell apoptosis. Consequently, we demonstrated the low dose of LNG can also result in inhibition of endometrial proliferation, which is consistent with previous studies that might be the explanation for the change of menstruation.

Although the effects of LNG on the uterine endometrium become active very promptly following insertion of the LNG-IUS, the effects disappear quickly when the device leaves the uterine cavity. Researchers found that removal of the LNG-IUS results in the rapid regeneration of the endometrium and normal menstruation occurs within 30 days [12]. In this study, most women using LNG-IUS-12 had regular cycles. Only six women had amenorrhea after the use of IUS for 3 years. We had continued making a follow-up for them, their menstrual cycle were observed to return to normal within 2 months after the removal of IUD, which means that the morphological appearance of the endometrium returns to normal, and this is associated with a complete return of fertility. Thus, we elucidate that LNG-IUS-12 is more acceptable in women who wished to continue their pregnancy.

LNG-IUS-12 is a new intrauterine contraceptive system for up to 3 years use with an average in vitro release rate of 12 μg of LNG per day. The lack of an appropriate control group and minor sample are limitations of the present study. Furthermore, LNG-IUS-12 is not used widespread in the field of contraceptive and treatment of disease in China recently. We had not evaluated the extent of suppression in endometrium after LNG-IUS-12 insertion. Hence, our research should be carried on as an adequately powered and well-designed randomized controlled trial to assess the

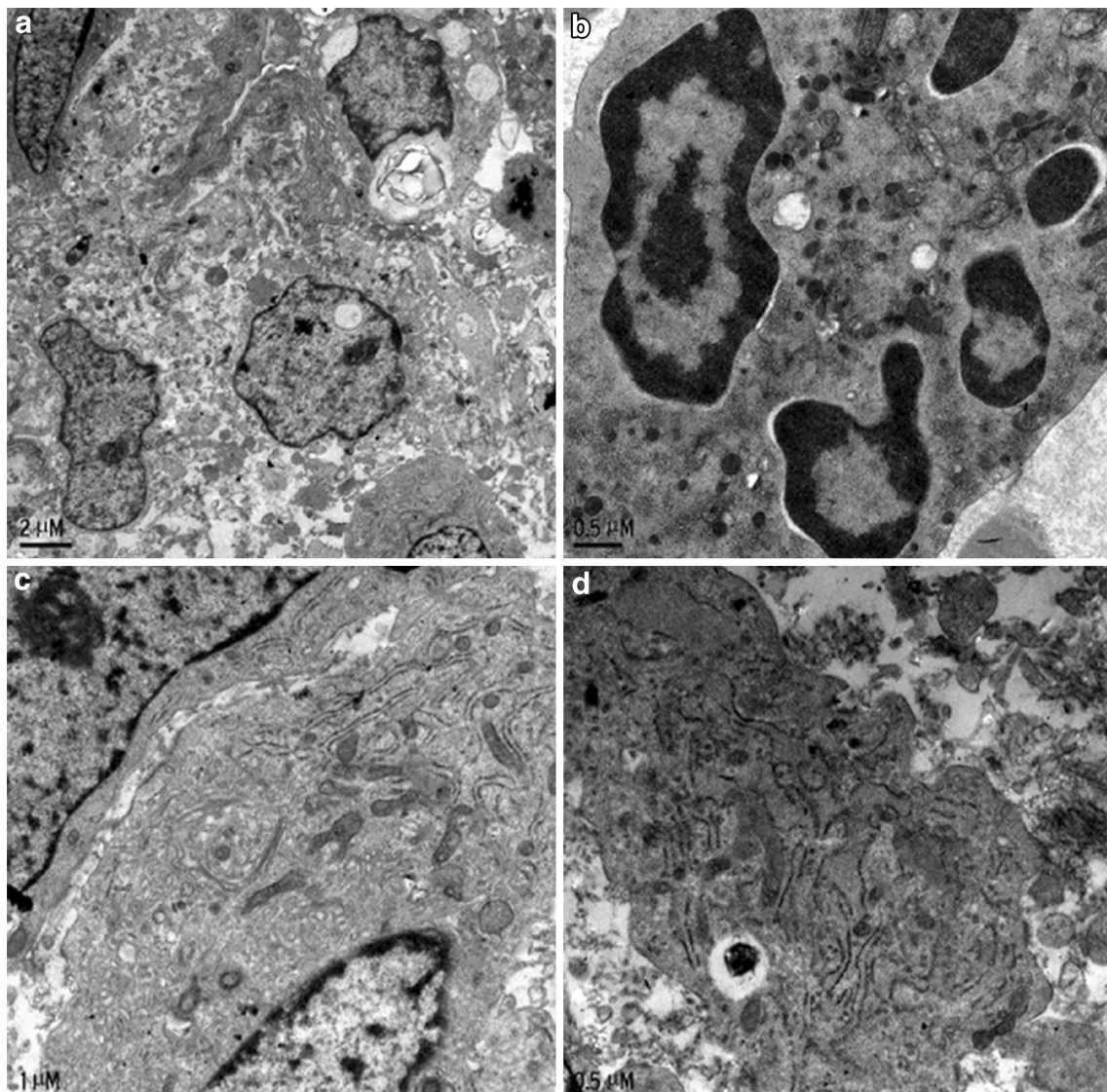


Fig. 2 **a** Low columnar glandular epithelial cells, several higher electron density of briquettes are observed, (original magnification $\times 4,000$). **b** Fragmented section of nucleus and several fragments across visual field. The cytoplasm is beginning to condense. Cell shrinkage and irregular outlines; vacuolar degeneration in partial

mitochondria, (original magnification $\times 15,000$). **c** Some mitochondria became irregularly swollen and displayed vacuolar degeneration, their edges fractured and became fuzzy, (original magnification $\times 12,000$). **d** The rough-surfaced endoplasmic reticulum is expanded lightly, (original magnification $\times 15,000$)

effect of LNG-IUS-12 on endometrium by further experimental studies. Nonetheless, we believe our study may serve as an impetus for future research on the difference of profound morphology or other aspects between LNG-IUS-20 and LNG-IUS-12.

The conclusion can be drawn that a low dose of LNG also has prolonged morphological and functional effects on endometrium. The LNG-IUS-12 users all showed suppressed endometrial proliferative activity similar to the changes found in the LNG-IUS-20 users. Our study summarizes the effects of LNG upon endometrial morphology to conclude that LNG-IUS-12 provides an effective, miniature and reversible delivery system released for endometrial

suppression in normal women that may avoid systemic effects and bring more benefits. This is just a speculation, and further study is needed. We hope there is a need for further confirmatory research to verify our findings.

Compliance with ethical requirements and Conflict of interest The study was initiated after getting approval of the study from Institutional Review Board (IRB)/Independent Ethics Committee (IEC), in compliance with local laws. Ethical principles that have their origin in the world medical association declaration of Helsinki, and all applicable local laws, rules, and regulations relating to the conduct of the study were followed. The authors acknowledge the contributions of Liyan Wang for excellent technical assistance. No conflict of interest exists in the submission of this manuscript.

References

1. Critchley HO, Wang H, Jones RL, et al. Morphological and functional features of endometrial decidualization following long-term intrauterine levonorgestrel delivery [J]. *Human Reprod.* 1998;13(5):1218–24.
2. Gu Z, Zhu P, Luo H, et al. A morphometric study on the endometrial activity of women before and after 1 year with LNG-IUD in situ. *Contraception.* 1995;52(1):57–61.
3. Lewis RA, Taylor D, Natavio MF, et al. Effects of the levonorgestrel-releasing intrauterine system on cervical mucus quality and sperm penetrability. *Contraception.* 2010;82(6):491–6.
4. Guttinger A, Critchley HO. Endometrial effects of intrauterine levonorgestrel. *Contraception.* 2007;75(6):93–8.
5. Rodriguez MI, Darney PD. Non-contraceptive applications of the levonorgestrel intrauterine system. *Int J Women's Health.* 2010;2:63–8.
6. Inki P. Long-term use of the levonorgestrel intrauterine system. *Contraception.* 2007;75(6):161–6.
7. Fraser IS. Add health benefits of the levonorgestrel contraceptive intrauterine system and other hormonal contraceptive delivery system. *Contraception.* 2013;87(3):273–9.
8. Xu Q, Qiu L, Zhu L, et al. Levonorgestrel inhibits proliferation and induces apoptosis in uterine leiomyoma cells. *Contraception.* 2010;82(3):301–8.
9. Kim MK, Seong SJ, Kim YS, et al. Combined medroxyprogesterone acetate/levonorgestrel-intrauterine system treatment in young women with early stage endometrial cancer. *Am J Obstet Gynecol.* 2013;209(4):358e1–4.
10. Jones RL, Critchley HOD. Morphological and functional changes in human endometrium following intrauterine levonorgestrel delivery. *Human Reprod.* 2000;15(3):162–72.
11. Haliloglu B, Celik A, Ilter E, et al. Comparison of uterine artery blood flow with levonorgestrel intrauterine system and copper intrauterine device. *Contraception.* 2011;83(6):578–81.
12. Sheppard BL, Phil D, Path MRC. Endometrial morphological changes in IUD users: a review. *Contraception.* 1987;36:1–10.