

## Abdominal Compartment Syndrome Due to OHSS

Veisi Firoozeh · Zangeneh Maryam ·  
Malekkhosravi Shohreh · Rezavand Negin

Received: 24 June 2011 / Accepted: 24 April 2012 / Published online: 28 September 2013  
© Federation of Obstetric & Gynecological Societies of India 2013

### Introduction

Infertility is a relatively common disorder. An estimated population of about 40.5 million seek therapy [1]. Ovarian hyperstimulation syndrome (OHSS) is an iatrogenic complication of ovulation stimulation in ART [2]. The prevalence of mild OHSS is 20–23 % of IVF cycles, while a 3–6 % moderate and 0.1–2 % severe form were reported as well [3–5]. Despite several factors contributing to increased vascular permeability, the pathophysiology of this syndrome remains unknown [6, 7]. Adnexal torsion, rupture of ovarian cysts, hemoperitoneum, thrombotic events, and anesthesia complications may be the consequences of OHSS [8–12]. Abdominal compartment syndrome (ACS) is quite rare considering the ART protocol, but can be fatal [13–15]. Several therapies have been proposed for severe OHSS [16–20]. However, ACS needs laparotomy.

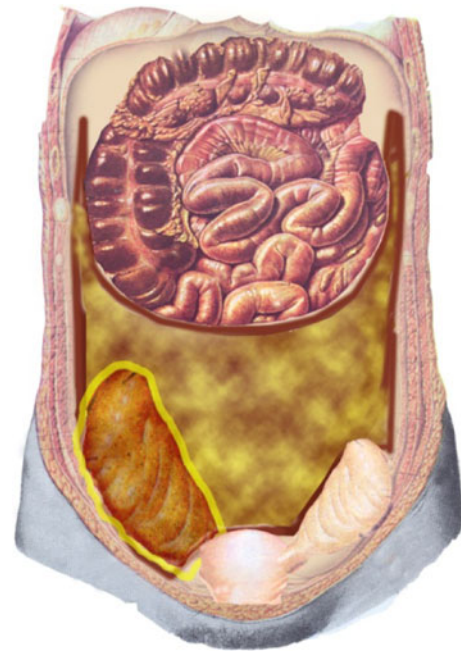
### Case

A 28-year-old woman was referred to the emergency department complaining of abdominal pain. She had a history of primary infertility for 10 years. Hormonal tests were prolactin = 18 ng/dL, FBS = 103 mg/dL, and TSH = 3.5  $\mu$ U/L. Oocytes were retrieved and 10 embryos were prepared. Owing to ovarian hyperstimulation, the embryos were frozen and GnRH antagonist was administered. Four days later, she presented with abdominal discomfort and dyspnea. Vital signs were RR = 28/min, PR = 120/min,  $T$  = 38.5 °C, and BP = 100/70 mmHg. Physical examination revealed, abdominal distension and tenderness, subicteric sclera, and oliguria was detected. Abdominal circumference = 120 cm, weight = 90 kg, and height = 170 cm. Lab: Hb = 12.2 mg/dL, WBC = 21.6 with shift to left, sodium = 135, potassium = 4.2, AST = 75, ALT = 60, Alk p = 380, and BS = 140. CXR revealed bilateral pleural effusion. Albumin = 2.8, direct bilirubin = 8.2, and indirect bilirubin = 2.1.

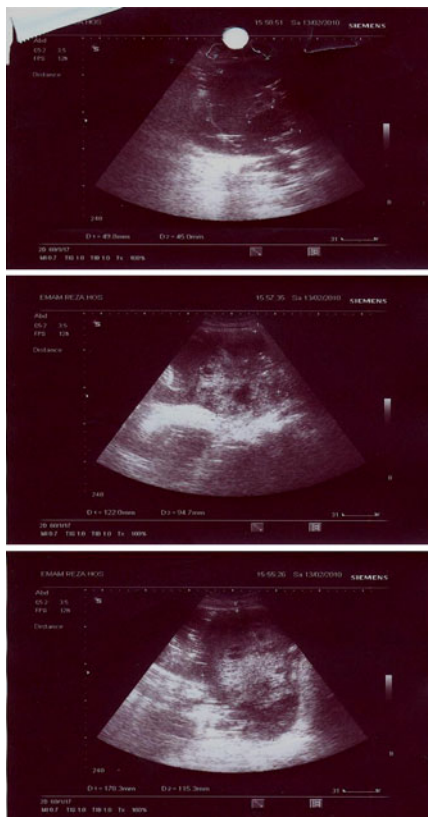Sonographic examination revealed multiple cysts in both ovary, free fluid in the abdomen, pleural effusion, and the initial diagnosis was OHSS. After taking blood sample, we started with ceftriaxone (1 g BD), venous crystalloids, albumin vial, and prophylactic heparin. On the third day, the patient developed a fever again with her vital signs as follows: BP = 90/60 mmHg, RR = 38/min, PR = 130/min, and  $T$  = 40 °C. Metronidazole and gentamycin were added to her antibiotic regimen. Sonography confirmed gas-filled abdomen with copious amounts of fluid in the abdominal and pelvic cavities, and large multicystic

Veisi F. (✉), Assistant Professor · Zangeneh M., Assistant Professor · Malekkhosravi S., Assistant Professor · Rezavand N., Assistant Professor  
High Risk Pregnancy Research Center, Obstetrics and Gynecology Department, Imam Reza Hospital, Kermanshah University of Medical Sciences, Parastar Avenue, Kermanshah, Iran  
e-mail: firoozehveisi@yahoo.com; f\_veisi@kums.ac.ir

ovaries (Fig. 1). Owing to the increasing distension and dyspnea despite supportive measurement, the patient was immediately prepared for laparotomy with an impression of ACS and peritonitis. Once the abdomen was opened, copious amounts of pus and gas ejected as high as 1.5 m, similar to a volcano. The abdominal fluid was purulent and foul-smelling. A cavity with definite boundaries was observed, filled with gas and pus, started from the pelvic with a tendency to the right side and reached the abdominal wall on both sides, pushing the intestines against the diaphragm (Fig. 2). Pus and gas reached the diaphragm in the paracolic grooves on both sides. The right ovary was discovered with a size of 150 × 180 mm, with copious pus surrounding it. About 4 L of pus was removed from the abdominal cavity. As the intestinal loops above the cavity, as well as the uterus and left ovary outside the cavity, were intact, we decided not to manipulate them. The abdominal cavity was irrigated with 10 L normal saline. Two petzer drains were placed on the sides of the pelvic cavity. Intravenous antibiotics continued. On the day following the surgery, the fever decreased and was resolved on the third day. Abdominal distension, decreased after surgery, reappeared after 3 days. Abdominal examination revealed fluid collection which increased in volume 5 days after



**Fig. 2** The entire abdominal cavity and both paracolic grooves were filled with pus up to the diaphragm. The necrotic right ovary with copious purulent collection, the uterus and the left ovary lied outside the cavity



**Fig. 1** Enlargement of ovaries and abdominal fluid despite therapy on the third day

surgery. The fever was resolved and appropriate urinary output was established. The lab tests on the fifth day after surgery are as follows: BS = 225; TSH = 11  $\mu$ U/L; electrolytes, renal, and hepatic tests were normal. The abdominal fluid was aspirated under sonographic guidance. About 1 L of a serous liquid with some particles was extracted which was not purulent or foul-smelling. The preserved left ovary sustained its large size with numerous follicles and cysts, giving it the view of hyperstimulation. It appeared that the refractory hyperstimulation syndrome caused the recurrent abdominal distension through serous oozing from the surface of the preserved ovary. Dosage of metformin (TDS) and levothyroxin 50  $\mu$ g daily was initiated. Two days later, the free fluid in abdomen decreased, and sonography reported the amount of abdominal fluid as moderate on day 10, and as minimal on day 15. Six months later the preserved left ovary was of normal size and had active follicles.

## Discussion

ACS is a dangerous clinical situation, usually following abdominal injuries and operations. In most cases, it leads to abdominal inflammation or peritonitis, entailing a high risk of mortality [12]. It is seldom observed in patients with gynecologic and obstetric problems. In our patient, severe sustained ascites collection and entry of microorganism via

the ovarian puncture resulted in peritonitis and the ACS. Oliguria and constipation indicated pressure on the urinary and GI system. Several cases of obstructive uropathy caused by ascites have been reported in OHSS, which have been managed with DJ catheter to prevent from renal failure [14].

Predicting factors for OHSS include low age, low weight, endocrine evaluations, and previous episodes of hyperstimulation [6, 22–25]. In our patient, the endocrine tests were initially normal, and a diagnosis of PCO was established only because of the increased LH/FSH ratio. However, as the disease progressed, hypothyroidism and diabetes were indicated. The initial value of about 3.5  $\mu\text{U/L}$  for TSH reached 11  $\mu\text{U/L}$  during the course of the disease, which seems to indicate treatment with levothyroxin in cases of PCO with TSH levels in the upper normal limit. Fluid collection in the third space resulted in pressure on pelvic organs, indicating laparotomy for abdominal decompression. The persistence of the condition may be attributed to the endocrine disorder. Following the extraction of purulent discharges, the patient was expected to experience improvement. However, copious serous fluid accumulated in the abdomen a few days later alongside swollen follicles in the preserved ovary. Cil et al. [26] reported one case that recovered after laparotomy and abdominal decompression. In our case, infection and elevated intra-abdominal pressure resolved following laparotomy, whereas serous oozing into third space persisted, which came to be resolved only after the endocrine disorders were addressed with levothyroxin and metformin. Most articles consider polycystic ovaries as the most important risk factor for OHSS [27]. Insulin resistance, hypothyroidism, and hyperprolactinemia are the most common causes of PCO. In the case of our patients, however, the blood sugar and thyroid tests were normal before ovarian induction, and the endocrine disorders manifested only after the aggravation of the disease and the laparotomy. PCO patients are recommended to consume metformin despite normal blood sugar, because of the insulin resistance. However, the studies do not recommend prophylactic administration of levothyroxin for ovarian induction. Transvaginal oocyte retrieval (TVOR) is the method of choice for retrieving oocytes in most fertility clinics, as it entail less danger to the large pelvic vessels which are visible in this method [28]. It is not, however, free of risks and cases of hemorrhage, hemoperitoneum, injury to pelvic organs, infection, and endometrial rupture have been reported [29, 30]. In one study conducted on 2,670 patients who underwent TVOR without receiving prophylactic antibiotics, the incidence of pelvic infection was reportedly 0.6 % [31]. Ovarian abscesses have been reported following TVOR [32]. Sepsis caused by pelvic infection is a life-threatening condition. Unfortunately, our patient had developed ovarian abscess and peritonitis caused by pelvic

infection. Lack of antibiotics before oocyte retrieval, undiagnosed diabetes, and hypothyroidism can lead to persistent hyperstimulation and pelvic infection.

## Conclusion

We concluded that ovarian hyperstimulation can be persistent because of endocrine underline disorders, and break in sterile technique may cause an operative site contamination.

**Acknowledgments** I would like to thank Somayyeh Amiri-moghaddam, MD (Moallem Educational & Cultural Institute, Tehran, I.R. Iran for editing the English version. This study was supported by High Risk Pregnancy Research Center, Kermanshah University of Medical Sciences, Kermanshah, Iran.

## References

- Boivin J, Bunting L, Collins JA. New debate: international estimates of infertility prevalence and treatment-seeking: potential need and demand for infertility medical care. *Hum Reprod*. 2007;22:1506–12.
- Delvigne A, Rozenberg S. Review of clinical course and treatment of ovarian hyperstimulation syndrome. *Hum Reprod Update*. 2003;9:77–96.
- Navot D, Bergh PA, Laufer N. Ovarian hyperstimulation syndrome in novel reproductive technologies: prevention and treatment. *Fertile Steril*. 1992;58:249–61.
- Golan A, Ron-El R, Herman A. Ovarian hyperstimulation syndrome: an update review. *Obstet Gynecol Surv*. 1989;44:430–40.
- Brinsden PR, Wada I, Tan SL. Review: diagnosis, prevention and management of ovarian hyperstimulation syndrome. *Br J Obstet Gynecol*. 1995;102:767–72.
- Albert C, Garrido N, Mercader A, et al. The role of endothelial cells in the pathogenesis of ovarian hyperstimulation syndrome. *Hum Reprod Update*. 2002;8:409–18.
- Gomez R, Simon C, Remohi J, et al. Vascular endothelial growth factor receptor-2 activation induces vascular permeability in hyperstimulated rats and this effect is prevented by receptor blockade. *Endocrinology*. 2003;143:4339–488.
- Gunabushanam G, Mandal K, Lai S. Hemoperitoneum from ruptured cyst in a hyperstimulated ovary: a sonographic mimic of ovarian hyperstimulation syndrome. *J Clin Ultrasound*. 2007;35:281–3.
- Qazi A, Ahmad AN, Qazi MP, et al. Ischaemic stroke with ovarian hyperstimulation syndrome. *J Pak Med Assoc*. 2008;58:411–3.
- Alasiri SA, Case AM. Thrombosis of subclavian and internal jugular veins following sever ovarian hyperstimulation syndrome: a case report. *J Obstet Gynaecol Can*. 2008;30:590–7.
- Bodri D, Guillen JJ, Polo A, et al. Complications related to ovarian stimulation and oocyte retrieval in 4052 oocyte donor cycles. *Reprod Biomed Online*. 2008;17:237–43.
- Kawamura G, Ito N, Hanaoka K, et al. Anesthetic management of a patient with sever ovarian hyperstimulation syndrome. *Masui*. 2009;58:360–2.
- Celoria G, Steingrub J, Dawson JA, et al. Oliguria from high intra-abdominal pressure secondary to ovarian mass. *Crit Care Med*. 1987;15:78–9.
- Merrilees DA, Kennedy-Smith A, Robinson RG. Obstructive uropathy as the etiology of renal failure in ovarian hyperstimulation syndrome. *Fertil Steril*. 2008;89:992.
- Scheppach W. Abdominal compartment syndrome. *Best Prac Res Clin Gastroenterol*. 2009;23:25–33.

16. Smith LP, Hacker MR, Alper MM. Patients with severe ovarian hyperstimulation syndrome can be managed safely with aggressive outpatient transvaginal paracentesis. *Fertil Steril*. 2009;92:1953–9.
17. Lainas TG, Sfontouris IA, Zorzovilis IZ, et al. Live births after management of severe OHSS by GnRH antagonist administration in the luteal phase. *Reprod Biomed Online*. 2009;19:789–95.
18. Lainas TG, Sfontouris IA, Zorzovilis IZ, et al. Management of severe early ovarian hyperstimulation syndrome by re-initiation of GnRH antagonist. *Reprod Biomed Online*. 2007;15:408–12.
19. Queenan TJ. Embryo freezing to prevent ovarian hyperstimulation syndrome. *Mol Cell Endocrinol*. 2000;169:79–83.
20. Ata B, Seyhan A, Orhaner S, et al. High dose cabergoline in management of ovarian hyperstimulation syndrome. *Fertil Steril*. 2009;92:1168.
21. Vyhnanek F. Abdominal catastrophe—surgeons view. *Rozh Chir*. 2010;89:356–60.
22. Licciardi FL, Liu HC, Rosenwaks Z. Day 3 estradiol serum concentrations as prognosticators of ovarian stimulation response and pregnancy outcome in patients undergoing in vitro fertilization. *Fertil Steril*. 1995;64:991–4.
23. Rosenwaks Z, Davis OK, Damario MA. The role of maternal age in assisted reproduction. *Hum Reprod*. 1995;10:165–73.
24. Seifer DB, Lambert-Messierian G, Hogan JW, et al. Day 3 serum inhibin-B is predictive of assisted reproductive technologies outcome. *Fertil Steril*. 1997;12:220–3.
25. Buyalos RP, Lee CT. Polycystic ovary syndrome: pathophysiology and outcome with in vitro fertilization. *Fertil Steril*. 1996;65:1.
26. Cil T, Tummon IS, House A, et al. A tale of two syndromes: ovarian hyperstimulation and abdominal compartment. *Hum Reprod*. 2000;15:1058–60.
27. Delvigne A, Rozenberg S. Epidemiology and prevention of ovarian hyperstimulation syndrome: a review. *Hum Reprod Update*. 2002;8:559–77.
28. Wikland M, Hamberger L, Enk L. Technical and clinical aspects of ultrasound-guided oocyte. *Hum Reprod*. 1989;4:79–92.
29. Dicker D, Dekel A, Orvieto R, et al. Ovarian abscess after ovum retrieval for in vitro fertilization. *Hum Reprod*. 1998;13:1813–4.
30. Scoccia B, Marcovici I, Brandt T. Uterine abscess after ultrasound-guided ovum retrieval in an in vitro fertilization-embryo transfer program: case report and review of the literature. *J Assist Reprod Genet*. 1992;9:285–9.
31. Bennet SJ, Waterstone JJ, Cheng WC, et al. Complications of transvaginal ultrasound-directed follicle aspiration: a review of 2670 consecutive procedures. *J Assist Reprod Genet*. 1993;10:72–7.
32. Kelada E, Ghani R. Bilateral ovarian abscesses following transvaginal oocyte retrieval for IVF: a case report and review of literature. *J Assist Reprod Genet*. 2007;24:143–5.