

Effectiveness of Human Amnion as a Graft Material in Lower Anterior Ridge Vestibuloplasty: A Clinical Study

Yogesh Sharma · Anisha Maria · Preeti Kaur

Received: 5 August 2010 / Accepted: 17 April 2011 / Published online: 6 May 2011
© Association of Oral and Maxillofacial Surgeons of India 2011

Abstract

Objective The aim of this study is to evaluate the clinical use of amnion as a biodegradable graft material for lower anterior ridge vestibuloplasty.

Study Design Ten patients who had been referred for pre-prosthetic surgery underwent mandibular anterior ridge vestibuloplasty using Clark's technique and amniotic membrane as a graft material. Preoperative vestibular depth was measured. Fresh amniotic membrane was placed in the surgical site and sutured with 4–0 vicryl. In all ten cases suction catheter stent was used and was secured in the depth of the vestibule by using 1–0 mersilk percutaneous sutures.

Results Vestibular depths were measured using a divider and a scale. Post operative measurements were taken at the end of 10th day, 1st month and 3rd month. And an average gain of 4–6 mm in the depth of the labial vestibule was noted.

Conclusion Amniotic membrane can be a favorable graft material for vestibuloplasty, promoting healing and preventing relapse. It is easily available and preserved and a cost effective material.

Keywords Amniotic membrane · Vestibuloplasty · Graft material · Biodegradable

Introduction

Vestibuloplasty is the surgical procedure whereby the oral vestibule is deepened by changing the soft tissue attachments. This procedure increases the size of denture bearing area and the height of residual alveolar ridge [1].

Various materials have been used to cover the denuded periosteum after mandibular vestibuloplasty, such as mucosal and skin grafts. However, palatal grafts can provide only a limited amount of transplantable mucosa. Furthermore, they are associated with patient discomfort at the donor site. Skin grafts also have many disadvantages like lack of denture adhesion, the presence of hair, contraction of the graft and the need for a secondary donor site [2].

Davis introduced the use of human fetal membranes in skin transplantation in 1910 and 3 years later Sabella described its use for burnt and ulcerated skin surfaces [3, 4]. Amnion is the inner layer that is continuous with the ectoderm of the embryo. It has an inner surface of cuboidal or flattened epithelial cells and an outer surface covered with mesenchymal connective tissue. The use of amniotic membranes offers the advantage that the thicker intact membrane can be handled more easily and remains on the wound longer than amnion by itself. In 1952, Douglas reported the use of amniotic membranes to temporarily cover burn wounds. Since then this material has yielded good results as a temporary wound dressing & is mostly used to treat burns [3, 4]. Fresh amnion has generally been used but frozen [5], dried [6], irradiated [6] and lyophilized [7] preparations have also been used.

The use of amnion in vestibuloplasty has only been once reported by Guler et al., who concentrated on studying the blood flow to the graft [2]. The aim of this study was to evaluate the clinical use of amnion as a biodegradable graft material for lower anterior ridge vestibuloplasty.

Materials and Methods

Ten patients comprising of three women and seven men (mean age = 58.5 years) with no known systemic disease,

Y. Sharma · A. Maria (✉) · P. Kaur
Department of Oral & Maxillofacial Surgery, Modern Dental
College and Research Centre, Indore, India
e-mail: anisha.maria@hotmail.com

referred from the Department of Prosthodontics who had a lack of vestibular depth in mandibular anterior region, took part in this study. They were examined radiographically and planned for Clark's vestibuloplasty with amniotic membrane graft.

Fresh amniotic membrane was obtained from healthy seronegative mothers who underwent caesarian section. Small sections ($6 \times 10 \text{ cm}^3$) of placenta were first rinsed with sterile saline and then kept in 400 ml of saline containing 100,000 IU penicillin at 4°C up to 24 h and then preserved in 85% glycerol for 24 h. The amniotic membrane was rinsed with generous amounts of sterile saline before use in the patient.

Selection Criteria

A minimal edentulous period of 6 weeks was recommended after extractions.

Clinically healthy mucosa was essential.

Orthopantomographs were taken and a minimal height of 20 mm of mandible between the mental foramen was considered necessary for including the case in the study (Fig. 1).

Informed written and verbal consent was taken.

Preoperative measurements were taken in the midline, left and right side in the canine regions (Fig. 2).

Surgical Procedure

All subjects received bilateral inferior alveolar nerve block injections of 2% lidocaine plus 1:80,000 epinephrine. Clark's technique was used for vestibuloplasty in the approximate area between the second premolars (Fig. 3). Fresh amniotic membrane was placed on the raw area of the alveolus and sutured with 4-0 vicryl to the underlying periosteum. The mesenchymal side of amniotic membrane was kept facing the underlying periosteum. In all ten cases suction catheter stent was used and was secured to the

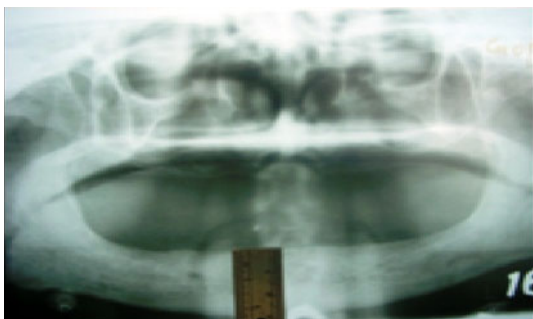


Fig. 1 OPG showing 20 mm of anterior bone height

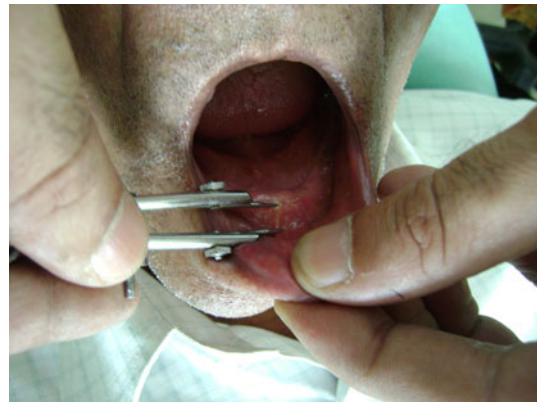

Fig. 2 Pre-op measurement of lower anterior ridge

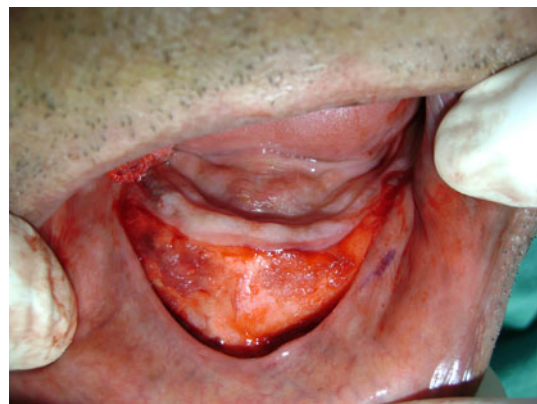


Fig. 3 Clark's vestibuloplasty done

depth of the vestibule by using 1-0 mersilk percutaneous sutures. The stent was removed after a week (Figs. 4, 5).

The area was reexamined on 10th day, 1 month, 3 months post-operatively. The vestibular depths were measured using a divider and a scale in the midline and right and left canine regions (Fig. 6) and the patients were

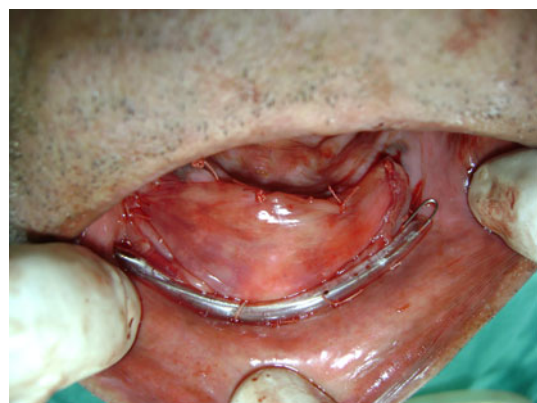

Fig. 4 Amnion secured over newly achieved vestibular depth

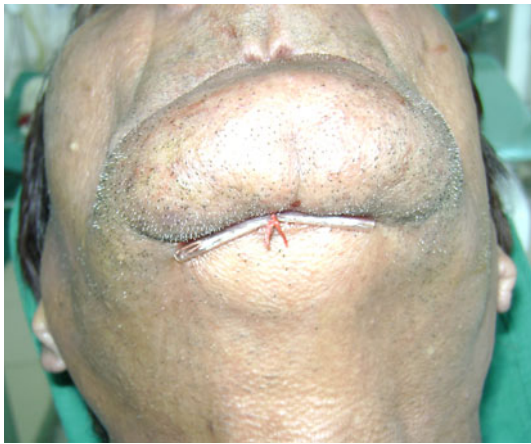

Fig. 5 Extraoral view

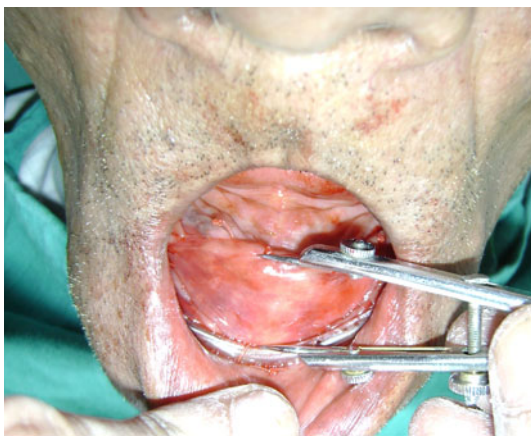


Fig. 6 Post-op measurement

followed up for symptoms such as pain, edema, hematoma, infection and paresthesia.

Results

The stent was removed after a week, and a white necrotic soft tissue layer could be seen with underlying hyperemic tissue. An average gain of 4–6 mm in the depth of labial vestibule could be noted (Table 1) and (Bar chart No 1).

A soft tissue layer similar to attached mucosa with the appropriate consistency was noticed 3 weeks after the procedure. At this time, the graft area could be noticed but the amnion had completely degenerated and disappeared. After 1 month, the subjects were referred for their prosthodontic treatment. By the third month, the graft area could not be distinguished from normal mucosa and an appropriate amount of attached mucosa had formed. A relapse in the depth of the labial vestibule ranged from 30 to 40% after a 3 month follows up. No complications such as

infection, burning sensation, mental paresthesia or graft rejection were noted.

Discussion

Amniotic membrane has unique properties including anti-adhesive effects, bacteriostatic properties, wound protection, pain reduction, and epithelialization effects. Another characteristic of amniotic membrane is the lack of immunogenicity. Amniotic membrane has been used as a surgical material for several decades in burn cases [5–7].

There are only few reports in the literature on reconstruction of oral tissues using amnion. Lawson in 1985 studied the use of amniotic membrane along with pectoralis major muscle for oral cavity reconstruction. He concluded that placement of amnion over the deep aspect of the muscle that is exposed in the oral cavity resulted in a more rapid formation of mucosa. When muscle was used without amniotic membrane, the healing process usually took twice as long. Also, when amnion was not used, one saw a significant amount of wound contracture. Lawson suggested that amnion enhanced re-epithelialization of the oral cavity and reduced the contracture effects in moderate-sized defects [2].

Marco Kesting et al. evaluated the use of multilayer human amniotic membrane (HAM) as a grafting material for the repair of mid-palate oronasal fistulas in minipigs. Two of the three fistulas closed with the HAM were successful and offered a promise as a simple and effective technique for tension-free closure of such fistulas [8].

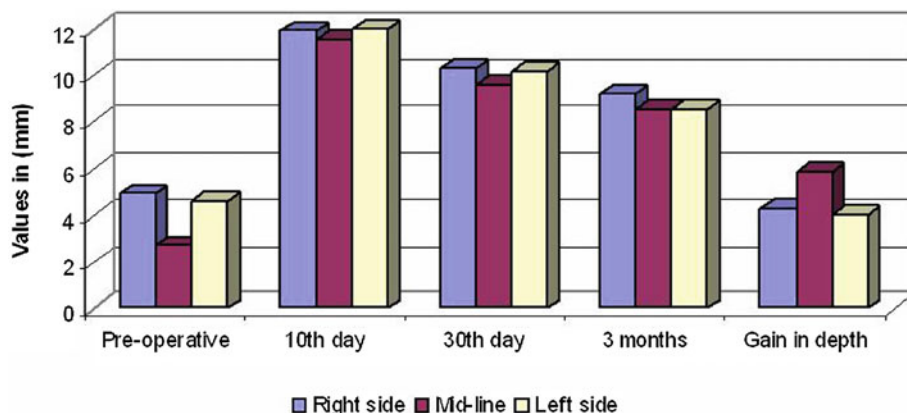
Several characteristics explain why the amniotic membrane can be useful to promote epithelial healing. The oral epithelium produces various growth factors and the basement membrane facilitates migration of epithelial cells which reinforces the adhesion of basal epithelial cells, and may promote epithelial differentiation. The probable mechanism of amnion's anti-adhesive characteristic is contact with healthy tissue that induces an arrest in tissue proliferation. In addition, the amniotic membrane transplant may also function as an anatomical barrier to fibrous tissue proliferation [8].

Another unique characteristic of amniotic membrane is its lack of immunogenicity [5]. The tissue does not express the usual major histocompatibility antigens such as HLA-A, B or D, as a result, amniotic membrane does not induce immunological rejection after its transplantation. The membrane, especially the epithelium, also produces various growth factors including basic fibroblast growth factor, hepatocyte growth factor, and transforming growth factor. They aid in neoangiogenesis [2].

In order to be practical for clinical use, amnion must be easily obtainable and be able to be conveniently stored for

Table 1 Mean values at different stages of right, mid-line and left sides (mm)

	Right side	Mid-line	Left side
Pre-operative	4.9 ± 1.7	2.7 ± 0.5	4.6 ± 1.3
10th day	11.9 ± 1.7	11.5 ± 2.0	12.0 ± 1.7
30th day	10.3 ± 1.5	9.6 ± 1.7	10.2 ± 1.6
3 months	9.2 ± 1.3	8.6 ± 1.6	8.6 ± 1.7



a long time, be free of contamination and not deteriorate in quality. Studies have shown that amnion can be maintained in viable condition for up to 6 weeks if stored aseptically at -48°C in 0.5% silver nitrate solution or in 20% glycerin solution or in sterile saline after passage through one rinse of 0.025% sodium hypochlorite solution. The amnion can be frozen at -70 to -90°C and can be used for over 6 months, but in this scenario the material must be thawed before use. Amnion retains its structural properties and when these conservation processes are used, it is comparable to fresh amnion in its effectiveness as a biological dressing [3]. The human amniotic membrane has also been enzymatically and chemically modified and used as a biological dressing [9].

Long-term preservation and storage of biological materials not only offers the advantage of good availability but also reduces the risk of disease transmission since there is time to check donor material for the presence of pathogens. Glycerol serves the basic main-stay for tissue preservation, glycerolization of skin tissue was first implemented by Basile in 1982 to preserve porcine skin for long periods at low cost. Glycerol dehydrates tissue by physically replacing most of the intracellular water but does not change the cell's ionic concentration, thus it is an efficient agent that preserves tissue by protecting cell integrity [3, 10]. We also kept the amniotic strips in 85% glycerol for 24 h and then after through rinsing with sterile normal saline were applied to the vestibuloplasty sites.

There are many other modalities used for preservation of amnion such as cryopreservation, freeze drying and gamma radiation but these require specialized and expensive equipment which makes the cost of the membrane economically non-viable. The human amniotic membrane can be preserved in antibiotic solution and silver nitrate for short period only. In addition with silver nitrate large quantities of saline and distilled water are needed for rinsing it well before use on patients.

Preservation in 85% glycerol is not only very simple, it is also suitable for preservation over longer periods (up to 5 years) [10].

The advantages of glycerol are:

- Ease of preservation and reconstitution,
- Low cost
- Preservation of morphological structure of the cells in amnion
- Low antigenicity
- Antiviral and antibacterial properties [10, 11]

Human Amniotic membrane is one of the oldest bio-materials used as a scaffold for tissue regeneration. Amniotic membrane was found useful in the management of burns, creation of surgical dressings as well as reconstruction of oral cavity, bladder and vagina, tympanoplasty, arthroplasty and so forth. The Human amniotic membrane (HAM) has gained importance because of its ability to reduce scarring and inflammation, enhance wound healing

and serve as a scaffold for cell proliferation and differentiation as a result of its antimicrobial properties. The extracellular matrix of the HAM and its components such as growth factors, suggest that the HAM is an excellent candidate for use in tissue engineering. In addition, the HAM is a biomaterial that can be easily obtained, processed and transported [12].

Gluer et al. in 1997 concluded that grafts of amnion might be better than other grafts in mandibular vestibuloplasty because of early healing. In their study of blood flow to the amniotic grafts with two different surgical techniques, there was a rapid increase in blood flow during the first 10 days, whereas palatal grafts have shown a reduction in blood flow during the same period. They stated that the angiogenic function of the amnion occurred within the first 10–15 days and blood flow returned to normal by 30 days after surgery [2].

But the use of amnion for the surgical treatment of oral submucous fibrosis was not effective as Lai et al. (1995) reported relapses of up to 62% in the inter incisal distance after 2 years compared to 50% in split thickness skin graft & 38% with pedicled buccal fat pad graft [2].

Other materials have also been used for vestibuloplasty for example, skin and mucosal grafts, collagen sheets. But keeping in mind the cost effectiveness, ease in procuring and preserving the human amniotic membrane (HAM), lack of antigenicity, patient acceptance, no secondary donor site morbidity, we have concluded that HAM is a very viable alternative to the above mentioned graft materials and excellent results were seen with our vestibuloplasty procedures.

Conclusion

No complications such as immunologic rejection and infection occurred in our subjects, and the prosthetic treatment could be started a month after the surgery.

Results suggest that amniotic membrane can be a favorable graft material for vestibuloplasty, promoting healing and preventing relapse. However, further studies with larger samples and longer follow-up is certainly recommended.

References

1. Starshak TJ (1980) Textbook of preprosthetic oral and maxillofacial surgery. C. V. Mosby Company, St. Louis
2. Samandari MH, Yaghmaei M, Ejlali M et al (2004) Use of amnion as a graft material in vestibuloplasty: a preliminary report. *Oral Surg Oral Med Oral Pathol Oral Radiol Endod* 97:574–578
3. Maral Tugrul, Borman Huseyin, Arslan Hande et al (1999) Effectiveness of human amnion preserved long-term in glycerol as a temporary biological dressing. *Burns* 25(7):625–635
4. Robson MC, Krizek TJ (1973) The effect of human amniotic membranes on the bacteria population of infected rat burn. *Ann Surg* 177:144–149
5. Colocho G, Graham WP, Greene AE, Matheson DW, Lynch D (1974) Human amniotic membrane as a physiologic wound dressing. *Arch Surg* 109:370–373
6. Rao TV, Chandrasekharam V (1981) Use of dry human and bovine amnion as a biological dressing. *Arch Surg* 116:891–896
7. Burgos H, Sergeant RJ (1983) Lyophilized human amniotic membranes used in reconstruction of the ear. *J R Soc Med* 76:433
8. Kesting MR, Loeffelbein DJ, Classen M et al. (2009) Repair of oronasal fistulas with human amniotic membrane in minipigs. *Br J Oral Maxillofac surg.* doi:10.1016/j.bjoms.2009.04.025
9. Perry J, Tsur H, Horowitz A, Gazit E (1982) Enzymatic chemical modification of human amniotic membrane and skin as a means for the preparation of biological dressing. *Burns* 8(3):207–209
10. Ravishanker R, Bath AS, Roy R (2003) “Amnion bank”—the use of long term glycerol preserved amniotic membranes in the management of superficial & partial thickness burns. *Burns* 29:369–374
11. Haberal M, Oner Z, Bayraktar U, Bilgin N (1987) The use of silver nitrate-incorporated amniotic membrane as a temporary dressing. *Burns* 13:159–163
12. Niknejad H, Peirovi H, Jorjani M et al. (2008) Properties of the amniotic membrane for potential use in tissue engineering. *European cells and materials* 15:88–99, ISSN 1473-2262