



Intraoperative Valsalva maneuver: a narrative review

Manœuvre de Valsalva peropératoire : une revue narrative

Chandra Mohan Kumar, MBBS, FFARCS, MSc, FRCA, EDRA · André A. J. Van Zundert, MD, PhD, FRCA, EDRA, FANZCA

Received: 30 July 2017 / Revised: 8 December 2017 / Accepted: 20 December 2017 / Published online: 24 January 2018
© Canadian Anesthesiologists' Society 2018

Abstract *The Valsalva maneuver (VM) involves expiratory effort against a closed mouth and/or glottis in the sitting or supine position with the increased intraoral and intrathoracic pressure raised to 40 mmHg for 15–20 sec after which the pressure is suddenly released and the breathing restored to normal. Complex cardiovascular and other physiologic changes occur during the VM. The VM has been used for diagnostic and therapeutic reasons as well as intraoperatively during specific surgical procedures. Although the VM is usually safe, rare complications have been reported. This review examines the published literature surrounding the VM and explores the physiologic changes that occur during its performance. Attempts have been made to understand its intraoperative uses and complications and how these can be prevented.*

Résumé *La manœuvre de Valsalva (MV) implique un effort expiratoire à bouche et/ou glotte fermées en position assise ou en décubitus, avec une pression intrabuccale et intrathoracique atteignant 40 mmHg pendant 15 à*

20 secondes avant la levée soudaine du blocage et la reprise d'une respiration normale. Des modifications physiologiques et cardiovasculaires complexes surviennent durant la MV. La MV a été utilisée à des fins diagnostiques et thérapeutiques, et aussi en peropératoires au cours d'interventions chirurgicales spécifiques. Bien que la MV soit habituellement sans danger, de rares complications ont été décrites. Cette revue examine les publications entourant la MV et explore les changements physiologiques survenant au cours de sa réalisation. Des tentatives sont faites pour comprendre son utilisation et ses complications peropératoires et comment ces dernières peuvent être évitées.

The Valsalva maneuver (VM) was conceived approximately 300 years ago by the Italian anatomist Antonio Maria Valsalva (who also described the Eustachian tube). Its purpose was to expel foreign bodies or exudates (i.e., pus) from the middle ear.¹ In an awake patient, the VM involves expiratory effort against a closed mouth and/or glottis in the sitting or supine position with the intraoral and -thoracic pressures raised to 40 mmHg for 15–20 sec, after which the pressure is suddenly released and the breathing restored to normal.² A maneuver similar to the VM can also occur whenever a person conducts a forced expiration by strongly contracting the thoracic and abdominal muscles against high airway outflow resistance or at the end of an expiration.^{3,4}

Although the VM technique is well described, its definition varies.⁵ An un-intentional VM can occur during many daily activities. These include bending,

C. M. Kumar, MBBS, FFARCS, MSc, FRCA, EDRA
Newcastle University, EduCity, Johor, Malaysia

C. M. Kumar, MBBS, FFARCS, MSc, FRCA, EDRA
Khoo Teck Puat Hospital, Yishun, Singapore

A. A. J. Van Zundert, MD, PhD, FRCA, EDRA, FANZCA
Department of Anesthesiology, The University of Queensland,
Brisbane, Australia

A. A. J. Van Zundert, MD, PhD, FRCA, EDRA, FANZCA (✉)
Department of Anesthesia & Perioperative Medicine, Royal
Brisbane & Women's Hospital – Anesthesia, The University of
Queensland, Ned Hanlon Building level 4 – Butterfield Street,
Herston Campus, Brisbane, QLD 4029, Australia
e-mail: vanzundertandre@gmail.com; a.vanzundert@uq.edu.au

sexual intercourse, straining during urination, or a strenuous attempt to evacuate the bowel, as well as with lifting heavy objects, rising off a bed using the arm and upper trunk muscles, weightlifting, and performing some sports (e.g., rowing).⁶ Furthermore, an unintentional VM can also occur in the perioperative period during coughing, vomiting, sneezing, gagging, and with any breathing against a closed end-expiratory valve. Indeed, in the operating room, a VM can be induced by the prevention of expiration while fresh gas flow continues to enter a circle system circuit with an adjustable pressure-limiting valve that is partially or fully closed.

When needed, the VM was previously simulated in awake individuals by asking the patient to exhale into the spigot of a rubber connecting tube of an aneroid sphygmomanometer,⁷ but now, alternative and safer techniques such as blowing a whistle or blowing into a specially devised manometer⁸ that exerts a constant intraoral pressure of 40 mmHg (with the glottis kept open) are commonly used. Such a specifically designed valsalvometer has been shown to be an effective device in standardizing VM in awake individuals.⁸ The well-known Heimlich maneuver⁹ is a variation of the VM and involves a rescuer standing behind a patient and using his or her hands to exert pressure below the diaphragm to compress the lungs and exert pressure to expel any foreign body that may be lodged in the trachea, with the intent of expelling it.

The VM has varied clinical applications, both diagnostic and therapeutic, as well as its intraoperative use during various surgical procedures.¹⁰ Intraoperative usefulness has been questioned because of associated complications and potentially related adverse events. The VM produces complex cardiovascular and other physiologic changes involving several regulatory mechanisms. These changes depend on whether the VM is performed actively, accidentally, or passively. The functional state of the autonomic nervous system and various pathologic states, medications, patient body positions, and intravascular volume statuses are all influencing factors on the full

extent of a VM. Furthermore, the changes may be altered during anesthesia.¹¹

In preparing this narrative review, the PubMed and Google Scholar search engines were used to identify articles on VM and related subjects using the key words Valsalva maneuver, anesthesia, anaesthesia, complications of Valsalva, applications of VM, baroreflex, bradycardia, tachycardia, hemostasis, surgery, thyroidectomy, parathyroidectomy, neurosurgery, and head neck surgery in various combinations. The search was limited to humans and English language articles published from the inception of these databases up to June 2017. Additional references were identified from reference lists in the resulting publications and review articles of interest.

The main purpose of this narrative review is to highlight the current understanding of the VM including the knowledge gaps and limitations in the literature. In addition, it addresses the interactions of physiologic changes and the VM mechanism and discusses its intraoperative applications, complications, and safe use during anesthesia.

Physiologic changes and the VM mechanism

Whenever an awake VM is performed, contraction of the chest wall muscles against a closed mouth or glottis compresses the lungs and causes a large increase in intrathoracic pressure. This increase may result in direct or transmitted forces on the aortic wall causing cardiopulmonary baroreceptor activation.⁵ Junqueira¹² proposed guidelines (Table) for correct performance of a VM in awake persons because errors in executing a VM procedure are common in clinical practice. The author identified three essential key elements for the maximum effect: 1) supine posture, 2) duration of 15–20 sec, and 3) an intraoral/intrathoracic pressure of 40 mmHg.

A correct VM is performed in awake individuals (after some training) in the supine position by asking them to take

Table Components of an optimal Valsalva maneuver (VM)^{2,12}

Proposed standard awake Valsalva maneuver¹²

1. Heart rate or risk ratio intervals should be obtained from the conventional electrocardiogram and non-invasive blood pressure should be noted
2. Person should be resting in the supine position with a slight inclination of the head in an ambient environment without any interference
3. At least three VMs should be sequentially performed to obtain mean indices of heart rate responses at five to ten minutes allowing the return of variables to baseline levels following each maneuver
4. Depth of inspiration before straining, the duration of straining, and its intensity (expressed by the magnitude of the intraoral pressure of 40 mmHg) should all be controlled as much as possible
5. Deep inspiration should not be allowed by a forced expiration against a resistance
6. 20-sec duration of the expiratory straining period is more reliable
7. Training sessions should be conducted before valid testing sessions

a normal or full inspiration and exhale against a closed airway for 15–20 sec. This creates positive intrapleural pressure that can be measured through a mouthpiece with tubing attached to a manometer or by using a catheter-based system inserted into the esophagus. The 20-sec protocol provokes a more potent and long-lasting stimulus that induces arterial pressure changes that lead to conspicuous and predictable heart rate (HR) baroreflex responses with marked modifications in the parasympathetic and sympathetic activities.⁸ An intraoral expiratory pressure of 40 mmHg against the manometer appears to be widely accepted.¹³ This generated pressure provides an environment for maximizing the effect while minimizing the potential onset of deleterious side effects, such as rebound tachycardia and bradycardia.^{2,4,14,15}

There are four phases of the HR and blood pressure changes following the VM (Fig. 1).^{16–20} In phase I (defined by the onset of the muscular straining), there is a transient increase in intrathoracic pressure and arterial blood pressure due to direct compressive effects on the thoracic aorta that cause blood to be expelled from thoracic vessels. This is also coupled with a compensatory and similarly transient decrease in HR triggered by the activation of baroreceptors within the aortic arch. Phase II (continued strain) begins with a progressive fall in systolic, diastolic, and pulse pressures as a result of the reduced venous return caused by the increase in intrathoracic pressure.¹¹ The impaired venous return consequently leads to the transfer of blood from the thorax and abdomen to the limbs²¹ with a gradual rise in the peripheral venous pressure²² noticeable by distension of the jugular vein, which is considered a crucial sign signaling a well-executed maneuver.^{12,23} The rate at which arterial pressure decreases eventually declines (with even a slight increase in pressure seen) after about

five seconds as a result of reflex vasoconstriction. The pulse pressure may even be increased at the end of phase II relative to resting baseline levels. The HR rises progressively for the first ten seconds during phase II. Phase III (release of the airway closure) occurs at the end of the VM-induced muscular strain and is identified by a sudden drop of blood pressure resulting from the pooling of blood in the pulmonary vessels following the release of the VM, which causes a decrease in intrathoracic pressure; there is also a compensatory rise in HR. Finally, in phase IV (recovery), there is an overshoot in arterial blood pressure and a compensatory bradycardia. These changes occur as a consequence of increased venous return resulting in increased aortic pressure as cardiac output is elevated (that is, accompanied by a compensatory baroreceptor-mediated bradycardia).

The VM causes internal jugular vein distension and increases in internal jugular venous pressure.¹⁸ In addition, cerebrospinal fluid (CSF) pressure in an awake human (without any intracranial pathology) increases immediately with the onset of the VM and in parallel to the rise in intrathoracic pressure. During VM, increased intrathoracic and intraabdominal pressures are transmitted to the large veins compressing the paravertebral venous plexus and spinal dura, which increases the subarachnoid pressure. The pressure wave is transmitted cephalad with a consequent increase in intracranial pressure (ICP) leading to CSF flow towards the cranium. Similar increases in CSF pressure and ICP occur with the VM in awake patients as well as during neurosurgical operations.²⁰ A significant reduction in cerebral perfusion pressure occurs during a VM due to increases in the ICP that are coupled with decreases in the mean arterial blood pressure (MAP).²⁴

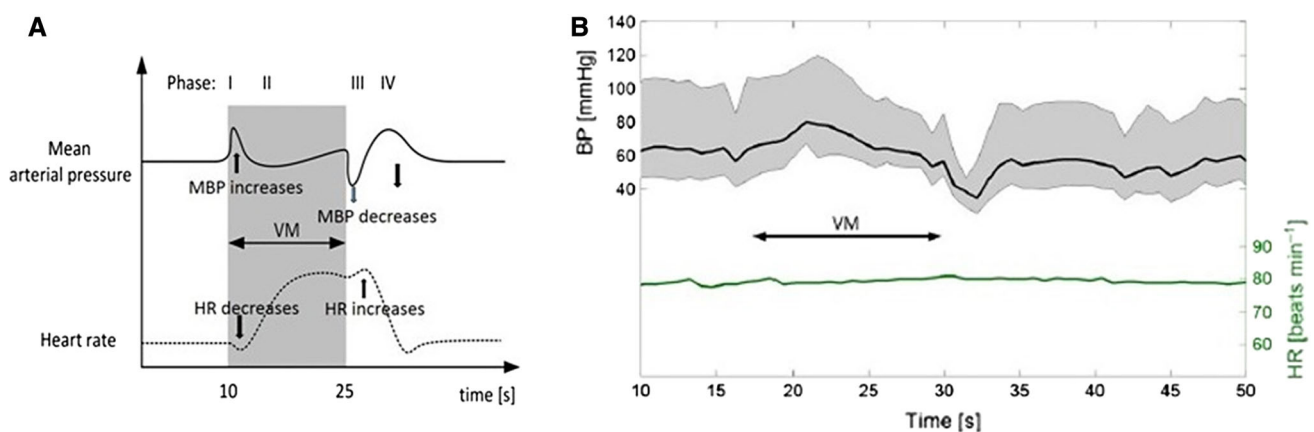


Fig. 1 A) Conceptual representation of the typical mean arterial pressure and heart rate variations during and after the Valsalva maneuver (VM) with normal inspiration before the maneuver. B) The arterial blood pressure (mean, diastolic and systolic) and heart rate response to the VM in a 62-yr-old female with diabetes mellitus and

renal complications. Adapted with permission from: *Pstras L, Thomaseth K, Waniewski J, Balzani I, Bellavere F. The Valsalva maneuver: physiology and clinical examples. Acta Physiol 2016; 217: 103–19*¹⁷

Altered physiologic responses to VM in awake patients and during anesthesia

Although the use of awake VM is widely practiced in clinical medicine, the interpretation of the physiologic responses is complex and challenging, requiring expert interpretation. The hemodynamic responses to VM may be altered and influenced by permanent or temporary physiologic conditions of the patient at the time of executing the VM, as well as concomitant diseases, and different body positions.¹⁷ The abnormal responses may involve attenuated or absent MAP recovery in late phase II, attenuated or absent MAP overshoot in phase IV, absent tachycardia in phase II, or absent bradycardia in phase IV, as well as completely different patterns of arterial blood pressure and HR.¹⁷ There may be over-exaggerated and prolonged bradycardia during phase I as well as an attenuation of the overshoot bradycardia in phase IV due to impaired baroreceptor mechanisms in hypertensive patients.^{25,26} In normal subjects with a marked vagotonic state, bradycardia instead of the expected tachycardia can be observed during phase II particularly when a low pressure VM is employed.⁴ An attenuated reduction in blood pressure in the early phase II may be observed in patients with impaired ventricular function or in some patients with mitral stenosis, constrictive pericarditis, or atrial septal defects. This is characterized by a square wave pressure response with no change of pulse pressure, along with a diminished or absent tachycardia in phase II and no bradycardia in phase IV.⁴

Data on physiologic responses to the VM under general anesthesia are limited. Rawlinson *et al.*¹¹ highlighted altered responses to the VM under general anesthesia (Fig. 2 A-B) in patients receiving certain anesthetic drugs. Indeed, Scott *et al.*²⁷ also confirmed that VM responses were different in patients anesthetized with thiopentone, suxamethonium, nitrous oxide, and tubocurarine compared

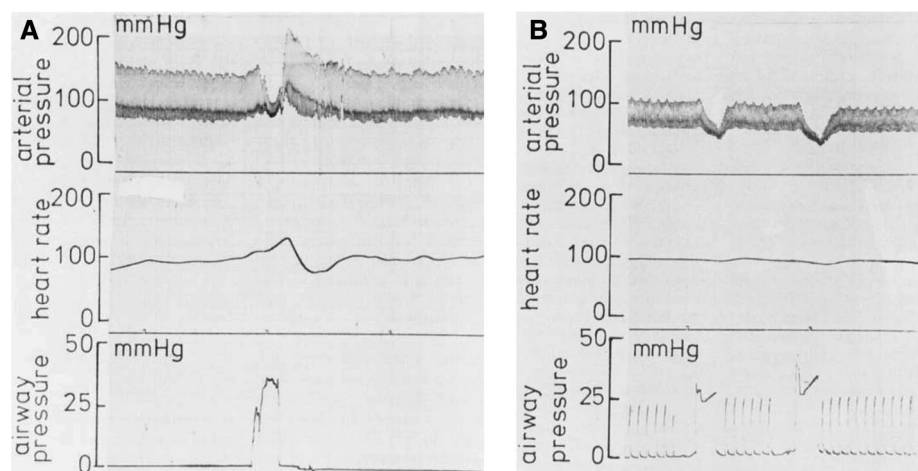
with those obtained in conscious subjects. There was a progressive fall in MAP but HR changes were inconsistent; thus, changes associated with the VM proved to be an unreliable indicator of circulatory reflex integrity in anesthetized patients.¹¹ No studies have been performed using more contemporary anesthetic agents.

Non-operative clinical applications of VM

The VM has been used to diagnose oro-antral communication following dental extractions,²⁸ protect the middle ear from trauma during hyperbaric oxygen therapy,²⁹ and improve the view of the hypopharynx to aid in identification of previously undiagnosed hyoid bone fracture due to the positive pressure opening up the collapsed recesses of the pharynx.^{30,31} As the autonomic system is responsible for controlling the exaggerated responses and involves the baroreceptors and cardiopulmonary and chemoreceptor reflexes,³² the physiologic changes produced by both the sympathetic and parasympathetic systems can help in the assessment of generalized autonomic failure, autonomic neuropathies, distal small-fiber neuropathy, and overall adrenergic function.

The VM can be used for the termination of some supraventricular tachycardias and to evaluate a range of cardiac conditions including heart murmurs.^{33,34} As a diagnostic technique for bedside evaluation of heart murmurs, it may help in distinguishing a fixed obstruction from a dynamic obstruction (as the cause of a heart murmur). For example, the reduced stroke volume and cardiac output usually diminish the intensity of most fixed causes of murmurs during phase II of the VM.³³ Nevertheless, the murmur associated with hypertrophic obstructive cardiomyopathy (HOCM), and the associated mitral regurgitation, is intensified with a VM as the increased subvalvular obstruction produced by the

Fig. 2 A) Normal Valsalva maneuver before the induction of anesthesia and B) Valsalva maneuver in the same patient but ten minutes after the induction of anesthesia using the intermittent positive-pressure ventilation technique. Adapted with permission from: Rawlinson WA, Edmonds-Seal J, Adams AP. Anesthesia and the Valsalva maneuver. A test of circulatory responses in neurosurgical patients including those in the sitting position. *Anesthesia* 1979; 34: 534-42¹¹



reduction of left ventricular volume overrides the decrease in cardiac blood flow seen during the active phase of the VM and as a result the systolic murmur is intensified.³⁴ Some authorities advocate the VM as the primary means to evaluate patients suspected of having HOCM.³⁵

The radicular pain associated with cervical spine degenerative and compressive lesions can be exaggerated by a VM, making it a helpful diagnostic tool. Indeed, as the VM increases intrathoracic and -spinal pressure, the pain may manifest or be exacerbated, indicating an impingement of the nerve by an intervertebral disc, osteophytes, or other bony compression.³⁶

Intraoperative applications of VM

Thyroid, head and neck surgery

Meticulous hemostasis is important for all surgical procedures. Nevertheless, due to its rich vascular supply, the head and neck area is particularly susceptible to bleeding and hematoma formation, which can lead to airway compromise. Recently, the use of drains in thyroidectomy, parathyroidectomy, and other head and neck surgeries has been questioned on the grounds of an adverse impact on outcome and hospital length of stay.³⁷⁻⁴⁰ Tokaç *et al.*³⁸ found that, although intraoperative VM provided identification of bleeding points in 32% of patients, it had no effect on the duration of the postoperative drain usage, amount of drainage, and risk of hematoma. Despite these data, many surgeons continue to request intraoperative VM during thyroidectomy, parathyroidectomy, and head and neck surgery to help evaluate for any potentially covert venous bleeding sites.

Neurosurgery

The VM is commonly used during suturing of dural tears following spinal surgery as well as for confirming venous hemostasis after trans-sphenoid pituitary surgery, craniotomy, and spinal surgery.¹⁰

Assessing integrity of the autonomic nervous system

Integrity of the autonomic nervous system can be assessed using the VM and has been shown to be a good indicator of baroreceptor reflex sensitivity because it tends to maintain a constant arterial pressure.⁴¹ Abnormal responses to the VM have been used for investigation in patients with autonomic neuropathies. The bradycardia associated with the overshoot of phase IV is less pronounced in the presence of autonomic dysfunction. The degree of abnormality of the HR response to the VM parallels the

severity of the signs and symptoms of autonomic dysfunction.⁴²

Venous cannulation

Reducing pain during venous cannulation has also been suggested as a benefit of a VM. Its mechanism is multifactorial with suggested explanations including vagal nerve stimulation, modulation of the cardiopulmonary and sino-aortic baroreceptor reflex arcs, and psychologic distraction by directing attention to a non-noxious stimulus or the activation of the segmental pain inhibitory pathways.^{43,44} Head-down tilt and VM are also known to produce venous distention aiding cannulation of both small and large veins.⁴⁵⁻⁴⁸ The VM can increase the success of the internal jugular vein cannulation as there is a substantial increase in the vascular lumen, and it reduces their collapsibility and opens their valves, especially in patient whose vessel is found to be collapsed (e.g., in hypovolemic patients).⁴⁷

Reduction of pain during spinal puncture

The VM is considered a painless non-pharmacologic method of pain attenuation in patients during the skin puncture of spinal anesthesia,⁴⁹ but caution should be exercised in using it only for superficial needle insertion as there is a risk of trauma to engorged veins in the epidural space due to transmitted backward pressure from the thorax.¹⁸

Valsalva maneuver under anesthesia

Though intraoperative VM is usually performed in mechanically ventilated patients, spontaneous ventilation using a supraglottic airway (SGA) or endotracheal tube (ETT) for major head and neck surgery is very common. A report of an intraoperatively modified VM in a patient breathing through an SGA was used with airway pressure of 15 cmH₂O during repair of an orbital socket to help identify and treat the source of a CSF leak at the posterior aspect of the orbit.⁵⁰ That said, balanced anesthesia techniques using muscle relaxants and mechanical ventilation with the airway secured by an ETT are more the routine for patients undergoing major head and neck surgery. If and when VM is required to check for hemostasis or an air leak towards the end of surgery, it can be performed simply by switching the ventilator to manual ventilation. With the adjustable pressure-limiting valve fully closed, the fresh gas flow can be increased and the breathing circuit bag squeezed for 15-20 sec to generate the needed VM pressure. Importantly, the depth of anesthesia must be adequate and/or neuromuscular

blockade assured to prevent any breathing against the forced ventilation. Some newer anesthetic machines have been made available that have the facilities to perform automated VM to a pre-set pressure and time (Aisys CS², Datex-OhmedaTM). As expected, if an automated system is used, there will be a lack of feel for the chest wall compliance, and this method is only suitable in patients who are adequately anesthetized and paralyzed. If general anesthesia is maintained and mechanically ventilated with total intravenous anesthesia with propofol and remifentanyl without a muscle relaxant and the VM is requested, anesthesia must be deepened, though this could be associated with a fall in arterial blood pressure needing vasopressor therapy independent of the VM itself.

Complications associated with the VM

The use of a VM is generally very safe. Low and colleagues⁵¹ have conducted 4,000 awake VMs per year since 1993 in the Mayo Clinic for the evaluation of generalized autonomic failure, benign autonomic disorders that mimic life-threatening disorders, distal small-fibre neuropathy, autonomic neuropathies, sympathetically maintained pain, and postural orthostatic tachycardia syndrome and have reported no complications.

Nevertheless, several real and theoretical complications can occur and have been variably reported. Reduced left ventricular stroke volume during the VM combined with inefficient autonomic regulation may contribute to periods of asystole (and very rarely with sudden death),⁵² and therefore emergency equipment must be readily available, particularly in patients with known coronary artery disease or in subjects who are sensitive to sudden changes of arterial pressure or HR.⁵³

Several cases of neurologic complications have been reported. Two healthy individuals developed stroke and epidural hematomas during sit-up exercises after VM-like effects presumably due to supraphysiologic increases in blood pressure, leading to vascular injury and serious neurologic consequences.⁵⁴ In a different report of a VM instituted during spina-bifida surgery, an egress of CSF following a rise in ICP led to atmospheric air being sucked into the fistula site after release of the VM and resulted in pneumocephalus.⁵⁵ In general, a decrease in the MAP and cerebral perfusion pressures during the strain of phase I and a compensatory rapid rise in the blood pressure after the release during phase II can cause a rise in cerebral blood flow and may lead to serious neurologic consequences including rupture of intracranial aneurysms and re-bleeding following surgical hemostasis during intracranial operations.⁵⁶ The size of a chronic subdural hematoma may expand after a transient decrease in ICP following a VM. The VM during labor delivery has been reported to

cause a recurrence of spontaneous intracranial hypotension (SIH) and typically results from spontaneous CSF leak, often at the spinal level.⁵⁷ Unfortunately, the cause often remains undetermined.⁵⁸

A VM-induced retinopathy is a rare entity but has been reported following activities such as coughing, vomiting, straining on stool, yelling, blowing up an air mattress, weight lifting, moving furniture, Judo training, water skiing, vigorous exercise, motor vehicle accident, thoracic trauma, and difficult intubation.⁵⁹ The VM increases intraocular pressure leading to retinal or macular hemorrhage.⁶⁰⁻⁶² A case of unilateral visual loss sustained shortly after tracheal intubation and a sustained VM has been reported.⁶³ This was considered to be caused by increased intrathoracic pressure and intraocular venous pressure resulting in pre-retinal hemorrhage from rupture of perifoveal capillaries and disruption of small capillary vessels, which caused pooling of blood between the vitreous humor and the retina. A case of spontaneous hyphema has also been reported on emergence from general anesthesia after laparoscopic appendectomy. A Valsalva-like maneuver with breath-holding during emergence or during CO₂ insufflation for laparoscopy may have led to the development of hyphema.⁶⁴ A case of hemorrhagic retinopathy has also been reported to have occurred during spontaneous vaginal delivery after VM. The increase in intra-abdominal/intrathoracic pressure against a closed glottis with the ensuing sudden rise in venous pressure leading to rupture of superficial retinal capillaries was suggested as a cause of retinal hemorrhage.⁶⁵

Spontaneous pneumothoraces (due to alveolar rupture) have been reported in patients suffering from chronic obstructive pulmonary diseases. In addition, pneumomediastinum and/or rupture of subpleural blebs/bullae have also been seen.^{66,67} Bilateral tension pneumothoraces, although uncommon, is a potentially lethal complication that has been reported in a child following shunt surgery^{67,68} presumably due to alveolar over-distention following application of the VM for trocar insertion, which increased the positive pulmonary pressure. Sudden death, although extremely rare, has also been reported.^{52,69}

Conclusions

Intraoperative VM remains a common though controversial procedure during head and neck surgery and its usefulness appears to be more convincing during neurosurgical procedures. A standard intraoperative VM has three recognized composites for optimal effects: duration of 15-20 sec, supine posture, and 40 mmHg intrathoracic

pressure. To reduce the possible unwarranted complications that appear to be associated with high intrathoracic pressure, there is a need to reconsider the application and technique of the intraoperative VM.

Conflicts of interest The authors declare no financial or any other conflict of interest.

Editorial responsibility This submission was handled by Dr. Hilary P. Grocott, Editor-in-Chief, *Canadian Journal of Anesthesia*.

Author Contributions Chandra Mohan Kumar and André A.J. Van Zundert contributed to the conception and design of the review, drafting the manuscript or revising it critically for important intellectual content, and final approval of the final manuscript.

References

1. Yale SH. Antonio Maria Valsalva (1666–1723). *Clin Med Res* 2005; 3: 35-8.
2. Taylor DM, Wong LF. Incorrect instruction in the use of the Valsalva manoeuvre for paroxysmal supra-ventricular tachycardia is common. *Emerg Med Australas* 2004; 16: 284-7.
3. Mateika JH, Demeersman RE, Kim J. Effects of lung volume and chemoreceptor activity on blood pressure and R-R interval during the Valsalva maneuver. *Clin Auton Res* 2002; 12: 24-34.
4. Looga R. The Valsalva manoeuvre–cardiovascular effects and performance technique: a critical review. *Respir Physiol Neurobiol* 2005; 147: 39-49.
5. Talasz H, Kofler M, Lechleitner M. Misconception of the Valsalva maneuver. *Int Urogynecol J* 2011; 22: 1197-8.
6. Klabunde RE. Cardiovascular Physiology Concepts. Hemodynamics of a Valsalva Maneuver 2012. Available from URL: <http://www.cvphysiology.com/Hemodynamics/H014> (accessed December 2017).
7. Lane RJ, Davies PT. Modified Valsalva test differentiates primary from secondary cough headache. *J Headache Pain* 2013; 14: 31.
8. Greenland HP, Hosker GL, Smith AR. A valsalvometer can be effective in standardising the Valsalva manoeuvre. *Int Urogynecol J Pelvic Floor Dysfunct* 2007; 18: 499-502.
9. Wikipedia. Henry J. Heimlich. Available from URL: https://en.wikipedia.org/w/index.php?title=Henry_Heimlich&oldid=777278484 (accessed December 2017).
10. Haldar R, Khandelwal A, Gupta D, Srivastava S, Rastogi A, Singh PK. Valsalva maneuver: its implications in clinical neurosurgery. *Neurol India* 2016; 64: 1276-80.
11. Rawlinson WA, Edmonds-Seal J, Adams AP. Anaesthesia and the Valsalva manoeuvre. A test of circulatory responses in neurosurgical patients including those in the sitting position. *Anaesthesia* 1979; 34: 534-42.
12. Junqueira LF. Teaching cardiac autonomic function dynamics employing the Valsalva (Valsalva-Weber) maneuver. *Adv Physiol Educ* 2008; 32: 100-6.
13. Smith G, Morgans A, Boyle M. Use of the Valsalva manoeuvre in the prehospital setting: a review of the literature. *Emerg Med J* 2009; 26: 8-10.
14. Waxman MB, Wald RW, Sharma AD, Huerta F, Cameron DA. Vagal techniques for termination of paroxysmal supraventricular tachycardia. *Am J Cardiol* 1980; 46: 655-64.
15. Taylor DM, Auble TF, Yealy DM. First-line management of paroxysmal supraventricular tachycardia. *Am J Emerg Med* 1999; 17: 214-6.
16. Hamilton WF, Woodbury RA, Harper HT Jr. Physiologic relationships between intrathoracic intraspinal and arterial pressures. *JAMA* 1936; 107: 853-6.
17. Pstras L, Thomaseth K, Waniewski J, Balzani I, Bellavere F. The Valsalva manoeuvre: physiology and clinical examples. *Acta Physiol (Oxf)* 2016; 217: 103-19.
18. Chung CP, Hsu HY, Chao AC, Wong WJ, Sheng WY, Hu HH. Flow volume in the jugular vein and related hemodynamics in the branches of the jugular vein. *Ultrasound Med Biol* 2007; 33: 500-5.
19. Williams B. Cerebrospinal fluid pressure changes in response to coughing. *Brain* 1976; 99: 331-46.
20. Greenfield JC Jr, Rembert JC, Tindall GT. Transient changes in cerebral vascular resistance during the Valsalva maneuver in man. *Stroke* 1984; 15: 76-9.
21. Eckberg DL. Parasympathetic cardiovascular control in human disease: a critical review of methods and results. *Am J Physiol* 1980; 239: H581-93.
22. Rushmer RF. Circulatory effects of three modifications of the Valsalva experiment: an experimental survey. *Am Heart J* 1947; 34: 399-418.
23. Attubato MJ, Katz ES, Feit F, Bernstein N, Schwartzman D, Kronzon I. Venous changes occurring during the Valsalva maneuver: evaluation by intravascular ultrasound. *Am J Cardiol* 1994; 74: 408-10.
24. Prabhakar H, Bithal PK, Suri A, Rath GP, Dash HH. Intracranial pressure changes during Valsalva manoeuvre in patients undergoing a neuroendoscopic procedure. *Minim Invasive Neurosurg* 2007; 50: 98-101.
25. Denq JC, O'Brien PC, Low PA. Normative data on phases of the Valsalva maneuver. *J Clin Neurophysiol* 1998; 15: 535-40.
26. Nishimura RA, Tajik AJ. The Valsalva maneuver and response revisited. *Mayo Clin Proc* 1986; 61: 211-7.
27. Scott DB, Slawson KB, Taylor SH. The circulatory effects of the Valsalva manoeuvre during anaesthesia and thoracotomy. *Cardiovasc Res* 1969; 3: 331-7.
28. Kretzschmar DP, Kretzschmar JL. Rhinosinusitis: review from a dental perspective. *Oral Surg Oral Med Oral Pathol Oral Radiol Endod* 2003; 96: 128-35.
29. Lima MA, Farage L, Cury MC, Bahmad F Jr. Middle ear barotrauma after hyperbaric oxygen therapy - the role of insufflation maneuvers. *Int Tinnitus J* 2012; 17: 180-5.
30. Freeman SRM, Keith AO, Aucott W, Kazmi N, Nigam A. Comparison between two valsalva techniques for improvement of hypopharyngeal nasendoscopy: a preliminary communication. *Clin Otolaryngol* 2007; 32: 488-91.
31. Spielmann PM, Hathorn IF, Clarke JK, Denholm S. Hyoid bone fracture identified only with nasal Valsalva manoeuvre. *J Laryngol Otol* 2010; 124: 431-2.
32. Zhang R, Crandall CG, Levine BD. Cerebral hemodynamics during the Valsalva maneuver: insights from ganglionic blockade. *Stroke* 2004; 35: 843-7.
33. Nishimura RA, Tajik AJ. The Valsalva maneuver-3 centuries later. *Mayo Clin Proc* 2004; 79: 577-8.
34. Smith GD, Fry MM, Taylor D, Morgans A, Cantwell K. Effectiveness of the Valsalva manoeuvre for reversion of supraventricular tachycardia. *Cochrane Database Syst Rev* 2015; 2: CD009502.
35. Jensen MK, Havndrup O, Pecini R, et al. Comparison of Valsalva manoeuvre and exercise in echocardiographic evaluation of left ventricular outflow tract obstruction in hypertrophic cardiomyopathy. *Eur J Echocardiogr* 2010; 11: 763-9.

36. Johnson RH, Smith AC, Spalding JM. Blood pressure response to standing and to Valsalva's manoeuvre: independence of the two mechanisms in neurological diseases including cervical cord lesions. *Clin Sci* 1969; 36: 77-86.
37. Khanna J, Mohil RS, Chintamani, et al. Is the routine drainage after surgery for thyroid necessary? A prospective randomized clinical study [ISRCTN63623153]. *BMC Surg* 2005; 5: 11.
38. Tokaç M, Dunlu EG, Bozkurt B, et al. Effect of intraoperative Valsalva maneuver application on bleeding point detection and postoperative drainage after thyroidectomy surgeries. *Int Surg* 2015; 100: 994-8.
39. Lee SW, Choi EC, Lee YM, Lee JY, Kim SC, Koh YW. Is lack of placement of drains after thyroidectomy with central neck dissection safe? A prospective, randomized study. *Laryngoscope* 2006; 116: 1632-5.
40. Ahluwalia S, Hannan SA, Mehrzad H, Crofton M, Tolley NS. A randomised controlled trial of routine suction drainage after elective thyroid and parathyroid surgery with ultrasound evaluation of fluid collection. *Clin Otolaryngol* 2007; 32: 28-31.
41. Keet SW, Bulte CS, Boer C, Bouwman RA. Reproducibility of non-standardised autonomic function testing in the pre-operative assessment screening clinic. *Anaesthesia* 2011; 66: 10-4.
42. Ewing DJ, Campbell IW, Burt AA, Clarke BF. Vascular reflexes in diabetic autonomic neuropathy. *Lancet* 1973; 2: 1354-6.
43. Agarwal A, Sinha PK, Tandon M, Dhiraaj S, Singh U. Evaluating the efficacy of the Valsalva maneuver on venous cannulation pain: a prospective, randomized study. *Anesth Analg* 2005; 101: 1230-2.
44. Akdas O, Basaranoglu G, Ozdemir H, Comlekci M, Erkalp K, Saidoglu L. The effects of Valsalva maneuver on venipuncture pain in children: comparison to EMLA® (lidocaine-prilocaine cream). *Ir J Med Sci* 2014; 183: 517-20.
45. Lewin MR, Stein J, Wang R, et al. Humming is as effective as Valsalva's maneuver and Trendelenburg's position for ultrasonographic visualization of the jugular venous system and common femoral veins. *Ann Emerg Med* 2007; 50: 73-7.
46. Dincyurek GN, Mogol EB, Turker G, et al. The effects of the Trendelenburg position and the Valsalva manoeuvre on internal jugular vein diameter and placement in children. *Singapore Med J* 2015; 56: 468-71.
47. Cowlshaw P, Ballard P. Valsalva manoeuvre for central venous cannulation. *Anaesthesia* 2007; 62: 640.
48. Ren QS, Zhao LM, Yu WJ. The effect of blowing a whistle on the cross-sectional area of the internal jugular vein. *Anaesthesia* 2016; 71: 350-1.
49. Kumar S, Gautam SK, Gupta D, Agarwal A, Dhirraj S, Khuba S. The effect of Valsalva maneuver in attenuating skin puncture pain during spinal anesthesia: a randomized controlled trial. *Korean J Anesthesiol* 2016; 69: 27-31.
50. Lovett P, Klingbeil R, Reimer R, Shine T. Laryngeal mask airway and Valsalva maneuver during ophthalmic surgery: a case report. *AANA J* 2016; 84: 423-5.
51. Low PA, Tomalia VA, Park KJ. Autonomic function tests: some clinical applications. *J Clin Neurol* 2013; 9: 1-8.
52. Greenfield JC Jr, Cox RL, Hernández RR, Thomas C, Schoonmaker FW. Pressure-flow studies in man during the Valsalva maneuver with observations on the mechanical properties of the ascending aorta. *Circulation* 1967; 35: 653-61.
53. Zema MJ, Restivo B, Sos T, Sniderman KW, Kline S. Left ventricular dysfunction—bedside Valsalva manoeuvre. *Br Heart J* 1980; 44: 560-9.
54. Uber-Zak LD, Venkatesh YS. Neurologic complications of sit-ups associated with the Valsalva maneuver: 2 case reports. *Arch Phys Med Rehabil* 2002; 83: 278-82.
55. Walker FO, Vern BA. The mechanism of pneumocephalus formation in patients with CSF fistulas. *J Neurol Neurosurg Psychiatry* 1986; 49: 203-5.
56. Markwalder TM, Reulen HJ. Influence of neomembranous organisation, cortical expansion and subdural pressure on the post-operative course of chronic subdural haematoma—an analysis of 201 cases. *Acta Neurochir (Wien)* 1986; 79: 100-6.
57. Qasem F, McCallum C, Armstrong P. Epidural blood patch treatment for headache caused by a ruptured Tarlov cyst. *Can J Anesth* 2017; 64: 983-4.
58. Ferrante E, Rubino GF, Ferrante MM. Can the Valsalva maneuver during delivery effort cause a recurrence of spontaneous intracranial hypotension? *Eur J Obstet Gynecol Reprod Biol* 2015; 189: 113-4.
59. Duane TD. Valsalva hemorrhagic retinopathy. *Trans Am Ophthalmol Soc* 1972; 70: 298-313.
60. Kadrmaz EF, Pach JM. Vitreous hemorrhage and retinal vein rupture. *Am J Ophthalmol* 1995; 120: 114-5.
61. Chapman-Davies A, Lazarevic A. Valsalva maculopathy. *Clin Exp Optom* 2002; 85: 42-5.
62. Gibran SK, Kenawy N, Wong D, Hiscott P. Changes in the retinal inner limiting membrane associated with Valsalva retinopathy. *Br J Ophthalmol* 2007; 91: 701-2.
63. Hönemann C, Brandt L. Valsalva retinopathy: a rare complication after general anesthesia. *A A Case Rep* 2015; 5: 231-3.
64. Aljalbout Y, Sandadi J. Spontaneous hyphema in a patient undergoing laparoscopic appendectomy. *A A Case Rep* 2013; 1: 8.
65. Eneh A, Almeida D. Valsalva hemorrhagic retinopathy during labour: a case report and literature review. *Can J Ophthalmol* 2013; 48: e145-7.
66. Dejene S, Ahmed F, Jack K, Anthony A. Pneumothorax, music and balloons: a case series. *Ann Thorac Med* 2013; 8: 176-8.
67. Park JM, Park Y-C, Lee JN, Bae JS, Kang SK. Pneumomediastinum after functional endoscopic sinus surgery under general anesthesia - a case report. *Korean J Anesthesiol* 2013; 64: 367-72.
68. Gazula S, Gooty S, Thakur N. Life-threatening complication of intraoperative Valsalva maneuver in an infant. *J Neurosurg Anesthesiol* 2015; 27: 179-81.
69. Sperry K. Achalasia, the Valsalva maneuver, and sudden death: a case report. *J Forensic Sci* 1994; 39: 547-51.