



Ondine's curse: anesthesia for laparoscopic implantation of a diaphragm pacing stimulation system

Le syndrome d'Ondine: l'anesthésie pour l'implantation par laparoscopie d'un stimulateur phrénique intradiaphragmatique

Ahtsham U. Niazi, MBBS · Aaron Mocon, MD ·
Robert G. Varadi, MD · Vincent W. Chan, MD ·
Allan Okrainec, MD

Received: 18 June 2011 / Accepted: 15 August 2011 / Published online: 25 August 2011
© Canadian Anesthesiologists' Society 2011

Abstract

Purpose Central alveolar hypoventilation syndrome (CAHS) is a rare disease characterized by the loss of autonomic control of breathing. This condition causes hypoventilation and obstruction during sleep. Throughout their lives, these patients require ventilatory assistance by means of positive pressure ventilation to their lungs via mask, tracheotomy, or other means, such as phrenic nerve pacers. The diaphragm pacing stimulation system (DPSS) is a new treatment where electrodes are implanted into the diaphragm and cause contraction on stimulation. The DPSS has been used successfully in tetraplegic patients and patients suffering from amyotrophic lateral sclerosis (ALS). It has been shown to improve quality of life and to extend survival in patients with advanced respiratory muscle weakness. In our case, we describe the perioperative management of an adult patient with acquired CAHS who presented for laparoscopic DPSS insertion.

Clinical features Our patient was a 50-yr-old female who developed CAHS at age thirteen after contracting encephalitis. Since the onset of her disease, she had been managed with positive pressure ventilation to her lungs via mask. Due to her longstanding disease, she presented with pulmonary

hypertension and cor pulmonale and was scheduled for laparoscopic DPSS implantation. Our anesthetic technique included a total intravenous technique with remifentanyl and propofol, and her trachea was intubated without the use of muscle relaxants. The pacemakers were switched on when the patient emerged from anesthesia, which provided her with ventilatory support and allowed us to extubate her trachea.

Conclusion We present the successful anesthetic management of an adult patient with CAHS undergoing laparoscopic DPSS insertion.

Résumé

Objectif Le syndrome d'hypoventilation alvéolaire centrale congénitale (HVACC) est une maladie rare qui se caractérise par la perte du contrôle autonome de la respiration. Cette affection provoque de l'hypoventilation et une obstruction pendant le sommeil. Tout au long de leur vie, les patients atteints de ce syndrome nécessitent une assistance ventilatoire qui s'effectue en fournissant une ventilation en pression positive à leurs poumons via un masque, une trachéotomie, ou d'autres moyens, tels que les stimulateurs phréniques. Le stimulateur phrénique intradiaphragmatique est un nouveau traitement qui consiste à implanter des électrodes dans le diaphragme, lesquels provoquent une contraction lorsqu'elles sont stimulées. Le stimulateur phrénique intradiaphragmatique a été utilisé avec succès chez des patients tétraplégiques et des patients atteints de sclérose latérale amyotrophique (SLA). Il a été démontré que ce dispositif améliorait la qualité de vie et prolongeait la survie chez les patients atteints d'une faiblesse avancée des muscles respiratoires. Dans le cas présenté ici, nous décrivons la prise en charge périopératoire d'une patiente adulte atteinte d'une HVACC acquise qui s'est présentée pour

A. U. Niazi, MBBS (✉) · A. Mocon, MD · V. W. Chan, MD
Department of Anesthesia and Pain Management, Toronto
Western Hospital, University Health Network, 399 Bathurst St.,
Toronto, ON M5T 2S8, Canada
e-mail: ahtsham.niazi@uhn.on.ca

R. G. Varadi, MD
Department of Respiratory Medicine, West Park Healthcare
Centre, York, ON, Canada

A. Okrainec, MD
Department of General Surgery, Toronto Western Hospital,
University Health Network, Toronto, ON, Canada

l'insertion par laparoscopie d'un stimulateur phrénique intradiaphragmatique.

Éléments cliniques *Notre patiente était une femme âgée de 50 ans qui a manifesté une HVACC à l'âge de treize ans après avoir contracté une encéphalite. Depuis l'apparition de sa maladie, elle a été prise en charge par ventilation en pression positive de ses poumons via un masque. En raison de sa maladie prolongée, elle s'est présentée avec une hypertension pulmonaire et un cœur pulmonaire; une chirurgie d'implantation par laparoscopie d'un stimulateur phrénique intradiaphragmatique a été prévue. Notre technique anesthésique consistait en une technique intraveineuse totale à l'aide de rémifentanyl et de propofol, et l'intubation de la trachée a eu lieu sans curare. Les stimulateurs ont été enclenchés lorsque la patiente s'est réveillée de l'anesthésie, ce qui lui a procuré un soutien ventilatoire et nous a permis d'extuber sa trachée.*

Conclusion *Nous présentons la prise en charge anesthésique réussie d'une patiente adulte atteinte de HVACC subissant une insertion de stimulateur phrénique intradiaphragmatique par laparoscopie.*

Central alveolar hypoventilation syndrome (CAHS) is an extremely rare condition characterized by failure of the autonomic control of breathing during sleep.¹ The term "Ondine's curse" is more commonly used for cases of congenital central alveolar hypoventilation (CCHS), but it is also applied to acquired cases. The term originates from a German myth about Ondine, an oceanic nymph who punished her unfaithful lover with the loss of all movements and functions that did not involve his conscious will. He was thus condemned to remain awake forever; otherwise, he would stop breathing and die. A similar condition develops in patients with CAHS—a rare neuropathologic syndrome characterized by an inadequate central respiratory drive with a blunted response to increasing arterial carbon dioxide tension (PaCO_2)—which results in hypoventilation and apnea leading to hypercarbia and hypoxemia.² The hypoventilation and apnea occur typically during periods of sleep when patients demonstrate a blunted sensitivity to hypercarbia.² Unless early invasive ventilation is instituted, these prolonged periods of hypoxia cause these patients to develop pulmonary hypertension and cor pulmonale.³ Diaphragm pacing stimulation is a new treatment recently approved by the Food and Drug Administration which provides direct diaphragmatic stimulation to assist breathing. It has been used successfully with tetraplegic patients and those who suffer from amyotrophic lateral sclerosis (ALS).⁴⁻⁶ It has been shown to improve quality of life and to extend survival in patients with advanced respiratory muscle weakness.⁷ This case report describes the anesthetic management and

considerations for a patient with CAHS undergoing DPSS implantation. Our patient provided written informed consent for publication prior to submission.

Case description

Our patient was a 50-yr-old female of small stature with a body mass index of 23. She had developed CAHS at the age of 13 after suffering from encephalitis. For several months, she was managed conservatively with a rocking bed, and she then had bilateral phrenic nerve pacemakers implanted, which successfully managed her condition for 24 yr. At age 37, nocturnal positive pressure ventilation (PPV) to her lungs via mask was added after she contracted pneumonia. Unfortunately, owing to progressive dysfunction of her phrenic nerve pacemakers, she developed worsening chronic ventilatory failure and eventual cor pulmonale. In addition, her history included rapid atrial flutter precipitating episodic cardiac failure. Though an ablation procedure was considered, the arrhythmia was ultimately controlled with oral beta-blockers. Her list of medications included diuretics, warfarin, and metoprolol. The warfarin was discontinued four days prior to her surgery, and she was given subcutaneous low-molecular-weight heparin until the day prior to surgery.

The patient's 2D echocardiogram showed a normally functioning left ventricle and a mildly enlarged right ventricle with severely reduced function. The right ventricular systolic pressure (RVSP) was 32 mmHg and the valves were normal. A complete blood count revealed polycythemia with a hemoglobin concentration of $192 \text{ g}\cdot\text{L}^{-1}$. Her baseline arterial blood gases on room air were pH 7.41, PCO_2 65, PO_2 43, HCO_3 42, and SaO_2 94%. The electrocardiogram showed atrial flutter, and her chest *x-ray* showed a small chronic left pleural effusion and bilateral atelectasis.

On the morning of surgery, the patient was breathing with the assistance of her volume-controlled ventilator which was set to assist-control mode with a tidal volume of 700 mL and 16 breaths $\cdot\text{min}^{-1}$. In the operating room, standard American Society of Anesthesiologists monitoring was used in addition to a radial arterial line, fluid warmer, and a forced-air warming blanket. Cardiac pacing/defibrillating pads were applied to the patient prior to induction, and a cardiac arrest cart was kept in the operating room in case the patient required cardioversion for atrial tachyarrhythmia. Prior to induction, the patient lungs were preoxygenated with 100% O_2 via bag-valve-mask assist ventilation. Anesthesia was induced with fentanyl $0.7 \text{ }\mu\text{g}\cdot\text{kg}^{-1}$ *iv* and propofol $2.3 \text{ mg}\cdot\text{kg}^{-1}$ *iv*, and the patient's trachea was intubated without any neuromuscular blockade. The patient was maintained with an air/oxygen

mixture and a total intravenous anesthetic technique using propofol $50\text{--}160\ \mu\text{g}\cdot\text{kg}^{-1}\cdot\text{min}^{-1}$ and remifentanyl $0.125\text{--}0.5\ \mu\text{g}\cdot\text{kg}^{-1}\cdot\text{min}^{-1}$. The patient's tidal volume was maintained at $450\text{--}500\ \text{mL}$ using volume control ventilation, and the respiratory rate was maintained at $8\text{--}10\ \text{breaths}\cdot\text{min}^{-1}$ to target a partial pressure of carbon dioxide (ETCO₂) which correlated with a PaCO₂ reflective of the patient's baseline value measured by serial arterial blood samples.

A laparoscopic surgical procedure was performed, and care was taken to keep the intra-abdominal pressures $<12\ \text{cm H}_2\text{O}$ during peritoneal insufflation. No change in blood pressure was noticed with slow intraperitoneal insufflation. After mapping the diaphragm, two electrodes were embedded into the musculature of the abdominal aspect of each hemidiaphragm, and the electrodes were then connected to an external stimulator for electrical activation of the diaphragm. The procedure was completed within three hours.

An arterial blood gas analysis performed on F_iO₂ at 0.7 prior to emergence from anesthesia showed pH 7.42, PCO₂ 51, PO₂ 84, HCO₃ 31, and SaO₂ 99%. The diaphragmatic pacemakers were then tested. Stimulation produced diaphragmatic contractions which were evident under direct visualization through the laparoscopic camera and by the appearance of a curare notch on the ETCO₂ curve. The ventilator was switched off, and spirometry showed adequate flow-volume curves with tidal volumes that varied from $250\text{--}290\ \text{mL}$ (Figure). Infusions were discontinued and emergence from anesthesia occurred within one to two minutes. Once the patient was awake and obeying commands, her trachea was extubated. The patient was transferred to the intensive care unit postoperatively with diaphragm pacer-driven ventilation assisted intermittently with PPV by bag-valve-mask to maintain a normal SpO₂. After a brief requirement for PPV by mask in the immediate postoperative

period, the patient was discharged on postoperative day one (F_iO₂ 0.3, pH 7.48, PCO₂ 36, PO₂ 85, HCO₃ 27, and SaO₂ 98%) to the Home Ventilation Assessment Unit for ongoing pacemaker adjustment and management.

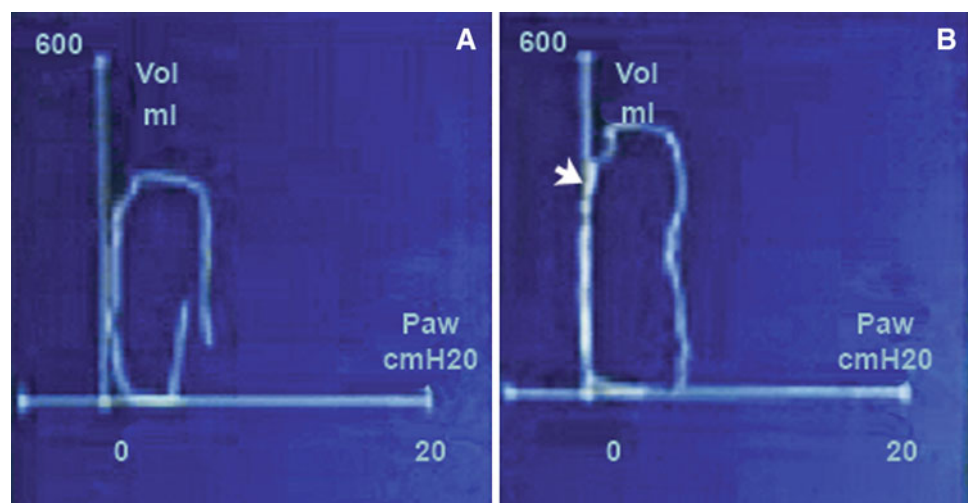
Discussion

We report the perioperative management of a patient with acquired CAHS who presented for laparoscopic DPSS implantation.

The term "Ondine's Curse" was used initially by Severinghaus and Mitchell⁸ in 1962 when they described three patients with acquired CAHS occurring following high cervical and brainstem surgery. These patients could breathe when awake and when told to breathe, but mechanical lung ventilation was needed to treat severe central sleep apnea. In 1970, Mellins *et al.*⁹ described the first case of an infant who presented with all the typical signs and symptoms of congenital CAHS, generally termed CCHS. While less common, acquired CAHS has been identified in conditions that either directly or indirectly affect the brainstem respiratory centre, including medullar tumours,¹⁰ infection (particularly poliomyelitis), upper cervical trauma, some mitochondrial diseases, degenerative diseases (e.g., multiple sclerosis), or non-specific anoxic ischemic insults.¹¹⁻¹³ Our patient stated that she had suffered from encephalitis at age thirteen, and since then, she required ventilatory support. Brainstem encephalitis has been described as a cause of acquired CAHS,¹⁴ and it has been postulated that the infection can cause small vessel vasculitis, which may impair blood flow to the brainstem.¹⁵ The exact cause in our patient is unclear.

Central alveolar hypoventilation syndrome—a rare neuropathologic syndrome characterized by an inadequate central respiratory drive with a blunted response to

Figure Pressure-volume loops for patient. A. Breathing spontaneously with no diaphragmatic stimulation; and B. Breathing spontaneously with diaphragmatic stimulator. Section B clearly shows the notch (white arrow) indicating diaphragmatic stimulation which provides an extra tidal volume of $100\text{--}150\ \text{mL}$ to the patient's spontaneous breath



PaCO₂—results in hypoventilation and apnea leading to hypercarbia and hypoxemia.² The hypoventilation and apnea occur typically during periods of sleep when patients demonstrate a blunted sensitivity to hypercarbia.² The mainstay of long-term care for children with congenital CAHS is PPV through a permanent tracheotomy.¹⁵⁻¹⁷ In contrast, our patient had been managed with a combination of phrenic nerve pacing and PPV by mask. As these treatments failed, her abnormal breathing and prolonged periods of hypoxia led to pulmonary vascular remodelling and eventual development of pulmonary hypertension, right heart failure, and subsequent arrhythmia.

Anesthetic goals for patients with CAHS involve minimizing respiratory depression in order to avoid prolonged mechanical lung ventilation. In view of their pulmonary hypertension, regional anesthesia, such as a carefully titrated lumbar epidural, appears to be the anesthetic of choice for CAHS patients where applicable. Spinal anesthesia should be avoided as it may cause a profound sympathetic blockade, decrease in venous return, and bradycardia, which can lead to right heart failure.¹⁸ Combined spinal epidural technique has been used successfully in patients with severe pulmonary hypertension during pregnancy.¹⁹ However, if general anesthesia is necessary, it is prudent to intubate the patient's trachea and control lung ventilation in all cases, as these patients will not breathe spontaneously when asleep. Relatively short-acting anesthetic agents are preferred. In our case, both remifentanyl and propofol provided optimal anesthetic qualities, and no long-acting opioid was used. Inhalation anesthetics were avoided, as their clearance would depend on adequate postoperative lung ventilation which may be deficient with patients suffering from CAHS. The absence of a neuromuscular blocking agent was necessary as the surgery required constant intraoperative mapping of the diaphragm. Short-acting muscle relaxants, such as succinylcholine, could have been used for tracheal intubation; however, due to hypotonia, it has been recommended to avoid succinylcholine until more data are available concerning its use in this patient group.² The absence of muscle relaxation did not affect the course of our anesthetic as the patient's trachea was intubated easily with the help of propofol and fentanyl; moreover, due to her weak respiratory muscles and her underlying condition, our patient did not offer much resistance to mechanical lung ventilation.

Other goals in this case included avoidance of hypoxia, hypercarbia, acidosis (respiratory or metabolic), hypo or hypovolemia, and hypothermia and provision of adequate anesthesia and pain control. These steps were taken to prevent a pulmonary hypertensive crisis and right ventricular failure. Hypoxia, hypercarbia, and acidosis can increase PVR directly or indirectly and should be avoided.¹⁸ Hypovolemia can cause impaired RV perfusion, and

hypovolemia can cause pulmonary congestion and RV failure.¹⁸ Particular attention was devoted to temperature regulation because patients with congenital CAHS can have problems with central temperature control.² Also, hypothermia could worsen the patient's pulmonary hypertension.¹⁸

Monitoring included routine monitors and arterial blood pressure. A central venous catheter would have allowed us to guide adequate cardiac preload and would have provided a route for cardiac pacing and vasopressor or inotrope administration, if required. However, due to the patient's history of uncontrolled atrial flutter leading to cardiac failure, it was decided to avoid catheter insertion due to the small risk of provoking another arrhythmia. In case the patient did develop an unstable arrhythmia, external pacing pads were applied, and a defibrillator was kept in the room for emergency cardioversion. We also considered treatment strategies in the event of a pulmonary hypertensive crisis, such as inhaled prostacyclin analogs, inhaled nitric oxide, and intravenous phosphodiesterase 5 inhibitors (e.g., milrinone).

Regarding extubation of the trachea, the patient could breathe only if sufficiently awake to respond; therefore, the anesthesia was designed to allow the patient to meet the extubation criteria earlier. With diaphragmatic stimulation, the patient was able to generate adequate tidal volumes of 290-300 mL, and once the patient was awake, her trachea was successfully extubated. The intensive care unit was notified to have a mechanical ventilator on standby if required.

Unlike the majority of phrenic nerve stimulators which are inserted through thoracic or cervical incisions,²⁰ in our case, the surgeon placed electrodes directly into the musculature of the diaphragm via an abdominal laparoscopic approach. This approach required a pneumoperitoneum which potentially could have caused a reduction in preload, acidosis due to CO₂ insufflation, and hypoxia due to increased intra-abdominal pressure.²¹ All of these conditions could have worsened our patient's pulmonary vascular resistance and induced RV failure.¹⁸ To avoid any problems, the patient was kept warm, good communication was maintained with the surgeon to minimize intra-abdominal pressures, and a close eye was kept on the ventilatory parameters to maintain baseline ETCO₂ and prevent hypoxia.²²

In conclusion, CAHS is a rare neuropathological disorder with profound perioperative concerns for the anesthesiologist. It is imperative for the anesthesiologist to have a good understanding of the condition and its secondary complications. In addition, it is recommended that good communication occur between the anesthesiologist, surgeon, and respiratory physician concerning the management of these patients.

Funding This project was completely funded by internal departmental funding.

Competing interests None declared.

References

1. Takeda S, Fujii Y, Kawahara H, Nakahara K, Matsuda H. Central alveolar hypoventilation syndrome (Ondine's curse) with gastroesophageal reflux. *Chest* 1996; 110: 850-2.
2. Strauser LM, Helikson MA, Tobias JD. Anesthetic care for the child with congenital central alveolar hypoventilation syndrome (Ondine's curse). *J Clin Anesth* 1999; 11: 431-7.
3. Gozal D. Congenital central hypoventilation syndrome: an update. *Pediatr Pulmonol* 1998; 26: 273-82.
4. Onders RP, Ponsky TA, Elmo M, Lidsky K, Barksdale E. First reported experience with intramuscular diaphragm pacing in replacing positive pressure mechanical ventilators in children. *J Pediatr Surg* 2011; 46: 72-6.
5. Onders RP, Elmo MJ, Ignagni AR. Diaphragm pacing stimulation system for tetraplegia in individuals injured during childhood or adolescence. *J Spinal Cord Med* 2007; 30(Suppl 1): S25-9.
6. Schmiesing CA, Lee J, Morton JM, Brock-Utne JG. Laparoscopic diaphragmatic pacer placement—a potential new treatment for ALS patients: a brief description of the device and anesthetic issues. *J Clin Anesth* 2010; 22: 549-52.
7. DiMarco AF, Onders RP, Kowalski KE, Miller ME, Ferek S, Mortimer JT. Phrenic nerve pacing in a tetraplegic patient via intramuscular diaphragm electrode. *Am J Respir Crit Care Med* 2002; 166(12 Pt 1): 1604-6.
8. Severinghaus JW, Mitchell RA. Ondine's curse - failure of respiratory center automaticity while awake. *Clin Res* 1962; 10: 122.
9. Mellins RB, Balfour HH Jr, Turino GM, Winters RW. Failure of automatic control of ventilation (Ondine's curse). Report of an infant born with this syndrome and review of the literature. *Medicine (Baltimore)* 1970; 49: 487-504.
10. Nakajima M, Katsura K, Hashimoto Y, Terasaki T, Uchino M. A case of Ondine curse associated with a medullary tumor (Japanese). *Rinsho Shinkeigaku* 2000; 40: 811-5.
11. Sadler M, Wiles CM, Stoodley N, Linnane SJ, Smith AP. Ondine's curse in a woman with Leber's hereditary optic neuropathy. *J Neurol Neurosurg Psychiatry* 2002; 73: 347-8.
12. Kraus J, Heckmann JG, Druschky A, Erbguth F, Neundorfer B. Ondine's curse in association with diabetes insipidus following transient vertebrobasilar ischemia. *Clin Neurol Neurosurg* 1999; 101: 196-8.
13. Juan G, Ramon M, Ciscar MA, et al. Acute respiratory insufficiency as initial manifestation of brain stem lesions (Spanish). *Arch Bronconeumol* 1999; 35: 560-3.
14. Khong P, Lazzaro A, Mobbs R. Phrenic nerve stimulation: the Australian experience. *J Clin Neurosci* 2010; 17: 205-8.
15. Tirupathi S, Webb DW, Phelan E, Butler K, McMamin JB. Central hypoventilation syndrome after haemophilus influenzae type b meningitis and herpes infection. *Pediatr Neurol* 2008; 39: 358-60.
16. Guillemainault C, McQuitty J, Ariagno RL, Challamel MJ, Korobkin R, McClead RE Jr. Congenital central alveolar hypoventilation syndrome in six infants. *Pediatrics* 1982; 70: 684-94.
17. Oren J, Kelly DH, Shannon DC. Long-term follow-up of children with congenital central hypoventilation syndrome. *Pediatrics* 1987; 80: 375-80.
18. Salehi A (2011) Pulmonary hypertension: a review of pathophysiology and anesthetic management. *Am J Ther* 2011; DOI: [10.1097/MJT.0b013e3181f94c02](https://doi.org/10.1097/MJT.0b013e3181f94c02).
19. Bonnin M, Mercier FJ, Sitbon O, et al. Severe pulmonary hypertension during pregnancy: mode of delivery and anesthetic management of 15 consecutive cases. *Anesthesiology* 2005; 102: 1133-7.
20. Chen ML, Tablizo MA, Kun S, Keens TG. Diaphragm pacers as a treatment for congenital central hypoventilation syndrome. *Expert Rev Med Devices* 2005; 2: 577-85.
21. Gerges FJ, Kanazi GE, Jabbour-Khoury SI. Anesthesia for laparoscopy: a review. *J Clin Anesth* 2006; 18: 67-78.
22. Girgis RE, Mathai SC. Pulmonary hypertension associated with chronic respiratory disease. *Clin Chest Med* 2007; 28: 219-32.