

# Comparison of different noninvasive diagnostic methods for biliary atresia: a meta-analysis

Jin-Peng He, Yun Hao, Xiao-Lin Wang, Xiao-Jin Yang, Jing-Fan Shao, Jie-Xiong Feng

Wuhan, China

**Background:** This study was undertaken to retrospectively analyze the accuracy of different methods in differentiating biliary atresia from neonatal jaundice.

**Methods:** A search was made in MEDLINE, and the Web of Science for relevant original articles published in English; methodological quality of the included studies was also assessed. Two reviewers extracted data independently. Studies were pooled, summary receiver operating characteristics curve and diagnostic odds ratio (DOR) with corresponding confidence intervals were calculated.

**Results:** For diagnosis of biliary atresia, ultrasonography (US), hepatic scintigraphy (HBS), and magnetic resonance cholangiography (MRCP) had a pooled sensitivity of 74.9% (range: 70.4%-79.1%), 93.4% (range: 90.3%-95.7%) and 89.7% (range: 84.8%-93.4%), a specificity of 93.4% (range: 91.4%-95.1%), 69.2% (range: 65.1%-73.1%) and 64.7% (range: 58.0%-71.0%), a positive likelihood ratio of 12.16 (range: 6.41-23.08), 3.01 (range: 2.15-4.20) and 3.10 (range: 1.59-6.06), a negative likelihood ratio of 0.23 (range: 0.13-0.38), 0.13 (range: 0.06-0.25) and 0.16 (range: 0.06-0.44), DOR of 72.56 (range: 27.34-192.58), 29.88 (range: 12.82-69.64) and 32.48 (range: 8.22-128.29), with an area under the curve of 0.96, 0.91, and 0.92, and Q value of 0.90, 0.85, and 0.85, respectively.

**Conclusions:** US, HBS and MRCP can be very useful for the diagnostic work-up of neonatal cholestasis. To improve the sensitivity and specificity, several additional measures can be used.

*World J Pediatr 2016;12(1):35-43*

**Key words:** biliary atresia;  
diagnostic methods;  
meta-analysis;  
noninvasive

**Author Affiliations:** Department of Pediatric Surgery, Tongji Hospital, Tongji Medical College, Huazhong University of Science and Technology, Wuhan, China (He JP, Hao Y, Wang XL, Yang XJ, Shao JF, Feng JX)

**Corresponding Author:** Jie-Xiong Feng, Department of Pediatric Surgery, Tongji Hospital, Tongji Medical College, Huazhong University of Science and Technology, 1095 Jiefang Ave, Qiaokou district, Wuhan 430030, China (Tel: +86-27-83665209; Fax: +86-27-83665209; Email: fengjixiong@126.com)

doi: 10.1007/s12519-015-0071-x

Online First December 2015

©Children's Hospital, Zhejiang University School of Medicine, China and Springer-Verlag Berlin Heidelberg 2015. All rights reserved.

## Introduction

Biliary atresia is a destructive inflammatory obliterative cholangiopathy of neonates that affects both intrahepatic and extrahepatic bile ducts. A timely hepatoportoenterostomy, or Kasai portoenterostomy, may restore the bile flow and help to prevent the progression of liver injury, potentially enhancing survival without liver transplantation.<sup>[1]</sup>

However, benign causes of prolonged jaundice, manifested as unconjugated hyperbilirubinemia, are common in breastfed infants. Many different diagnostic methods are applied to differentiate biliary atresia from other causes, but only by operation and cholangiogram can a diagnosis be ultimately made. In patients with neonatal hepatitis, correct diagnosis may avoid unnecessary surgery. Therefore, it is important to determine accurately the cause of persistent neonatal jaundice as early as possible. Making a presurgical diagnosis is sometimes difficult with the available noninvasive diagnostic procedures, including hepatic scintigraphy (HBS) with technetium 99m-diisopropyliminodiacetic acid, ultrasonography (US), and magnetic resonance cholangiography (MRCP).

## Methods

PubMed and Web of Science were searched (last search was performed on February 15, 2014 using the search terms: "biliary atresia", "diagnosis" and "ultrasonography" or "hepatobiliaryscintigraphy", "magnetic resonance"; the time of start to search was set as the default time with all of those studies included in PubMed or Web of Science). References of selected articles and reviews were also searched manually for additional relevant studies. When more than one of the same patient populations was included in several publications, only the most recent or complete study was used to avoid duplication of information.

Two independent reviewers assessed the eligibility of studies by reviewing titles, abstracts and sometimes full texts identified by the search. Differences were resolved by discussion and consensus. The inclusion criteria for the identified articles were as follows: 1) the sensitivity and specificity of different diagnosis methods were evaluated; 2)

the final diagnosis was made by liver biopsy or operation; 3) articles were published in full texts in English; 4) studies with sufficient information for analysis. The exclusion criteria were as follows: 1) duplicate studies on the same patients; 2) letters, reviews, case reports, conference abstracts, editorials, expert opinion reviews and abstracts.

### Data extraction and study assessment

Two investigators extracted data from eligible studies independently, discussed discrepancies, and reached consensus on all items. The data were collected from each study according to different methods of diagnosis. Duplication of data was avoided by matching author's name and the name of research centers.

### Statistical analysis

Sensitivity, specificity, positive likelihood ratio (LR+), negative likelihood ratio (LR-), diagnostic odds ratio

(DOR) and summary receiver operating characteristic (sROC) curve were used to evaluate the accuracy of different diagnosis methods. Heterogeneity between the studies was tested using Q-statistics. If the heterogeneity existed, we used a random-effects model in place of a fixed-effects model. All *P* values were in two tails. Statistical calculations were performed using Meta Disc 1.4 and STATA 12.0.

## Results

### Ultrasonography

A total of 306 relevant studies were identified for initial review using search strategies as described previously for the method of ultrasonography diagnosis. Of these, 263 were initially excluded after reading the titles and abstracts, whereas 27 were excluded after full review of the articles according to the exclusion criteria. Because

**Table.** Summary of the 31 studies included in the study

Authors	Year	DM	<i>n</i>	TP	FP	FN	TN	Sensitivity (%)	Specificity (%)
Lai et al <sup>[6]</sup>	1994	US	126	29	13	12	72	70.73	84.71
Choi et al <sup>[3]</sup>	1998	US	40	12	1	0	27	100.00	96.43
Park et al <sup>[5]</sup>	1999	US	79	21	1	4	53	84.00	98.15
Tan Kendrick et al <sup>[7]</sup>	2000	US	60	10	0	2	48	83.33	100.00
Kotb et al <sup>[8]</sup>	2001	US	65	25	0	0	40	100.00	100.00
Kanegawa et al <sup>[9]</sup>	2003	US	55	27	1	2	25	93.10	96.15
Visrutaratna et al <sup>[10]</sup>	2003	US	46	22	6	1	17	95.65	73.91
Lee et al <sup>[11]</sup>	2003	US	83	16	1	1	65	94.12	98.48
Dehghani et al <sup>[12]</sup>	2006	US	65	10	11	9	35	52.63	76.09
Takamizawa et al <sup>[13]</sup>	2007	US	85	41	2	7	35	85.42	94.59
Humphrey et al <sup>[14]</sup>	2007	US	90	22	0	8	60	73.33	100.00
Yang et al <sup>[15]</sup>	2009	US	69	17	6	17	29	50.00	82.86
Lee et al <sup>[16]</sup>	2009	US	64	18	0	11	35	62.07	100.00
Imanieh et al <sup>[17]</sup>	2010	US	58	7	2	3	46	70.00	95.83
Mittal et al <sup>[18]</sup>	2011	US	99	7	2	23	67	23.33	97.10
Jiang et al <sup>[19]</sup>	2013	US	51	21	2	2	26	91.30	92.86
Majd et al <sup>[20]</sup>	1981	HBS	22	10	5	0	7	100.00	58.33
Gerhold et al <sup>[21]</sup>	1983	HBS	27	16	1	0	10	100.00	90.91
Ang et al <sup>[22]</sup>	1986	HBS	110	43	18	0	49	100.00	73.13
Spivak et al <sup>[23]</sup>	1987	HBS	28	7	7	0	14	100.00	66.67
Salvatori et al <sup>[24]</sup>	1989	HBS	17	6	1	0	10	100.00	90.91
Rosenthal et al <sup>[25]</sup>	1989	HBS	26	10	1	2	13	83.33	92.86
Lai et al <sup>[2]</sup>	1994	HBS	76	25	4	8	39	75.76	90.70
Park et al <sup>[4]</sup>	1997	HBS	71	24	30	1	16	96.00	34.78
Gilmour et al <sup>[26]</sup>	1997	HBS	86	40	13	0	33	100.00	71.74
Lee et al <sup>[27]</sup>	2000	HBS	130	49	14	0	67	100.00	82.72
Tan Kendrick et al <sup>[7]</sup>	2000	HBS	38	12	6	0	20	100.00	76.92
Dehghani et al <sup>[12]</sup>	2006	HBS	65	16	24	3	22	84.21	47.83
Yang et al <sup>[15]</sup>	2009	HBS	69	30	19	4	16	88.24	45.71
Liu et al <sup>[28]</sup>	2010	HBS	84	29	14	0	41	100.00	74.55
Shah et al <sup>[29]</sup>	2012	HBS	46	22	7	6	11	78.57	61.11
Norton et al <sup>[30]</sup>	2002	MRCP	23	9	1	3	10	75.00	90.91
Han et al <sup>[31]</sup>	2002	MRCP	47	23	1	0	23	100.00	95.83
Ryeom et al <sup>[32]</sup>	2005	MRCP	23	4	8	0	11	100.00	57.89
Yang et al <sup>[15]</sup>	2009	MRCP	69	29	5	15	20	65.91	80.00
Huang et al <sup>[33]</sup>	2011	MRCP	60	13	0	2	45	86.67	100.00
Jiang et al <sup>[19]</sup>	2013	MRCP	23	11	8	1	3	91.67	27.27
Liu et al <sup>[34]</sup>	2014	MRCP	190	103	55	1	31	99.04	36.05

DM: diagnostic method; TP: true positive; FP: false positive; FN: false negative; TN: true negative; US: ultrasonography; HBS: hepatobiliaryscintigraphy; MRCP: magnetic resonance cholangiopancreatography.

of the overlapping studying period, part of patients included in two studies were repeatedly reported by Choi et al<sup>[2,3]</sup> and Park et al.<sup>[4,5]</sup> After careful analysis, we selected one of the two studies in our meta-analysis, and excluded the other one for its duplicated result.<sup>[2,3]</sup> Only 16 studies were included in this meta-analysis (Table). Ultimately, the systematic literature search yielded a total of 16 studies comprising 1135 patients for final analysis.

Figs. 1 and 2 show the forest plots of sensitivity and specificity pooling. For diagnosis of biliary atresia, ultrasonography had an overall sensitivity of 74.9% (range: 70.4%-79.1%), a specificity of 93.4% (range:

91.4%-95.1%), LR+ of 12.16 (range: 6.41-23.08), LR- of 0.23 (range: 0.13-0.38) and DOR of 72.56 (range: 27.34-192.58). The sROC of the meta-analysis is shown in Fig. 3 with an AUC of 0.96 and Q of 0.90. Figs. 4 and 5 show the funnel plots of sensitivity and specificity pooling for ultrasonography.

### Hepatic scintigraphy

Ninety-four relevant studies were identified for initial review using search strategies as described previously for the method of hepatobiliary scintigraphy diagnosis. Of these, 65 were excluded after reading the titles and

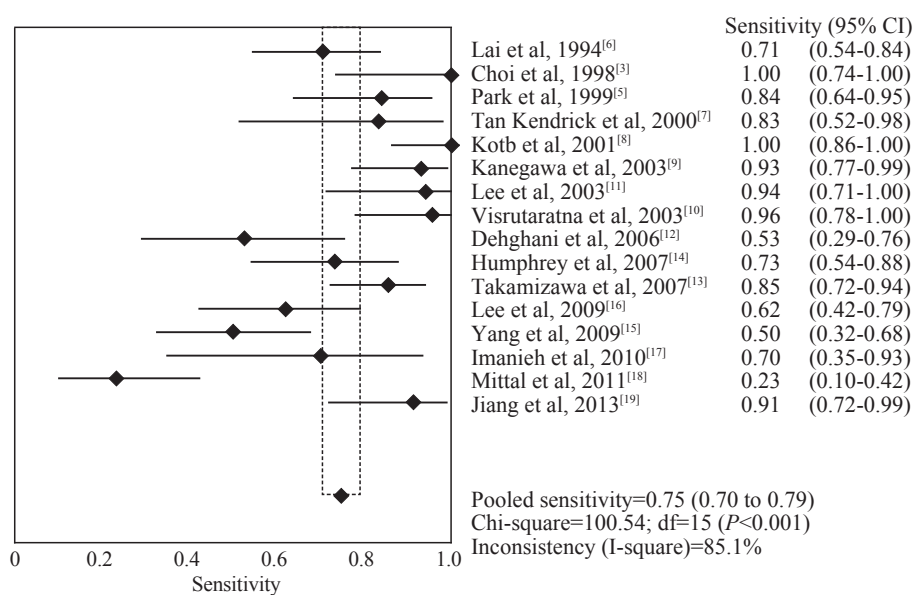


Fig. 1. The forest plots of sensitivity pooling for ultrasonography. CI: confidence interval.

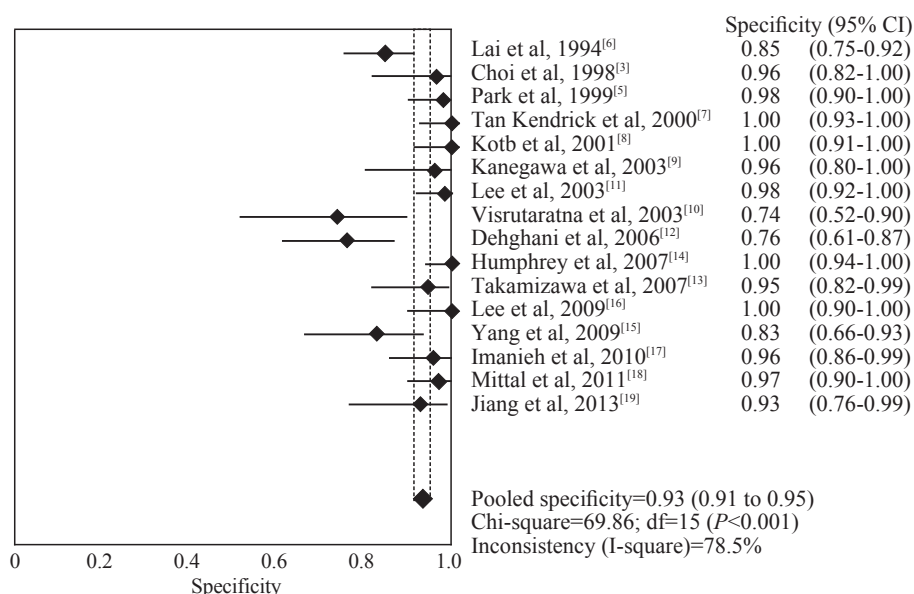


Fig. 2. The forest plots of specificity pooling for ultrasonography. CI: confidence interval.

abstracts, whereas 12 were excluded after full review of articles according to the exclusion criteria. Only 14 studies were included in this meta-analysis (Table). Ultimately, literature search yielded a total of 14 studies comprising 868 patients for final analysis.

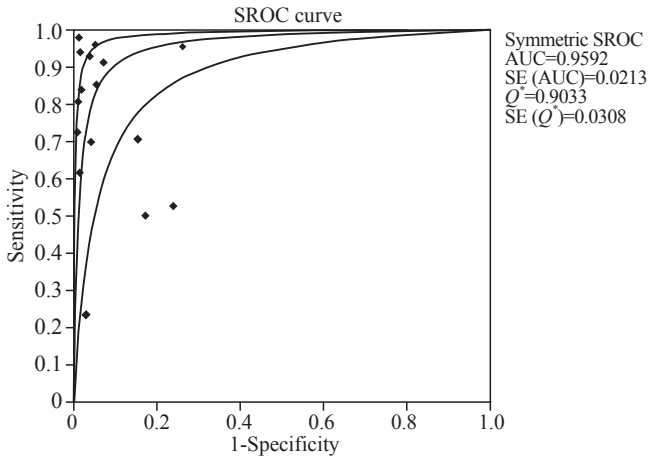


Fig. 3. Summary receiver operating characteristics (SROC) curve of the ultrasonography. AUC: area under the curve; SE: standard error;  $Q^*$ :  $Q$  value.

Figs. 6 and 7 show the forest plots of sensitivity and specificity pooling. For the diagnosis of biliary atresia, scintigraphy had an overall sensitivity of 93.4% (range: 90.3%-95.7%), a specificity of 69.2% (range: 65.1%-73.1%), LR+ of 3.01 (range: 2.15-4.20), LR- of 0.13 (range: 0.06-0.25) and DOR of 32.90 (range: 12.29-75.78). The sROC of the meta-analysis is shown in Fig. 8 with an AUC of 0.90 and  $Q$  of 0.83.

**Magnetic resonance cholangiography**

Altogether 113 relevant studies were identified for initial review using search strategies as described previously for magnetic resonance diagnosis. Of these, 103 were excluded after reading the titles and abstracts, whereas 3 were excluded after full review of articles according to the exclusion criteria. Only 7 studies were included in this meta-analysis (Table). Ultimately, the literature search yielded a total of 7 studies comprising 435 patients for final analysis.

Figs. 9 and 10 demonstrate the forest plots of sensitivity and specificity pooling. For the diagnosis

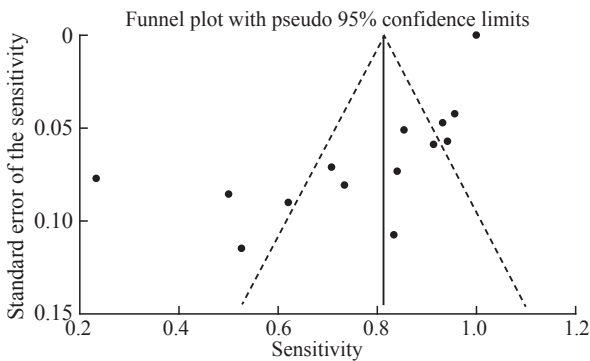


Fig. 4. The funnel plots of sensitivity pooling for ultrasonography.

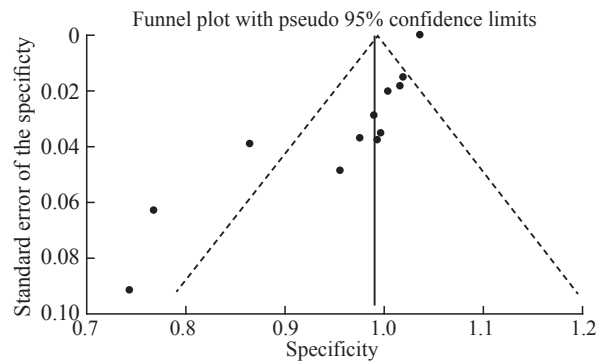


Fig. 5. The funnel plots of specificity pooling for ultrasonography.

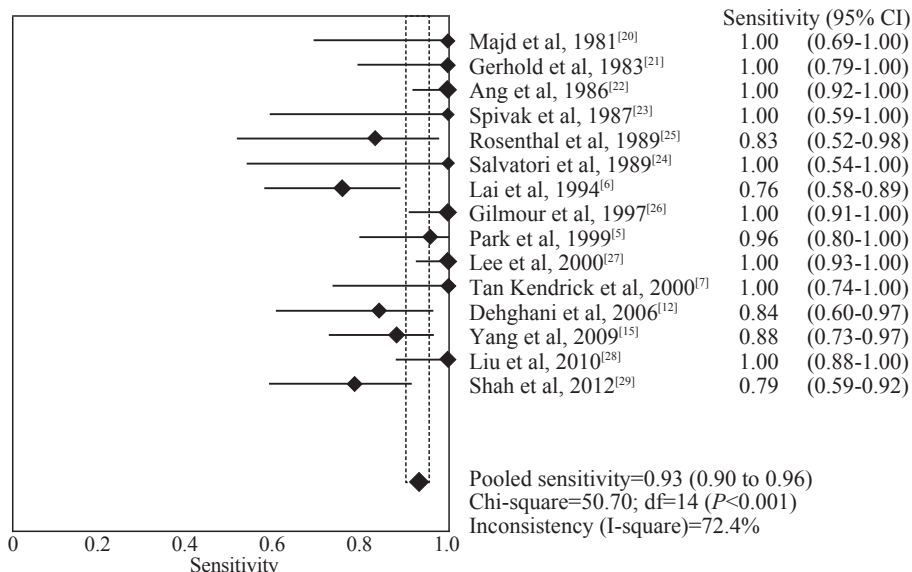


Fig. 6. The forest plots of sensitivity pooling for hepatic scintigraphy. CI: confidence interval.

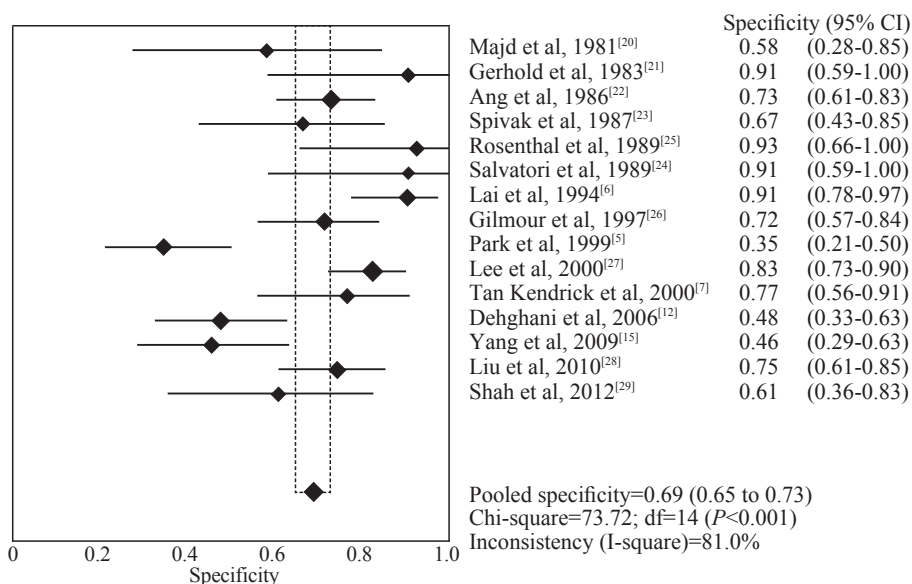


Fig. 7. The forest plots of specificity pooling for hepatic scintigraphy. CI: confidence interval.

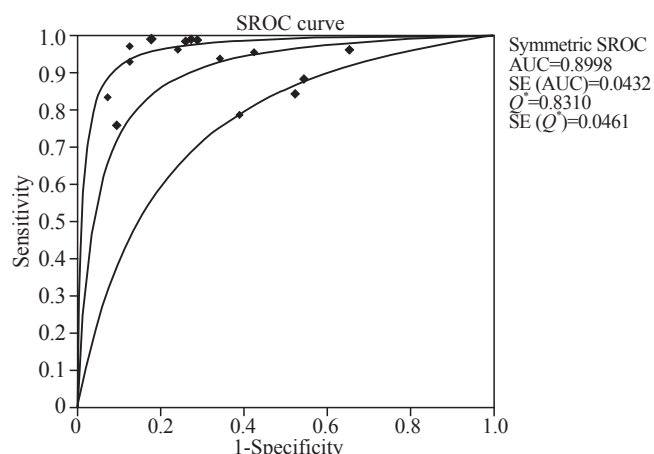


Fig. 8. Summary receiver operating characteristics (SROC) curve of the hepatic scintigraphy. AUC: area under the curve; SE: standard error; Q\*: Q value.

of biliary atresia, MRCP had an overall sensitivity of 89.7% (range: 84.8%-93.4%), a specificity of 64.7% (range: 58.0%-71.0%), LR+ of 3.10 (range: 1.59-6.06), LR- of 0.16 (range: 0.06-0.44), and DOR of 32.48 (range: 8.22-128.29). The sROC of the meta-analysis is shown in Fig. 11 with an AUC of 0.92 and Q of 0.85.

**Methodological quality of the studies**

By two authors all studies were assessed with high levels of methodological quality according to the Newcastle-Ottawa quality assessment scale.

**Discussion**

Biliary atresia and infantile hepatitis are the two most common causes of infantile jaundice and they have similar clinical manifestations. The North American Society for

Pediatric Gastroenterology, Hepatology, and Nutrition (NASPGHAN) guidelines for the evaluation of cholestatic jaundice in infants recommend that any infant noted to be jaundiced at the two-week well child visit should be evaluated for cholestasis.<sup>[35]</sup> Evaluation of breast-fed infants may be delayed until three weeks of age if they have a normal physical examination, no history of dark urine or light stools, and can be reliably monitored.<sup>[35-37]</sup> Neonatal hepatitis and biliary atresia (BA), which typically occur in term infants, account for 70%-80% of cases.<sup>[38]</sup>

However, they have quite different treatment procedures. Early diagnosis of BA is crucial to the success of the surgical treatment of this disease. US, a simple and noninvasive procedure, is widely used. It is more helpful in the diagnosis of choledochal cysts but can also suggest the diagnosis of BA. In 1996, Choi et al<sup>[2]</sup> reported that triangular cord sign (TCS), a focal area of increased echogenicity anterior to the bifurcation of the portal vein representing the fibrotic remnant of the extrahepatic biliary tree at the porta hepatis, has been considered as an specific diagnostic feature for BA. What's more, US features showed a significant difference between the BA and non-BA groups. The features with the greatest individual sensitivity and specificity, respectively, in the diagnosis of BA were triangular cord sign (73% and 100%), abnormal gallbladder wall (91% and 95%) and shape (70% and 100%), and an absent common bile duct (93% and 92%). The hepatic artery diameter was significantly larger in infants with BA than in those without BA (mean±standard deviation, 2.2±0.59 mm vs. 1.6±0.40 mm, P<0.001).<sup>[14]</sup> After further studies, even though TCS was a more useful sonographic finding for diagnosing biliary atresia than gallbladder length and contraction,<sup>[9]</sup> TCS combined with gallbladder length



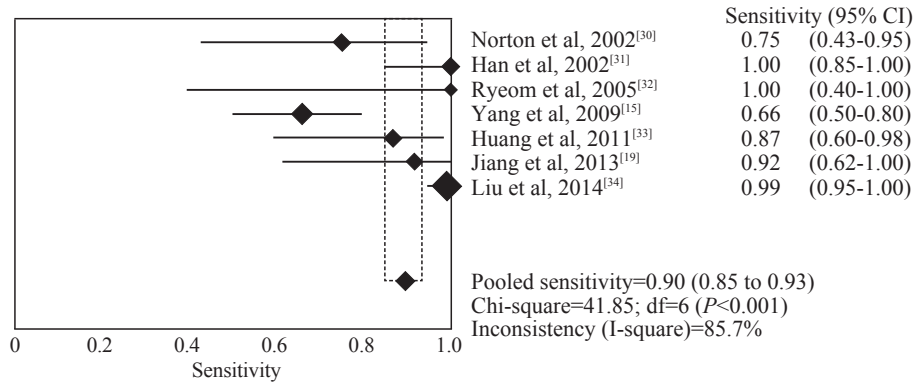


Fig. 9. The forest plots of sensitivity pooling for magnetic resonance cholangiography. CI: confidence interval.

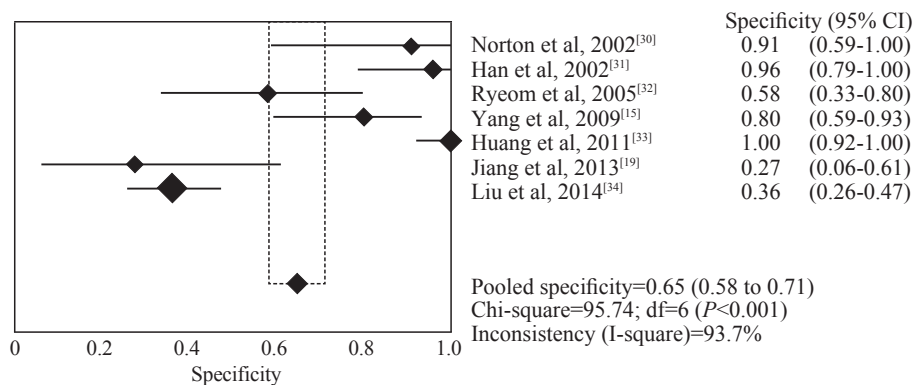


Fig. 10. The forest plots of specificity pooling for magnetic resonance cholangiography. CI: confidence interval.

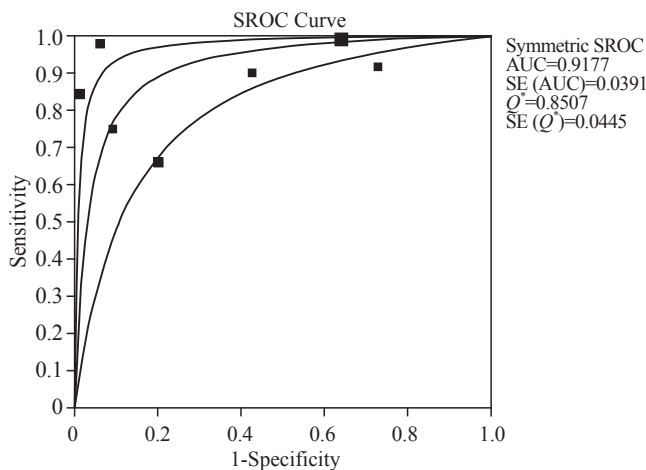


Fig. 11. Summary receiver operating characteristics (SROC) curve of the magnetic resonance cholangiography. AUC: area under the curve; SE: standard error; Q\*: Q value.

(GBL) and gallbladder contractility (GBC) was set as the internationally accepted diagnostic criterion for BA.<sup>[13]</sup>

In this meta-analysis, US performed well in differentiating neonatal hepatitis and biliary atresia (pooled DOR=72.56, AUC=0.9592 and Q value=0.9033) through the TCS with or without GBL and GBC. US showed low sensitivity in diagnosis of BA with pooled sensitivity as 74.9%. This finding shows that false-negative results

(TCS was not found) are the major shortcoming of US. On the other hand, the pooled specificity of the test was as high as 93.4%. This indicates that false-positive results (pseudo TCS) are extremely rare. The reasons for poor sensitivity are as follows: 1) the triangular cord is too small to be identified, 2) the sonographic doctor cannot show the triangular cord due to his/her inexperience with US, and 3) the TCS was not the only diagnostic criterion for BA. Most of the methods used for increasing the accuracy of US aim at increasing the sensitivity, such as measurement of hepatic artery diameter, high-frequency US and color Doppler US. Some studies demonstrated that US is a repeatable, convenient, prominent and noninvasive examination for diagnosis of BA with the development of US technology.

HBS with technetium-labeled iminodiacetic acid analogs can be helpful in distinguishing BA from neonatal hepatitis and other causes of cholestasis. The diagnosis of infantile cholestasis is mostly dependent on the presence or absence of tracer excretion. The majority of the infants who have BA are expected to have no excretion of tracer into the small bowel. In this meta-analysis, HBS performed well in differentiating neonatal hepatitis and biliary atresia (pooled DOR=32.90, AUC=0.9184 and Q value=0.8515). Pooled sensitivity was very high (93%). This shows that false-negative

results (excretion of the tracer into the bowel despite biliary atresia) are extremely rare. It is very probable that these false-negative results are caused by urine contamination interpreted as bowel excretion. HBS showed low specificity in diagnosis of BA with pooled specificity as 69%. This means that false-positive results (no excretion of tracer and bowel non-visualization in neonatal hepatitis) are the major shortcoming of HBS.

Most of the methods used for increasing the accuracy of HBS aim at increasing the specificity, such as premedication, new type of radiotracer, different dosing protocols and imaging protocols. In 2000, Lee et al<sup>[27]</sup> reported that gallbladder visualization on hepatobiliary scintigraphy is frequent in patients with biliary patency when lengthy fasting is required before and during imaging. All visualized gallbladders contracted after feeding. Presence of bowel and gallbladder radioactivity will increase the accuracy of differentiating BA from biliary patency.<sup>[27]</sup> Sevilla et al<sup>[39]</sup> reported that HBS single photon emission computed tomography improves the diagnostic accuracy to a level compatible to the planar study when performed with phenobarbitone premedication.

US and HBS are the initial imaging methods for evaluating the pediatric pancreaticobiliary ductal system. If they fail to provide an accurate diagnosis, endoscopic retrograde cholangiopancreatography (ERCP) is often performed.<sup>[40]</sup> However, ERCP is difficult to perform in young children and infants because it requires special equipment and expertise that are not available in many institutions.<sup>[41]</sup> In addition, ERCP is an invasive procedure with potential complications,<sup>[42]</sup> it is more difficult to perform and more hazardous in the pediatric population than in adults.<sup>[43]</sup>

Magnetic resonance cholangiopancreatography (MRCP) is an innovative technique for evaluating the biliary tree and pancreatic duct, initially used in adults in the early 1990s.<sup>[44,45]</sup> Obviously MRCP is noninvasive, requires no contrast material, is free from ionizing radiation, and can be performed at the outpatient clinic. The safety is comparable to that of US.<sup>[46]</sup> Thus MRCP has been increasingly used to replace ERCP or percutaneous cholangiograph in assessing many pancreaticobiliary diseases.<sup>[47,48]</sup>

In this meta-analysis, MRCP was performed well in differentiating neonatal hepatitis and biliary atresia (pooled DOR=32.48, AUC=0.9177 and Q value=0.8507). The pooled sensitivity was as high as 90%, showing that false-negative results are extremely rare. On the other hand, the pooled specificity was not as high as 65%, indicating that false-positive results are the major shortcoming of MRCP.

The present meta-analysis showed that US has a good specificity whereas HBS and MRCP have a better

sensitivity in differentiating BA from other causes of infantile jaundice. Four studies reported the accuracy of US and HBS in a series of patients, and a meta-analysis of these studies revealed the similar results. MRCP is to some extent identical to HBS. However, there were only two studies reporting the accuracy of MRCP and US in a series of patients, and the results of these studies were identical to ours. We found that none of these noninvasive methods can promise an accuracy of 100%. Sometimes, invasive methods should be used. The NASPGHAN guidelines recommend that a percutaneous liver biopsy should be performed in most infants with undiagnosed cholestasis.<sup>[35]</sup> The results of biopsy should be interpreted by a pathologist with expertise in pediatric liver disease. The biopsy should be done before a surgical procedure is performed to diagnose BA. If the results are equivocal and biopsy is performed for an infant below 6 weeks old, a repeated biopsy may be necessary. Liver biopsy is the most invasive method among various tests, but it is the most accurate one.

### Other important issues

#### Publication bias

We evaluated publication bias using funnel plots and several statistical methods. Funnel plots of sensitivity and specificity pooling showed considerable asymmetry, confirmed by the statistically significant Egger linear regression method. This finding indicates that publication bias could affect the results of our meta-analysis. The funnel plots of sensitivity and specificity pooling for US are shown in Figs. 4 and 5. The same evaluation was made for HBS and MRCP. The Egger linear regression for sensitivity and specificity pooling was  $P < 0.01$  for US, HBS and MRCP. To quantify possible publication bias, we used Duval and Tweedie's<sup>[49]</sup> trim and fill method, which showed less than 5% changes in sensitivity and specificity after adjusting the observed results for possible publication bias. Overall, publication bias can be concerned, especially with specificity pooling, and this can be considered a limitation of our study.

#### Quality of the included studies

Not all articles reporting those examination methods were included in this meta-analysis for their different criteria selected as the gold standard, as reviewed by Kianifar et al.<sup>[50]</sup> Some studies had non-consecutive recruitment or a narrow spectrum of studied patients. Others used a combination of tests and follow-up for final diagnosis of biliary atresia and neonatal hepatitis, they were not included for their inconsistency in the golden diagnostic tests. This can affect the accuracy of different studies and can be considered as the major limitation for our meta-analysis. All of the studies

included in our meta-analysis used the results of surgery or liver biopsy as the final diagnosis for any patients. With this universal inclusion criterion, we are sure that all studies were consistent with their gold standard tests.

The studies included in our meta-analysis calculated the accuracy of each diagnostic method on the basis of the universal standard, with a definite diagnostic method as surgery or liver biopsy. However, we admit that we didn't pay much attention to the preliminary diagnostic value of MRCP or HBS because MRCP and HBS are usually performed after ultrasonography. Taking those clinical routine manners into consideration, a further prospective comparative study is needed.

## Conclusions

US, HBS and MRCP can be used for the diagnosis of neonatal cholestasis. To improve the sensitivity and specificity, several measures can be taken.

The results of this meta-analysis showed that none of the noninvasive methods has an accuracy rate of 100%. None of noninvasive methods can be fixed for ever. Appropriate combination of different examination methods is important to make an accurate diagnosis. For example, combination of US and MRCP or HBS is a proper choice, but MRCP with HBS for the common pool specificity. While a combination of US with HBS or MRCP would complement each other and liver biopsy is sometimes necessary. Therefore, a well-coordinated multidisciplinary approach is required in the assessment of suspected cases of biliary atresia.

In this meta-analysis, we compared the accuracy of three different noninvasive diagnostic methods, without a high incidence of BA. Many studies have reported small samples in the past decade. Since few studies compared the different diagnostic methods we were first to make a meta-analysis of the three noninvasive diagnostic methods, using a huge number of samples pooled from different studies. However, further randomized controlled trials were needed to make a better understanding of those noninvasive diagnostic methods and to guide the clinical diagnosis and treatment.

## Acknowledgements

We thank Yin P for assisting in preparation of this manuscript.

**Funding:** None.

**Ethical approval:** All analyses were based on previous published studies, thus no ethical approval and patient consent are required.

**Competing interest:** All the authors declare no conflict of interest.

**Contributors:** He JP wrote the article under the supervision of

Feng JX. He JP and Feng JX mainly conceived and designed the study. He JP analyzed the data and wrote the paper. All authors read and approved the final manuscript.

## References

- 1 Poddar U, Thapa BR, Das A, Bhattacharya A, Rao KL, Singh K. Neonatal cholestasis: differentiation of biliary atresia from neonatal hepatitis in a developing country. *Acta Paediatr* 2009;98:1260-1264.
- 2 Choi SO, Park WH, Lee HJ, Woo SK. "Triangular cord": a sonographic finding applicable in the diagnosis of biliary atresia. *J Pediatr Surg* 1996;31:363-366.
- 3 Choi SO, Park WH, Lee HJ. Ultrasonographic "triangular cord": the most definitive finding for noninvasive diagnosis of extrahepatic biliary atresia. *Eur J Pediatr Surg* 1998;8:12-16.
- 4 Park WH, Choi SO, Lee HJ, Kim SP, Zeon SK, Lee SL. A new diagnostic approach to biliary atresia with emphasis on the ultrasonographic triangular cord sign: comparison of ultrasonography, hepatobiliary scintigraphy, and liver needle biopsy in the evaluation of infantile cholestasis. *J Pediatr Surg* 1997;32:1555-1559.
- 5 Park WH, Choi SO, Lee HJ. The ultrasonographic "triangular cord" coupled with gallbladder images in the diagnostic prediction of biliary atresia from infantile intrahepatic cholestasis. *J Pediatr Surg* 1999;34:1706-1710.
- 6 Lai MW, Chang MH, Hsu SC, Hsu HC, Su CT, Kao CL, et al. Differential diagnosis of extrahepatic biliary atresia from neonatal hepatitis: a prospective study. *J Pediatr Gastroenterol Nutr* 1994;18:121-127.
- 7 Tan Kendrick AP, Phua KB, Ooi BC, Subramaniam R, Tan CE, Goh AS. Making the diagnosis of biliary atresia using the triangular cord sign and gallbladder length. *Pediatr Radiol* 2000;30:69-73.
- 8 Kotb MA, Kotb A, Sheba MF, El Koofy NM, El-Karakasy HM, Abdel-Kahlik MK, et al. Evaluation of the triangular cord sign in the diagnosis of biliary atresia. *Pediatrics* 2001;108:416-420.
- 9 Kanegawa K, Akasaka Y, Kitamura E, Nishiyama S, Muraji T, Nishijima E, et al. Sonographic diagnosis of biliary atresia in pediatric patients using the "triangular cord" sign versus gallbladder length and contraction. *AJR Am J Roentgenol* 2003;181:1387-1390.
- 10 Visrutaratna P, Wongsawasdi L, Lerttumnongtum P, Singhavejsakul J, Kattipattanapong V, Ukrapol N. Triangular cord sign and ultrasound features of the gall bladder in infants with biliary atresia. *Australas Radiol* 2003;47:252-256.
- 11 Lee HJ, Lee SM, Park WH, Choi SO. Objective criteria of triangular cord sign in biliary atresia on US scans. *Radiology* 2003;229:395-400.
- 12 Dehghani SM, Haghighat M, Imanieh MH, Geramizadeh B. Comparison of different diagnostic methods in infants with Cholestasis. *World J Gastroenterol* 2006;12:5893-5896.
- 13 Takamizawa S, Zaima A, Muraji T, Kanegawa K, Akasaka Y, Satoh S, et al. Can biliary atresia be diagnosed by ultrasonography alone? *J Pediatr Surg* 2007;42:2093-2096.
- 14 Humphrey TM, Stringer MD. Biliary atresia: US diagnosis. *Radiology* 2007;244:845-851.
- 15 Yang JG, Ma DQ, Peng Y, Song L, Li CL. Comparison of different diagnostic methods for differentiating biliary atresia from idiopathic neonatal hepatitis. *Clin Imaging* 2009;33:439-446.



- 16 Lee MS, Kim MJ, Lee MJ, Yoon CS, Han SJ, Oh JT, et al. Biliary atresia: color doppler US findings in neonates and infants. *Radiology* 2009;252:282-289.
- 17 Imanieh MH, Dehghani SM, Bagheri MH, Emad V, Haghghat M, Zahmatkeshan M, et al. Triangular cord sign in detection of biliary atresia: is it a valuable sign? *Dig Dis Sci* 2010;55:172-175.
- 18 Mittal V, Saxena AK, Sodhi KS, Thapa BR, Rao KL, Das A, et al. Role of abdominal sonography in the preoperative diagnosis of extrahepatic biliary atresia in infants younger than 90 days. *AJR Am J Roentgenol* 2011;196:W438-W445.
- 19 Jiang LP, Chen YC, Ding L, Liu XL, Li KY, Huang DZ, et al. The diagnostic value of high-frequency ultrasonography in biliary atresia. *Hepatobiliary Pancreat Dis Int* 2013;12:415-422.
- 20 Majd M, Reba RC, Altman RP. Hepatobiliary scintigraphy with <sup>99m</sup>Tc-PIPIDA in the evaluation of neonatal jaundice. *Pediatrics* 1981;67:140-145.
- 21 Gerhold JP, Klingensmith WC 3rd, Kuni CC, Lilly JR, Silverman A, Fritzberg AR, et al. Diagnosis of biliary atresia with radionuclide hepatobiliary imaging. *Radiology* 1983;146:499-504.
- 22 Ang ES, Goh AS, Quak SH, Phua KB, Sundram FX. Hepatobiliary scintigraphy in the diagnosis of biliary atresia--a Singapore experience. *Ann Acad Med Singapore* 1986;15:502-506.
- 23 Spivak W, Sarkar S, Winter D, Glassman M, Donlon E, Tucker KJ. Diagnostic utility of hepatobiliary scintigraphy with <sup>99m</sup>Tc-DISIDA in neonatal cholestasis. *J Pediatr* 1987;110:855-861.
- 24 Salvatori M, Valenza V, De Franco A, De Gaetano AM. Hepatobiliary scintigraphy in the study of neonatal hepatic cholestasis. *Radiol Med* 1989;78:638-644. [In Italian]
- 25 Rosenthal P, Miller JH, Sinatra FR. Hepatobiliary scintigraphy and the string test in the evaluation of neonatal cholestasis. *J Pediatr Gastroenterol Nutr* 1989;8:292-296.
- 26 Gilmour SM, Hershkop M, Reifen R, Gilday D, Roberts EA. Outcome of hepatobiliary scanning in neonatal hepatitis syndrome. *J Nucl Med* 1997;38:1279-1282.
- 27 Lee CH, Wang PW, Lee TT, Tiao MM, Huang FC, Chuang JH, et al. The significance of functioning gallbladder visualization on hepatobiliary scintigraphy in infants with persistent jaundice. *J Nucl Med* 2000;41:1209-1213.
- 28 Liu SX, Huang ZH. The value of radionuclide hepatobiliary scintigraphy in combination with determination of bilirubin from duodenal drainage in differential diagnosis of infantile persistent jaundice. *Front Med China* 2010;4:342-345.
- 29 Shah I, Bhatnagar S, Rangarajan V, Patankar N. Utility of <sup>99m</sup>Tc-Mebrofenin hepato-biliary scintigraphy (HIDA scan) for the diagnosis of biliary atresia. *Trop Gastroenterol* 2012;33:62-64.
- 30 Norton KI, Glass RB, Kogan D, Lee JS, Emre S, Shneider BL. MR cholangiography in the evaluation of neonatal cholestasis: initial results. *Radiology* 2002;222:687-691.
- 31 Han SJ, Kim MJ, Han A, Chung KS, Yoon CS, Kim D. Magnetic resonance cholangiography for the diagnosis of biliary atresia. *J Pediatr Surg* 2002;37:599-604.
- 32 Ryeom HK, Choe BH, Kim JY, Kwon S, Ko CW, Kim HM, et al. Biliary atresia: feasibility of mangafodipir trisodium-enhanced MR cholangiography for evaluation. *Radiology* 2005;235:250-258.
- 33 Huang CT, Lee HC, Chen WT, Jiang CB, Shih SL, Yeung CY. Usefulness of magnetic resonance cholangiopancreatography in pancreatobiliary abnormalities in pediatric patients. *Pediatr Neonatol* 2011;52:332-336.
- 34 Liu B, Cai J, Xu Y, Peng X, Zheng H, Huang K, et al. Three-dimensional magnetic resonance cholangiopancreatography for the diagnosis of biliary atresia in infants and neonates. *PLoS One* 2014;9:e88268.
- 35 Moyer V, Freese DK, Whittington PF, Olson AD, Brewer F, Colletti RB, et al. Guideline for the evaluation of cholestatic jaundice in infants: recommendations of the North American Society for Pediatric Gastroenterology, Hepatology and Nutrition. *J Pediatr Gastroenterol Nutr* 2004;39:115-128.
- 36 Winfield CR, MacFaul R. Clinical study of prolonged jaundice in breast- and bottle-fed babies. *Arch Dis Child* 1978;53:506-507.
- 37 Kelly DA, Stanton A. Jaundice in babies: implications for community screening for biliary atresia. *BMJ* 1995;310:1172-1173.
- 38 el-Youssef M, Whittington PF. Diagnostic approach to the child with hepatobiliary disease. *Semin Liver Dis* 1998;18:195-202.
- 39 Sevilla A, Howman-Giles R, Saleh H, Trpezanovski J, Concannon R, Williams K, et al. Hepatobiliary scintigraphy with SPECT in infancy. *Clin Nucl Med* 2007;32:16-23.
- 40 Fitoz S, Erden A, Boruban S. Magnetic resonance cholangiopancreatography of biliary system abnormalities in children. *Clin Imaging* 2007;31:93-101.
- 41 François E, Devière J. Endoscopic retrograde cholangiopancreatography. *Endoscopy* 2002;34:882-887.
- 42 Missavage AE, Sugawa C. Caroli's disease: role of endoscopic retrograde cholangiopancreatography. *Am J Gastroenterol* 1983;78:815-817.
- 43 Metreweli C, So NM, Chu WC, Lam WW. Magnetic resonance cholangiography in children. *Br J Radiol* 2004;77:1059-1064.
- 44 Hall-Craggs MA, Allen CM, Owens CM, Theis BA, Donald JJ, Paley M, et al. MR cholangiography: clinical evaluation in 40 cases. *Radiology* 1993;189:423-427.
- 45 Wallner BK, Schumacher KA, Weidenmaier W, Friedrich JM. Dilated biliary tract: evaluation with MR cholangiography with a T2-weighted contrast-enhanced fast sequence. *Radiology* 1991;181:805-808.
- 46 Silva MA, Munasinghe SH, Munasinghe D, Deen KI. Magnetic resonance cholangio-pancreatography (MRCP). *Surgery (Oxford)* 2002;20:120b-120e.
- 47 Griffin N, Wastle ML, Dunn WK, Ryder SD, Beckingham IJ. Magnetic resonance cholangiopancreatography versus endoscopic retrograde cholangiopancreatography in the diagnosis of choledocholithiasis. *Eur J Gastroenterol Hepatol* 2003;15:809-813.
- 48 Park DH, Kim MH, Lee SS, Lee SK, Kim KP, Han JM, et al. Accuracy of magnetic resonance cholangiopancreatography for locating hepatolithiasis and detecting accompanying biliary strictures. *Endoscopy* 2004;36:987-992.
- 49 Duval S, Tweedie R. Trim and fill: a simple funnel-plot-based method of testing and adjusting for publication bias in meta-analysis. *Biometrics* 2000;56:455-463.
- 50 Kianifar HR, Tehranian S, Shojaei P, Adinehpour Z, Sadeghi R, Kakhki VR, et al. Accuracy of hepatobiliary scintigraphy for differentiation of neonatal hepatitis from biliary atresia: systematic review and meta-analysis of the literature. *Pediatr Radiol* 2013;43:905-919.

Received June 4, 2014

Accepted after revision September 2, 2014