

# Expression and clinical significance of heparanase in neuroblastoma

Li-Duan Zheng, Qiang-Song Tong, Shao-Tao Tang, Zhi-Yong Du, Yuan Liu, Guo-Song Jiang, Jia-Bin Cai

Wuhan, China

**Background:** Previous studies indicate that heparanase (HPA), an endoglycosidase involved in tumor angiogenesis and metastasis, is up-regulated in a variety of malignancies. However, the expression of HPA in neuroblastoma (NB), one of the most common extra cranial solid tumors in children, remains unknown. This study was undertaken to explore the expression and clinical significance of HPA in NB.

**Methods:** Immunohistochemical staining was applied to detect the expression of HPA in 42 cases of NB. The relationships among HPA expression, international neuroblastoma staging system (INSS) stages, histopathological classification, and postoperative survival of the NB patients were analyzed.

**Results:** The expression rate of HPA in NB was 61.9% (26/42), mainly in the cytoplasm of neuroblastoma cells. The expression rates of stage 1-2, stage 3-4 and stage 4S were 35.7%, 80.0% and 62.5%, respectively. The differences between stage 1-2 and stage 3-4 were significant ( $P<0.01$ ). The expression of HPA was significantly higher in the NB cases that had one of the histopathological factors: age more than 1 year ( $P<0.01$ ), poorer differentiation ( $P<0.01$ ), and higher mitosis karyorrhexis index ( $P<0.01$ ). The survival time of HPA-negative patients was significantly longer than that of HPA-positive patients ( $P<0.05$ ).

**Conclusion:** Although these results indicate that heparanase might be correlated with development and progression of NB, a larger series of patients with a

longer follow-up are probably needed to strengthen its role in assessment of NB prognosis.

*World J Pediatr* 2009;5(3):206-210

**Key words:** heparanase; neuroblastoma; risk; survival

## Introduction

Neuroblastoma (NB) is one of the most common malignant tumors in children, and is responsible for about 15% of all pediatric cancer deaths.<sup>[1]</sup> Spontaneous regressions and differentiation *in vivo* are common in infants with early-stage tumors, whereas children who are over 1 year of age at clinical presentation often have metastatic disease that fails to respond to medical intervention.<sup>[2]</sup> Little is known about the factors leading to systemic spread and metastasis of NB. A series of studies have indicated that heparanase (HPA), an endoglycosidase, promotes tumor metastasis by degrading heparan sulfate proteoglycans (HSPG) in the extracellular matrix and basement membrane, allowing tumor cells to spread.<sup>[3,4]</sup> The expression of HPA is found to be correlated with the metastatic potential of tumor cells, and is up-regulated in a variety of malignancies.<sup>[5]</sup> However, the expression of HPA in NB remains obscure. In this research, we examined the correlation of the expression of HPA in NB with the tumor stage using the international neuroblastoma staging system (INSS) and pathological classification based on the Shimada classification system. We also investigated the risk effects of HPA expression, INSS stages, pathological classification on postoperative survival of NB patients.

## Methods

### Tissue samples

Tissue samples were obtained from 42 NB patients

**Author Affiliations:** Department of Pathology (Zheng LD) and Department of Pediatric Surgery (Tong QS, Tang ST, Du ZY, Liu Y, Jiang GS, Cai JB), Union Hospital of Tongji Medical College, Huazhong University of Science and Technology, Wuhan 430022, China

**Corresponding Author:** Qiang-Song Tong, PhD, MD, Department of Pediatric Surgery, Union Hospital of Tongji Medical College, Huazhong University of Science and Technology, Wuhan 430022, China (Tel: 86-27-63776478; Email: qs\_tong@hotmail.com)

doi:10.1007/s12519-009-0039-9

©2009, World J Pediatr. All rights reserved.

undergoing surgery during 1997-2007 in the Union Hospital of Tongji Medical College, Huazhong University of Science and Technology in Wuhan, China. The diagnosis of NB was confirmed by at least two pathologists independently. Patients with ganglioneuroma or ganglioneuroblastoma were excluded from this study. Eleven patients were subjected to complete resection, 12 to partial resection, and the remaining 19 to biopsies. Twenty-two tumors were from the adrenal gland, 13 from retroperitoneum and the remaining 7 from mediastinum. The age of patients ranged from 4 months to 8 years, with an average of 2 years and 6 months. Twenty-six were boys and 16 girls with a male to female ratio of 1.6:1. According to the INSS, 7 patients were classified as stage 1, 7 stage 2, 9 stage 3, 11 stage 4, and 8 stage 4S. Based on the Shimada classification system,<sup>[6]</sup> the mitosis karyorrhexis index (MKI), degree of neuroblastic differentiation, and stromal maturation combined with patient age, 19 patients were classified as favorable histology (FH) and 23 unfavorable histology (UFH). Histologically, 6, 28, and 8 patients were classified as undifferentiated, poorly differentiated, and differentiated types, respectively. Twenty-eight NB patients were followed up for 6 months to 5 years with complete follow-up information. The survival time was defined as the time from the day of surgery to the last day of follow-up or the day of relapse, metastasis or death.

### Immunohistochemical staining

Tissue samples were fixed with 10% formalin, embedded in paraffin and then cut into 4-5  $\mu\text{m}$  thick sections. The streptavidin-peroxidase-biotin (SP) immunohistochemical method was applied to detect the expression of HPA. The sections were deparaffinized, hydrated and underwent antigen retrieval using the bathing method. When citric acid buffer (pH 6.0) was heated up to 95°C-99°C. The sections were bathed in the buffer for 30 minutes and then cooled at room temperature for 20 minutes. Then the sections were taken out and washed with phosphate buffered saline (PBS). The 3%  $\text{H}_2\text{O}_2$  was used to block intrinsic peroxidase activities. After incubation with normal serum, tissue sections were soaked with murine monoclonal anti-human HPA antibody (InSight Company, Rehovot, Israel) at 4°C overnight; the second antibody was from SP reagent kit (Zhongshan Biotechnology Company, Beijing, China). Stained with diaminobenzidine (DAB), the sections were counterstained with hematoxylin. Negative controls included parallel sections treated with mouse serum (an isotype control) or PBS solution, but not with primary antibody.

### Heparanase staining index

Under a light microscope, HPA positive immunohistochemical staining reaction presented brown cytoplasmic granules. Five to ten high microscope fields were randomly selected to calculate the numbers of positively staining cells in 1000 tumor cells, and a positive index (PI) = (number of positive staining cells/1000)  $\times$  100% was obtained. Tissue was considered negative (-) if less than 5% of the cells were positive; weakly positive (+) if 6%-25% of the cells were positive; moderately positive (++) if 26%-50% of the cells were positive; and strongly positive (+++) if more than 50% of the cells were positive.

### Statistical analysis

The SPSS 12.0 statistical software was used to analyze the results. The Chi-square test and Fisher's exact test were used for comparison. The Mann-Whitney *U* test and the Kruskal-Wallis test were used to compare the graded staining intensities. The Kaplan-Meier method and log-rank test were used for survival analysis.  $P < 0.05$  was considered statistically significant.

## Results

### Expression of HPA in NB tissues

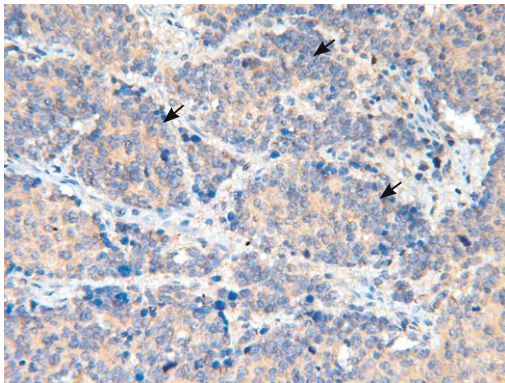
HPA was detected in 26 (61.9%) of the 42 patients and the staining was weak (+) in 6, moderate (++) in 8, and strong (+++) in 12. As shown in Figs. 1, 2, HPA was mainly expressed in the cytoplasm of tumor cells within the neuroblastic nests. HPA was also expressed in some ganglionic differentiated tumor cells. No nuclear localization of HPA was noted in the NB specimens examined. There was no immunostaining of HPA within the fibrillary stroma of the tumors.

### Correlation between expression of HPA and INSS stages of NB

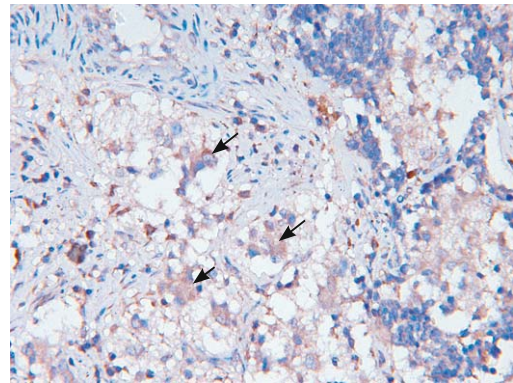
There was 35.7% (5/14) disperse or local heparanase expression in NB samples of stages 1-2, 80.0% (16/20) in NB samples of stage 3-4, and 62.5% (5/8) in stage 4S. The differences of HPA expression between stage 1-2 and stage 3-4 were significant ( $P < 0.01$ ) (Table 1).

### Correlation between HPA expression and histopathological types of NB

The relations between each of the known histopathological factors and the expression of HPA are shown in Table 2. The expression of HPA was significantly higher in the NB patients who had one of the factors: age more than 1 year ( $P < 0.01$ ), poorer differentiation ( $P < 0.01$ ), and higher MKI ( $P < 0.01$ ).



**Fig 1.** Expression of heparanase in the cytoplasm of tumor cells within the neuroblastic nests of neuroblastoma tissues (DAB staining, original magnification  $\times 200$ ).



**Fig 2.** Expression of heparanase in some ganglionic differentiated tumor cells of neuroblastoma tissues (DAB staining, original magnification  $\times 200$ ).

**Table 1.** Expression of heparanase in different INSS stages of neuroblastoma

INSS stages	n	Expression of heparanase				Positive rates (%)
		-	+	++	+++	
Stages 1-2	14	9	3	2	0	35.7
Stages 3-4	20	4	1	4	11	80.0*
Stage 4S	8	3	2	2	1	62.5**

\*:  $P < 0.01$ , compared with stages 1-2; †:  $P > 0.05$ , compared with stages 1-2; ‡:  $P > 0.05$ , compared with stages 3-4.

**Table 2.** Correlation of heparanase expression with age and histological types of neuroblastoma

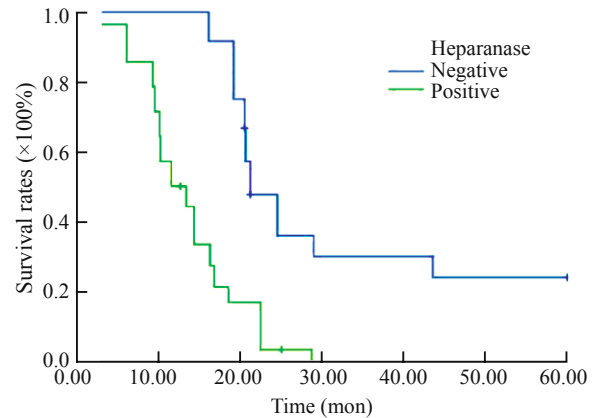
Factors	n	Expression of heparanase				Positive rates (%)	P value
		-	+	++	+++		
<b>Age</b>							
<1 year	20	12	1	3	4	40.0	<0.01
$\geq 1$ year	22	4	5	5	8	81.8	
<b>Differentiation</b>							
Undifferentiated	6	0	1	2	3	100.0	
Poorly differentiated	28	9	4	6	9	67.9	>0.05*
Differentiated	8	7	1	0	0	12.5	<0.01**
<b>MKI</b>							
<200	17	13	2	1	1	23.5	<0.01
>200	25	3	4	7	11	88.0	

\*: compared with undifferentiated; †: compared with poorly differentiated. MKI: mitosis karyorrhexis index.

**Table 3.** The relation among survival time, INSS stages, histopathological types and heparanase expression of neuroblastoma

Variables	n	Median survival time (mon)	P value
<b>INSS stages</b>			
Stages 1-2	12	25.2	
Stages 3-4	10	14.6	<0.05*
Stage 4S	6	21.2	<0.05†
<b>Shimada's classification</b>			
Favorable	16	24.3	
Unfavorable	12	15.6	<0.05
<b>Heparanase expression</b>			
Negative	11	23.4	
Weak	6	18.1	<0.05‡
Moderate	5	16.2	<0.05§
Strong	6	12.2	<0.05§§

\*: compared with stages 1-2; †: compared with stages 3-4; ‡: compared with negative; §: compared with weak.



**Fig 3.** Survival curve of neuroblastoma patients with different heparanase expression.

**Correlation between HPA expression and postoperative survival time of NB**

Twenty-eight NB patients were followed up. The information obtained from these patients indicated that the median survival time was significantly correlated with INSS stages, histopathological types, and degree of HPA positivity (Table 3). As shown in Fig. 3, the median survival time of HPA-negative patients (23.4 months) was longer than that of HPA-positive patients (14.2 months,  $P < 0.05$ ).

**Discussion**

Neuroblastoma is the most common extra cranial malignant solid tumor in children. Although the mechanisms that control the cellular differentiation, proliferation, and apoptosis of NB have been considerably clarified at the molecular biological levels, the clinical outcome in the advanced disease is not improved significantly.<sup>[7]</sup> Varied outcomes in NB patients, even in the same staging category, indicate

a need for better understanding of the basic biology of NB in an attempt to define relevant targets and to develop novel therapeutic approaches.<sup>[7]</sup>

By catalyzing the cleavage of HSPG, HPA disrupts extracellular matrix and basement membranes, and thus promotes tumor invasion and metastasis.<sup>[8]</sup> Recently, HPA up-regulation has been documented in an increasing number of primary human tumors such as bladder, gastric, cervical and colorectal cancer.<sup>[9-12]</sup> Similarly, HPA up-regulation is found to be correlated with increased lymph node and distant metastasis, showing a clinical support for the pro-metastatic property of HPA.<sup>[10,13,14]</sup> In addition, HPA plays an important role in tumor angiogenesis by releasing growth factors such as fibroblast growth factor and vascular endothelial cell growth factor stored in the extracellular matrix<sup>[15]</sup> and by inducing the expression of vascular endothelial cell growth factor and cyclooxygenase-2.<sup>[16,17]</sup> Since these evidences indicate that HPA plays important roles in tumor development and progression, we hypothesize that HPA might contribute to the clinicopathological characteristics of NB patients.

In the current study, we examined the HPA expression in specimens from 42 NB patients. HPA expression was noted in 61.9% of these patients which was in agreement with previously reported HPA expression in several other human malignancies.<sup>[10,13,14]</sup> According to the classification of Pediatric Oncology Group for NB,<sup>[18]</sup> stage 1-2 patients commonly have low risks of death, while stage 3-4 patients have intermediate or high risk; the risk of death for stage 4S patients may be low, intermediate or high. We compared the HPA expression within different risk groups (stage 1-2, stage 3-4 and stage 4S) of NB. Clearly, HPA expression correlated with INSS stages, histopathological features, and postoperative survival time of NB patients. These findings were consistent with what found in other human cancers with enhanced metastatic spread and reduced postoperative survival noted for HPA over-expressing patients,<sup>[10,13,14]</sup> which clinically support the pro-metastatic function of HPA. For one stage 4S patient with tumor metastasis to the liver, strong HPA expression was observed. We suspect that the strong HPA expression may attribute to the metastasis of tumor to the liver. However, further studies are needed to explore the exact role of HPA in the liver metastasis of NB. In this study, HPA exhibited a mostly cytoplasmic localization. No nuclear localization of HPA in the NB specimens was shown to correlate with cellular differentiation.<sup>[19]</sup> Our results suggest that HPA expression may be useful as a prognostic marker for NB patients. Because of the limited number of patients and duration of the follow-

up, however, a larger series of patients with a long-term follow-up are needed to prove this conclusion.

For patients with HPA-positive tumors, new targeted therapies are worth pursuing. Inhibitors of HPA like non-anticoagulant heparins, and specific HPA-neutralizing antibodies show promising results in *in vitro* and *in vivo* studies of cancer therapy.<sup>[20]</sup> HPA inhibitors such as phosphomannopentaose sulfate (PI-88), laminarin sulfate, and 4-alkyl-RK-486, which have been confirmed to inhibit tumor cell invasion *in vitro* and metastasis in animal tumor xenograft models,<sup>[21,22]</sup> can be developed as novel therapeutic agents to treat cancers. We suppose that HPA may also serve as a target for the therapy of NB, which warrants our further investigation. Taken together, our results suggest that HPA is expressed in NB and correlates with poor outcome, which may therefore be considered as a target for the development of anticancer drugs for advanced stage NB.

**Funding:** This work was supported by grants from the National Natural Science Foundation of China (No. 30200284, No. 30600278 and No. 30772359), the Program for New Century Excellent Talents in University (NCET-06-0641), and Scientific Research Foundation for Returned Overseas Chinese Scholars (2008-889).

**Ethical approval:** This study was approved by the Data Inspectorate of China and by the Ethical Committee of Tongji Medical College, Huazhong University of Science and Technology, China.

**Competing interest:** No benefits in any form have been received or will be received from a commercial party related directly or indirectly to the subject of this article.

**Contributors:** Zheng LD and Tong QS contributed equally to this work. Tong QS proposed the study and wrote the draft. Zheng LD analyzed the data. All authors contributed to the interpretation of this study and to further drafts. Tong QS is the guarantor.

## References

- 1 Tong QS, Zheng LD, Tang ST, Ruan QL, Liu Y, Li SW, et al. Expression and clinical significance of stem cell marker CD133 in human neuroblastoma. *World J Pediatr* 2008;4:58-62.
- 2 Pritchard J, Hickman JA. Why does stage 4s neuroblastoma regress spontaneously? *Lancet* 1994;344:869-870.
- 3 Cohen I, Pappo O, Elkin M, San T, Bar-Shavit R, Hazan R, et al. Heparanase promotes growth, angiogenesis and survival of primary breast tumors. *Int J Cancer* 2006;118:1609-1617.
- 4 Edovitsky E, Elkin M, Zcharia E, Peretz T, Vlodavsky I. Heparanase gene silencing, tumor invasiveness, angiogenesis, and metastasis. *J Natl Cancer Inst* 2004;96:1219-1230.
- 5 Ilan N, Elkin M, Vlodavsky I. Regulation, function and clinical significance of heparanase in cancer metastasis and angiogenesis. *Int J Biochem Cell Biol* 2006;38:2018-2039.
- 6 Shimada H, Ambros IM, Dehner LP, Hata J, Joshi VV, Roald B, et al. The International Neuroblastoma Pathology Classification (the Shimada system). *Cancer* 1999;86:364-372.

- 7 Kaneko M, Tsuchida Y, Uchino J, Takeda T, Iwafuchi M, Ohnuma N, et al. Treatment results of advanced neuroblastoma with the first Japanese study group protocol. Study Group of Japan for Treatment of Advanced Neuroblastoma. *J Pediatr Hematol Oncol* 1999;21:190-197.
- 8 Vlodavsky I, Friedmann Y, Elkin M, Aingorn H, Atzmon R, Ishai-Michaeli R, et al. Mammalian heparanase: gene cloning, expression and function in tumor progression and metastasis. *Nat Med* 1999;5:793-802.
- 9 Gohji K, Hirano H, Okamoto M, Kitazawa S, Toyoshima M, Dong J, et al. Expression of three extracellular matrix degradative enzymes in bladder cancer. *Int J Cancer* 2001;95:295-301.
- 10 Takaoka M, Naomoto Y, Ohkawa T, Uetsuka H, Shirakawa Y, Uno F, et al. Heparanase expression correlates with invasion and poor prognosis in gastric cancers. *Lab Invest* 2003;83:613-622.
- 11 Shinyo Y, Kodama J, Hongo A, Yoshinouchi M, Hiramatsu Y. Heparanase expression is an independent prognostic factor in patients with invasive cervical cancer. *Ann Oncol* 2003;14:1505-1510.
- 12 Nobuhisa T, Naomoto Y, Ohkawa T, Takaoka M, Ono R, Murata T, et al. Heparanase expression correlates with malignant potential in human colon cancer. *J Cancer Res Clin Oncol* 2005;131:229-237.
- 13 Rohloff J, Zinke J, Schoppmeyer K, Tannapfel A, Witzigmann H, Mössner J, et al. Heparanase expression is a prognostic indicator for postoperative survival in pancreatic adenocarcinoma. *Br J Cancer* 2002;86:1270-1275.
- 14 Sato T, Yamaguchi A, Goi T, Hirono Y, Takeuchi K, Katayama K, et al. Heparanase expression in human colorectal cancer and its relationship to tumor angiogenesis, hematogenous metastasis, and prognosis. *J Surg Oncol* 2004;87:174-181.
- 15 Mikami S, Ohashi K, Katsube K, Nemoto T, Nakajima M, Okada Y. Coexpression of heparanase, basic fibroblast growth factor and vascular endothelial growth factor in human esophageal carcinomas. *Pathol Int* 2004;54:556-563.
- 16 Zetser A, Bashenko Y, Edovitsky E, Levy-Adam F, Vlodavsky I, Ilan N. Heparanase induces vascular endothelial growth factor expression: correlation with p38 phosphorylation levels and Src activation. *Cancer Res* 2006;66:1455-1463.
- 17 Okawa T, Naomoto Y, Nobuhisa T, Takaoka M, Motoki T, Shirakawa Y, et al. Heparanase is involved in angiogenesis in esophageal cancer through induction of cyclooxygenase-2. *Clin Cancer Res* 2005;11:7995-8005.
- 18 Weinstein JL, Katzenstein HM, Cohn SL. Advances in the diagnosis and treatment of neuroblastoma. *Oncologist* 2003;8:278-292.
- 19 Nobuhisa T, Naomoto Y, Okawa T, Takaoka M, Gunduz M, Motoki T, et al. Translocation of heparanase into nucleus results in cell differentiation. *Cancer Sci* 2007;98:535-540.
- 20 He X, Brenchley PE, Jayson GC, Hampson L, Davies J, Hampson IN. Hypoxia increases heparanase-dependent tumor cell invasion, which can be inhibited by antiheparanase antibodies. *Cancer Res* 2004;64:3928-3933.
- 21 Ishida K, Hirai G, Murakami K, Teruya T, Simizu S, Sodeoka M, et al. Structure-based design of a selective heparanase inhibitor as an antimetastatic agent. *Mol Cancer Ther* 2004;3:1069-1077.
- 22 Miao HQ, Elkin M, Aingorn E, Ishai-Michaeli R, Stein CA, Vlodavsky I. Inhibition of heparanase activity and tumor metastasis by laminarin sulfate and synthetic phosphorothioate oligodeoxynucleotides. *Int J Cancer* 1999;83:424-431.

Received June 10, 2008

Accepted after revision February 16, 2009