

EEG and MRI findings and their relation with intellectual disability in pervasive developmental disorders

Özlem Ünal, Özlem Özcan, Özgür Öner, Melda Akcakin, Ayla Aysev, Gülhis Deda

Ankara, Turkey

Background: The diagnostic category pervasive developmental disorders (PDDs) refer to a group of five disorders: autism, Rett syndrome, childhood disintegrative disorder, Asperger syndrome, and pervasive developmental disorder not otherwise specified (PDD-NOS). EEG abnormalities and seizures are considered much frequent in autistic subjects with comorbid intellectual disability (ID). In this study, we aimed to evaluate the EEG and MRI findings and their relation with ID in pervasive developmental disorder.

Methods: A retrospective, cross-sectional and non-experimental study was performed. Subjects included 81 patients diagnosed with autism or PDD-NOS according to the DSM-IV criteria. The age range of the patients was 2-15 years (mean 6.6 years, SD 3.0). Among them, 21 (25.9%) were girls and 60 boys (74.1%).

Results: Patients with severe ID had a higher rate of EEG abnormalities ($P=0.03$) than patients without ID as well as patients with mild or moderate ID. The association remained significant after the structural MRI abnormalities were controlled ($P=0.04$). The severity of ID was not associated with abnormal MRI. The most frequent EEG and MRI abnormalities were active epileptic anomaly/paroxysmal abnormality and cerebral atrophy/periventricular leukomalacia, respectively. Almost a third of the EEG abnormalities were associated

with temporal cortex and adjacent cortical structures.

Conclusions: Consistent with previous studies, almost a fourth of the patients in this relatively large sample of patients with pervasive developmental disorders had EEG and/or MRI abnormalities. EEG results indicate that temporal cortex may play a significant role in pervasive developmental disorders.

World J Pediatr 2009;5(3):196-200

Key words: autism; electroencephalography; magnetic resonance imaging; pervasive developmental disorders

Introduction

The diagnostic category pervasive developmental disorders (PDDs) refer to a group of five disorders characterized by delays in the development of multiple basic functions including socialization and communication. PDDs are autism, Rett syndrome, childhood disintegrative disorder, Asperger syndrome, and pervasive developmental disorder not otherwise specified (PDD-NOS), which includes atypical autism. Autism is frequently associated with intellectual disability (ID), electroencephalogram (EEG) abnormalities and seizures. Previous studies indicate that EEG abnormalities and seizures are much frequent in autistic subjects with comorbid ID.^[1] The most frequent types of seizures include generalized tonic-clonic, atypical absence, complex partial and myoclonic seizures.^[2] Seizures in autistic subjects show two peaks during development, one before 5 years of age and the other after 10 years.^[1] Almost 15%-20% of autistic patients without epilepsy show EEG paroxysmal abnormalities.^[3,4] The clinical importance of epileptiform discharges without overt seizures is not clear, but they may cause behavioral and cognitive problems.^[5,6] Epileptiform EEG recordings in other childhood neuropsychiatric disorders, like attention deficit/hyperactivity disorder, may also be increased

Author Affiliations: Department of Developmental and Behavioral Pediatrics, Ankara University School of Medicine (Ünal Ö); Inonu University School of Medicine (Özcan Ö); NIMH Fogarty International Mental Health and Developmental Disabilities Program (Öner Ö); Department of Child Psychiatry, Ankara University School of Medicine (Akcakin M, Aysev A); Department of Child Neurology, Ankara University School of Medicine (Deda G)

Corresponding Author: Özlem Ünal, Department of Developmental and Behavioral Pediatrics, Ankara University School of Medicine, 06100 Cebeci/Ankara, Turkey (Tel: +90 542 251 88 00; Fax: +90 312 319 14 40; Email: unalozlem@gmail.com)

doi:10.1007/s12519-009-0037-y

©2009, World J Pediatr. All rights reserved.

(6.1%) when compared with normal school age children (3.5%).^[7] Cumulative risk for epilepsy in patients with ID by 15 years of age was 13%, largely depending on the presence of associated disabilities, like cerebral palsy.^[8] In the absence of associated disabilities and postnatal injury, the risk was much lower (3.9%). However, the rate of epilepsy in severe ID was reported to be over 60%.^[9] Another study reported that while the risk of developing epilepsy was 7% in children with mild ID, it was 35% in severe ID.^[10]

Magnetic resonance imaging (MRI) is a frequently used research tool in autism that yields valuable clinical data. Former studies indicate that MRI abnormalities may occur in 25%-45% of autistic subjects, depending on the nature of the subjects (e.g., presence of macrocrania);^[11,12] however, these abnormalities do not always warrant treatment.^[11]

Patients who have problems in social interaction, communication and repetitive behavior pattern but unable to fulfill the necessary criteria for a diagnosis of autism may be diagnosed as having PDD-NOS.^[13] This disorder may be much more prevalent than classic autism. A recent study indicated that EEG and MRI abnormalities can be as frequent (almost 25%) in patients with PDD-NOS as in those with autism.^[11] This study aimed to evaluate EEG and MRI findings and their relation with intellectual disability in pervasive developmental disorders.

Methods

We studied 81 patients with autism or PDD-NOS diagnosed according to the DSM-IV criteria. All the patients were Caucasian children and adolescents recruited from consecutive admissions to a general outpatient clinic in the child psychiatry department of Ankara University School of Medicine. Patients who were diagnosed with neurological or medical conditions were excluded. The age range of the studied patients was 2-15 years (mean 6.6 years, SD 3.0). Among them, 21 (25.9%) were girls and 60 boys (74.1%).

The diagnoses were made by two experienced child psychiatrist and psychologist (Ozgur Oner and Melda Akcakin). All patients fulfilled the DSM-IV criteria for autism or PDD-NOS. The patients varied from severely retarded patients without speech to milder ones with prominent social problems but with better development in other areas. In fact, this was consistent with our objective to reflect the clinical picture. Thus, our sample was heterogeneous.

EEG investigations were recorded according to the 10-20 system. The recordings were interpreted by the same pediatric neurologist. Since all patients were in the

autistic spectrum and most of them were intellectually disabled, EEG was performed during sleep, during a monitoring time of 1 hour. Unless the sleep was spontaneous, we used hydroxyzine 10-20 mg per dose. For every patient we collected data about MRI findings with standard 1.5 Tesla equipment.

All patients had an IQ evaluation with one of the following measures: Stanford-Binet Intelligence Scale, Weschler Intelligence Scale for Patients-Revised (WISC-R), or the Ankara Developmental Screening Inventory (ADSI). The ADSI is a 154-item inventory developed for children of Turkish culture. It was used to evaluate the present development and capacity of infants and children at the age of 0-6 years or older children who had equivalent mental development and the total score was used to assess the developmental level of the patients. Clearly, the ADSI has a high internal consistency (Cronbach alpha for different age groups: 0.88-0.98) and test-retest reliability ($r=0.88-0.99$ for different age groups).^[14] A recent study showed that the ADSI shows a close correlation ($r=0.95$) with the Vineland Adaptive Behavior Checklist.^[15]

ID severity was grouped into four categories: average, mild, moderate, and severe disability. For WISC-R and Stanford-Binet tests, the groups were: Non-ID (IQ>70), mild ID (IQ 50-69), moderate ID (IQ 35-49), and severe ID (IQ<35). For the ADSI, the groups were: non-ID (total score above 20% of the population average), mild ID (total score above 20% but below 30% of the population average), moderate ID (total score slightly below 30% of the population average), and severe ID (total score much below the population average).

Information about obstetric complications was also obtained from the parents by a semi-structured interview, which included questions about hypoxic birth injury, birth weight, parental health and drug usage during pregnancy, and history of delivery. All the problems were recorded into a single dichotic variable reflecting obstetric complications. Fifteen patients had such complications.

We used the Chi-square test and Fisher's exact test and student's *t* tests to evaluate group differences. Two-tailed *P* values are used for each test and *P* values <0.05 were considered statistically significant.

Results

EEG was performed in all patients, and 22 (27.2%) of the 81 patients had abnormal EEG recordings. The most frequent abnormalities were active epileptic and paroxysmal abnormalities, which were focal in most of the patients: 4 patients had right temporal-

centrotemporal-temporoparietal abnormalities; 4 had left temporal-centrotemporal-temporoparietal abnormalities; and 2 had bitemporal and 2 had frontal abnormalities. The other EEG findings are summarized in Table 1. Three patients had background abnormalities and voltage suppression, which might suggest encephalopathy. The patients with severe ID had a significantly higher rate of EEG abnormalities; while 8.3% of non-ID patients had abnormal EEG results, 23.1%, 16.7%, and 50.0% of mild, moderate and severe ID patients had EEG abnormalities, respectively ($\chi^2=8.5$, $P=0.03$) (Fig., Table 2).

MRI abnormalities were detected in 10 (12.3%) of the patients. The most frequent MRI abnormalities were mild cortical atrophy and bilateral periventricular leukomalacia. There were no statistically significant

differences in the frequency of MRI abnormalities among the ID groups ($\chi^2=3.10$, $P=0.377$). While 16.7% ($n=2$) of non-ID patients had abnormal MRI scans, no patients with mild ID had abnormal MRI ($n=0$), and 20.0% ($n=6$) of moderate and 12.5% ($n=2$) of severe ID patients had abnormal MRI scans. The percent of abnormal MRI findings are summarized in Table 2.

When the MRI abnormalities of patients with and without EEG abnormalities were compared, the patients with abnormal EEG were not found to have significantly more MRI abnormalities ($\chi^2=0.355$, $P=0.55$). When the patients with abnormal MRI were excluded, the rates of EEG abnormalities (25.5%) and distribution among the IQ groups were almost the same: while 7.1% of the non-ID patients had abnormal EEGs, 19.0%, 14.3%, and 50.0% of mild, moderate and severe ID patients had EEG abnormalities, respectively ($\chi^2=8.2$, $P=0.04$). The patients with a history of obstetric complications had no significantly higher EEG ($\chi^2=0.069$, $P=0.80$) or MRI abnormalities ($\chi^2=0.891$, $P=0.35$). History of obstetric complications was not significantly related to MRI abnormalities ($\chi^2=1.28$, $P=0.53$); however the sample size for this comparison was very small. Patients with EEG abnormalities were significantly older than those without EEG abnormalities (7.6 ± 2.4 years vs 6.2 ± 3.1 years; $P=0.034$). That was not the case for MRI abnormalities ($P>0.47$).

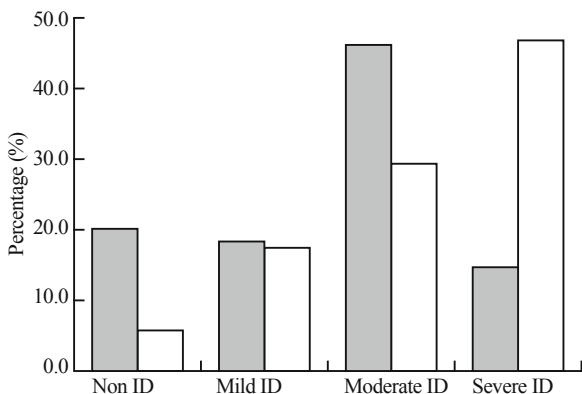


Fig. Percentage of autism and PDD-NOS patients with EEG abnormalities related to intellectual disability (ID) severity.

Table 1. EEG findings in patients with autism and PDD-NOS

Brain regions of EEG abnormality	Number
Left temporal-centrotemporal-parietotemporal	4
Right temporal-centrotemporal-parietotemporal	4
Bitemporal	2
Frontal	2
Disseminated	2
Right hemisphere	1
Central	3
Left hemisphere	1
Voltage suppression and background abnormality	3

Table 2. Percentage of abnormal EEG and MRI findings in patients with different severity of intellectual disability (ID)

Groups	EEG (% abnormal)	MRI (% abnormal)
Whole group	27.2	12.3
Non ID	8.3	16.7
Mild ID	23.1	0.0
Moderate ID	16.7	20.0
Severe ID	50.0	12.5

Discussion

There are three main findings in the present study. First, 27.2% of the patients had abnormal EEG recordings and 12.3% had abnormal MRI scans. This result supports the importance of EEG and MRI evaluations in this population. However, Kawasaki et al^[16] reported higher rates (up to 60%) of EEG abnormalities in autistic subjects. The lower levels of EEG abnormalities in our study might be due to the younger age of the sample (aged 6 or younger, 53.1%). It is known that seizures are more prevalent in adolescents and young adult patients.^[6] In fact, patients with EEG abnormalities were significantly older in our study. Besides, over 60% of patients in the study by Kawasaki et al^[16] had severe mental retardation, but only 25% of our patients were severely intellectually disabled. We did not find any association between MRI abnormalities and the severity of ID. This might be due to the low power of the study with small sample size.

We found the relation of abnormal EEG recordings with ID. Approximately half of the patients with severe ID had EEG abnormalities, but only 8.3% of the non-ID patients had EEG abnormalities. This finding is consistent with that of previous studies.^[1,17] Therefore

non-ID subjects with pervasive developmental disorders might have more preserved neural functions. As shown in Fig., mild and moderate ID patients had higher rates of EEG abnormalities than non-ID patients, but severe ID patients had a higher rate of EEG abnormality than milder ID patients, suggesting that the association of EEG abnormalities with ID could be "severity-dependent". This is also consistent with previous studies which have shown that the risk of epilepsy increases significantly in patients with severe ID.^[10] Thus, the frequency of abnormal EEG in PDD patients may be attributable to ID status, as in individuals without PDD.

Our results suggest that consistent with previous literature, patients with PDD frequently have EEG and MRI abnormalities. However, when patients without MRI abnormalities were analyzed, the rate of EEG abnormalities remained the same and the relation with ID persisted. The findings suggest that EEG abnormalities in patients with PDD are frequent both with and without MRI structural abnormalities.

MRI abnormalities detected in 12.3% of the patients were mild cortical atrophy and bilateral periventricular leukomalacia. EEG abnormalities detected were focal active epileptic and paroxysmal abnormalities which were frequently detected in the right and left temporal cortex and adjacent cortical structures. The findings are consistent with previous studies,^[3,18] suggesting that focal and multifocal paroxysmal EEG abnormalities are common in the centro-parieto-temporal regions, and that temporal cortex might play an important role in the pathophysiology of autism. Joint attention deficit in autism, which is a core symptom, may be related to medial temporal lobe dysfunction.^[19] Single photon emission computed tomography and positron emission tomography studies also suggest medial temporal lobe involvement.^[20,21] In tuberous sclerosis, a hereditary neurocutaneous syndrome associated with a high incidence of autism, symptoms of autism are strongly related to the presence of tubers and epileptiform discharges in the temporal lobe.^[22,23] Brain regions other than the temporal cortex have been implicated in autism. Postmortem and neuroimaging studies have found abnormalities in the anterior cingulate cortex,^[24] cerebellum,^[25] and facial nucleus.^[26] However, these studies were conducted with pure autistic subjects; therefore, it may not be possible to generalize the findings to all PDD patients.

Frequent MRI abnormalities were mild cortical atrophy and bilateral periventricular leukomalacia, which could be related to hypoxic-ischemic encephalopathy. This is consistent with previous studies.^[11] This result might support the idea that birth

trauma and related hypoxia might be an important cause of pervasive developmental disorders.^[27] We did not find significant differences in the frequency of EEG and MRI abnormalities in patients with or without obstetric complications; however, the use of parental history to obtain information about obstetric complications might be inaccurate. Moreover, not every of hypoxic births results in PDD, suggesting that obstetric complications might trigger an existing vulnerability in PDD patients. The type of MRI pathology was not related to a history of obstetric complication history, although the sample for this analysis was very small.

There are limitations in this study. Since this study is retrospective, a uniform diagnostic method for establishment of a PDD diagnosis was not used. In summary, almost a fourth of the patients with pervasive developmental disorders had EEG or MRI abnormalities, and the rate of EEG abnormalities has a severity-dependent relation with ID. The most frequent MRI abnormalities might be related to hypoxic-ischemic encephalopathy, and temporal cortex and adjacent cortical structures are the most frequent sites of local active epileptic and paroxysmal EEG abnormalities.

Funding: None.

Ethical approval: Not needed.

Competing interest: None declared.

Contributors: Ünal Ö wrote the first draft of this paper. All authors contributed to the intellectual content and approved the final version. Özcan Ö is the guarantor.

References

- 1 Volkmar FR, Nelson DS. Seizure disorders in autism. *J Am Acad Child Adolesc Psychiatry* 1990;29:127-129.
- 2 Tuchman R, Rapin I. Epilepsy in autism. *Lancet Neurol* 2002;1:352-358.
- 3 Rossi PG, Parmegianni A, Bach V, Santucci M, Visconti P. EEG features and epilepsy in patients with autism. *Brain Dev* 1995;17:169-174.
- 4 Tuchman RF, Rapin I. Regression in pervasive developmental disorders: seizures and epileptiform electroencephalogram correlates. *Pediatrics* 1997;99:560-566.
- 5 Scott RC, Neville BG. Developmental perspectives on epilepsy. *Curr Opin Neurol* 1998;11:115-118.
- 6 Ballaban-Gil K, Tuchman R. Epilepsy and epileptiform EEG: association with autism and language disorders. *Ment Retard Dev Disabil Res Rev* 2000;6:300-308.
- 7 Richer LP, Shevell MI, Rosenblatt BR. Epileptiform abnormalities in children with attention-deficit-hyperactivity disorder. *Pediatr Neurol* 2002;26:125-129.
- 8 Goulden KJ, Shinnar S, Koller H, Katz M, Richardson SA. Epilepsy in children with mental retardation: a cohort study.

- Epilepsia 1991;32:690-697.
- 9 Amano K, Takamatsu J, Ogata A, Miyazaki C, Kaneyama H, Katsuragi S, et al. Characteristics of epilepsy in severely mentally retarded individuals. *Psychiatry Clin Neurosci* 2000;54:17-22.
- 10 Airaksinen EM, Matilainen R, Mononen T, Mustonen K, Partanen J, Jokela V, et al. A population-based study on epilepsy in mentally retarded children. *Epilepsia* 2000;41:1214-1220.
- 11 Challman TD, Barbaresi WJ, Katusic SK, Weaver A. The yield of the medical evaluation of children with pervasive developmental disorders. *J Autism Dev Disord* 2003;33:187-192.
- 12 Parmeggiani A, Posar A, Giovanardi-Rossi P, Andermann F, Zifkin B. Autism, macrocrania and epilepsy: how are they linked? *Brain Dev* 2002;24:296-299.
- 13 American Psychiatric Association. In: *Diagnostic and Statistical Manual of Mental Disorders*, 4th ed. Washington DC: American Psychiatric Association, 1994.
- 14 Savasir I, Sezgin, N, Erol N. *Handbook of the Ankara Developmental Screening Inventory*, 1st ed. Ankara: Turkish Psychologists Association Publication, 1994.
- 15 Alpas B, Akcakin M. Vineland Adaptive Behavior Scales (Survey Form): adaptation, validity and reliability for infants of 0-47 months of age. *Turkish J Psychol* 2003;18:57-71.
- 16 Kawasaki Y, Yokota K, Shinomiya M, Shimizu Y, Niwa S. Brief report: electroencephalographic paroxysmal activities in the frontal area emerged in middle childhood and during adolescence in a follow-up study of autism. *J Autism Dev Disord* 1997;27:605-620.
- 17 Tuchman RF, Rapin I, Shinnar S. Autistic and dysphasic children. II: Epilepsy. *Pediatrics* 1991;88:1219-1225.
- 18 Olsson I, Steffenburg S, Gillberg C. Epilepsy in autism and autistic like conditions. A population-based study. *Arch Neurol* 1988;45:666-668.
- 19 Mundy P. Annotation: the neural basis of social impairments in autism: the role of the dorsal medial-frontal cortex and anterior cingulate system. *J Child Psychol Psychiatry* 2003;44:793-809.
- 20 Zilbovicius M, Boddaert N, Belin P, Poline JB, Remy P, Mangin JF, et al. Temporal lobe dysfunction in childhood autism: a PET study. *Positron emission tomography. Am J Psychiatry* 2000;157:1988-1993.
- 21 Ohnishi T, Matsuda H, Hashimoto T, Kunihiro T, Nishikawa M, Uema T, et al. Abnormal regional cerebral blood flow in childhood autism. *Brain* 2000;123(Pt 9):1838-1844.
- 22 Bolton PF, Griffiths PD. Association of tuberous sclerosis of temporal lobes with autism and atypical autism. *Lancet* 1997;349:392-395.
- 23 Bolton PF, Park RJ, Higgins JN, Griffiths PD, Pickles A. Neuro-epileptic determinants of autism spectrum disorders in tuberous sclerosis complex. *Brain* 2002;125(Pt 6):1247-1255.
- 24 Bauman ML, Kemper TL. Neuroanatomic observations of the brain in autism. In: Bauman ML, Kemper TL, eds. *The Neurobiology of Autism*. Baltimore: Johns Hopkins University Press, 1994.
- 25 Courchesne E, Yeung-Courchesne R, Press GA, Hesselink JR, Jernigan TL. Hypoplasia of cerebellar vermal lobules VI and VII in autism. *N Engl J Med* 1988;318:1349-1354.
- 26 Courchesne E. Brainstem, cerebellar and limbic neuroanatomical abnormalities in autism. *Curr Opin Neurobiol* 1997;7:269-278.
- 27 Deykin EY, MacMahon B. Pregnancy, delivery, and neonatal complications among autistic children. *Am J Dis Child* 1980;134:860-864.

Received May 19, 2008

Accepted after revision November 26, 2008