



# Soft tissue aneurysmal bone cyst of left hemithorax with review of literature

Ajay Kumar Yadav<sup>1</sup> · Mohit Sharma<sup>1</sup>  · Ketul Puj<sup>1</sup>

Received: 5 October 2020 / Revised: 5 November 2020 / Accepted: 9 November 2020 / Published online: 28 January 2021  
© Indian Association of Cardiovascular-Thoracic Surgeons 2021

## Abstract

Soft tissue aneurysmal bone cysts (STABCs) are extremely rare extraosseous counterpart of aneurysmal bone cyst (ABC), with close resemblance to histo-morphologic characteristics of ABC. Here we would like to report a 13-year-old female patient, who presented with a large mass, occupying the entire left hemithorax. Patient underwent resection of the thoracic mass. On histopathological examination, it was found to be a soft tissue ABC. It is a very rare tumor and until date 28 cases have been reported in English literature, to the best of our knowledge. On review of the literature, we found this to be the first case of STABC reported in thoracic cavity. The objective of this case presentation is to provide information regarding clinical presentation, radiological and pathological features, and course of management for this rare disease. Soft tissue ABCs are a new class of tumors, so more extensive research is required to establish standard guidelines for their diagnosis and management, to yield better prognosis.

**Keywords** Soft tissue aneurysmal bone cyst · Thoracic mass

## Introduction

Soft tissue aneurysmal bone cyst (STABC) is an extremely rare, extraosseous, neoplastic lesion characterized by varying sizes of proliferating vessels, round to spindle cells, hyalinised stroma, multinucleated osteoclastic giant cells, hyaline cartilage, and reactive osteoid material. It is a very rare tumor and until date 29 cases have been reported in English literature, and none in the thoracic cavity, to the best of our knowledge. Salm and Sissons were the first in 1972 to describe STABC as a giant cell tumor of the soft tissue, with pathological features similar to primary aneurysmal bone cysts (ABC) [1]. The objective of this case presentation is to provide information regarding clinical presentation, radiological and pathological features, and course of management for this rare disease.

## Case report

A 13-year-old female patient presented to our institute with complaints of dyspnea on exertion and backache for the last 2 months. Patient was evaluated with contrast-enhanced computerized tomography (CT) scan of the thorax. It was suggestive of a 11 × 10 × 15-cm heterogeneously enhancing soft tissue density lesion with thin peripheral calcification involving the left hemithorax and causing complete collapse of the left lung. Mass lesion caused mediastinal shift to the right side. Lesion also showed multiple internal hypodense areas suggestive of septations, calcification, and hemorrhage within the lesion. CT-guided biopsy of the lesion was done, which was suggestive of benign spindle cell neoplasm of fibro-histiocytic origin. Patient was planned for surgery after tumor board discussion. Preoperative evaluation of the cardiovascular and respiratory systems was done. Patient was detected coronavirus disease of 2019 (COVID-19) positive, and therefore, excision of left thoracic mass was deferred for 1 month. Patient was placed in right lateral decubitus position and postero-lateral thoracotomy was done through the left 5th intercostal space. The left 5th rib was resected to get access to the left hemithorax. Tumor was found to occupy the complete left hemithorax. The left lung was found to be compressed and collapsed antero-superiorly. Tumor was found free from

✉ Mohit Sharma  
mohit.sharma@gcriindia.org

Ajay Kumar Yadav  
drajaykumaryadavms@gmail.com

Ketul Puj  
ketul.puj@gcriindia.org

<sup>1</sup> The Gujarat Cancer & Research Institute, Ahmedabad, Gujarat, India

diaphragm, so meticulous dissection was started at posterior surface of the tumor. Anteriorly, tumor was carefully dissected from left common carotid and subclavian vessels (Fig. 1a, b). Tumor was resected and sent for histopathological examination. The left lung expanded well. Postoperative recovery of patient was uneventful and patient was discharged after 7 days. Histopathological examination report was suggestive of soft tissue aneurysmal bone cyst, measuring  $18 \times 15 \times 8$  cm in size, and showing varying sizes of proliferating vessels, round to spindle cells, hyalinised stroma, multinucleated osteoclastic giant cells, hyaline cartilage, and reactive osteoid material (Fig. 2). Resected 5th rib was found completely free of tumor. It is the only reported case of soft tissue aneurysmal bone cyst in the thorax.

## Review of literature

Jaffe and Lichtenstein were the first (1942) to introduce ABCs as a non-neoplastic, expansile bone lesion with distinct pathology from neoplastic lesions [2]. ABC can occur in any bone, but is more frequently seen in the long bone metaphysis region and vertebral column. Salm and Sissons first described 2 cases in 1972 as “vascular cystic tumours of soft tissue” with microscopic features similar to intraosseous ABC but they never arise from bone. Lopez-Barea et al. [3] and Shannon et al. [4] defined STABC as extraosseous counterpart of ABC, which was histologically identical to ABC, but diagnosed

much less frequently. Dal Cin et al., in 2000, confirmed that chromosome bands 16q22 and 17p13 were nonrandomly rearranged in the entire spectrum of ABCs, including solid variants and extraosseous forms, and they had a common pathogenesis [5]. Data is continuously evolving for STABC as more and more cases are being reported. We have summarized all cases reported so far in literature (Table 1). There are 21 female and 8 male patients from 7 to 60 years of age [6–10]. STABC can occur in any soft tissue of the body. Our case is the first to be occurring in the left thoracic cavity.?)

Aneurysmal bone cyst is a benign cystic lesion of bone, containing blood-filled spaces, separated by connective tissue septa containing fibroblasts, osteoclast-type giant cells, and reactive woven bone [5]. Jaffe and Lichtenstein postulated that alterations in local hemodynamics cause increased venous pressure and engorgement of the vascular bed in the transformed bone, leading to resorption, connective tissue replacement, and osteoid formation [2]. ABC can be classified as primary and secondary types. Primary type can be congenital or acquired and can arise from pre-existing arterio-venous malformations. The congenital type is usually seen in children and young adults without history of trauma, whereas the acquired type is more common in adults with history of trauma. The secondary type is found to be associated with degeneration of pre-existing lesions such as a cyst, tumor, or fibro-osseous lesion.

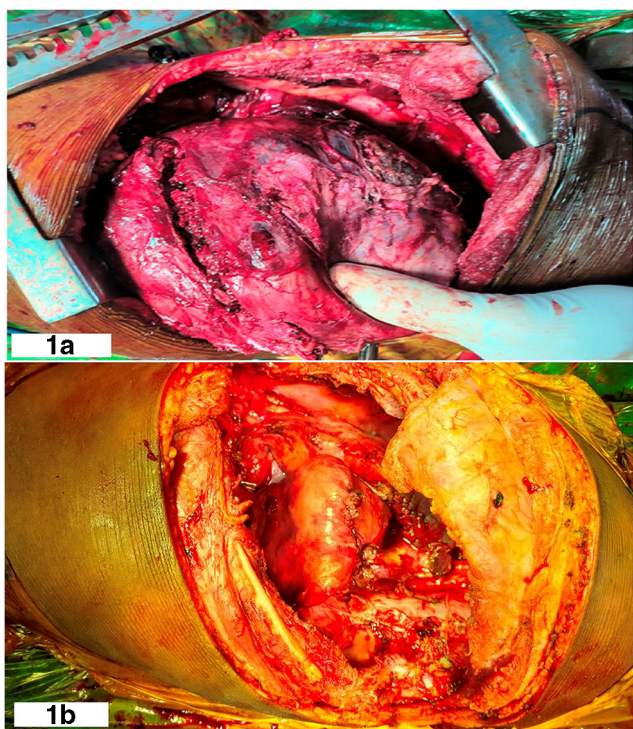
STABCs are extremely rare, extraosseous counterpart of ABC, with close resemblance to histo-morphologic characteristics of ABC. Extraosseous ABC can present as diagnostic dilemma due to its rare presentation and resemblance to other giant cell tumors including myositis ossificans, teno-synovial giant cell tumor, and extra-skeletal telangiectatic osteosarcoma. STABCs’ clinical, radiological, and pathological characteristics, along with newer evolving molecular characteristics, make them a different group of tumor.

## Clinical presentation

STABC usually present as slow growing, painless or painful, soft tissue swelling, mainly located in the lower or upper limb, abdominal wall, breast, groin, and pelvis in decreasing order of frequency. Our case is the only case reported in the thoracic cavity. Our patient presented with complaints of dyspnea on exertion and backache, which was explained by compression caused by the large tumor occupying the complete left hemithorax. These may present between ages of 7 and 60 years.

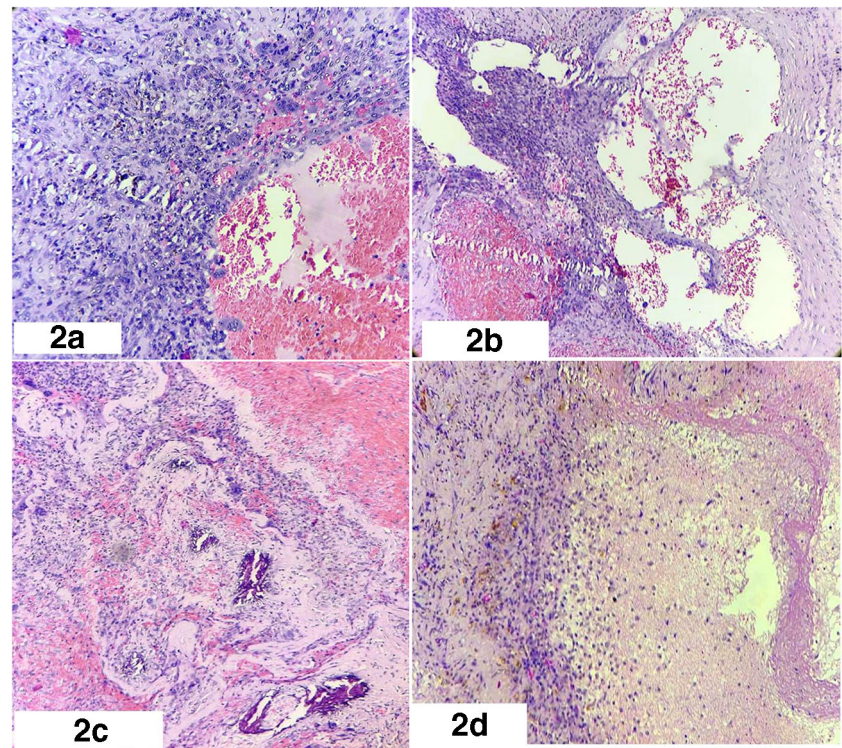
## Radiological features

STABC can be evaluated by magnetic resonance imaging (MRI) or CT scan. MRI can show blood-filled cystic spaces and produce characteristic fluid-fluid levels, which are best



**Fig. 1** a Intraoperative photograph of left hemithorax mass. b Post resection left hemithorax

**Fig. 2** **a** Cystic cavity lined by giant cell. **b** Blood-filled spaces with intervening fibrous septa containing osteoclast-type giant cell. **c** Hyalinized stroma with calcification and proliferation of bland fibroblast. **d** Infarct type of necrosis on right side



**Table 1** All case reports of STABC until date. Asterisk presents that data is received from reference no. [8]

Case no.	Age	Gender	Site	Size in cm	Author	Year
1	32 years	M	Vastus medialis	6.0	Salm et al. [1]*	1972
2	45 years	F	Abdominal wall	3.5	Salm et al. [1]*	1972
3	15 years	F	Groin	4.5	Amir et al.*	1992
4	7 years	M	Left common carotid	3.0	Petrik et al.*	1993
5	20 years	F	Infraspinous region	7.0	Rodriguez-Peralto et al.*	1994
6	57 years	F	Left upper arm	8.0	Lopez-Barea et al.*	1996
7	29 years	F	Left retroclavicular region	3.1	Shannone et al.*	1997
8	8 years	M	Shoulder	-	Dal Cin et al.*	2000
9	51 years	F	Pelvis	10.0	Samura et al.*	2000
10	8 years	M	Shoulder	8.0	Nielsen et al.*	2002
11	29 years	F	Right Groin	4.0	Nielsen et al.*	2002
12	37 years	F	Upper arm	2.5	Nielsen et al.*	2002
13	28 years	F	Left deltoid	9.0	Nielsen et al.*	2002
14	30 years	F	Thigh	4.0	Nielsen et al.*	2002
15	21 years	M	Right gluteus medius	9.0	Wang et al.*	2004
16	12 years	F	Left thigh	4.0	Ajilogba et al.*	2005
17	10 years	F	Left thigh	7.7	Ellison et al.*	2007
18	60 years	F	Breast	12.0	D'Costa et al. [9]	2007
19	26 years	F	Right thigh	7.0	Pietschmann et al.*	2011
20	38 years	M	Left upper arm	4.0	Pietschmann et al.*	2011
21	41 years	F	Left arm	7.0	Baker et al. [6]	2015
22	26 years	F	Left thigh	6.6	Lopez et al. [10]	2017
23	49 years	F	Biceps Femoris	4.5	Song et al. [7]	2019
24	34 years	F	Vastus Lateralis	4.0	Song et al. [7]	2019
25	15 years	M	Vastus medialis	2.5	Song et al. [7]	2019
26	19 years	F	Vastus medialis	4.0	Song et al. [7]	2019
27	16 years	F	Oblique transverse abdominis	8.0	Song et al. [7]	2019
28	32 years	M	Gluteus minimus	4.0	Song et al. [7]	2019
29	13 years	F	Left hemithorax	15.0	Our case	2020

seen on more fluid sensitive sequences. The capsule and septations usually have low T1 and T2 signal, as a result of their fibrous nature, and enhance on post-contrast images, producing a “honeycomb” appearance. CT scan can show soft tissue mass with peripheral calcification and hypodense center, which may have septations and calcification [6]. Radiological appearance and behavior of tumor can differentiate STABC from other tumors.

## Pathological features

ABC and STABC are histologically indistinguishable from each other. STABC presents as well-defined soft tissue mass, consisting of cavernous spaces filled with blood and separated by fibrous septa, which lack smooth muscle or an endothelial lining, but contain osteoclast-type multinucleated giant cells, flattened spindle-shaped fibroblasts, and delicate reactive woven bone [11]. It is now generally accepted that primary ABC and STABC are a neoplastic process, owing to rearrangements involving the ubiquitin-specific peptidase 6 (USP6) gene located at chromosome 17p13, as a reproducible genetic event [7].

## Treatment

Surgical resection is the treatment of choice. As this tumor is very rare, every reported case will provide new insights for treatment options.

## Conclusions

As STABC is an entirely new class of tumors, more extensive research is required to establish standard guidelines for their diagnosis and management to yield better prognosis.

**Funding** None.

## Compliance with ethical standards

**Conflict of interest** The authors declare that there is no conflict of interest.

**Ethics committee approval** Institutional ethics committee approval for publication is taken.

**Informed consent** A written informed consent for publication of patient clinical details and/or clinical images was obtained from the mother of the patient. A copy of the consent form is available for review by the Editor of the journal.

**Human and animal rights** No animals were involved.

## References

1. Salm R, Sissons HA. Giant-cell tumours of soft tissues. *J Pathol.* 1972;107:27–39.
2. Jaffe HL, Lichtenstein L. Solitary unicameral bone cyst with emphasis on the roentgen picture, the pathologic appearance and the pathogenesis. *Arch Surg.* 1942;44:1004–25.
3. Lopez-Barea F, Burgos-Lizalde E, Rodríguez-Peralto JL, Alvarez-Linera J, Sanchez-Herrera S. Primary aneurysmal cyst of soft tissue. Report of a case with ultrastructural and MRI studies. *Virchows Archiv.* 1996;428:125–129.
4. Shannon P, Bédard Y, Bell R, Kandel R. Aneurysmal cyst of soft tissue: report of a case with serial magnetic resonance imaging and biopsy. *Hum Pathol.* 1997;28:255–7. [https://doi.org/10.1016/s0046-8177\(97\)90117-9](https://doi.org/10.1016/s0046-8177(97)90117-9).
5. Dal Cin P, Kozakewich HP, Goumnerova L, Mankin HJ, Rosenberg AE, Fletcher JA. Variant translocations involving 16q22 and 17p13 in solid variant and extraosseous forms of aneurysmal bone cyst. *Genes Chromosomes Cancer.* 2000;28: 233–34.
6. Baker KS, Gould ES, Patel HB, Hwang SJ. Soft tissue aneurysmal bone cyst: a rare case in a middle aged patient. *J Radiol Case Rep.* 2015;9:26–35.
7. Song W, Suurmeijer AJH, Bollen SM, Cleton-Jansen AM, Bovée JVMG, Kroon HM. Soft tissue aneurysmal bone cyst: six new cases with imaging details, molecular pathology, and review of the literature. *Skeletal Radiol.* 2019;48:1059–67.
8. Hao Y, Wang L, Yan M, Jin F, Ge S, Dai K. Soft tissue aneurysmal bone cyst in a 10-year-old girl. *Oncol Lett.* 2012;3:545–8. <https://doi.org/10.3892/ol.2011.530>.
9. D’Costa GF, Hastak MS, Patil YV. Primary aneurysmal cyst: bone type in the breast. *Indian J Surg.* 2007;69:248–50.
10. Lopez LV, Rodriguez MG, Siegal GP, Wei S. Extraskeletal aneurysmal bone cyst: report of a case and review of the literature. *Pathol Res Pract.* 2017;213:1445–9.
11. Rosenberg AE, Nielsen GP, Fletcher JA. World Health Organisation classification of tumours. In: *Pathology and Genetics of Tumours of Soft tissues and Bone.* Lyon: IARC Press; 2002. p. 338.

**Publisher’s note** Springer Nature remains neutral with regard to jurisdictional claims in published maps and institutional affiliations.