

# Transtrochanteric Rotational Osteotomy for Nontraumatic Osteonecrosis of the Femoral Head in Young Adults

Sandeep Biswal MS, Sunit Hazra MS,  
Ho Hyun Yun MD, Chang Yong Hur MD, PhD,  
Won Yong Shon MD, PhD

Received: 23 February 2008 / Accepted: 19 December 2008 / Published online: 14 January 2009  
© The Association of Bone and Joint Surgeons 2009

**Abstract** Transtrochanteric rotational osteotomy (TRO) is a controversial procedure with reported inconsistent results. We reviewed 50 patients (60 hips) who underwent this procedure for extensive osteonecrosis of the femoral head, focusing on varization to determine its effectiveness as a head-preserving procedure in young adults. The mean age of the patients was 28 years (range, 18–46 years). Using the Ficat-Arlet classification, 40 hips had Stage II and 20 hips had Stage III involvement. According to the classification system of Shimizu et al., the extent of the lesions were Grade C in 54 hips and Grade B in six hips; the location of the lesions were Grade c in 56 hips and Grade b in four hips. Minimum followup was 18 months (mean, 84 months; range, 18–156 months). The mean preoperative Harris hip score was 44.7 points (range, 32–62 points) which improved to an average postoperative score of 80.1 points (range, 44–100 points) at the latest followup. Forty-four hips showed no radiographic evidence of progression of collapse. Ten hips showed progressive collapse, seven hips showed progressive varus deformity, three hips had stress fractures of the femoral neck, and one hip had

infection. We believe TRO with varization is worth attempting for extensive osteonecrosis of the femoral head in young adults, although failures and complications are not uncommon.

**Level of Evidence:** Level IV, case series. See the Guidelines for Authors for a complete description of levels of evidence.

## Introduction

Osteonecrosis of the femoral head (ONFH) presents a clinical challenge because of its inconsistent and suboptimal results with head-preserving procedures. Nontraumatic ONFH usually affects young adults during the third to fourth decades of life, and most of the radiographically larger lesions progress to collapse, resulting in osteoarthritis without treatment [24, 27, 28, 30, 43]. The risk of collapse of the femoral head depends on the extent and location of the lesion [1, 24, 36]. Despite improvements in techniques and materials in total hip arthroplasty (THA), survivorship in young patients is still suboptimal owing to the high rate of complications [7, 18, 20, 33]. Although head-preserving surgeries such as core decompression [10, 26] and vascularized and nonvascularized grafting [12, 26, 32, 45] appear to delay the progression of collapse and subsequent arthritic changes, in these studies the indications vary in terms of etiologic factors, radiographic staging, or indications for surgery, and the survival rate of the femoral head decreases with increases in size and stage of the lesion [1, 4, 10, 32].

Sugioka, the developer of the TRO, achieved a promising long-term survival rate of 78% to 86% using the technique for treatment of nontraumatic ONFH in the Japanese population [40–42]. Other Japanese and Asian

---

Each author certifies that he has no commercial associations (eg, consultancies, stock ownership, equity interests, patent/licensing arrangements, etc) that might pose a conflict of interest in connection with the submitted article.

Each author certifies that his or her institution has approved or waived approval for the human protocol for this investigation and that all investigations were conducted in conformity with ethical principles of research.

---

S. Biswal, S. Hazra, H. H. Yun, C. Y. Hur, W. Y. Shon (✉)  
Department of Orthopaedic Surgery, Korea University,  
Guro Hospital, #80, Guro-Dong, Guro-Gu, Seoul 152-703,  
South Korea  
e-mail: shonwy@hotmail.com

studies have reproduced similar outcomes in patients with ONFH using this technique [14–16, 21]. Inao et al. [15] reported that 11 of 14 hips had no collapse of the femoral head at a mean of 13.2 years followup after TRO. In another study, Koo et al. [21] reported his patients experienced no additional collapse at a mean followup of 54 months. However, some studies in the American and European literature reported high failure rates for TRO [3, 8, 9, 31, 44]. Despite strict adherence to the original technique and protocol of Sugioka et al. [42], Rijnen et al. [31] reported conversion of 17 of 26 hips (65%) to THA during an average followup of 8.7 years. Similarly, Dean and Cabanela [8] reported progression of collapse in 15 of 18 hips (83%) at a mean of 5 years after performing TRO for ONFH. Eyb and Kotz [9] also reported that reoperation including THA was necessary in 17 of 39 hips (59%) at a mean of 49 months after TRO, with a high rate (46.2%) of postoperative complications.

Several other studies have advocated varus osteotomy as an effective head preservation surgery in which the lateral intact area of the femoral head can be placed into the acetabular weightbearing portion, thus preventing progression of collapse [19, 24, 34]. Sugioka [40] suggested intentional varus positioning should be planned for patients with advanced collapse and extensive lesions, and when the ratio of the intact area of the femoral head to the acetabular weightbearing area was greater than 36% on postoperative anteroposterior (AP) radiographs, additional collapse was observed in only four of 102 hips. Similarly, Atsumi and Kuroki [2] reported a mean of 80.3% (range, 53%–100%) extension of the intact articular surface of the loaded portion of the femoral head was obtained, compared with preoperative values (mean, 6.9%; range, 0%–40%), on AP radiographs with 10° to 25° intentional varus positioning in the posterior rotation of TRO for patients with extensive ONFH lesions. Collapse was prevented in 17 of 18 hips at a mean followup of 42 months.

Therefore, we asked whether: (1) TRO with varization would prevent progression of collapse in extensive ONFH lesions as judged by clinical and radiographic survivorship, and (2) staging, extent, and location of the lesion, and preoperative and postoperative intact ratios differed in patients with progressive collapse and no collapse. We then determined (3) complication rates for TRO with varization and (4) whether this procedure would result in substantial leg-length discrepancy (LLD).

## Material and Methods

We retrospectively reviewed 53 patients (64 hips) in whom TRO had been performed for extensive nontraumatic ONFH between April 1994 and February 2006. Three

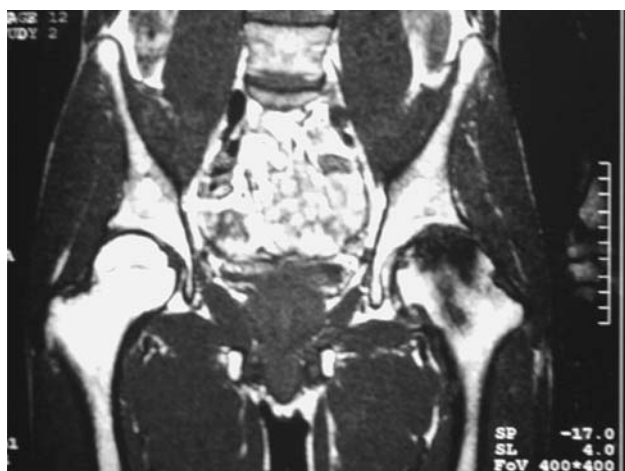patients (four hips) were lost to followup less than 18 months after surgery; therefore, 50 patients (94% of patients with 60 hips) were available for retrospective review. The study population comprised 32 men and 18 women with a mean age of 28 years (range, 18–46 years). Ten of the 50 patients had extensive bilateral disease. The etiologies were alcoholism in 32 patients (38 hips), steroid use in six patients (10 hips), and idiopathic in 12 patients (12 hips). The minimum followup was 18 months (mean, 84 months; range, 18–156 months).

In all patients we obtained AP, Lauenstein lateral, and Sugioka views and MRI 3 weeks before surgery. All showed nontraumatic ONFH on radiographs and MRI; 40 had Stage II and 20 had Stage III involvement per the Ficat-Arlet classification [11]. We used the classification of Shimizu et al. [36] to define the extent and location of the lesion on the MR images. According to this classification, the extent of the lesion is defined as Grade A when the maximal radial distance of necrosis is less than  $\frac{1}{4}$  of the diameter of the head. Similarly, the extent of the lesion is graded B when the maximal radial distance of the lesion is between  $\frac{1}{4}$  to  $\frac{1}{2}$  the head's diameter, and Grade C when it is greater than  $\frac{1}{2}$  the head's diameter. Likewise, the location of the lesion is defined as Grade a when it occupies less than  $\frac{1}{3}$  of the acetabular weightbearing rim, Grade b when it occupies between  $\frac{1}{3}$  to  $\frac{2}{3}$  and Grade c when it occupies  $\frac{2}{3}$  or more, on coronal MR images. The lesions with Grade c locations were further subdivided into Types c1 and c2 as described by Sugano et al. [37, 38]. Both types occupy greater than the medial  $\frac{2}{3}$  of the weightbearing portion, but, whereas Type c2 lesions extend laterally to the acetabular edge, Type c1 lesions do not.

A lesion was defined as extensive if it had at least an extent of Grade C or location of Grade c: all 60 hips had extensive lesions. Extent and location of involvement were Shimizu Grades C and c in 50 hips, Grades C and b in four hips, and Grades B and c in six hips, respectively (Fig. 1). The locations of the lesions were Type c1 in 34 and Type c2 in 22 hips [37].

The amount of varization was determined on the preoperative AP radiograph. We attempted to set the maximum varization at a 110° to 120° angle; the amount of varus was determined in individual cases by subtracting the preoperative neck-shaft angle from 110° to 120°. The amount of posterior or anterior intact area was evaluated on a view described by Sugioka et al. [42], and anterior or posterior rotation was planned accordingly. The ratio of the intact to the total area was calculated as described by Sugioka et al. [42]. Anterior TRO was performed in 54 hips and posterior TRO was performed in six.

The senior author (WYS) performed all surgeries using the modified Ollier's approach with the patient in a lateral position. The principal line of the osteotomy was



**Fig. 1** A lesion with Grade B extent and Grade c location according to the classification of Shimizu et al. [36] is seen in this MR image.

performed as per the preoperative plan. Anterior rotation ranged from 75° to 105° with a mean of 87°. Posterior rotation ranged from 95° to 135° with a mean of 110°. Fixation of osteotomy was performed while maintaining a gap of a few millimeters inferiorly at the superior aspect of the lateral cortex to compensate for loss of length owing to varization (Fig. 2). Three or four cannulated 6.5-mm screws were used in the first 44 hips, whereas 125° dynamic hip screws were used in the later 16 hips.

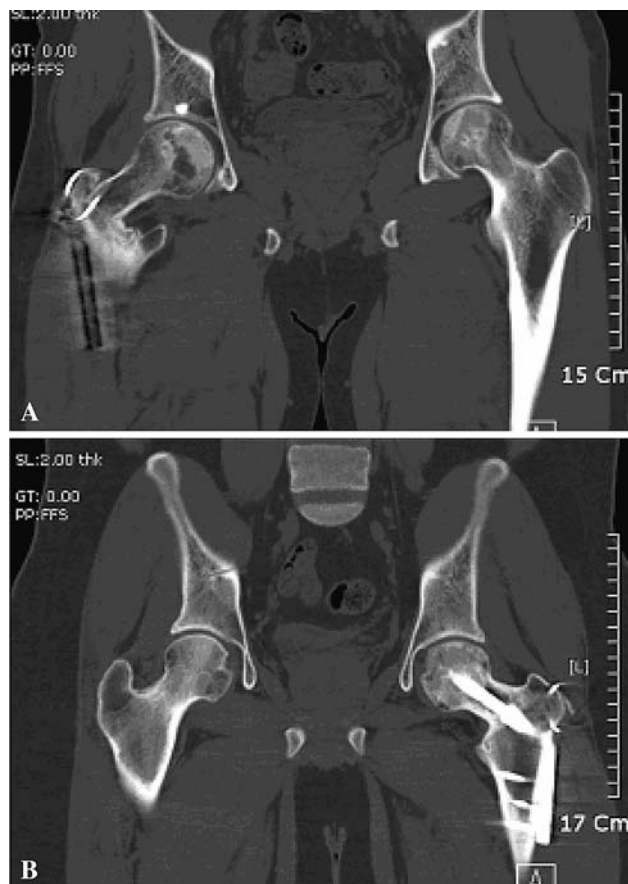Patients were kept in skin traction for 2 weeks and performed intermittent quadriceps and active range of motion exercises as tolerated. Nonweightbearing crutch walking was encouraged after 2 weeks for a minimum of 3 months, followed by partial weightbearing for another 3 months. Crutch walking was continued until 4 to 6 months after surgery.

To determine the vascular status of the head, we performed scintigraphy 3 to 4 weeks after the surgery, and blood perfusion of the proximal segment was evaluated. All patients received an injection of 20 mL 99mTc methylene diphosphonate, and 3 hours later, anterior and posterior radionuclide scans were obtained and the uptake in the proximal segment was evaluated.

Patients were followed clinically and radiographically at 1- to 3-month intervals during the first year after the operation, depending on the union at the osteotomy site and clinical status of the patient, at 3- to 6-month intervals for 2 to 3 years, and at 6- to 12-months intervals thereafter.

All the patients were assessed with the Harris hip score (HHS) [13] preoperatively and at the last followup. We used a lower limb scanogram to measure any LLD.

An orthopaedic fellow (SH) not involved in the treatment calculated the immediate postoperative intact ratio by taking angular measurements of the area of the lateral loaded noncollapsed femoral head that corresponded to the



**Fig. 2A–B** Computed tomography scans after TRO show (A) the proximal fragment was placed approximately 10 mm proximally from the lower-most end of the osteotomy plane of the distal fragment of the femur and (B) the greater trochanter was reattached more distally than the distal trochanteric portion of the proximal fragment of the femur to compensate for inevitable LLD after TRO.

acetabular roof on postoperative AP radiographs according to the method described by Sugioka et al. [42].

Followup radiographs were evaluated to determine progression of collapse. We defined collapse as progressive when the maximum collapse of the transposed intact area beneath the acetabular weightbearing portion on the final followup AP radiograph was greater than 2 mm compared with the immediate postoperative film. On the preoperative, immediate postoperative, and latest followup radiographs, neck-shaft angle was calculated. The change in varus angulation between the immediate postoperative and the latest followup radiographs also was calculated to evaluate progression of varus angulation.

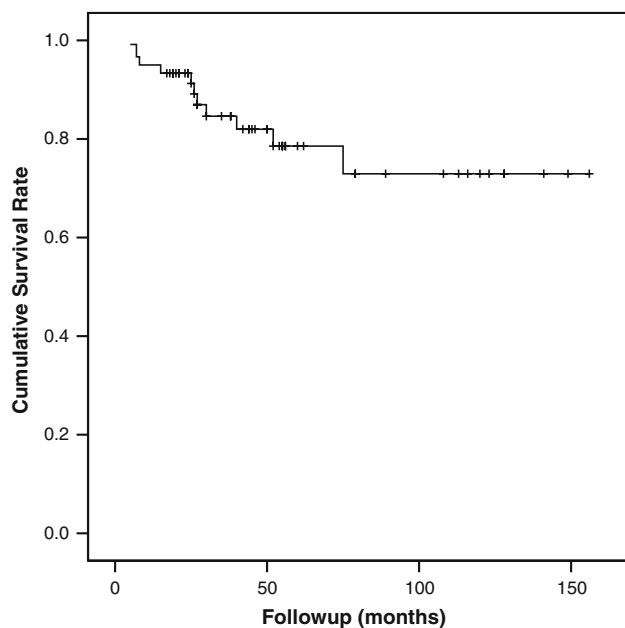
We determined differences in staging, extent, and location of the lesion, and preoperative and postoperative intact ratios, between the progressive collapse group and the no collapse group using Fisher's exact test. A Kaplan-Meier survival analysis [17] was performed with corresponding 95% confidence intervals with conversion to

THA as the end point. Statistical analyses were performed using SAS<sup>®</sup> (Version 9.1; SAS Institute Inc, Cary, NC).

## Results

Forty-four of 60 hips (73%) showed no progressive collapse at the final followup. The Kaplan-Meier survivorship with the end point defined as the time when the hip was converted to THA was 82% at 132 months (95% confidence interval, 107–141 months) postoperatively (Fig. 3). The average preoperative HHS was 44.7 points (range, 32–62 points) which improved to an average postoperative score of 80.1 points (range, 44–100 points) at the most recent followup. Of the surviving 49 hips, 44 had a HHS greater than 80 and five hips had a HHS between 70 and 80. At the most recent visit, 44 hips had no pain or limp and five had some intermittent pain associated with or without a limp. The remaining 11 hips were converted to THA at an average of 20 months including five hips for progressive collapse.

Progressive collapse developed in 10 hips and one of these had postoperative cold uptake on the postoperative bone scan. The postoperative intact ratio was greater ( $p = 0.02$ ) in the no collapse group than in the collapse group. The number of patients with a Shimizu Grade c location also was greater ( $p = 0.02$  for c1;  $p = 0.01$  for c2) in the noncollapse group than in the collapse group (Table 1). The average intact ratio increased from 28%



**Fig. 3** A Kaplan-Meier survivorship curve with the end point defined as the time when the hip was converted to THA shows 82% survival at 132 months (95% confidence interval, 107–141 months) postoperatively.

**Table 1.** Comparison of the collapse and noncollapse groups

Parameter	Noncollapse group (n = 44)	Collapse group (n = 10)	p Value*
Preoperative intact ratio <sup>†</sup> (%)	29 (20–38)	27 (19–36)	0.9
Postoperative intact ratio <sup>†</sup> (%)	42 (36–46)	32 (28–36)	0.02
Ficat-Arlet Stage II	30	6	0.85
Ficat-Arlet Stage III	14	4	0.8
Extent of lesion <sup>‡</sup> (Grade C) (n = 49)	40	9	0.89
Location of lesion <sup>‡</sup> (Grade c1) (n = 30)	26	4	0.02
Location of lesion <sup>‡</sup> (Grade c2) (n = 21)	16	5	0.01

\* Fisher's exact test; <sup>†</sup> values expressed as means, with ranges in parentheses; <sup>‡</sup> classification of Shimizu et al. [36] and Sugano et al. [37].

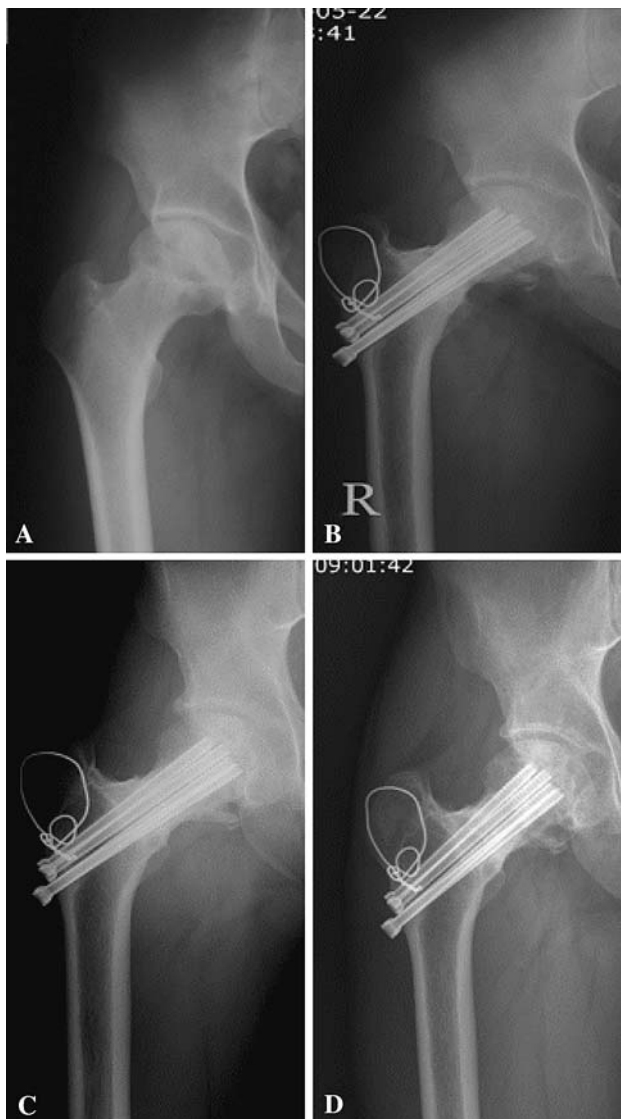
(range, 19%–38%) to 40% (range, 28%–46%), and the average neck-shaft angle decreased from 132° (range, 126°–138°) to 110° (range, 102°–119°) after surgery.

Stress fractures of the femoral neck developed in three hips, one treated with nonoperative management and two were converted to THA (Fig. 4). We observed progressive varus deformity with the neck-shaft angle decreasing to less than 100° in seven hips (11.6%). Three were converted to THA because of combined advanced collapse of the femoral head whereas four had refixation using dynamic hip screws or subtrochanteric valgization osteotomy and had not been converted at the time of the most recent followup. One patient had a culture-confirmed deep infection; this patient underwent resection arthroplasty and later had conversion surgery to THA.

The maximum LLD in our patients was 12 mm and the minimum was 4 mm, with a mean of 8 mm. All the patients with surviving hips were symptom free of LLD with or without appropriate shoe lift.

## Discussion

ONFH is a potentially disabling condition which may cause rapid femoral head collapse in young patients. The failure rates of various femoral head-preserving surgical procedures for an extensive ONFH lesion are high [1, 10, 12, 26, 32, 35, 45]. The reported success rate of TRO also is inconsistent and controversial even though some authors including Sugioka et al. reported TRO is an effective head-preserving procedure in younger patients [2, 3, 8, 9, 14–16, 21–23, 29, 31, 32, 39–42, 44]. We therefore questioned whether TRO with varization would prevent progression of collapse in extensive ONFH lesions and thus increase the survivorship clinically and radiographically, whether there



**Fig. 4A–D** (A) A preoperative AP radiograph shows Grades C and c2 osteonecrosis in a 32-year-old man. (B) A radiograph obtained 2 years after TRO shows a vertical stress fracture of the mid neck portion of the femur with minimal displacement. Radiographs obtained (C) 3 years and (D) 5.2 years after TRO show union of the previous stress fracture of the femoral neck.

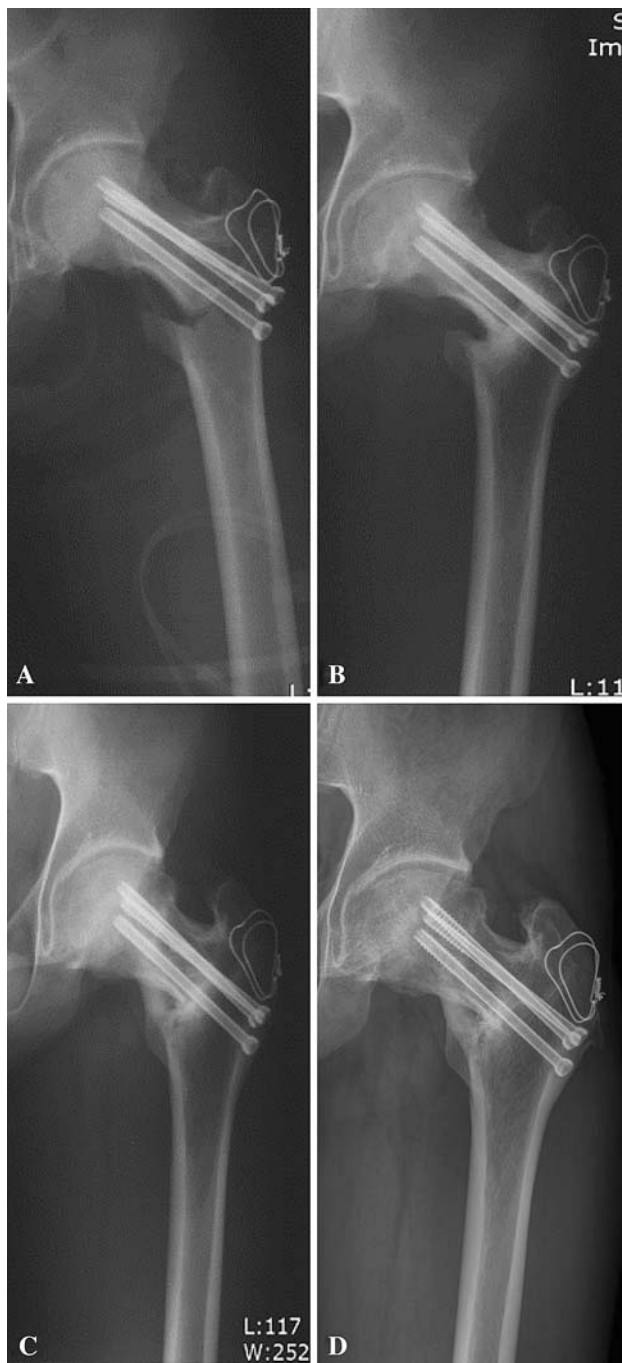
are any differences in the staging, extent, and location of the lesion, and we wished to determine preoperative and postoperative intact ratios between the progressive collapse and no collapse groups to see if these variables have any effect on progression of collapse. We also wished to determine the complication rate with this procedure and whether it would result in substantial LLD.

Limitations to our study include the lack of control patients with other treatment methods. Our patient population was selected and limited to patients in whom there was some intact bone either posteriorly or anteriorly on Sugioka's view and laterally on the AP view. Therefore,

the outcomes cannot be generalized to a population in whom the lesion extends onto the entire head with no intact bone. However, nontraumatic ONFH usually affects the anterior, superior, and lateral aspects, with the presence of some intact bone posteriorly [12]. Therefore, anterior TRO was performed in most of our patients. We used two types of fixation. Cannulated screws are mechanically weaker than a plate and screw construct [2, 22]. Chen et al. [6] reported fixation only with screws resulted in higher stress values in the proximal femur compared with the dynamic hip screw. Of 10 cases of varization-related complications (such as stress fracture, delayed union, and nonunion with progressive varus deformity), nine were associated with cannulated screw constructs and only one was associated with dynamic hip constructs with stress fracture of the femoral neck, which suggests the dynamic hip screw construct is a better choice of implant in this procedure. We also agree that gradual stimulation with prolonged partial weightbearing is essential for developing new trabeculae by remodeling because rapid full weightbearing may lead to degeneration of newly created articular cartilage in the weightbearing area of the femoral head owing to unre-modeled subchondral bone and supporting trabeculae [40]. Therefore, we believe one should wait for the appearance of remodeling of supporting trabeculae and medial cortical bone of the proximal femur, which can be achieved only by prolonged gradual application of partial loads (Fig. 5).

The principal concept of femoral osteotomy in the treatment of ONFH, first reported by Merle D'Aubigné et al. [24] in 1965, is that the necrotic femoral head focus is moved away from the major weightbearing portion underneath the acetabulum and weightbearing forces are transmitted to living areas of the femoral head. Sugioka et al. [42] introduced the new concept of rotation after trochanteric osteotomy to achieve transposition of the intact articular surface of the femoral head to the weightbearing area as an effective treatment for ONFH, Masuda et al. [23] reported 36 of 52 hips (69%) showed no evidence of progressive collapse of the femoral head during an average 5.1 years followup, whereas Hisatome et al. [14] reported survival of 80% for 25 hips at a mean of 6.4 years after TRO. However, the middle and long-term success rates from other studies, except for those from Japan, generally have been reported as unfavorable (Table 2). Forty four of 60 hips (73%) did not develop progressive collapse at a mean of 84 months after TRO and varization for ONFH in our series.

Possible reasons for high incidences of failure of TRO in those reports may be related to technical difficulty or improper surgical techniques including preservation of nutrient vessels, varus position of the proximal femur after osteotomy, fixation stability, and improper postoperative management [3, 8, 9, 31, 44]. Sugioka et al. [42]



**Fig. 5A–D** (A) An immediate postoperative AP view of a 23-year-old man with Ficat-Arlet Stage III shows fixation using three 6.5-mm cannulated screws with varus position. (B) A radiograph obtained 1 year after TRO showed complete union of the TRO. (C) A radiograph taken 4 years after TRO shows marked bony remodeling of the proximal femur. (D) A radiograph obtained 10 years after surgery shows no evidence of progression of collapse and mild osteophytes of the femoral head.

emphasized considerable care is required during osteotomy and rotation to preserve the vascular structure of the proximal femur, but in some reports which revealed high

rates of failure, postoperative vascular status of the femoral head was not described [8, 9, 44]. Dean and Cabanela [8] suggested early weightbearing after surgery, valgus position, and vascular compromise owing to a race-dependent difference in the anatomy of the hip capsule (ethnic origin) may have been factors in collapse of the femoral head after this procedure. Belal and Reichelt [3] considered TRO technically difficult and associated it with a high risk of late complications including progressive collapse, with failure of six of seven hips at a mean followup of 6.7 years. Rijnen et al. [31] also stated the technique in Caucasian patients was more demanding for TRO owing to the different dimension of the hips and larger body size and weight of the patients. Sugano et al. [39] reported a 56% success rate in 41 hips at mean followup of 6.3 years and considered skillful performance of the technique one of the important factors for success of TRO. We also experienced progressive varus deformity in seven of 44 hips (16%) with multiple cannulated screw fixation and negative uptake on the postoperative bone scan in one hip early in this series.

Another important factor correlating with a high failure rate of TRO may be improper selection of patients [9, 15–17, 21, 23, 25, 29, 32, 39]. Some authors, including Saito et al. and Sugano et al. [32, 39], have pointed out inappropriate patient selection in relation to the extent of necrosis of the femoral head and stage of necrosis. Eyb and Kotz [9] also concluded TRO is indicated only for young patients with good function and sectors of necrosis of the femoral head up to 90°. Sugioka [40] suggested greater than 1/3 of the extent of the intact femoral articular surface of the femoral head under the weightbearing portion of the acetabulum on the preoperative true lateral radiograph was indicated for TRO. Iwasada et al. [16] also reported no progressive collapse at the final followup in 30 hips (62%) at an average of 4.6 years after surgery and less than 30% ratio of the intact area of the articular surface on the preoperative lateral radiograph showed additional collapse. However, Onodera et al. [29] reported the extent of the newly established healthy weightbearing area as seen on the immediate postoperative radiograph was greater in the satisfactory group than in the unsatisfactory group. As per Sugioka et al. [41], the success rate was 93% in hips in which greater than 36% of the intact area of the total articular surface area of the femoral head corresponded to the acetabular weightbearing area on the postoperative AP radiograph. Sugioka [40] suggested intentional varus positioning combined with rotation is an important factor in obtaining a larger intact area for patients with advanced collapse and an extensive lesion. In our patients we were able to achieve a mean postoperative intact ratio of 33% in 60 hips (90%), although 50 hips (83%) had a preoperative intact area less than 33%. This is because the additional varization increased the postoperative intact area of the

**Table 2.** Results of TRO for ONFH in published studies

Study	Year of publication	Number of hips	Followup (years)*	Number of satisfactory results (%)
Sugioka et al. [42]	1982	128	2–9	98 (76%)
Sugioka [40]	1984	158	2–11	121 (76%)
Tooke et al. [44]	1987	18	1.6–6.1 (3.3)	4 (22%)
Eyb and Kotz [9]	1987	39	1.1–8.8 (4.1)	23 (9%)
Masuda et al. [23]	1988	52	1–10 (5.1)	39 (69%)
Saito et al. [32]	1988	15	2–14	9 (60%)
Sugioka et al. [41]	1992	295	3–16	132 (79%)
Sugano et al. [39]	1992	41	3–11 (6.3)	23 (56%)
Dean and Cabanela [8]	1993	18	(5)	3 (17%)
Belal and Reichelt [3]	1996	7	2.5–15.3	0 (0%)
Iwasada et al. [16]	1997	43	3–7.1 (4.6)	30 (62%)
Inao et al. [15]	1999	12	10–17.7 (13.2)	6 (50%)
Miyanishi et al. [25]	2000	125	(13.8)	97 (78%)
Hisatome et al. [14]	2004	25	3.4–12.4 (6.4)	20 (80%)
Onodera et al. [29]	2005	38	2–6.2 (4)	22 (58%)
Rijnen et al. [31]	2005	26	6.6–10 (8.7)	7 (27%)
Current study	2008	60	1.5–13 (7)	44 (73%)

\* Values expressed as ranges, with averages in parentheses; TRO = transtrochanteric rotational osteotomy; ONFH = osteonecrosis of the femoral head.

head below the acetabular weightbearing surface. Moreover, the average postoperative intact ratio of the collapse group was less than that of the noncollapse group (32% versus 42%). Our results agree with the fact that the important correlating factor in successful head preservation after TRO is maintenance of the ratio of the intact area of the femoral head to the acetabular weightbearing area greater than 36% postoperatively [25, 40, 41]. Our data showed Shimizu Grade c location is another risk factor for progressive collapse (Table 1). We observed no difference between Ficat Stages II and III even though some authors reported success also depends on stage [33, 39].

One of the major disadvantages of TRO is a high rate of postoperative complications [8, 9, 16, 31, 44]. Progressive varus deformity is the most frequent complication after TRO [8, 9, 16]. Eyb and Kotz [9] revealed a high incidence of complications (46%) including pseudarthrosis in five hips and increasing varus angulation in four of 39 hips at a mean followup of 49 months. Progressive varus deformity developed in 16% of our 44 hips and three hips were converted to THA. Progressive varus deformity was attributable to not only 6.5-mm cannulated screw fixation but also to the additional varus position of the proximal part of the femur despite prolonged partial or nonweightbearing after TRO. Another important postoperative complication is neck fracture [29, 32, 39]. Sugano et al. [39] reported failure was attributable to complications, including six (15%) postoperative fractures of the femoral

neck. Sugioka et al. [41] reported femoral neck fractures were observed in four of 474 hips after TRO and the hip complex obtained was disproportionate with respect to mechanical strength and weightbearing capability, resulting in subsequent neck fracture. There were three hips (5%) with delayed neck fracture in our series, two were fixed with 6.5-mm cannulated screws and one with a dynamic hip screw even though Sugano et al. [39] stressed using a more solid method of fixation and mechanical reinforcement of the neck than screw fixation. Delayed neck fracture in our patients seemed to be associated with varus positioning of the proximal femur after TRO, and the patients needed more careful postoperative rehabilitation for a longer time after TRO with varization.

LLD is associated with varus osteotomies around the neck of the femur. Bombelli [5] reported a 30° varus wedge osteotomy of the proximal femur produces an approximately 29- to 38-mm LLD. We fixed the neck at a higher level than the upper border of the lesser trochanter to decrease the amount of LLD (Fig. 2). The final LLD in our series was 4 to 12 mm. The possible cause of this small LLD could be attributable to fixing the primary osteotomy at a higher level even with the average varization of 20°.

The middle to long-term results of our patients who had TRO plus varization were encouraging, considering the extensive nature of their ONFH. Despite the associated complications and failures, it seems a worthwhile head-

preserving surgery for extensive lesions of ONFH. The postoperative intact ratio is a significant factor in postoperative survival after TRO.

**Acknowledgments** We thank Prof. Man Sik Park (Statistical Analysis of Medicine, Korea University, College of Medicine) for useful advice on the statistical analysis.

## References

- Athanasios E, Bassounas A, Apostolos H, Karantanas B, Dimitrios I, Fotiadis C, Konstantinos N, Malizos D. Femoral head osteonecrosis: volumetric MRI assessment and outcome. *Eur J Radiol.* 2007;63:10–15.
- Atsumi T, Kuroki Y. Modified Sugioka's osteotomy: more than 130° posterior rotation for osteonecrosis of the femoral head with large lesion. *Clin Orthop Relat Res.* 1997;334:98–107.
- Belal MA, Reichelt A. Clinical results of rotational osteotomy for treatment of avascular necrosis of the femoral head. *Arch Orthop Trauma Surg.* 1996;115:80–84.
- Berend KR, Gunneson EE, Urbaniak JR. Free vascularized fibular grafting for the treatment of postcollapse osteonecrosis of the femoral head. *J Bone Joint Surg Am.* 2003;85:987–993.
- Bombelli R. *Osteoarthritis of the Hip: Pathogenesis and Consequent Therapy.* Berlin, Germany: Springer-Verlag; 1976.
- Chen WP, Tai CL, Shih CH, Hsieh PH, Leou MC, Lee MS. Selection of fixation devices in proximal femur rotational osteotomy: clinical complications and finite element analysis. *Clin Biomech.* 2004;19:255–262.
- Cornell CN, Salvati EA, Pellicci PM. Long-term follow-up of total hip replacement in patients with osteonecrosis. *Orthop Clin North Am.* 1985;16:757–769.
- Dean MT, Cabanela ME. Transtrochanteric anterior rotational osteotomy for avascular necrosis of the femoral head: long-term results. *J Bone Joint Surg Br.* 1993;75:597–601.
- Eyb R, Kotz R. The transtrochanteric anterior rotational osteotomy of Sugioka: early and late results in idiopathic aseptic femoral head necrosis. *Arch Orthop Trauma Surg.* 1987;106:161–167.
- Fairbank AC, Bhatia D, Jinnah RH, Hungerford DS. Long-term results of core decompression for ischaemic necrosis of the femoral head. *J Bone Joint Surg Br.* 1995;77:42–49.
- Ficat RP. Idiopathic bone necrosis of the femoral head: early diagnosis and treatment. *J Bone Joint Surg Br.* 1985;67:3–9.
- Ganz R, Büchler U. Overview of attempts to revitalize the dead head in aseptic necrosis of the femoral head: osteotomy and revascularization. *Hip.* 1983:296–305.
- Harris WH. Traumatic arthritis of the hip after dislocation and acetabular fracture: treatment by mold arthroplasty. *J Bone Joint Surg Am.* 1969;51:737–755.
- Hisatome T, Yasunaga Y, Takahashi K, Ochi M. Progressive collapse of transposed necrotic area after transtrochanteric rotational osteotomy for osteonecrosis of the femoral head induces osteoarthritic change: mid-term results of transtrochanteric rotational osteotomy for osteonecrosis of the femoral head. *Arch Orthop Trauma Surg.* 2004;124:77–81.
- Inao S, Ando M, Gotoh E, Matsuno T. Minimum 10-year results of Sugioka's osteotomy for femoral head osteonecrosis. *Clin Orthop Relat Res.* 1999;368:141–148.
- Iwasada S, Hasegawa Y, Iwase T, Kitamura S, Iwata H. Transtrochanteric rotational osteotomy for osteonecrosis of the femoral head: 43 patients followed for at least 3 years. *Arch Orthop Trauma Surg.* 1997;116:447–453.
- Kaplan EL, Meier P. Nonparametric estimation from incomplete observations. *J Am Stat Assoc.* 1958;53:457–481.
- Katz RL, Bourne RB, Rorabeck CH, McGee H. Total hip arthroplasty in patients with avascular necrosis of the hip: follow-up observations on cementless and cemented operations. *Clin Orthop Relat Res.* 1992;281:145–151.
- Kerboul M, Thomine J, Postel M, Merle d'Aubigné R. The conservative surgical treatment of idiopathic aseptic necrosis of the femoral head. *J Bone Joint Surg Br.* 1974;56:291–296.
- Kim YH, Oh JH, Oh SH. Cementless total hip arthroplasty in patients with osteonecrosis of the femoral head. *Clin Orthop Relat Res.* 1995;320:73–84.
- Koo KH, Song HR, Yang JW, Yang P, Kim JR, Kim YM. Trochanteric rotational osteotomy for osteonecrosis of the femoral head. *J Bone Joint Surg Br.* 2001;83:83–89.
- Langlais F, Fourastier J. Rotation osteotomies for osteonecrosis of the femoral head. *Clin Orthop Relat Res.* 1997;343:110–123.
- Masuda T, Matsuno T, Hasegawa I, Kanno T, Ichioka Y, Kaneda K. Results of transtrochanteric rotational osteotomy for non-traumatic osteonecrosis of the femoral head. *Clin Orthop Relat Res.* 1988;228:69–74.
- Merle D'Aubigné R, Postel M, Mazabraud A, Massias P, Gueguen J. Idiopathic necrosis of the femoral head in adults. *J Bone Joint Surg Br.* 1965;47:612–633.
- Miyaniishi K, Noguchi Y, Yamamoto T, Irisa T, Suenaga E, Jingushi S, Sugioka Y, Iwamoto Y. Prediction of the outcome of transtrochanteric rotational osteotomy for osteonecrosis of the femoral head. *J Bone Joint Surg Br.* 2000;82:512–516.
- Mont MA, Hungerford DS. Non-traumatic avascular necrosis of the femoral head. *J Bone Joint Surg Am.* 1995;77:459–474.
- Musso ES, Mitchell SN, Schink-Ascani M, Bassett CA. Results of conservative management of osteonecrosis of the femoral head: a retrospective review. *Clin Orthop Relat Res.* 1986;207:209–215.
- Ohzono K, Saito M, Takaoka K, Ono K, Saito S, Nishina T, Kadowaki T. Natural history of nontraumatic avascular necrosis of the femoral head. *J Bone Joint Surg Br.* 1991;73:68–72.
- Onodera S, Majima T, Abe Y, Ito H, Matsuno T, Mianmi K. Transtrochanteric rotational osteotomy for osteonecrosis of femoral head. *J Orthop Sci.* 2005;10:367–373.
- Patterson RJ, Bickel WH, Dahlin DC. Idiopathic avascular necrosis of the head of the femur: a study of fifty-two cases. *J Bone Joint Surg Am.* 1964;46:267–282.
- Rijnen WC, Gardeniers JM, Westrek BM, Buma P, Schreurs BW. Sugioka's osteotomy for femoral-head necrosis in young Caucasians. *Int Orthop.* 2005;29:140–144.
- Saito S, Ohzono K, Ono K. Joint-preserving operations for idiopathic avascular necrosis of the femoral head: results of core decompression, grafting, and osteotomy. *J Bone Joint Surg Br.* 1988;70:78–84.
- Saito S, Saito M, Nishina T, Ohzono K, Ono K. Long-term results of total hip arthroplasty for osteonecrosis of the femoral head: a comparison with osteoarthritis. *Clin Orthop Relat Res.* 1989;244:198–207.
- Sakano S, Hasegawa Y, Torii Y, Kawasaki M, Ishiguro N. Curved intertrochanteric varus osteotomy for osteonecrosis of the femoral head. *J Bone Joint Surg Br.* 2004;86:359–365.
- Scher MA, Jakim I. Intertrochanteric osteotomy and autogenous bone-grafting for avascular necrosis of the femoral head. *J Bone Joint Surg Am.* 1993;75:1119–1133.
- Shimizu K, Moriya H, Akita T, Sakamoto M, Suguro T. Prediction of collapse with magnetic resonance imaging of avascular necrosis of the femoral head. *J Bone Joint Surg Am.* 1994;76:215–223.
- Sugano N, Atsumi T, Ohzono K, Hotokebushi R, Takaoka K. The 2001 revised criteria for diagnosis, classification, and staging of



- idiopathic osteonecrosis of the femoral head. *J Orthop Sci.* 2002;7:601–605.
38. Sugano N, Ohzono K, Masuhara K, Takaoka K, Ono K. Prognostication of osteonecrosis of the femoral head in patients with systemic lupus erythematosus by magnetic resonance imaging. *Clin Orthop Relat Res.* 1994;305:190–199.
  39. Sugano N, Takaoka K, Ohzono K, Matsui M, Saito M, Saito S. Rotational osteotomy for non-traumatic avascular necrosis of the femoral head. *J Bone Joint Surg Br.* 1992;74:734–739.
  40. Sugioka Y. Transtrochanteric rotational osteotomy in the treatment of idiopathic and steroid-induced femoral head necrosis, Perthes' disease, slipped capital femoral epiphysis, and osteoarthritis of the hip: indications and results. *Clin Orthop Relat Res.* 1984;184:12–23.
  41. Sugioka Y, Hotokebuchi T, Tsutsui H. Transtrochanteric anterior rotational osteotomy for idiopathic and steroid-induced necrosis of the femoral head: indications and long-term results. *Clin Orthop Relat Res.* 1992;277:111–120.
  42. Sugioka Y, Katsuki I, Hotokebuchi T. Transtrochanteric rotational osteotomy of the femoral head for the treatment of osteonecrosis: follow-up statistics. *Clin Orthop Relat Res.* 1982;169:115–126.
  43. Takatori Y, Kokubo T, Ninomiya S, Nakamura S, Morimoto S, Kusaba I. Avascular necrosis of the femoral head: natural history and magnetic resonance imaging. *J Bone Joint Surg Br.* 1993;75:217–221.
  44. Tooke SM, Amstutz HC, Hedley AK. Results of transtrochanteric rotational osteotomy for femoral head osteonecrosis. *Clin Orthop Relat Res.* 1987;224:150–157.
  45. Urbaniak JR, Coogan PG, Gunneson EB, Nunley JA. Treatment of osteonecrosis of the femoral head with free vascularized fibular grafting: a long-term follow-up study of one hundred and three hips. *J Bone Joint Surg Am.* 1995;77:681–694.