

Stepped Osteotomy of the Trochanter for Stable, Anatomic Refixation

Johannes D. Bastian MD, Alexandra T. Wolf MD,
Tobias F. Wyss MD, Hubert P. Nötzli MD

Published online: 9 December 2008
© The Association of Bone and Joint Surgeons 2008

Abstract Refixation of a trochanteric osteotomy carries a high complication rate. To enhance stability and facilitate anatomic reduction of the trochanteric fragment, we have introduced a stepped osteotomy. Between April 2006 and June 2007, we performed surgical hip dislocations using the modified trochanteric osteotomy combined with a relatively aggressive rehabilitation program. Full weight-bearing was allowed at a mean of 42 days (range, 33–54 days). The minimum followup was 8 months (median, 13 months; range, 8–24 months). Postoperative radiographs were assessed prospectively for consolidation or the appearance of malreduction/nonunion/malunion of the osteotomy and heterotopic ossification. In 110 of 113 hips, the trochanteric osteotomy healed in the anatomic position. Two patients had a trochanteric delayed union with loss of anatomic position, and one additional patient underwent revision surgery for a pseudarthrosis and cranial migration of the trochanteric fragment. All three complications related to healing occurred in the first 60 patients when the step height was 3 to 4 mm. After increasing the step heights to 6 mm, we observed no healing complications. Despite more aggressive postoperative mobilization, the incidence

of malunion or nonunion related to the new stepped osteotomy is low and approaches zero for steps of 6 mm. It is now our technique of choice.

Level of Evidence: Level IV, therapeutic study. See the Guidelines for Authors for a complete description of levels of evidence.

Introduction

In the classic technique of trochanteric detachment for hip arthroplasty, the origin of the vastus lateralis muscle is released from the trochanteric fragment [3]. The resulting unidirectional muscle forces acting on the fragment occasionally lead to nonunion and/or cranial migration of the fragment and subsequent weakening of the abductor muscle force [15]. With the introduction of the “digastrique” osteotomy in which the origin of the vastus lateralis muscle remains attached to the fragment [12], the gluteal force could be counteracted. Additionally, the resultant force of the gluteus medius and vastus lateralis muscles exerts a compressive moment on the plane of the osteotomy [5]. Using this technique, the incidence of superior migration of the greater trochanter more than 1 cm has decreased to 0% averaging 1.5 mm (range, 0–8 mm) [15]. With this innovation, the application of the transtrochanteric approach has expanded from primary THA to revision hip arthroplasty [11], to fracture fixation of the acetabulum [4, 16] or the femoral head [9], and to the treatment of femoroacetabular impingement [8]. However, nonunion and malunion of the trochanteric osteotomy, even in patients with good bone stock, are still not infrequent (approximately 5%) [1, 7]. Because of these concerns about nonunion/malunion and because precise reduction is often difficult with a flat osteotomy, we introduced a stepoff in the osteotomy, which

Each author certifies that he or she has no commercial associations (eg, consultancies, stock ownership, equity interest, patent/licensing arrangements, etc) that might pose a conflict of interest in connection with the submitted article.

Each author certifies that his or her institution either has waived or does not require approval for the human protocol for this investigation and that all investigations were conducted in conformity with ethical principles of research.

J. D. Bastian, A. T. Wolf, T. F. Wyss, H. P. Nötzli (✉)
Department of Orthopaedic Surgery and Traumatology,
Spital Netz Bern-Ziegler, Morillonstrasse 75–91, 3001 Bern,
Switzerland
e-mail: hubert.noetzli@spitalnetzbern.ch

does not encroach on the bed of the circumflex vessel. In addition to providing a key to reduction, the step would theoretically resist tensile and rotational forces. Stability of the fragment may also speed union and rehabilitation.

The purposes of our study were to: (1) determine the rate of radiographic and clinical healing of this new osteotomy; (2) establish the rate of associated complications such as heterotopic ossification; and (3) ascertain the frequency with which patients experienced pain related to the osteotomy or hardware.

Materials and Methods

We prospectively followed all 109 patients with 113 surgical hip dislocations performed for the treatment of femoroacetabular impingement and treated with stepped osteotomy between April 2006 and June 2007. There were 70 male and 39 female patients; 59 of the hips were on the right and 54 on the left. The mean age of the patients was 28 years (range, 16–48 years). Sixteen of the 113 hips had the following previous surgeries: surgical hip dislocation (three), shaping of the femoral head-neck junction through an anterior approach (three), hip arthroscopy (three), intertrochanteric osteotomy (two), periacetabular osteotomy with femoral osteotomy (two), open reduction and internal fixation of a femoral head fracture (two), and transposition of the psoas muscle (one). The remaining 97 hips had no previous surgery. All 109 patients were available for complete followup evaluation. The minimum followup period was 8 months (median, 13 months; range 8–24 months) for the entire group of 113 trochanteric osteotomies.

All surgery was performed by one surgeon (HPN). The patient was positioned in the lateral decubitus position using a method of trunk stabilization described by others [6]. The straight direct lateral 18- to 23-cm skin incision was centered over the greater trochanter and made with the hip fully extended. One-third of the incision extended proximal to the tip of the greater trochanter. The iliotibial band was split longitudinally, proximally following the anterior border of the gluteus maximus muscle according to the description of Henry [10]. The interval between the gluteus maximus and the gluteus medius was developed (Fig. 1). The gluteus maximus muscle was retracted posteriorly and the bursal tissue over the greater trochanter was incised longitudinally to expose the structures attached to the posterior aspect of the greater trochanter. The posterior origin of the vastus lateralis fascia, including connections to the tendon of the gluteus maximus and linea aspera, was released and the muscle lifted from the bone epiperiosteally, leaving the tendinous origin from the tubercle intact (Fig. 2).

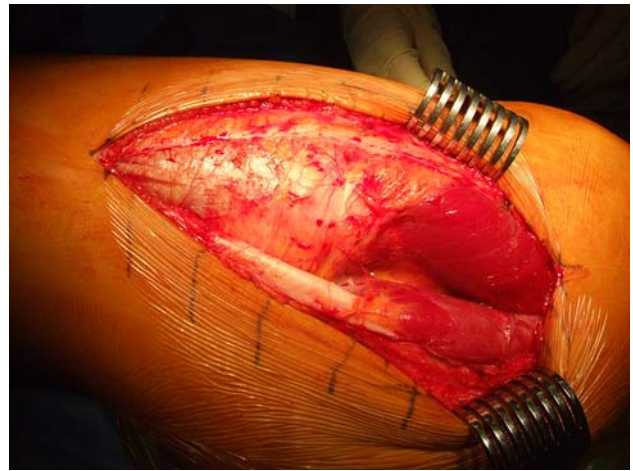


Fig. 1 Visualization of the interval between the gluteus maximus and the gluteus medius in the left hip is shown.

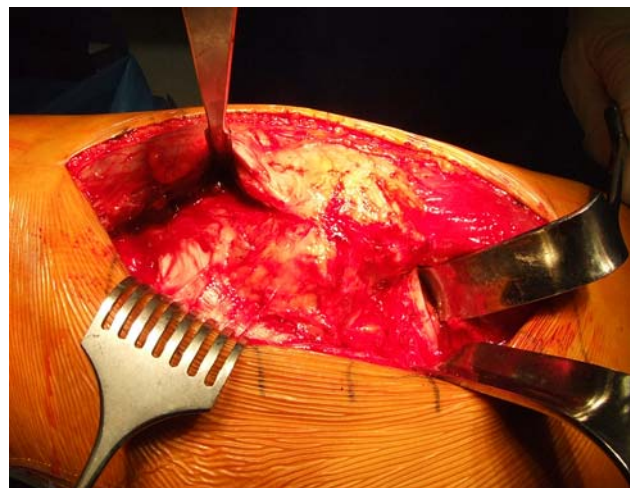


Fig. 2 The posterior aspect of the greater trochanter and the posterior borders of the vastus lateralis and the gluteus medius muscles are defined in internal rotation of the joint. The vastus lateralis muscle has been detached from the femur distal to the innominate tubercle from its posterior insertion and the interval between the gluteus medius and piriformis as well as the gluteus minimus has been defined.

The stepped osteotomy of the trochanter has the same start and end points as the flat osteotomy. It begins in the posterosuperior tip of the greater trochanter and ends distally 10 to 15 mm distal to the lateralis tubercle. For reference, the line of osteotomy was inscribed in the periosteum with a knife. The first (proximal) segment of the osteotomy extended distally approximately three-fifths of the length of the greater trochanter and ended lateral to the plane of a straight osteotomy (Fig. 3A–B). The second (distal) segment of the osteotomy started below the origin of the vastus lateralis and extended proximally to a point medial to the plane of a straight osteotomy and directly medial to the distal end of the first cut (Fig. 4A–B).

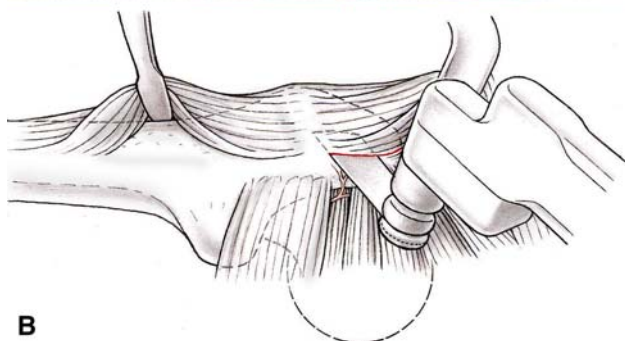
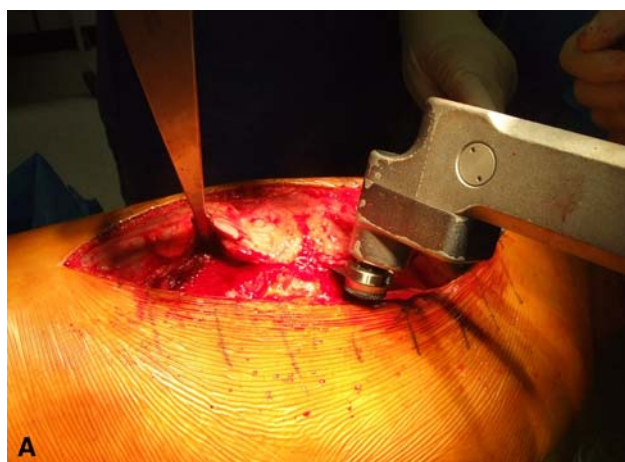


Fig. 3A–B (A) Intraoperative and (B) schematic views show the first osteotomy, which starts at the tip of the greater trochanter. The sawing stops at approximately three-fifths of the intended longitudinal length of the trochanteric fragment.

These two cuts were then connected by a third, transverse cut creating a step in the osteotomy (Fig. 5A–B).

At the beginning of our series, the distal cut was set in approximately 3 mm, but after 60 cases, we increased the inset to 6 mm. In that circumstance, the top of the distal cut lies 6 mm medial to the bottom of the proximal cut (Fig. 4A–B). The full osteotomy was then completed by connecting the first cuts with a thin, straight 6-mm osteotome (Accuratus, Bern, Switzerland) (Fig. 5A–B). During the second and third cuts, the position of the proximal was marked by placing a free saw blade into the cut. During the third cut, the osteotome simply followed the distal edge of that saw blade. Generally, the fragment popped free with the third cut. If not, the second cut was completed with another thin osteotome. The third cut traversed slightly (15° to 20°) distally as one cut from back to front. This ensured the step would resist the tendency to displace the fragment anteriorly as the anterior part of the gluteus medius pulls the fragment, especially in flexion into the anterior direction.

In all other aspects, this technique follows principles described in other papers on surgical dislocation. When creating the osteotomies with the oscillating saw, one

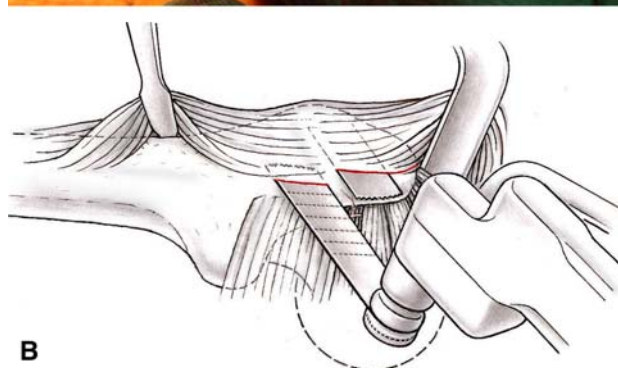



Fig. 4A–B (A) Intraoperative and (B) schematic views showing the second osteotomy, which starts at the distal end of the first osteotomy with the section plane parallel to the first osteotomy but with a medial displacement of approximately 6 mm. A saw blade has been positioned in the first osteotomy working as a placeholder and a visual indicator for the second section plane.

should keep in mind (1) the correct anteroposterior plane for the osteotomy lies parallel to the lateral surface of the trochanter; (2) the thickness of the trochanteric fragment is determined by the curvature of the tip of the greater trochanter and can therefore be quite variable; and (3) for protection of the deep branch of the medial circumflex artery proximally, the osteotomy should never start medial to the tip of the trochanter nor enter the trochanteric fossa. Thus, when the tip is unusually curved or hook-shaped, the proximal part of the fragment may be thin.

Subsequently, the stepped trochanteric fragment was flipped anteriorly using a small Hohmann retractor placed over the anterior edge of the stable trochanter (Fig. 6A–B). The surgery continues in the conventional manner, and the fragment was always fixed with two 3.5-mm cortical screws (Fig. 7A–B). Because the osteotomy entered through the tip of the trochanter, the tendinous insertion of the gluteus medius was split over 1 to 2 cm, leaving the majority of the tendon on the fragment. The small slip remaining with the femur was sewn back to the tendon during closure.

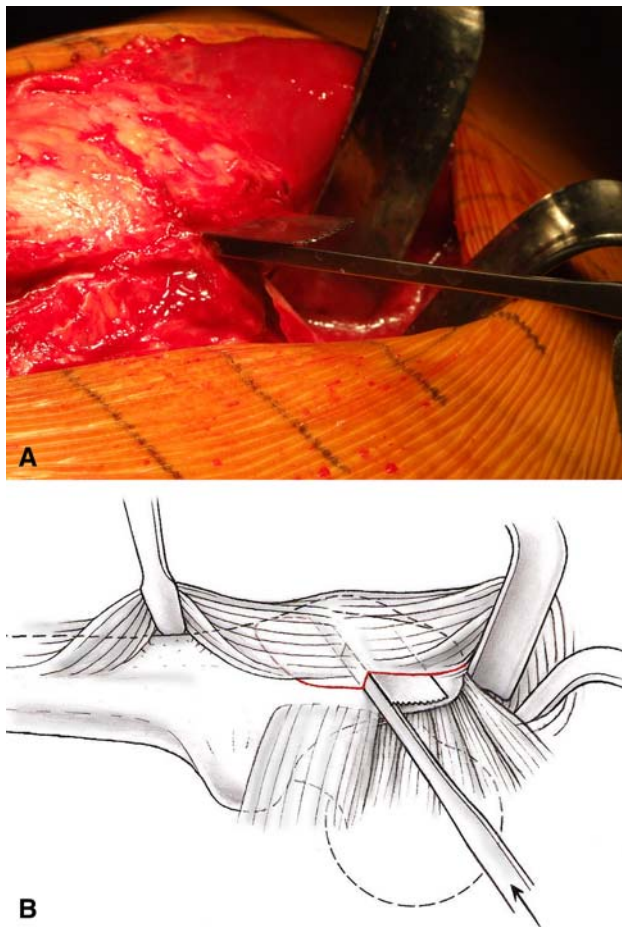


Fig. 5A–B (A) Intraoperative and (B) schematic views show completion of the osteotomy. Both section planes are connected by a 6-mm osteotome, which follows the undersurface of the saw blade positioned in the first osteotomy.

For the first 6 weeks, the rehabilitation protocol was as follows. The patients were mobilized with crutches and partial weightbearing of one-fourth of their body weight for 5 weeks. Patients with no pain were then allowed to increase weightbearing to full body weight but had to stay on crutches until the first consultation in our outpatient clinic. Active hip motion was restricted to 60° and passive motion to 90°. Active abduction and passive adduction were prohibited. Stretching of the quadriceps and isometric muscle training of quadriceps and hamstrings were encouraged. All patients without contraindication against nonsteroidal anti-inflammatory drugs received ibuprofen to prevent heterotopic ossifications for 14 days and low-molecular-weight heparin for 6 weeks as deep venous thrombosis prophylaxis.

In case of radiographic and clinical evidence of stable consolidation of the trochanteric osteotomy at the first followup evaluation at approximately 6 weeks postsurgery, the patients (assisted by the physiotherapists) started full weightbearing and strengthening of the abductor muscles.

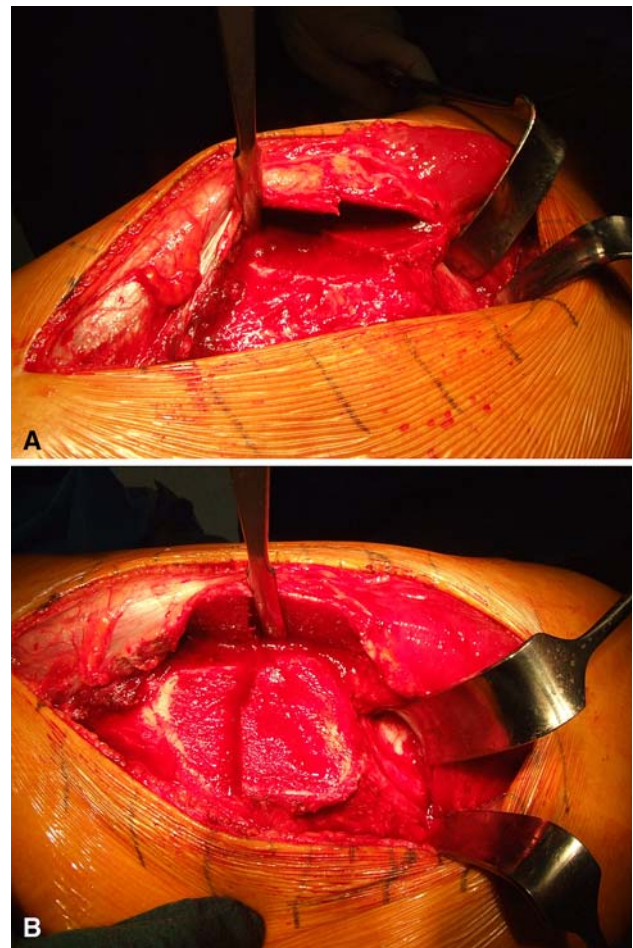


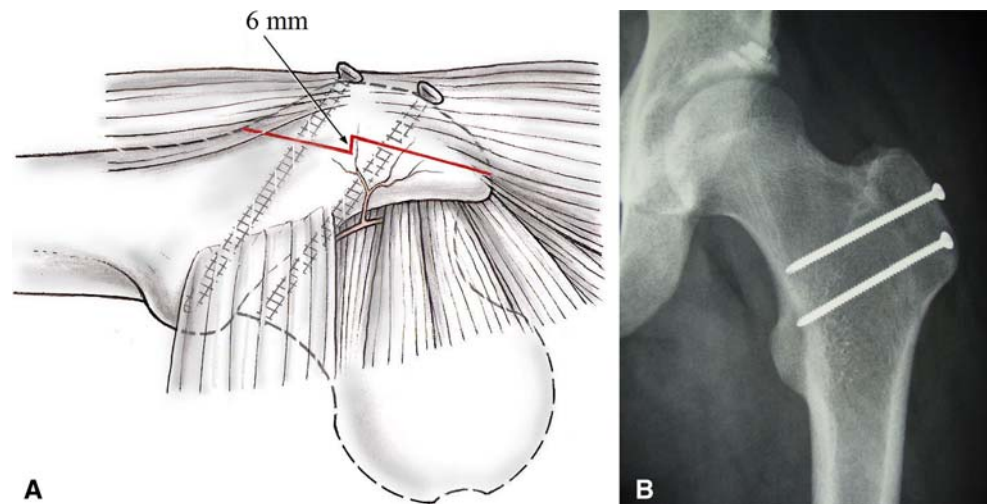
Fig. 6A–B (A) The remaining fibers of the gluteus medius muscle and the vastus lateralis muscle are released from the stable trochanter and the posterior margin of the femoral shaft, respectively. Subsequently, the trochanteric fragment is flipped anteriorly using a small Hohmann retractor placed over the anterior edge of the stable trochanter. (B) The osteotomy is fully visualized with the gluteus medius and minimus muscles and vastus lateralis muscle attached to the trochanteric fragment.

The occurrence of any complications related to the trochanteric osteotomy and to the hip dislocation itself was assessed.

The clinical assessments continued typically in 6- to 8-week intervals until the patients were back to their normal daily activities without limitation. In some patients, the first visit with radiographs was earlier than 6 weeks as a result of constraints in the scheduling system and because some patients tripped, fell, or otherwise violated the activity guidelines.

A standard anteroposterior and a crosstable view were taken postoperatively during the hospital stay and a hip anteroposterior view at the first outpatient visit, typically after 6 weeks (range, 4–7 weeks). An anteroposterior pelvis view and a crosstable or Dunn view were repeated roughly 1 year after surgery. One surgeon (JDB) not

Fig. 7A–B (A) Schematic and (B) radiographic anteroposterior views show the anatomic reduction and fixation of the trochanteric fragment after a stepped trochanteric osteotomy.



involved in the care of the patients examined the radiographs for signs of healing of the osteotomy (disappearance of the visible osteotomy), nonunion (a persistent visible osteotomy, sclerosis of the osteotomy lines, gap formation), or instability of the trochanteric fragment (tipping of the fragment, radiolucency around the screws, bending of the screws, heterotopic ossifications around the screw heads, cranial migration of the fragment). This radiographic evaluation was used as a direct measure for healing of the trochanteric osteotomy. Additionally, the radiographs were assessed for signs of heterotopic ossification using the classification of Brooker et al. [2]. In patients with delayed healing, the patients were followed until definitive healing. All complications related to the trochanteric osteotomy and to the hip dislocation procedure were recorded.

During the first clinical assessments, absence of residual pain, joint mobility without discomfort over the trochanteric region, and no pain with palpation over the trochanter were used as clinical signs of osteotomy healing. At that time, the abductor strength was usually not evaluated. Residual rest pain, pain with pressure on the fragment, or pain with active abduction was seen as a sign of probable instability.

Results

One hundred ten of 113 (97%) trochanteric osteotomies showed radiographic and clinical signs of consolidation at the initial visit, ie, at a median followup of 42 days (range, 33–54 days). These osteotomies all healed without cranial migration of the fragment or other displacement from an anatomic position. Signs of fragment instability and delayed union were evident in two patients: bending of the two cortical screws in one (consolidation at 72 days) and

tipping of the fragment with the appearance of a 2-mm gap distally in the other (consolidation at 70 days). In the third patient, trochanter instability of the osteotomy with pain, a 2-mm gap, and 3-mm cranial displacement of the fragment was treated by revision surgery and refixation of the trochanteric fragment at 10 weeks (consolidation at 112 days). All three complications related to the trochanteric osteotomy happened in the first 60 cases when the step in the osteotomy was 3 to 4 mm. All three patients with delayed union of the osteotomy had accidentally placed full weight on the limb as a result of missteps or falls in the early postoperative period. No delayed union or malunion occurred after the step height was enlarged to 6 mm.

We observed heterotopic ossification in seven of 113 hips, six Class I (according to Brooker et al. [2]) and one Class II. Five of these cases of ossification occurred in the group of smaller steps and two in the group of larger steps, and none was associated with delayed union or symptoms.

Seventy-six of 109 patients experienced some discomfort around the greater trochanter (eg, when lying on the operated side on a hard surface) or showed signs of trochanteric bursitis of variable degrees. In all 76 patients, we removed the hardware after a median of 5 months (range, 2–18 months). Thirteen of these 76 additionally underwent excision of a bursa around the screw heads at the time of screw removal. After hardware removal and additional excision of the bursa, if indicated, 42 of the 76 patients were completely pain-free. Eighteen reported considerably less discomfort. In 11 patients, residual pain around the hip was present, mostly a mixture of trochanteric, muscle, and groin pain. In three of these, diagnostic intraarticular infiltration with a local anesthetic was performed and led to complete absence of pain indicating the reason for residual pain was not the trochanter, but the joint itself.

Three patients had perioperative complications for which they underwent additional surgery: evacuation

of a hematoma in two patients and reclosure of the skin for breakage of the sutures in one. There were no relevant intraoperative complications, no neurovascular complications, and no infections.

Discussion

We introduced a stepped trochanteric osteotomy to improve the initial stability of the fixation and prevent subsequent migration of the fragment. We therefore: (1) determined the rate of radiographic and clinical healing of this new osteotomy; (2) established the rate of associated complications such as heterotopic ossification; and (3) ascertained the frequency with which patients experienced pain related to the osteotomy or hardware.

The major limitation of the study is the difficulty of measuring time to union with meaningful precision. Many subjects did not have postoperative radiographs before 6 weeks because this was the initial clinical routine. Furthermore, healing is not always easy to ascertain and is subject to interobserver variability; we had only one individual look at these films. The discovery that some osteotomies united early is based on a group that came in early or inadvertently walked on the limb and then were found to have apparent union on early radiographs and examination. This initial impression was confirmed by subsequent radiographs showing no adverse changes 6 to 12 months later. Proof that the stepped osteotomy reliably unites before 6 weeks will require a different study and human subject approval.

The rate of nonunion after trochanteric osteotomy with release of the vastus origin varies between 4% [5] and 23% [14]. Reported union rates with a trochanteric “flip” are close to 100%. For example, in a case series of 280 surgical hip dislocations with a conventional, flat osteotomy, five nonunions (1.8%) were treated surgically (Beck M. Mid-term results of surgical hip dislocation. Bernese Hip Symposium, Bern; March 15–17, 2007). This improvement is attributed to retention of the vastus lateralis origin, but postoperative weightbearing is still restricted for 6 to 8 weeks [6] as a result of uncertainty about stability of the trochanteric fragment. Schneeberger et al. [15] reported an average cranial migration of the fragment of 1.3 ± 2.2 mm (range, 0–8 mm) in 39 patients with a “digastrique” osteotomy and a traditional rehabilitation routine. Although trochanter displacement of less than 10 mm will not impair the power of the abductor muscles [13], cranial migration demonstrates the initial instability of the flat osteotomy.

The stepped osteotomy essentially eliminated cranial migration of the fragment (0 mm in 112 of 113 osteotomies). After increasing the step to 6 mm, the rates of migration and malunion were 0%. Patients were allowed to

initiate full weightbearing and strengthening of the abductor muscles at a relatively early date. If, as these observations suggest, a step in the osteotomy creates more stable fixation of the trochanteric fragment without additional hardware, it should be possible to reduce the period of restricted motion and weightbearing to less than the current 6 to 8 weeks. Heterotopic ossification occurred in seven of 109 patients. In three of these seven patients, prophylactic nonsteroidal anti-inflammatory drugs were stopped as a result of gastrointestinal symptoms or renal side effects. One of the four patients receiving nonsteroidal anti-inflammatory drugs had a postoperative hematoma. The etiology of heterotopic ossifications in the other three remains unclear. However, none of these seven cases of heterotopic ossification was associated with clinical symptoms. Interestingly, five of the seven ossifications appeared in the group with the smaller step, which may suggest more micromotion compared with the fragment fixed with a bigger step.

In our experience, trochanteric osteotomies of all kinds are associated with a certain frequency of discomfort related to the hardware. The reason for this has not been fully elucidated. Impingement on the iliotibial band, foreign body reaction, and altered bone stress patterns are all possible factors. We suspect age, activity level, and absence of overlying fat in athletes contribute as well. At the time of initial consent, patients are informed that postoperative hardware removal may be indicated. In young patients, we recommend early screw removal because later on, the procedure is commonly complicated by bone overgrowth and screw breakage. We now usually remove hardware under fluoroscopy through a stab incision under regional anesthesia as an outpatient procedure.

Surgical dislocation for femoroacetabular impingement typically is performed in young, active individuals who cannot participate in occupational or athletic activities as a result of painfully restricted flexion/internal rotation. This group in particular will benefit if the time required to achieve normal hip motion and abductor muscle strength is reduced.

Execution of the step osteotomy is more demanding than a flat cut, especially for surgeons unfamiliar with a basic trochanteric flip. The method, however, does have offsetting technical advantages over a uniplanar cut. The proximal limb can be more shallow, permitting one to stay out of the trochanteric fossa in cases in which the tip of the trochanter is unusually hooked or small. Reduction of the fragment is easier. The step provides a clear “read” and, in contrast to the flat osteotomy, the fragment does not rotate or slip proximally when held for screw placement.

Acknowledgments We thank Prof John M. Clark, Seattle, WA, for his helpful comments on the paper and for his support to complete the manuscript in proper English.

References

- Bal BS, Kazmier P, Burd T, Aleto T. Anterior trochanteric slide osteotomy for primary total hip arthroplasty: review of nonunion and complications. *J Arthroplasty*. 2006;21:59–63.
- Brooker AF, Bowerman JW, Robinson RA, Riley LH Jr. Ectopic ossification following total hip replacement: incidence and a method of classification. *J Bone Joint Surg Am*. 1973;55:1629–1632.
- Charnley J, Ferreiraade S. Transplantation of the greater trochanter in arthroplasty of the hip. *J Bone Joint Surg Br*. 1964;46:191–197.
- Ebraheim NA, Patil V, Liu J, Haman SP. Sliding trochanteric osteotomy in acetabular fractures: a review of 30 cases. *Injury*. 2007;38:1177–1182.
- English TA. The trochanteric approach to the hip for prosthetic replacement. *J Bone Joint Surg Am*. 1975;57:1128–1133.
- Espinosa N, Beck M, Rothenfluh DA, Ganz R, Leunig M. Treatment of femoro-acetabular impingement: preliminary results of labral refixation: surgical technique. *J Bone Joint Surg Am*. 2007;89:36–53.
- Frankel A, Booth RE Jr, Balderston RA, Cohn J, Rothman RH. Complications of trochanteric osteotomy: long-term implications. *Clin Orthop Relat Res*. 1993;288:209–213.
- Ganz R, Gill TJ, Gautier E, Ganz K, Krugel N, Berlemann U. Surgical dislocation of the adult hip a technique with full access to the femoral head and acetabulum without the risk of avascular necrosis. *J Bone Joint Surg Br*. 2001;83:1119–1124.
- Henle P, Kloen P, Siebenrock KA. Femoral head injuries: which treatment strategy can be recommended?. *Injury*. 2007;38:478–488.
- Henry AK. *Extensile Exposure Applied to Limb Surgery*. Baltimore: Williams & Wilkins; 1952.
- Jando VT, Greidanus NV, Masri BA, Garbuz DS, Duncan CP. Trochanteric osteotomies in revision total hip arthroplasty: contemporary techniques and results. *Instr Course Lect*. 2005;54:143–155.
- Mercati E, Guary A, Myquel C, Bourgeon A. A postero-external approach to the hip joint: value of the formation of a digastric muscle [in French]. *J Chir (Paris)*. 1972;103:499–504.
- Nutton RW, Checketts RG. The effects of trochanteric osteotomy on abductor power. *J Bone Joint Surg Br*. 1984;66:180–183.
- Ritter MA, Gioe TJ, Stringer EA. Functional significance of nonunion of the greater trochanter. *Clin Orthop Relat Res*. 1981;159:177–182.
- Schneeberger AG, Murphy SB, Ganz R. The trochanteric flip osteotomy [in German]. *Oper Orthop Traumatol*. 1997;9:1–15.
- Siebenrock KA, Gautier E, Ziran BH, Ganz R. Trochanteric flip osteotomy for cranial extension and muscle protection in acetabular fracture fixation using a Kocher-Langenbeck approach. *J Orthop Trauma*. 1998;12:387–391.