

Delayed surgical treatment of supracondylar humerus fractures in children using a medial approach

Abdullah Eren · Melih Güven · Bülent Erol ·
Murat Çakar

Received: 25 June 2007 / Accepted: 17 November 2007 / Published online: 3 January 2008
© EPOS 2007

Abstract

Purpose The appropriate management of supracondylar humerus fractures in children is frequently delayed due to various factors, and there is still no agreement on the treatment of choice. The purpose of this study was to evaluate the effects of delayed treatment of displaced supracondylar humerus fractures on the treatment results and complication rate.

Methods A total of 31 children with supracondylar humerus fractures who had not received adequate treatment for their displaced fractures were included in this study. The conditions leading to delayed treatment mainly included severe swelling or skin problems around the elbow and the health facility problems unique to our district. The mean delaying time was 6 days (range 2–19 days). There were 24 males and 7 females with a mean age of 7 years (range 1–13 years). The fractures were classified as type III-A ($n = 15$; 48%) and type III-B ($n = 16$; 52%) according to Gartland. Surgical treatment consisting of sentiment manual reduction through a medial approach and percutaneous cross-pinning was applied to all. No image intensifier was used during the

procedures. A long-arm splint was used for post-operative immobilization.

Results The average hospital stay was 2 days (range 1–3 day) and the patients were followed clinically and radiographically for an average of 4 years (range 2–11 years). Pins were removed at the end of the third week post-operatively, at which time the range of motion exercises were begun. None of the patients required physical therapy and full functional recovery was achieved within 3 months in 29 (93.5%) patients and within 5 months in the remaining 2 (6.5%). Two (6.5%) pre-operative nerve injuries (1 interosseous, 1 ulnar) were resolved spontaneously within 3 months post-operatively. At the final follow-up, 7 (22.5%) patients had cubitus varus deformity. Except for 2 (6.5%) pin-tract infections, which were resolved by oral antibiotics and pin removal, none of the patients had early or late complications, not even neurological deficit or myositis ossificans.

Conclusions Delayed presentation of displaced supracondylar humerus fractures in children did not increase complication rates or unsatisfactory results following an open reduction. Medial approach and cross-pinning is an effective and reliable treatment method for these fractures.

A. Eren · M. Güven (✉)
2nd Orthopaedic and Traumatology Clinic,
Göztepe Training and Research Hospital,
Göztepe, Istanbul, Turkey
e-mail: maguven2000@gmail.com

B. Erol
Department of Orthopaedics and Traumatology,
The Hospital of University of Marmara, Istanbul, Turkey

M. Çakar
Orthopaedics and Traumatology Clinic,
Bağcılar Training and Research Hospital,
Bağcılar, Istanbul, Turkey

Keywords Children · Supracondylar humerus fractures · Delayed treatment · Open reduction · Complications

Introduction

Supracondylar humeral fractures are usually treated as an emergency–urgency manner in children. Over the past several decades there has been a shift from nonoperative management to surgical stabilization for these fractures. The rationale offered to justify such emergent treatment

has traditionally been to minimize swelling in an effort to decrease the risk of perioperative complications—such as compartment syndrome, infection and nerve injuries—and to reduce the likelihood that a conversion to an open reduction will be needed [1–3]. However, some authors have found no significant difference between early and delayed treatment of supracondylar humeral fractures in children with regard to perioperative complications and the need for open reduction [4, 5].

Severe swelling or skin problems around the elbow are the universally accepted conditions that delay a surgical intervention following a supracondylar humeral fracture in children. In developing countries, problems relating to the disorganized health insurance system and some traditional incorrect interventions (by some non-doctor personnel) unique to that specific country can also significantly influence the time interval between the injury and the definitive treatment. Under these circumstances, the management of a late-presented supracondylar humerus fracture becomes an inevitable obligation for the orthopedic surgeon.

Closed reduction with percutaneous crossed K-wires has gained support as the preferred method of treatment for supracondylar humerus fractures in children [1, 6–9]. If attempts at closed reduction fail, then open reduction of the fracture followed by cross-pinning should be considered. Open reduction may also frequently be required in late-presented supracondylar humeral fractures. The purpose of this study was to present the long-term results of patients who underwent delayed surgery for their supracondylar humerus fractures by means of the open medial approach.

Materials and methods

The patient database at the Ministry of Health Göztepe Training and Research Hospital Orthopaedic Clinics was searched for the time period January 1992 to February 2005 for patients who had undergone surgery for supracondylar humerus fractures. Hospital records and radiographs were reviewed and only those patients who had delayed treatment for a type-III supracondylar fracture, as defined by the lack of cortical contact between the proximal and distal fragments, were included in the study. Exclusion criteria were an age of greater than 18 years, open fracture, nondisplaced fracture, metabolic bone disease, a dysvascular extremity and ipsilateral upper-extremity fracture.

There were 24 males and 7 females with a mean age of 7 years (range 1–13 years). All fractures were extension type and classified as type III-A ($n = 15$; 48%) and type III-B ($n = 16$; 52%), according to Wilkins modification of Gartland classification [10]. None of the patients in this

series had received adequate treatment for their displaced supracondylar humerus fracture within the first 24 h following injury.

Hospital charts were reviewed to determine the date of injury, time of injury and arrival at our hospital (emergency department or outpatient clinics), time of operation, pre- and post-operative neurological and vascular examination, other pertinent physical examination findings (i.e., closed vs. open injury), exact description of operation, perioperative complications, total number of hospital days and date of resolution of any neurological or vascular compromise. The conditions leading to delayed treatment were also searched in detail. This investigation included the conditions leading to delay, both before and after the admission of the patients to our hospital. All attempts to reduce these fractures closely in other centers or in our hospital emergency department were also recorded.

Pre-operative radiographs and hospital records were evaluated to determine the type-III nature of the fractures, the classification of those fractures into extension- and flexion-type injuries, and the direction of displacement in the extension type into posterolateral and posteromedial categories. The radiographs, made at the time of injury and/or at the delayed admission to our hospital, were used for the radiographic evaluation (Figs. 1, 2). Due to lack of a C-arm machine in the operating room, no more attempts were performed for close reduction of the fractures. All patients in this series received a surgical treatment consisting of manual reduction through a medial approach and percutaneous cross-pinning (Figs. 3, 4).

Post-operatively, a posterior long-arm splint was applied to all children for 3–4 weeks according to the radiographic healing. In patients that had exact healing radiographically at the end of third post-operative week, the K-wires and splint were removed, and range-of-motion exercises were started. For the others, both splint and K-wires were removed at the end of the fourth post-operative week. Clinical evaluation of the final follow-up was based on the carrying angle and the arc of flexion–extension of both the injured and uninjured elbows. Radiographic assessment of both elbows was performed using the Baumann's angle and humero-ulnar angle for adults. All the radiological and clinical assessments on the final follow-up were made by other surgeons in the same clinic.

Results

The average hospital stay was 2 days (range 1–3 days), and the average follow-up time was 4 years (range 2–11 years) in this series. The average time interval between the initial injury and the surgical procedures (the mean delaying time) was 6 days (range 2–19 days). Except for 7 (22.5%)

Fig. 1 A 6-year-old boy fell from a bicycle and sustained an injury to the left elbow. The plain anteroposterior and lateral radiographs showed type III-A displaced supracondylar humerus fracture at the time of injury

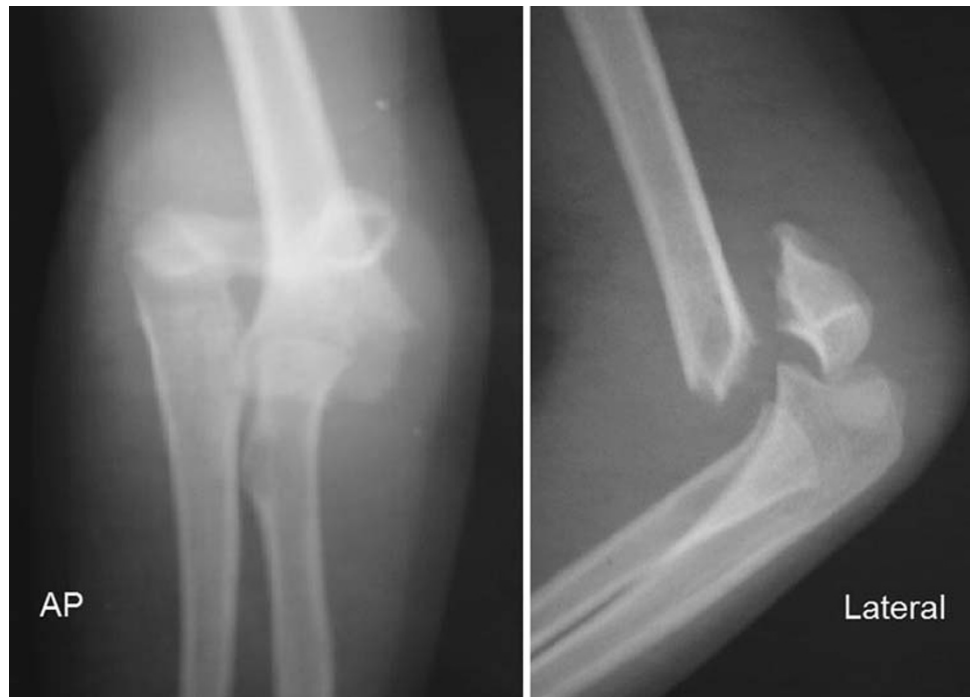
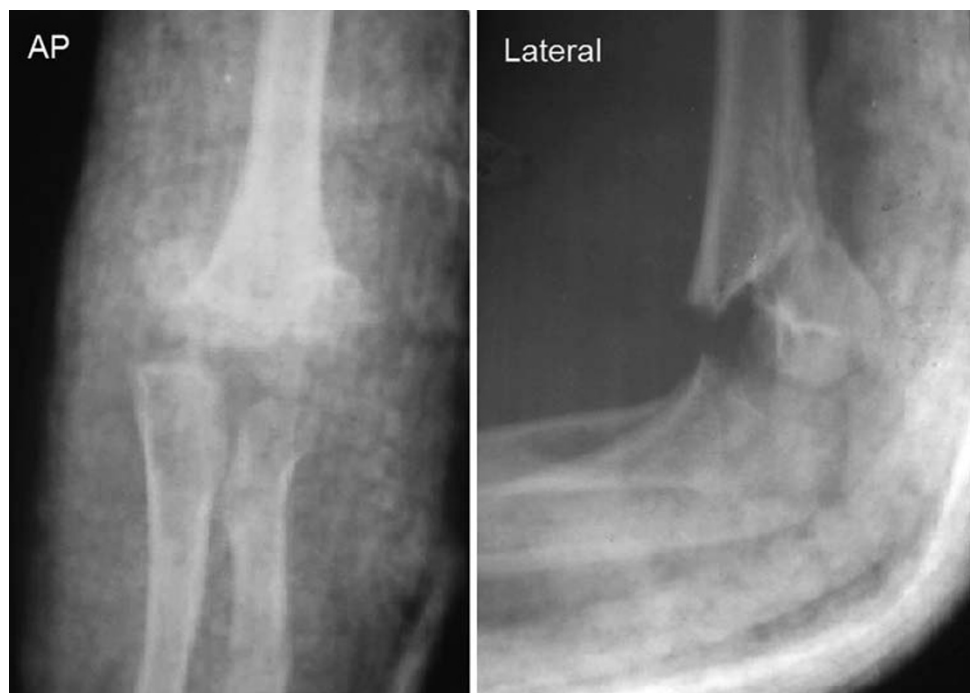
Fig. 2 The 6-year-old boy was referred to our hospital 10 days after the initial injury because of failure of close reduction. The anteroposterior and lateral radiographs showed severe displacement



children who were admitted to our hospital within the first 24 h, 24 (77.5%) of 31 patients in this series were seen in another (sometimes more than one) medical center, outpatient clinic or hospital initially and had a transient or permanent therapeutic intervention. These 24 patients were admitted to our hospital after the first day of injury. While some children were referred to our hospital after a long-arm splint applied to the affected extremity without any

attempt for closed reduction, the rest were followed in a long-arm cast following an inadequate fracture reduction. The 7 who were directly admitted in the first 24 h underwent an unsuccessful closed reduction in the emergency department and were operated on on the next available surgery day.

Except for 2 (6.5%) patients with anterior interosseous and ulnar nerve injuries pre-operatively, which resolved

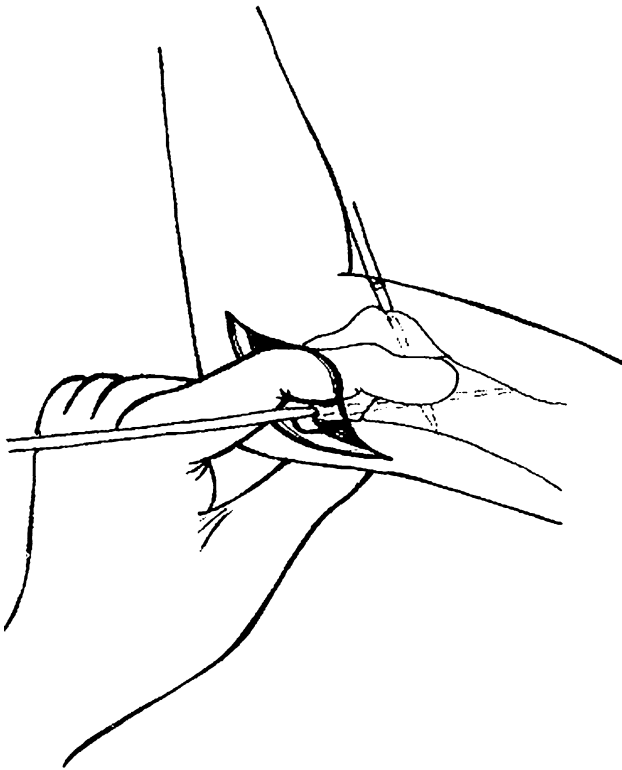
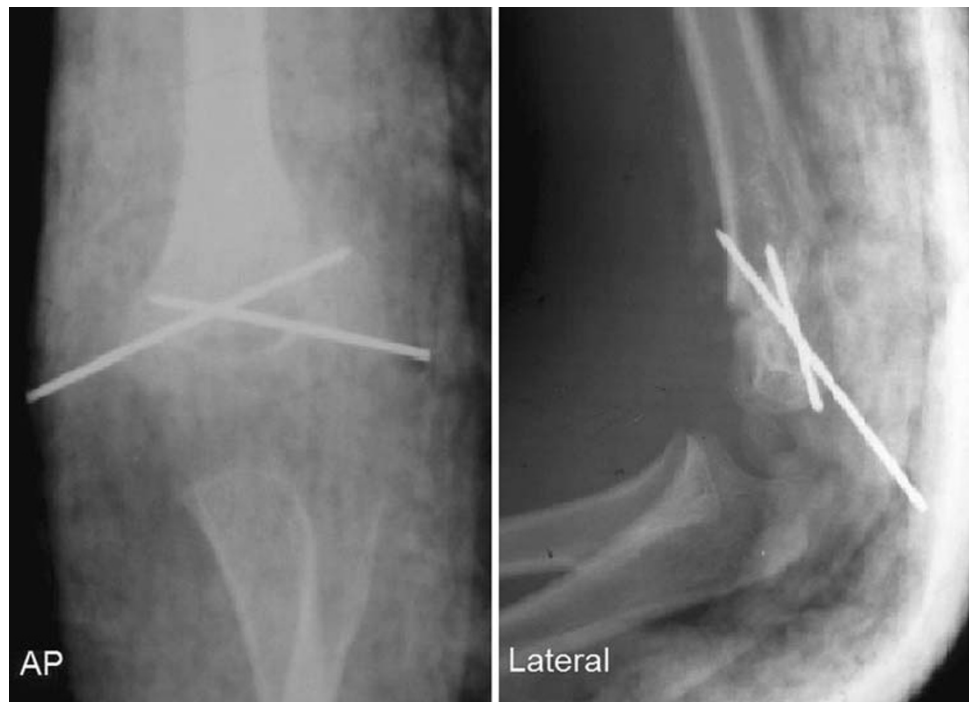

Fig. 3 The line drawing shows sentiment manual reduction using a medial approach

spontaneously within 3 months post-operatively, none of the patients had neurological involvement before or after the operations. Patients with neurological injury underwent

Fig. 4 Early post-operative anteroposterior and lateral radiographs after open reduction using a medial approach and cross-pinning

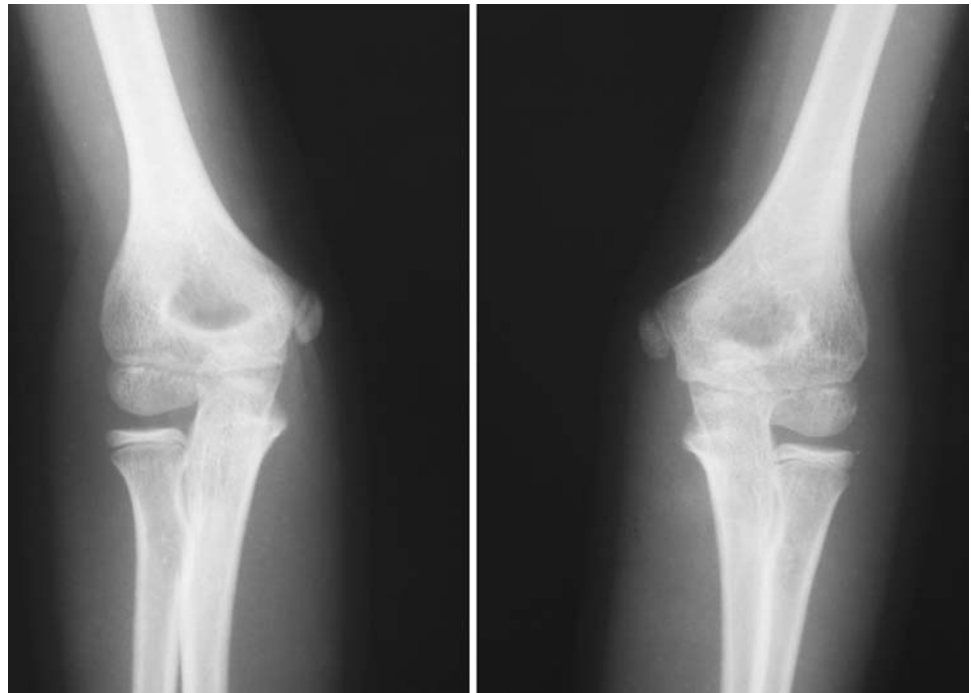


the electromyography examination to achieve correct diagnosis and follow-up. Pin-tract infection developed in 2 (6.5%) patients during the second post-operative week. These infections were resolved with a course of oral antibiotics and pin removal after adequate osseous healing. In 7 (22.5%) patients, a mean carrying angle loss of 12.4° (range 6° – 29°) was observed. None of the patients developed myositis ossificans or cubitus varus. At the final follow-up all patients had full range of motion of the affected elbow (Fig. 5). The radiographic examination revealed an average Baumann's angle of 76.8° (range 71° – 89°). Mean humero-ulnar angle was 4° in males (range -5° to 11°) and 6.8° in females (range -10° to 14°). Full functional recovery was obtained within 3 months in 29 (93.5%) patients (average elbow extension 0° , flexion 140°) and within 5 months in the remaining 2 (6.5%) patients (average elbow extension 3° , flexion 138°).

Discussion

Displaced supracondylar humeral fractures in children may be associated with vascular, neurological and infectious complications in addition to difficulties in achieving and maintaining a satisfactory reduction [11–13]. Many authors have previously expressed the opinion that emergent treatment of these fractures is necessary to avoid such complications [2, 3, 14–16]. However, others have not been able to identify a difference between emergent and urgent

Fig. 5 The 6-year-old boy had full range of motion on the left elbow 5 years post-operatively. The anteroposterior radiograph showed 15° humero–ulnar angles on the both elbows



interventions with regard to open reduction and peri- and post-operative complications [4, 5].

There are various factors leading to delayed treatment following supracondylar humeral fractures in children. Inability to achieve a satisfactory closed reduction of the fracture due to continued swelling and/or skin problems is the main concern. In addition to these medical conditions, the need for open reduction and internal fixation increases as the time until surgery increases. The rate of conversion to open reduction has been reported as ranging from less than 3% to about 46% [13, 18–20]. Cheng et al. [21] reported a series of 180 patients with type-III supracondylar fractures, with an open reduction rate approaching 38%. However, in this series, only 17% of the fractures were presented on the day of injury. In our series, 22.5% of the patients were admitted to our institution on the day of injury; however, due to unsuccessful closed reduction performed in the emergency department, all these patients were scheduled for open reduction. The health facility problems relating to the disorganized health insurance system unique to our country constituted the main reasons for the delayed presentation of these patients to our hospital. In addition, some of the children were treated by non-doctor personnel (witch doctors; still common in developing countries) initially, before being referred to a medical center. A closed reduction was attempted in the emergency department for all children, regardless of whether they had already undergone closed reduction. However, in none of them was an acceptable reduction achieved. Surgical treatment was performed on the next available surgery day.

Prior to the 1999 report by Iyengar et al. [17], addressing the issue of surgical timing as it relates to complications following supracondylar fracture surgery, these fractures had been treated as an emergency. Those authors focused on several clinical parameters, including the need to convert to open reduction, nerve injury and signs of compartment syndrome such as decreased grip strength. Their main outcome variable was the need to convert to open reduction, which occurred in 3 (%13) of the 23 patients in the early-treatment group compared with 6 (%17) of the 35 patients in their delayed-treatment group. The authors were unable to identify any significant differences between their early and delayed surgical groups concerning associated nerve injuries and measured parameters.

Mehlman et al. [4] performed a similar study to investigate the effect of surgical timing on the perioperative complications. In their series, 52 patients had early (8 h or less following injury) and 146 patients had delayed (more than 8 h following injury) surgical treatment of a displaced supracondylar humeral fracture. The authors found no significant difference between the two groups with respect to the need for conversion to open reduction, pin-tract infection or iatrogenic nerve injury. No compartment syndrome occurred in either group.

The treatment options reported in the literature for delayed presentation of displaced supracondylar humeral fractures are re-manipulation [22], skin traction [23], delayed percutaneous pinning after skeletal traction [24] and open surgery [25]. Devnani [23] reported that gradually reducing the fracture with traction reduced the risks

related with delayed supracondylar humeral fractures. The mean delaying time was 5.6 days in his series, and 5 (18%) cubitus varus deformities were corrected later by an osteotomy. The average hospital stay was 14 days. He had poor results in children with posteromedial angulation. Agus et al. [24] evaluated 13 children treated with closed percutaneous pinning after skeletal overhead traction. There were two fair functional results in that series. Lal and Bhan [25] reported a series of 20 children with delayed open reduction by means of a posterior approach for supracondylar humeral fractures. The delaying time changed between 11 and 17 days in this study. Of the patients, 35% had cubitus varus deformity, and the loss of range of motion was 70%. In our series, the delaying time was 6 days on average (range 2–19 days); 7 (22.5%) patients had cubitus varus deformity with a mean carrying angle loss of 12.4° (range 6°–29°); none of the patients required physical therapy; full functional recovery was achieved within 3 months in 29 (93.5%) patients; and there was no evidence of a correlation between duration of immobilization and delay in range of motion recovery.

Deep infections or osteomyelitis is rare following surgical treatment of displaced supracondylar humeral fractures; pin-tract infections usually are seen [26]. Recently reported rates of infection associated with percutaneous fixation have ranged from 2.4 to 6.6% [13, 21, 27]. In our study, the infection rate was 6.5%. All these infections were pin tract and resolved with a course of oral antibiotics followed by pin removal after adequate osseous healing.

Nerve injuries associated with displaced supracondylar humeral fractures may be separated into those associated with the injury itself and those associated with treatment of the injury [28]. Although a crossed K-wire configuration has been shown to be biomechanically superior [29], recent approaches to treatment have de-emphasized the need for medial pins in the treatment of these fractures because of the increased morbidity associated with such pins [30, 31]. A literature review demonstrated 3.6% iatrogenic nerve injury, with the ulnar nerve being involved in 81% of these cases [6, 11, 28, 30–32]. In this series, we performed crossed K-wire configuration in all patients. We observed no iatrogenic nerve injury and the nerve injuries that existed pre-operatively were resolved within 3 months post-operatively. Volkmann ischemic contracture is a rare event, with a prevalence of 0.5% or less [33]. In our study, we found no cases of compartment syndrome.

In summary, we were unable to identify any significant difference in perioperative complication rates of displaced supracondylar fractures of the humerus in children who had delayed treatment. Delayed treatment significantly increases the need for open reduction of the fracture fragments. If intraoperative fluoroscopy was available,

closed reduction would be possible in our cases. We identified no increase in infection, iatrogenic nerve injury or Volkmann ischemic contracture following an open reduction in those patients treated more than 24 h after injury. These fractures can be treated as an urgency; however, despite being treated in the following few days after injury, perioperative complication rates did not appear to be increased significantly. Open reduction using a medial approach is a safe method for delayed presentation of displaced supracondylar humeral fractures in children and can be applied without an image intensifier or X-ray control. In our study, 22.5% of the patients had cubitus varus deformity. This is similar to that observed in other series in the literature. However, our functional recovery time is better than in these reports and similar to that seen with closed percutaneous pinning.

References

- Harris IE (1992) Supracondylar fractures of the humerus in children. *Orthopedics* 15:811–817
- Minkowitz B, Busch MT (1994) Supracondylar humerus fractures. Current trends and controversies. *Orthop Clin North Am* 25:581–594
- Paradis G, Lavallee P, Gagnon N, Lemire L (1993) Supracondylar fractures of the humerus in children: technique and results of crossed percutaneous K-wire fixation. *Clin Orthop* 297:231–237
- Mehlman CT, Strub WM, Roy DR, Wall EJ, Crawford AH (2001) The effect of surgical timing on the perioperative complications of treatment of supracondylar humeral fractures in children. *J Bone Joint Surg Am* 83:323–327
- Sibinski M, Sharma H, Bennet GC (2006) Early versus delayed treatment of extension type-3 supracondylar fractures of the humerus in children. *J Bone Joint Surg Br* 88(3):380–381
- Pirone AM, Graham HK, Krajbich JI (1988) Management of displaced extension type supracondylar fractures of the humerus in children. *J Bone Joint Surg Am* 70:641–650
- Gjerloff C, Shobjerg JO (1988) Percutaneous pinning of supracondylar fractures of the humerus. *Acta Orthop Scand* 49:597–599
- Mehserle WL, Meehan PL (1991) Treatment of displaced supracondylar fracture of the humerus (type III) with closed reduction and percutaneous cross-pin fixation. *J Pediatr Orthop* 6:705–711
- Smith JPI, Snowdowne RB, Du Toit WJ (1996) The management of supracondylar fractures of the humerus in children. *J Bone Joint Surg* 6:23–27
- Wilkins KE (1990) The operative management of supracondylar fractures. *Orthop Clin North Am* 21:269–289
- Brown IC, Zinar DM (1995) Traumatic and iatrogenic neurological complications after supracondylar humerus fractures in children. *J Pediatr Orthop* 15:440–443
- Crawford AH, Oestreich AE (1983) Danger of loss of reduction of supracondylar elbow fracture during radiography. *J Pediatr Orthop* 3:523
- Cramer KE, Devito DP, Green NE (1992) Comparison of closed reduction and percutaneous pinning versus open reduction and percutaneous pinning in displaced supracondylar fractures of the humerus in children. *J Orthop Trauma* 6:407–412

14. Flynn JC, Zink WP (1995) Complications of elbow fractures and dislocations in children. In: Epps CH Jr, Bowen JR (eds) *Complications in pediatric orthopaedic surgery*. JB Lippincott, Philadelphia, pp 47–74
15. Otsuka NY, Kasser JP (1997) Supracondylar fractures of the humerus in children. *J Am Acad Orthop Surg* 5:19–26
16. Segal D (1979) Pediatric orthopedic emergencies. *Pediatr Clin North Am* 26:793–802
17. Iyengar SR, Hoffinger SA, Townsend DR (1999) Early versus delayed reduction and pinning of type III displaced supracondylar fractures of the humerus in children: a comparative study. *J Orthop Trauma* 13:51–55
18. Peters CL, Scott SM, Stevens PM (1995) Closed reduction and percutaneous pinning of displaced supracondylar humerus fractures in children: description of a new closed reduction technique for fractures with brachialis muscle entrapment. *J Orthop Trauma* 9:430–434
19. Danielsson L, Pettersson H (1980) Open reduction and pin fixation of severely displaced supracondylar fracture of the humerus in children. *Acta Orthop Scand* 51:249–255
20. Walloe A, Egung N, Eikelund L (1985) Supracondylar fracture of the humerus in children: review of closed and open reduction leading to a proposal for treatment. *Injury* 16:296–299
21. Cheng JC, Lam TP, Shen WY (1995) Closed reduction and percutaneous pinning for type III displaced supracondylar fractures of the humerus in children. *J Orthop Trauma* 9:511–515
22. Vohvanen V, Aalto K (1978) Supracondylar fracture of the humerus in children. A long-term follow-up study of 107 cases. *Acta Orthop Scand* 49(3):225–233
23. Devnani AS (2005) Late presentation of supracondylar fracture of the humerus in children. *Clin Orthop* 431:36–41
24. Agus H, Kalenderer O, Kayali C, Eryilmaz G (2002) Skeletal traction and delayed percutaneous fixation of complicated supracondylar humerus fractures due to delayed or unsuccessful reductions and extensive swelling in children. *J Pediatr Orthop Br* 11(2):150–154
25. Lal GM, Bhan S (1991) Delayed open reduction for supracondylar fractures of the humerus. *Int Orthop* 15(3):189–191
26. Kasser JR (1992) Percutaneous pinning of supracondylar fractures of the humerus. *Instr Course Lect* 41:385–390
27. Boyd DW, Aronson DD (1992) Supracondylar fractures of the humerus: a prospective study of percutaneous pinning. *J Pediatr Orthop* 12:789–794
28. Fowles JV, Kassab MT (1974) Displaced supracondylar fractures of the elbow in children. A report on the fixation of extension and flexion fractures by two lateral percutaneous pins. *J Bone Joint Surg Am* 56:490–500
29. Zions LE, McKellop HA, Hathaway R (1994) Torsional strength of pin configurations used to fix supracondylar fractures of the humerus in children. *J Bone Joint Surg Am* 76:253–256
30. Kallio PE, Foster BK, Paterson DC (1992) Difficult supracondylar elbow fractures in children: analysis of percutaneous pinning technique. *J Pediatr Orthop* 12:11–15
31. Topping RE, Blanco JS, Davis TJ (1995) Clinical evaluation of crossed-pin versus lateral-pin fixation in displaced supracondylar humerus fractures. *J Pediatr Orthop* 15:435–439
32. Lyons J, Ashley E, Hoffer MM (1998) Ulnar nerve palsies after percutaneous cross-pinning of supracondylar fractures in children's elbows. *J Pediatr Orthop* 18:43–45
33. Rang M (1974) *Children's fractures*. JB Lippincott, Philadelphia, pp 101