



Posterior reconstruction during robotic-assisted radical cystectomy with intracorporeal orthotopic ileal neobladder: description and outcomes of a simple step

Bernardo Rocco¹ · Lorenzo G. Luciani² · Justin Collins³ · Rodolfo Sanchez-Salas³ · Christofer Adding³ · Daniele Mattevi² · Abolfazl Hosseini³ · Peter Wiklund^{3,4}

Received: 3 June 2020 / Accepted: 22 June 2020 / Published online: 29 June 2020
© Springer-Verlag London Ltd., part of Springer Nature 2020

Abstract

A posterior reconstruction (PR) might improve the fluidity and delicacy of the maneuvers related to the neovesico-urethral anastomosis during robotic-assisted radical cystectomy (RARC). Our objective is to describe in detail the surgical steps of PR and to assess its feasibility and functional outcomes. The data regarding patients undergoing a totally intracorporeal RARC with neobladder and PR for high-grade and/or muscle-invasive urothelial cancer of the bladder at Karolinska University Hospital between October 2015 and November 2016 by a single surgeon (PW) were reviewed. Prior to the anastomosis, a modified posterior Rocco's repair involving the Denonvillier's fascia, the rhabdosphincter, and the posterior side of the ileal neobladder neck was performed. The steps are shown in a video at <https://doi.org/10.1089/vid.2019.0029>. The primary outcome was urinary continence; the secondary outcomes were urinary leakage, intermittent catheterization, and complications related to the reconstructive steps. Eleven male patients with a median age and BMI of 67 years and 24, respectively, underwent RARC with PR associated to the neovesico-urethral anastomosis. Overall and posterior reconstruction time were 300' (195–320) and 6' (4–7), respectively. The daytime and nighttime continence rates were 100% and 44% at 12 months, respectively; the median pad weight was 3.5 g and 108 g at daytime and nighttime, respectively. One urinary leakage from the urethrovesical anastomosis was treated conservatively. Two patients perform intermittent catheterization. The posterior reconstruction during RARC is safe and feasible, providing good continence rates. It supported a careful suturing of the anastomosis as well as an uncomplicated catheter placement.

Keywords Bladder cancer · Robotic surgery · Radical cystectomy · Neobladder · Posterior reconstruction · Urinary incontinence

Purpose

Robot-assisted laparoscopic radical cystectomy (RARC) is a viable alternative to open radical cystectomy for the treatment of patients with bladder cancer, with acceptable peri- and postoperative outcomes [1].

Incontinence is one of the drawbacks of radical cystectomy with neobladder and significantly impairs quality of life. Posterior reconstruction (PR) during radical prostatectomy was initially proposed in order to facilitate anastomosis and to possibly improve early continence rates [2].

Although the influence of PR on post-prostatectomy continence has been questioned [3], many surgeons around the world included this step in robotic-assisted radical prostatectomy (RARP) because of an improved hemostasis and a greater support for a delicate anastomosis.

✉ Lorenzo G. Luciani
lorenzo_luciani@hotmail.com

¹ Department of Urology, University of Modena and Reggio Emilia, Modena, Italy

² Department of Urology, S. Chiara Regional Hospital, L.Go Medaglie d'Oro, 38122 Trento, Italy

³ Department of Urology, Karolinska University Hospital, Stockholm, Sweden

⁴ Icahn School of Medicine at Mount Sinai Health System, New York, NY, USA

The ileum of the neobladder is a relatively weaker tissue as compared to the bladder wall in radical prostatectomy. The early and late complications related to the ileourethral anastomosis of neobladder account for 10% in open cystectomy even in experienced hands [4], making of PR a very attractive approach in order to reduce undue tractions on the tissues involved in the anastomosis.

We describe a simple technique of PR which can be incorporated into the neovesico-urethral anastomosis of the neobladder during RARC. The early and intermediate functional results of the cohort of patients treated with RARC and PR are reported.

Methods

Study design

Between October 2015 and November 2016, 33 consecutive patients underwent a totally intracorporeal RARC with a modified Studer neobladder at Karolinska University Hospital by three different surgeons (PW, AH, CA), for high-grade and/or muscle-invasive urothelial cancer of the bladder. During this time interval, all male patients operated by one surgeon (PW) received a posterior reconstruction (PR) associated to the neovesico-urethral anastomosis. Preoperative clinical characteristics, intra- and postoperative data were prospectively collected in an ethically approved database and reviewed. A detailed informed consent was obtained in all cases. The outcomes of the study included: continence rates and urinary leakage. RARCs with PR were performed by a surgeon (PW) with extensive experience in robotics (> 200 RARCs).

Preoperative evaluation and data collection

For each patient, we prospectively collected preoperative (age, BMI, American Society of Anaesthesiologists—ASA-score), perioperative (overall and PR operative time, blood loss, complications related to the PR and to anastomosis, peri- and postoperative complications within 30 days), and pathologic data (tumor staging, surgical margin status). Cystoprostatectomy for advanced prostate cancer and cystectomies for bladder cancer in the female were excluded. None of the patients had undergone preoperative radiotherapy. Medical and surgical complications were collected for all patients through a combination of institutional electronic medical records and operative notes.

Assessment of continence and complications

The primary outcome of interest was urinary continence, defined as no leakage or use of a safety pad for minimal

leakage during a given time (day or night). Continence rates as assessed by third-party personnel with self-administrated questions 1 and 5 of the EPIC questionnaire at 6, and 12 months after catheter removal were recorded. Additional data on mucous leakage, and pad size, timing (daytime or nighttime) and wetness were also gathered. The secondary outcomes measured were (1) urinary leakage, (2) intermittent catheterization, and (3) overall complications and those directly related to the reconstructive steps (anastomosis and posterior reconstruction) of RARC, as assessed by the Clavien–Dindo classification [5].

Description of the RARC technique and postoperative management

Cystectomy and neobladder

The surgical technique combining RARC, pelvic lymph node dissection, and intracorporeal urinary diversion has been previously described [6, 7]. A modified Studer ileal neobladder is fashioned; the anastomosis between the ureters and the afferent limb of the pouch is performed using the Wallace technique. Special attempt was made to preserve the maximal urethral length and the neurovascular bundles to various degrees at the surgeon's discretion, and directed by preoperative clinical and functional assessment.

Posterior reconstruction and urethrovesical anastomosis

Figure 1 depicts the main steps of the posterior reconstruction in a sagittal view (Fig. 1). After the ileum is brought down to the urethra by placing two vessel loops around the intestine through the mesentery, the posterior reconstruction is started. The technique includes a modified posterior Rocco's repair with a bidirectional barbed suture (Quill 3–0) suturing the rhabdosphincter and the median fibrous raphe to the remaining Denonvillier's fascia in a running fashion; thus reconstructed plane is then fixed to the posterior side of the selected tubularized bowel segment 1 cm dorsocephalad (Fig. 2). On tying this suture, the ileum segment descends close to the urethral stump (Fig. 3). At the tip of the U-shaped ileal loop, a 1.5 cm incision is made with the robotic scissors at the level of the urethral anastomosis (Fig. 4). The urethrovaginal anastomosis is then performed according to the Van Velthoven technique [8], using a second bidirectional 3–0 Quill needle. The running suture is started by placing both needles outside-in through the intestine opening, which will act as the neobladder neck, and inside-out through the urethra at corresponding sites (Fig. 5). After passing the catheter through the urethra, the anterior side of the suture is completed and the distal ends tied together (Fig. 6). The surgical steps of the PR

Fig. 1 The surgical steps of the posterior reconstruction are depicted in a sagittal view, emphasizing the anatomical landmarks involved in the procedure. A is an overview prior to cystoprostatectomy, whereas B, C, and D, equate to Figs. 2, 3, and 5, respectively

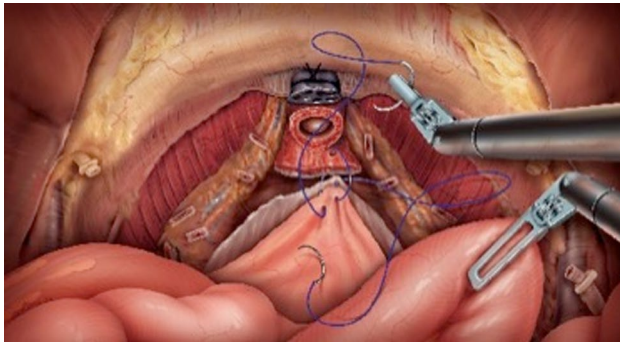
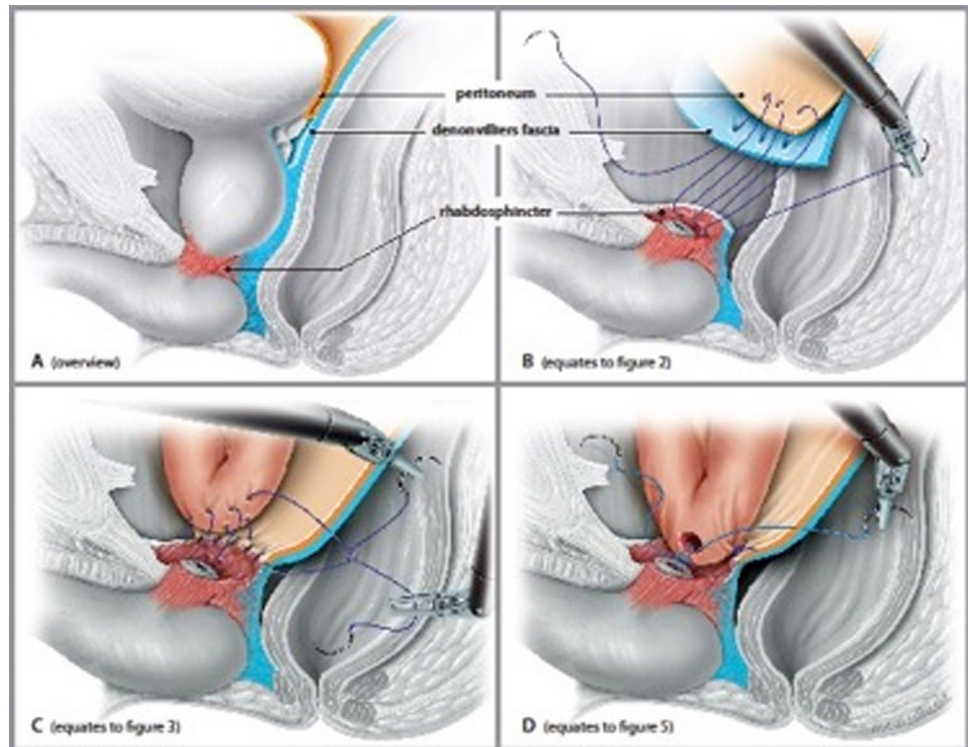


Fig. 2 After the selected tubularized bowel segment is brought down to the urethra, the posterior reconstruction begins by suturing the rhabdosphincter to the remaining Denonvillier's fascia in a running fashion

during RARC with neobladder are also illustrated in a recently published video (see at <https://doi.org/10.1089/vid.2019.0029>) [9].

Postoperative management

In case of uneventful postoperative course, the drain is removed on day 1, the ureteral stents on day 10, and the catheter on postoperative day 21. In case of persistent drain output, a urine sample is taken from the catheter and analyzed for creatinine level. A cystogram is performed only if urinary leakage is suspected. Leakage of the anastomosis is

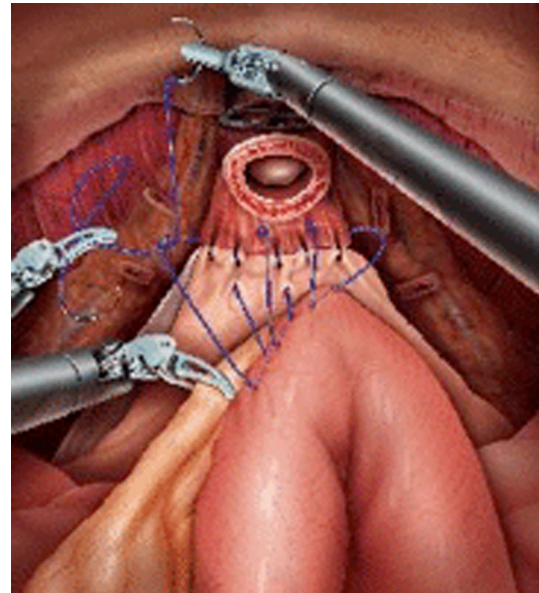


Fig. 3 The reconstructed plane (rhabdosphincter plus Denonvillier's fascia) is fixed to the posterior side of the ileum. As a result, the ileum segment descends close to the urethral stump

possibly managed conservatively by maintaining an indwelling catheter for an additional period, according to the degree of leakage.

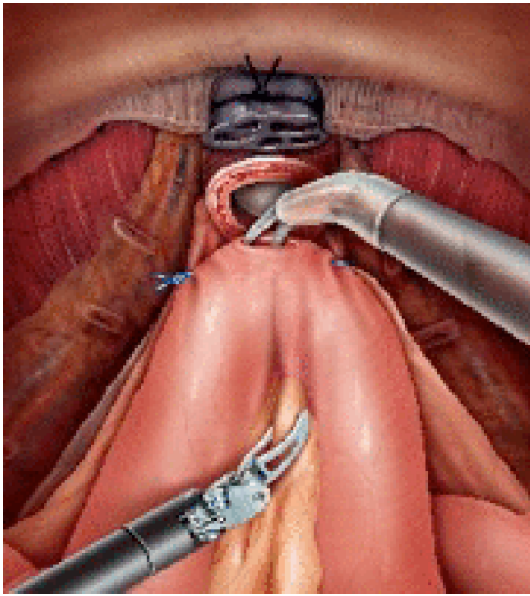


Fig. 4 At the tip of the U-shaped ileal loop, a small incision is made at the level of the urethral anastomosis

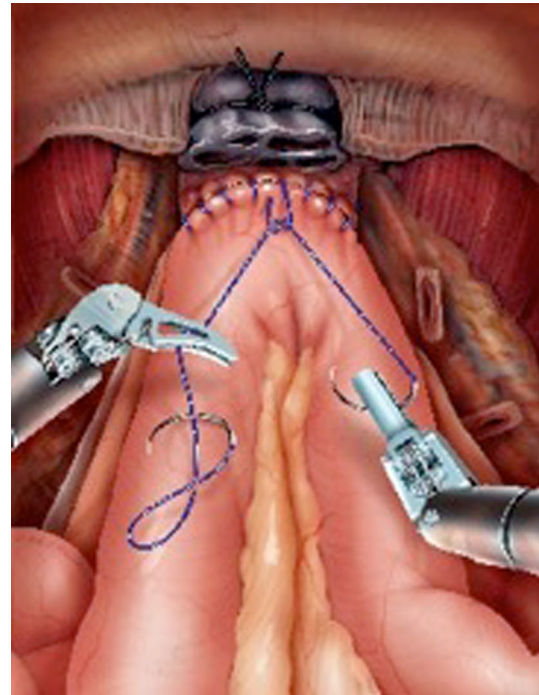


Fig. 6 After passing the catheter through the urethra, the anterior side of the suture is completed and the distal ends tied together

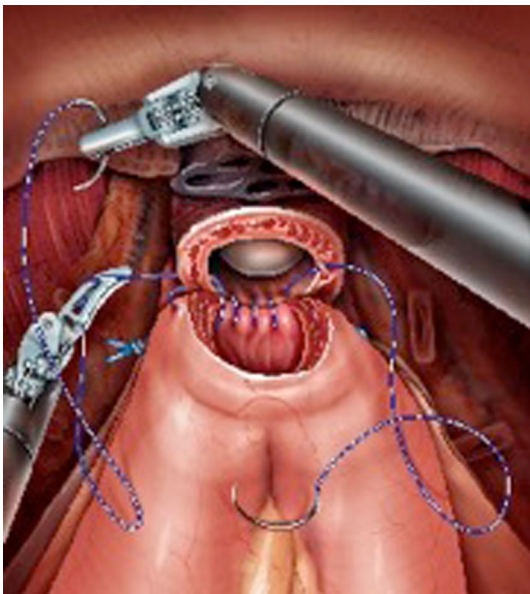


Fig. 5 The urethrovvesical anastomosis is performed according to the Van Velthoven technique, using a second bidirectional needle

Results

Eleven male patients with a median age and BMI of 67 years (range 55–76) and 24 (21–33), respectively, underwent RARC with posterior reconstruction associated to the neovesico-urethral anastomosis in the study

interval. Seven patients had an ASA score of 3. Overall and posterior reconstruction time were 300' (195–320) and 6' (4–7), respectively. Eight patients underwent a nerve-sparing RARC. No positive surgical margins were reported. Operative and functional results are reported in Table 1. Table 2a reports the complications according to the Clavien–Dindo system, including a urinary leakage from the ureteroenteric anastomosis in two cases, treated with bilateral nephrostomy. One urinary leakage from the urethrovvesical anastomosis was treated conservatively with an indwelling catheter for 2 months. Two patients perform clean intermittent catheterization (CIC) due to increased residual volume; one of them experiences night incontinence as well. Table 2b reports the continence rates and pad weight. The daytime continence rates were 100% at 6 and 12 months. The nighttime continence rates were 42% and 44% at 6 and 12 months, respectively. The 12-month follow-up was unavailable in two cases, due to the insufficient time lapse from surgery.

Discussion

Urinary diversion with orthotopic ileal neobladder involves inherent changes in continence mechanisms, due to the loss of bladder stretch reflexes and filling sensation. Although continence rates for most patients continue to improve over

Table 1 Demographic, operative and pathologic data

Demographic and operative data	
Age	67 (55–76)
BMI	24 (21–33)
ASA score	
2	4
3	7
Overall operative time	300' (195–320)
Operative time for PR	6' (4–7)
Nerve-sparing	
Bilateral	8
Unilateral	1
No	2
Oncologic data	
Neoadjuvant chemotherapy	8
Pathology	
pT0	5
pTa-Tis	2
pT2	1
pT3a	3
pN+	1
Positive margins	1
Follow-up	
ANED	8
AWD	1
DNED	1
Lost	1

Values are expressed as median with range or number

BMI body mass index, *ANED* alive, no evidence of disease, *AWD* alive with disease, *DNED* died, no evidence of disease

time as the neobladder capacity increases, reporting of combined daytime and nighttime continence was still as high as 49% by more than 18–36 months [10]. Although incontinence is regarded as one of the most important keys to patient satisfaction, therapeutic options in men have been limited up until now and include pelvic floor training [11], pharmacological agents [12], retourethral slings [13], and artificial sphincter placement [14]. However, these studies comprise a very limited number of patients and often report only moderate amelioration of the symptoms or unacceptable side effects.

The PR technique was first reported by Rocco in 2001 [1] and this technical modification has since become a common practice during RARP [15]. The rationale is that it restores the anatomical and functional length of the rhabdosphincter, possibly increasing the early continence rates. According to this theory, the PR reestablishes the continuity of the musculofascial plate, which is disrupted during pelvic radical surgery [16]. Accordingly, some authors consider the median dorsal raphe as a fulcrum for the contraction of the sphincter that, combined with the activity of the pubo-perinealis muscle, results in a double-sling mechanism for closure of the urethra [17]. Of note, autoptic studies have shown that the rhabdosphincter has more connective and smooth muscle and less striated muscle, partly accounting for greater difficulty in recovery of urinary control following pelvic surgery in older patients, who are often the object of pelvic oncologic surgery [16].

Although the role of the PR during radical prostatectomy is still controversial [15], the PR might prove particularly useful in case of radical cystectomy with ileal neobladder. A strong argument for undertaking a PR is the greater support that it can provide to the neovesico-urethral anastomosis. Both the ileal wall and the urethra are soft tissues with some

Table 2 Operative and functional results

(a)	RARC+PR (n = 11)			
Clavien 1: paralytic ileus (conservative)	1			
Clavien 2: increased urine residual (clean intermittent catheterization)	2			
U.T.I. (antibiotics)	2			
Urinary leakage (indwelling catheter)	1			
Clavien 3: urinary leakage (bilateral nephrostomy)	2			
Clavien 4: M.I. and cardiac arrest (ICU: resuscitation; cardiac stent)	1			
Clavien 5: –	0			
(b)	6-month continence (%)	6-month pad weight	12-month continence (%)	12-month pad weight
Daytime	100	10 g (0–99)	100	3.5 g (0–16)
Nighttime	42	164 g (70–500)	44	108 g (150–307)

(a) Complications according to Clavien–Dindo and their management. (b) 6- and 12-month urinary incontinence rates and mean pad weight measured during daytime and nighttime. Two patients are on clean intermittent catheterization. 12-month follow-up unavailable in two cases

MI myocardial infarction, *UTI* urinary tract infection

degree of elasticity. However, they can be easily disrupted during a complex and delicate surgical step such as the robotic suturing of the neovesico-urethral anastomosis, due to instruments conflict or traction by the ileal mesentery. Another advantage of PR is that it facilitates the placement of the catheter during the neovesico-urethral anastomosis: this easy step can become extremely useful, especially in case a difficult catheterization of the neobladder neck is experienced during a RARC.

The functional results presented in this study are very promising. The 6- and 12-month continence rates were 100% during daytime, including a patient performing CIC. As expected, the results improved over time and compare very favorably with the results of open and robotic cystectomy with neobladder reconstruction. The analysis of the historical functional outcomes of 70 RARCs with neobladder without posterior reconstruction at Karolinska showed that 19 males (90.5%) and 2 out of 3 (66.7%) females were continent (0–1 pad/day) at 12 months [18]. Hautmann found a “good” or “satisfactory” level of continence in 95.9% of patients within 5 years [4]. Clifford et al. reported a daytime continence rate of 92% at more than 12–18 months in a more recent large cohort of patients undergoing open radical cystectomy and Studer pouch [10]. Yuh reported a daytime continence rate ranging from 83 to 100% in men in a systematic review on functional results after RARC [19]. However, there is a high variability in terms of definition of continence. According to Yuh, only three of six studies reported a distinct definition of continence; these studies generally lack reporting of pad weight and rely mostly on the number of pads [20]. At 12 months, the daytime pad weight was only 3.5 g in our series. It might be argued that this is the result of the meticulousness reachable by robotic cystectomy per se and not of the posterior reconstruction. Of course, this is a very reasonable argument: only a parallel study with a larger sample size will clarify this issue. Still, the present cohort includes a limited number of patients but it has been closely followed up with an objective methodology and the results are promising. The only complications reported in our series which might be directly associated to the PR were one case of a urinary leakage from the neovesico-urethral anastomosis, treated with an indwelling catheter for 2 months, and two cases of increased residual volume requiring intermittent catheterization. These results are in line with those of open and robotic series of radical cystectomy with neobladder without posterior reconstruction [4, 20, 21].

We recognize several limitations in our study. First, a small number of cases is presented. Initially, the operations were performed with the standard approach but, with increasing experience, anatomic restoration was preferred. Second, our study was retrospective in design. We believe a prospective controlled multi-institutional study would be the most successful. Third, the continence criteria were not

strict. We accepted minimal leakage as continent, and that definition may have improved our outcomes for all groups. By design and practicality, we did not measure the entire urinary function domain nor the entire realm of the EPIC questionnaire. We selected the EPIC questions that we considered most appropriate for the study hypothesis together with the pad weight.

In conclusion, we continue to include the posterior musculofascial plate reconstruction in our technique, because this step is simple, reproducible, with a very limited increase in operative time, and with only a negligible risk of potential harm to the patient.

Conclusions

Posterior reconstruction incorporated into the neovesico-urethral anastomosis during RARC is a safe and feasible procedure, which can be performed in a few minutes. Although the sample size of this study limits definitive conclusions, the overall continence rates were promising. In general, it supported a careful suturing of the delicate tissues of the neovesico-urethral anastomosis as well as an uncomplicated catheter placement, suggesting that this easy step should be included into the RARC procedure.

Compliance with ethical standards

Conflict of interest The authors declare that they have no conflict of interest.

Ethical approval All procedures performed in studies involving human participants were in accordance with the ethical standards of the institutional and/or national research committee and with the 1964 Helsinki Declaration and its later amendments or comparable ethical standards.

Informed consent Informed consent was obtained from all individual participants included in the study.

References

1. Novara G, Catto WF, Wilson T et al (2015) Systematic review and cumulative analysis of perioperative outcomes and complications after robot-assisted radical cystectomy. *Eur Urol* 67:476–501
2. Rocco F, Gadda F, Acquati P et al (2001) Personal research: reconstruction of the urethral striated sphincter. *Arch Ital Urol Androl* 73:127–137
3. Ghani KR, Menon M (2012) Posterior reconstruction: weighing the evidence. *Eur Urol* 62:791–793
4. Hautmann RE, De Petriconi R, Gottfried HW, Kleinschmidt K, Mattes R, Paiss T (1999) The ileal neobladder: complications and functional results in 363 patients. *J Urol* 161:422–428
5. Dindo D, Demartines N, Clavien PA (2004) Classification of surgical complications: a new proposal with evaluation in a cohort of 6336 and result of a survey. *Ann Surg* 240:205–213

6. Wiklund PN, Poulakis V (2011) Surgery illustrated-surgical atlas: robotic neobladder. *BJU Int* 107:1514–1537
7. Collins JW, Tyritzis S, Nyberg T et al (2013) Robot-assisted radical cystectomy: description of an evolved approach to radical cystectomy. *Eur Urol* 64:654–663
8. Van Velthoven RF, Ahkering TE, Peltier A, Skarecky DW, Clayman RV (2003) Technique for laparoscopic running urethrovesical anastomosis: the single knot method. *Urology* 61:699–702
9. Rocco B, Luciani LG, Collins J, Sanchez-Salas R, Adding C, Mattevi D, Hosseini A, Wiklund P (2019) Posterior reconstruction during robot-assisted radical cystectomy with intracorporeal orthotopic ileal neobladder. *Videourology*. <https://doi.org/10.1089/vid.2019.0029>
10. Clifford TG, Shah SH, Bazargani ST et al (2016) Prospective evaluation of continence following radical cystectomy and orthotopic urinary diversion using a validated questionnaire. *J Urol* 196:1685–1691
11. Zellner M (2011) Incontinence after radical prostatectomy and cystectomy: are combined training with mechanical devices and whole body vibration effective? *Urologe A* 50:433–444
12. Schlenker B, Gratzke C, Reich O et al (2006) Preliminary results on the off-label use of duloxetine for the treatment of stress incontinence after radical prostatectomy or cystectomy. *Eur Urol* 49:1075–1078
13. Mayer M, Bauer RM, Walther S et al (2009) Stress urinary incontinence after radical cystectomy: neobladder reconstruction and placement of retrourethral sling. *Urologe A* 48:645–648
14. Simma-Chiang V, Ginsberg DA, Teruya KK, Boyd SD (2012) Outcomes of artificial urinary sphincter placement in men after radical cystectomy and orthotopic urinary diversions for the treatment of stress urinary incontinence: the University of Southern California experience. *Urology* 79:1397–1401
15. Rocco B, Cozzi G, Spinelli MG et al (2012) Posterior musculo-fascial reconstruction after radical prostatectomy: a systematic review of the literature. *Eur Urol* 62:779–790
16. Burnett AL, Mostwin JL (1998) In situ anatomical study of the male urethral sphincteric complex: relevance to continence preservation during major pelvic surgery. *J Urol* 160:179–192
17. Walz J, Burnett AL, Costello AJ et al (2010) A critical analysis of the current knowledge of surgical anatomy related to the optimization of cancer control and preservation of continence and erection in candidates for radical prostatectomy. *Eur Urol* 57:179–192
18. Tyritzis SI, Hosseini A, Collins J et al (2013) Oncologic, functional, and complications outcomes of robot-assisted radical cystectomy with totally intracorporeal neobladder diversion. *Eur Urol* 64:734–741
19. Yuh B, Wilson T, Bochner B et al (2015) Systematic review and cumulative analysis of oncologic and functional outcomes after robot-assisted radical cystectomy. *Eur Urol* 67:402–422
20. Goh AC, Gill IS, Lee DJ et al (2012) Robotic intracorporeal orthotopic ileal neobladder: replicating open surgical principles. *Eur Urol* 62:891–901
21. Satkunasivam R, Santomauro M, Chopra S et al (2016) Robotic intracorporeal orthotopic neopladder: urodynamic outcomes, urinary function, and health-related quality of life. *Eur Urol* 69:247–253

Publisher's Note Springer Nature remains neutral with regard to jurisdictional claims in published maps and institutional affiliations.