



Clinical Experience with a Port-Free Internal Liver Retractor in Laparoscopic Bariatric Surgery

Hideharu Shimizu · Esam Batayyah · Tomasz Rogula

Published online: 4 January 2014
© Springer Science+Business Media New York 2014

Abstract

Background As laparoscopic techniques and instrumentation advance, bariatric surgery has begun to be performed through smaller incisions and fewer ports. Since the visualization of the dorso-lateral portion of the left liver lobe is critical for most bariatric procedures, surgeons have developed various techniques for providing adequate liver retraction without compromising patient safety. Herein, we present our experience with a port-free internal liver retractor used for bariatric cases. **Methods** Endolift™ does not require an additional port or anchoring to an external device. After insertion through an existing 5-mm port by means of the applier, one of the two attached clips (one on either end) was anchored to the left crus of the diaphragm while the other was fixed to the peritoneum above the right liver lobe through or beneath the falciform ligament. At the end of the surgery, the device was easily removed by using the applier.

Results We used this technique for 31 Roux-en-Y gastric bypasses and 2 single-incision sleeve gastrectomies. There were 24 females and 9 males with a mean age of 46 and mean body mass index 45.0 kg/m². The mean operative time was 136.5 min. The time required for the placement of the device was 1–3 min. The approach to the upper part of the stomach was satisfactory in all patients. No device-related complications were observed.

Conclusions The internal liver retractor is easy to handle and provides adequate retraction and exposure for bariatric cases. It also has potential benefits for single-incision and reduced port laparoscopic procedures.

Keywords Laparoscopic bariatric surgery · Morbid obesity · Gastric bypass · Liver retraction

H. Shimizu (✉) · E. Batayyah · T. Rogula
Bariatric and Metabolic Institute, M61, Cleveland Clinic,
9500 Euclid Avenue, Cleveland, OH 44195, USA
e-mail: hideharumaki@gmail.com
URL: <http://weightloss.clevelandclinic.org>

Introduction

Laparoscopic bariatric surgery is now the mainstay of weight loss strategies for morbidly obese patients. With the recent advances in laparoscopic techniques and instrumentation, bariatric surgeons are now able to perform the same procedures through smaller incisions and fewer ports. However, this new method may limit the laparoscopic view of the stomach and the area around the esophageal hiatus underlying the hypertrophic fatty liver typically seen in bariatric cases. Obtaining an adequate range of vision and working space is dependent on liver-lifting methods employed during laparoscopic surgery. The conventional mechanical liver retractors have been used as a standard technique for lifting the liver. However, they need an additional wound to serve as a port and pose the risk of iatrogenic liver injury [1–4]. Various techniques for liver retraction which do not use an additional port have been reported [5–19]. However, many of these techniques are not in standard use and require a liver puncture and/or sutures exteriorized through the abdominal wall, thereby limiting space to maneuver the retractor and posing the danger of creating additional scars. Herein, we report our experience with a port-free internal liver retractor, Endolift™ (Virtual Ports, Richmond, VA), which allows the entire procedure to be conducted intracorporeally.

Methods

This study was approved by the Institutional Review Board at the Cleveland Clinic. A Veress needle technique was used to create a pneumoperitoneum. A carbon dioxide pneumoperitoneum was established at a pressure of 15 mmHg. Four ports were placed in the right and left upper quadrants for laparoscopic Roux-en-Y gastric bypass (LRYGB). For single-incision laparoscopic sleeve gastrectomy (SILSG), three ports were inserted through the umbilicus. The Endolift™ device, which consists of a telescopic bar and two articulated clips on

either end of the bar, was introduced into the abdomen through an existing 5 mm port with the applicator. After the exposure of the gastroesophageal junction with the help of a grasper, the distal clip was anchored to the peritoneum of the left diaphragmatic crus adjacent to the gastroesophageal junction (Fig. 1). The vessels supplying the diaphragm were spared when applying the device as a safety precaution. The applicator was used to grasp the proximal clip on the other end and moved it to the right side above the right liver lobe through or beneath the falciform ligament. In this process, the bar was used to lift up the left liver lobe (Fig. 2). When an adequate view of the lesser curvature, esophageal hiatus, and the angle of His was obtained, the clip was anchored to the peritoneum of the right anterior abdominal wall (Fig. 3). The device was repositioned for the desired exposure as needed during the procedure. At the end of the procedure, the device was detached and removed using the applicator.

Results

From April 2011 to April 2012, laparoscopic bariatric procedures using Endolift™ were successfully performed on 33 patients. There was no need to resort to conventional liver retraction due to inadequate visualization or technical difficulties. The procedures performed included 31 LRYGB (2 revisions from adjustable gastric banding) and 2 SILSG. The patients were 24 females and 9 males with a mean age of 46 (25–65) and a mean body mass index of 45.0 kg/m² (33.6–56.1 kg/m²). With regard to obesity-related diseases, 12 patients had type 2 diabetes (36.4 %), 18 had hypertension (54.5 %), 12 had dyslipidemia (36.4 %), and 7 had nonalcoholic steatohepatitis (21.2 %). The mean operative time was

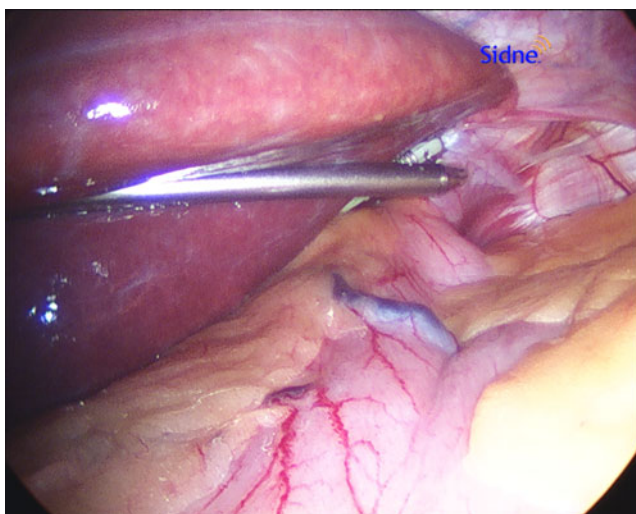


Fig 1 Placement of internal liver retractor at the angle of His. With the help of a grasper, the clip on the end of device is anchored to the peritoneum of the left diaphragmatic crus by the applicator

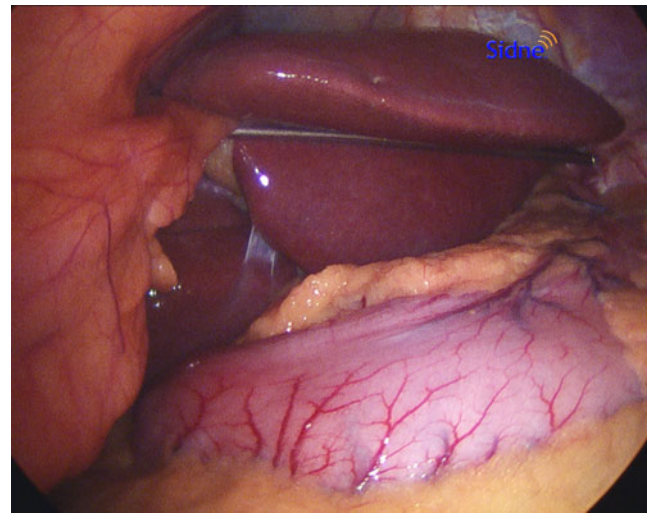


Fig 2 Exposure of the dorso-lateral portion of left liver lobe

136.5 min (77–231 min). The time required for the placement of Endolift™ was 1–3 min. In all patients, the device provided adequate visualization for completing the bariatric procedure. The application technique was reproducible and the repositioning of the device was easily performed when necessary. No device-related complications were observed perioperatively. The excess weight loss was 19.3 % (8.5–25.8 %) at the 1-month follow-up and 34.8 % (16.6–50.2 %) at the 3-month follow-up. One case of gastrojejunal stricture required balloon dilatation after LRYGB.

Discussion

In laparoscopic upper abdominal surgery, the lateral lobe of the liver restricts the range of vision. Since hypertrophic fatty liver is a common finding in obese patients, the safety and

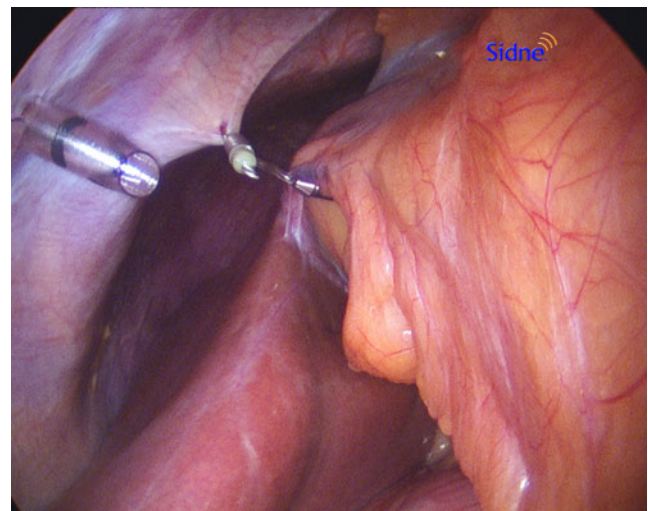


Fig 3 Fixation of the clip on the other end of device to the right side peritoneum above the right liver lobe beneath the falciform ligament

accuracy of laparoscopic bariatric surgery depends on adequate retraction of the left liver lobe. The conventional mechanical liver retractors have been used as part of the standard method of obtaining an adequate range of vision for laparoscopic upper gastrointestinal and bariatric surgery [11]. However, these techniques require an additional subxiphoid or right flank port and carry potential disadvantages such as postoperative pain, port-related complications, and iatrogenic liver injuries [1–4]. They also require a mounting device to limit the patient's position and add clutter to the operating table.

In recent years, because of the increasing attention paid to aesthetic outcomes after laparoscopic surgery and new developments in the field of minimally invasive surgery, bariatric surgeons face the challenge of exposing the lesser and greater curvatures of the stomach and the area around the esophageal hiatus through smaller incisions and fewer ports. A variety of liver retraction techniques not requiring a dedicated port and assistant have been described in the literature [5–19]. The methods and characteristics of these techniques are summarized in Table 1. The authors have reported that their liver-lifting methods allowed adequate exposure of the laparoscopic surgical field to complete the procedures. However, some disadvantages of the methods are the need for incision of the liver ligament, liver puncture, or abdominal wall/skin puncture. The incision of the coronary ligament of the left liver lobe adds to increased operative time and risk especially when a fatty and hypertrophic left lobe obstructs the field of view and increases technical difficulty. The liver puncture method apparently poses a higher risk of bleeding, while maneuvering a straight needle in and out of the abdominal cavity is technically challenging in obese patients who limit working space and have an abnormally enlarged liver. This method involves more trauma to the liver compared with the liver suspension technique even though the trauma is clinically insignificant [18]. Since the liver is a vital organ responsible for the synthesis and metabolism of essential body proteins, minimizing liver dysfunction caused by liver retraction is important during the early postoperative period [16]. The puncture of the abdominal wall is associated with a higher risk of bleeding and poses a technical challenge in obese patients due to a thicker abdominal wall. This method also involves an additional stab wound to the skin, which might leave a scar or cause pain. The above-described techniques are not easy to perform in bariatric patients and the process of repositioning the left liver lobe is difficult to reproduce because of the exteriorized sutures and additional time required for the set up. Hence, these methods have not become widespread due to the associated technical challenges and limitations in patients with an increased BMI and a heavy left liver lobe.

The device we used for retraction of the liver in laparoscopic bariatric surgery is remarkable for the fact that it can be used entirely intracorporeally. It does not require a separate skin incision, puncturing the liver and abdominal wall, an additional port, or anchoring to any external device that limits the patient's position and adds clutter to the operating field and table. Technically, the application is simple, and employs a reusable applier, which is available in two sizes to accommodate the bariatric patient. If necessary, the device can be easily repositioned during the operation to optimize retraction. The clips on both ends were minimally traumatic, left only slightly visible marks on the peritoneal wall, and held the peritoneum in place tightly enough to suspend even the bulky left lobes. There was no slipping or sliding of the device. In all cases, a single application of the device was sufficient to create an adequate field of view. The device was easy to use, and the time required for an application decreased to 1–3 min after three trials. We performed two single-incision laparoscopic sleeve gastrectomies with Endolift™ and found using the device in single-incision surgery to be as easy, safe, and effective as a laparoscopic bariatric procedure with four ports. We believe that this completely intracorporeal technique offers a clear advantage over the other techniques for single-incision and reduced port laparoscopic surgery because it leaves virtually no scar and requires only one wound for liver retraction. The device was inserted through a 5-mm port in the umbilicus and easily anchored the peritoneum in preparation for lifting the left liver lobe. The use of Endolift™ does increase the cost of the procedure, but this disadvantage is offset by the ease and safety of the liver retraction and the potential benefits of the technique in single-incision and reduced port laparoscopic procedures. A complete description of the intracorporeal techniques for liver retraction has been reported by Galvani et al. and Huang et al. [7, 11]. Galvani et al. [7] developed an internal retractor by securing a hook to a laparoscopic bulldog clamp. This technique appears to be easy and reproducible but requires a 10 mm port for insertion and may need to be performed a second time in patients with an enlarged left liver lobe. Huang et al. [11] developed a V-shaped liver suspension technique by using a Penrose drain and laparoscopic stapler. This technique is more surgeon-dependent in bariatric cases because of the weight of the hypertrophic liver and the technical challenges posed by limited working space.

The new liver retraction techniques that do not require an extra port have been discussed for the past 5 years. Many of these techniques are not in standard use because of the lack of availability of the device and technical issues associated with its use. By comparison Endolift™ is safe and easy to use with no added risk, involving few learning steps and providing an effective alternative to conventional mechanical liver retractors for creating an adequate laparoscopic field of vision.

Table 1 Summary of liver retraction techniques

Author	Year	Method	Incision of liver ligament	Liver puncture	Abdominal wall and skin puncture	Procedure time	Type of laparoscopic surgery
Lee	2007	Straight needle, suture, gauze	No	Yes	Yes	NA	Gastric surgery
Sakaguchi	2008	Penrose drain, J-shaped retractor, suture, suture passer	Yes	No	Yes	<10 min	NA
Saber	2008	Nathanson liver retractor	No	No	Yes	NA	Single-incision sleeve gastrectomy
Huang	2009	Jackson-Pratt drain, suture, straight needle	No	Yes	Yes	5 min	Single-incision transumbilical Roux-en-Y gastric bypass
de la Torre	2009	Suture, suture passer	No	No	Yes	NA	Transumbilical single port adjustable gastric band
Galvani	2010	Lone star retractor hook, bulldog clamp	No	No	No	NA	Single-incision sleeve gastrectomy
Hamzaoglu	2010	Penrose drain, suture, suture passer	Yes	No	Yes	5–7 min	Transumbilical totally single port Nissen fundoplication
Shabbir	2010	Gauze, suture, suture passer	No	No	Yes	NA	Total gastrectomy
Huang	2011	Penrose drain, stapler	No	No	No	8 min 21 s	Gastric bypass, sleeve gastrectomy, and single-incision transumbilical bariatric surgery
Takemura	2011	Silicone disk, suture, suture passer	Yes	No	Yes	NA	Gastrectomy, gastropasty, and fundoplication
Woo	2011	Gauze, suture, straight needle	No	No	Yes	8.5+ to 3.1 min	Radical gastrectomy with or without robot
Shinohara	2011	Penrose, suture, suture passer	Yes	No	Yes	NA	Gastrectomy
Gianni	2012	Veress needle, naso-gastric tube	No	No	Yes	1 min	Single-incision gastric surgery
Yilmaz	2012	Straight needle, suture	Yes	No	Yes	NA	Single-incision Nissen fundoplication
Fan	2013	Cyanoacrylate glue	Yes	No	No	NA	Transumbilical single-incision fundoplication
Shimizu	2013	Endolift, applier	No	No	No	1–3 min	Gastric bypass, sleeve gastrectomy, single-incision sleeve gastrectomy

Conclusion

Endolift™, an internal liver-lifting device for laparoscopic bariatric procedures, is safe and easy to use and provides advantages over conventional methods in single-incision and reduced port laparoscopic surgery.

Disclosures Drs. Hideharu Shimizu, Esam Batayyah, and Tomasz Rogula have no conflicts of interest or financial ties to disclose.

Funding None.

References

1. Firoozmand E, Ritter M, Cohen R, et al. Ventricular laceration and cardiac tamponade during laparoscopic Nissen fundoplication. *Surg Laparosc Endosc.* 1996;6:394–7.
2. Kinjo Y, Okabe H, Obama K, et al. Elevation of liver function tests after laparoscopic gastrectomy using a Nathanson liver retractor. *World J Surg.* 2011;35:2730–8.
3. Pasenau J, Mamazza J, Schlachta CM, et al. Liver hematoma after laparoscopic Nissen fundoplication: a case report and review of retraction injuries. *Surg Laparosc Endosc Percutaneous Tech.* 2000;10:178–81.
4. Yassa NA, Peters JH. CT of focal hepatic injury due to surgical retractor. *AJR Am J Roentgenol.* 1996;166:599–602.
5. de la Torre RA, Satgunam S, Morales MP, et al. Transumbilical single-port laparoscopic adjustable gastric band placement with liver suture retractor. *Obes Surg.* 2009;19:1707–10.
6. Fan Y, Wu SD, Kong J, Su Y, Tian Y. Transumbilical single-incision laparoscopic fundoplication: a new technique for liver retraction using cyanoacrylate. *Journal of laparoendoscopic & advanced surgical techniques Part A;* 2013.
7. Galvani CA, Choh M, Gorodner MV. Single-incision sleeve gastrectomy using a novel technique for liver retraction. *JSLs: J Soc Laparoendosc Surg Soc Laparoendosc Surgeons.* 2010;14:228–33.
8. Gianni S, De Luca M, Oscar B, et al. Veress needle: a simple liver retraction technique for lap band positioning in (single incision laparoscopic technique) SILS. *Obes Surg.* 2012;22:190–1.
9. Hamzaoglu I, Karahasanoglu T, Aytac E, et al. Transumbilical totally laparoscopic single-port Nissen fundoplication: a new method of liver retraction: the Istanbul technique. *J Gastrointest Surg: official journal of the Society for Surgery of the Alimentary Tract.* 2010;14:1035–9.
10. Huang CK, Houg JY, Chiang CJ, et al. Single incision transumbilical laparoscopic Roux-en-Y gastric bypass: a first case report. *Obes Surg.* 2009;19:1711–5.
11. Huang CK, Lo CH, Asim S, et al. A novel technique for liver retraction in laparoscopic bariatric surgery. *Obes Surg.* 2011;21:676–9.
12. Lee JH, Ryu KW, Doh YW, et al. Liver lift: a simple suture technique for liver retraction during laparoscopic gastric surgery. *J Surg Oncol.* 2007;95:83–5.
13. Saber AA, Elgamel MH, Itawi EA, et al. Single incision laparoscopic sleeve gastrectomy (SILS): a novel technique. *Obes Surg.* 2008;18:1338–42.
14. Sakaguchi Y, Ikeda O, Toh Y, et al. New technique for the retraction of the liver in laparoscopic gastrectomy. *Surg Endosc.* 2008;22:2532–4.
15. Shabbir A, Lee JH, Lee MS, et al. Combined suture retraction of the falciform ligament and the left lobe of the liver during laparoscopic total gastrectomy. *Surg Endosc.* 2010;24:3237–40.
16. Shinohara T, Kanaya S, Yoshimura F, et al. A protective technique for retraction of the liver during laparoscopic gastrectomy for gastric adenocarcinoma: using a Penrose drain. *J Gastrointest Surg: official journal of the Society for Surgery of the Alimentary Tract.* 2011;15:1043–8.
17. Takemura M, Ikebe T, Mayumi K, et al. A novel liver retraction technique for lateral lobe of the liver during laparoscopic surgery using silicone disk. *J Laparoendosc Adv Surg tech Part A.* 2011;21:729–32.
18. Woo Y, Hyung WJ, Kim HI, et al. Minimizing hepatic trauma with a novel liver retraction method: a simple liver suspension using gauze suture. *Surg Endosc.* 2011;25:3939–45.
19. Yilmaz H, Alptekin H. Single-port laparoscopic Nissen fundoplication: a new method for retraction of the left lobe of the liver. *Surg laparosc endosc percutaneous tech.* 2012;22:e265–6.