

Obere Extremität 2020 · 15:289–294

<https://doi.org/10.1007/s11678-020-00603-y>

Received: 4 June 2020

Accepted: 2 September 2020

Published online: 2 October 2020

© The Author(s) 2020



Nadine Ott¹ · Roger Van Riet² · Michael Hackl¹ · Kilian Wegmann¹ ·
Lars Peter Müller¹ · Tim Leschinger¹

¹ Department of Trauma, Hand and Elbow Surgery, University Hospital of Cologne, Cologne, Germany

² Division of Orthopedic and Elbow Surgery, University of Antwerp, Antwerp, Belgium

Medial epicondylopathy— microtrauma and pathologic overuse as a cause of degeneration of the flexor tendons

Background

Epicondylopathy humeri ulnaris (EHU, “Golfer’s elbow”) is a common clinical condition in everyday clinical practice, which often severely restricts the quality of life and the everyday professional life of patients [31]. The term “epicondylitis” has been increasingly abandoned in recent times because inflammation cannot be regarded as the cause. Rather, studies have shown that microtrauma and overload lead to degenerative changes at the origin of the flexor tendons (“common flexor origin,” CFO; [4, 7, 30]). As a result, the tendon is restructured, which often leads to tendon failure and to instability of the elbow joint as a final consequence [15, 19]. Hence, the term “epicondylitis” is more commonly used in clinical practice. The affected tendons are the pronator teres, flexor carpi radialis, palmaris longus, flexor digitorum superficialis, and the flexor carpi ulnaris muscle (▣ Fig. 1).

The term “golfers’ elbow” is frequently used because hitting the ball increases the valgus stress on the medial condyle [16]. An incidence of 1–3% has been described in epidemiological studies, with an occurrence more often on the lateral or radial side [18, 24]. The relevance of epicondylitis results from an often-inconsistent therapy concept.

Being overweight, of moderate age (especially 40–60 years), nicotine abuse, increased effort, and repetitive/stereotyped movements of the corresponding muscle groups for at least 2 h a day are predictors for the occurrence of epicondylitis [4, 7, 21]. It is not uncommon for patient-specific factors such as accompanying neck pain, depressive episodes, symptom duration over 3 months, or specific physical occupational and, for example, one-sided manual activities to correlate with a poorer prognosis for the patient [7, 18]. The often-inconsistent therapy concepts are commonly based on the lack of uniform classification of the EHU. The distinction between an acute and a chronic form is certainly to be considered sen-

sible. According to the duration of the symptoms, the EHU can be divided into an acute (<6 months) and a chronic form (>6 months).

Diagnosis

In the anamnesis the patients commonly report pain in the area of the medial epicondyle, which usually radiates into the forearm. Trauma has often preceded this, which can be understood as a trigger. Patients describe increased and stereotypical, repetitive movements in leisure time

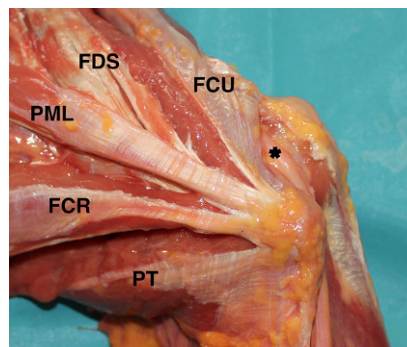


Fig. 1 ▲ Common flexor origin (CFO), pronator teres (PT), flexor carpi radialis (FCR), palmaris longus (PML), flexor digitorum superficialis (FDS), flexor carpi ulnaris (FCU) with the ulnar nerve (black asterisk)

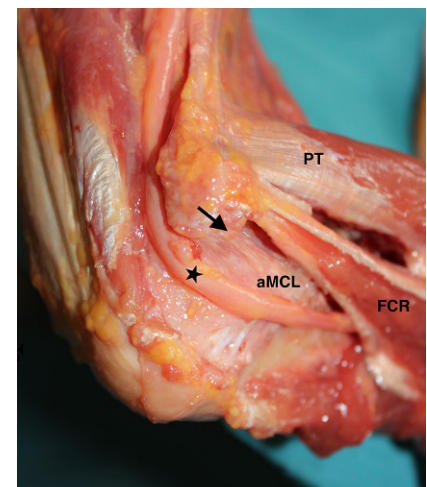


Fig. 2 ▲ Close relationship of common flexor origin due to the ulnar nerve (black star) and Lig. collaterale ulnare anterior (aMCL); pronator teres (PT), flexor carpi radialis (FCR)

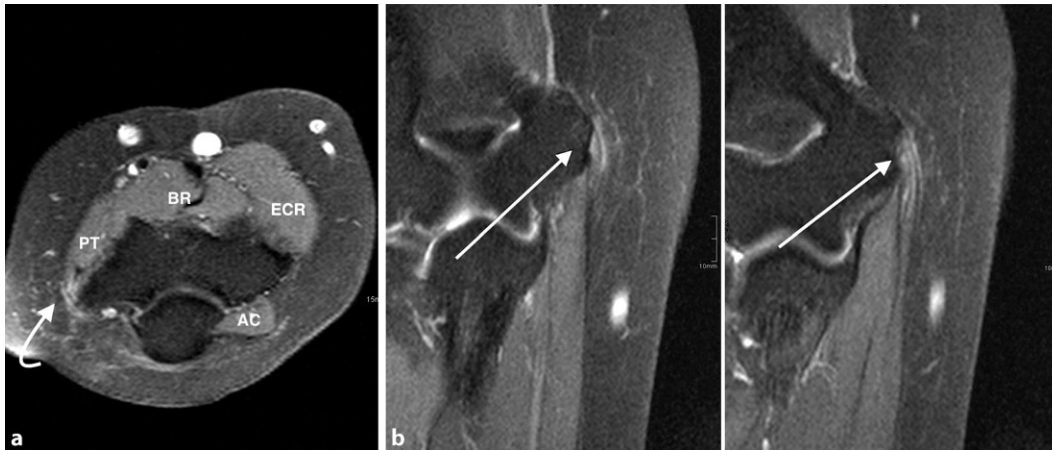


Fig. 3 ◀ magnetic resonance imaging of epicondylitis in axial (a) and coronary view (b). T1- and T2-weighted scans show signal difference in the area of the flexor tendons (white arrows); no sign of accompanying lesions of the medial collateral ligament or incongruency of the joint; pronator teres (PT), brachialis (BR), extensor carpi radialis (ECR), anconeus (AC)

and at work. In the course of the medical history, previous injuries and previous treatments should be queried. Previous trauma can often be seen as the trigger.

Clinical examination

The clinical examination usually focuses on a typical pain pattern. The range of motion of the affected elbow joint should be documented according to the neutral-zero method in relation to the opposite side. Often, however, the range of motion can be assessed as unrestricted. In addition to provoking pain during final movements, local pressure, stretching, and tension pain above the origin of the flexors are to be rated as typical. Various tests are available for assessment, for example, the Reversed Cozen Test. Weakness of the arm is often described in the context of chronic epicondylitis. Therefore, the detection of peripheral blood circulation, motor skills, and sensitivity are of great importance. Accompanying symptoms of the ulnar nerve are not uncommon (■ Fig. 2). A positive Tinel sign can indicate compression of the ulnar nerve. If there is a clinical indication of an accompanying neurogenic pathology, a neurophysiological examination including electroneurography/electromyography should be sought. Also, the stability of the elbow joint should be checked [28]. In particular, overhead athletes must be examined for valgus instability by applying valgus stress to the elbow in 30° of flexion, with the forearm pronated and the wrist flexed

or by use of stress tests (e.g., the milking test; [3]). Possible differential diagnoses should be excluded. Therefore, an examination of the adjacent joints and the cervical spine is strongly recommended.

Imaging diagnostics

As part of the initial presentation, conventional radiological diagnosis of the elbow joint should be aimed for. In addition to free joint bodies or joint mismatches, visible arthritic changes and calcifications can be assessed.

Sonography has established itself for the assessment of tendinopathy. In addition to low-echo changes, hypervascularization in the tendon insertion of the flexor group may also be visible. Moreover, the evaluation of changes of the ulnar nerve could be possible. Park et al. showed that ultrasonography performed by a radiologist had sensitivity, specificity, and positive and negative predictive values of >90% for the diagnosis of medial epicondylitis [20]. A dynamic examination may improve sensitivity and specificity [14]. Hence, the diagnostic accuracy depends greatly on the operator.

Thus, magnetic resonance imaging (MRI) diagnostics should be used as the standard imaging tool. Especially in chronic epicondylitis, it should be the diagnostic tool of choice. To assess accompanying or even consecutive instability, MRI should be performed in supination and extension (■ Fig. 3; [30]). On T2-weighted sequences, intermediate-to-high signal intensity at the

common origin of the flexor tendons is typically indicative of medial epicondylitis [12]. Hence, in 50% of asymptomatic patients, edema of the CFO could be detected. Thus, it may be that CFO changes on the MRI do not correlate with the clinical symptoms of the patient [22].

Therapy

Various nonsurgical and surgical treatment options are available to manage medial epicondylitis. The initial focus of acute supportive care is to relieve the pain, rehabilitate the pathologic tendon, and prevent recurrence.

Conservative therapy

Initially, conservative therapy is the treatment of choice as complete remission can be observed in approximately 90% of cases within the first 12 months [4]. Patients should be informed about the high probability of a complete remission of the symptoms. However, structural damage of the tendon should be excluded.

In addition to the modification of repetitive stress, the spectrum of conservative therapy consists in physiotherapeutic exercise treatment, manual therapy, as well as massage therapy and anti-inflammatory oral and topical therapy. Injections with cortisone, platelet-rich plasma (PRP), or botulinum toxin are the subject of ongoing discussion. Especially at the beginning of treatment, stress adjustment should be the focus of therapy. Therefore, the professional and

social history of the patient is essential to be able to adjust the repetitive overload. In particular, athletes with concomitant lateral ulnar collateral ligament (LUCL) injury should avoid valgus stress during the first week of the treatment. Acute pain and swelling can be treated with ice and nonsteroidal anti-inflammatory drugs [4, 11]. In the area of physiotherapeutic exercise treatment, manual therapy and friction treatment can support training therapy, but should not be understood as the only treatment [8–10]. In baseball pitchers with medial epicondylitis, pain relief by using the forearm kinesiology taping technique was demonstrated [5].

Injections of cortisone should be used cautiously. Although a corticosteroid injection is able to relieve medial elbow pain in the short term, multiple injections of cortisone are no longer recommended. Cortisone could induce changes of the tendon and produce necrosis of the fatty tissue [6]. In spite of the reliable clinical outcome in the short term, the mid- and long-term effects are debated [17]. Stahl and Kaufmann reported an acute improvement over the first 6 weeks, but no difference after 3 months [25]. Lee et al. found acute improvement in pain scores over the first 2 weeks followed by a plateau [14]. Hence, repetitive injections can also lead to a lesion of the flexors with consecutive, secondary instability. Moreover, injections should be performed carefully due to the close relationship to the ulnar nerve [25, 26]. In the end, there is insufficient scientific evidence regarding the results after use and application/injection. Also, injections with botulinum toxin have shown a reliable short-term effect [6]. Injections of PRP injection are more common for lateral epicondylitis. According to the study by Suresh et al., a combined needle stimulation and injection of PRP resulted in decreased scores on the visual analog scale. Most of the patients (20 out of 26) had two autologous blood (2 ml) injections combined with 2 ml of bupivacaine [27]. Based on the literature findings, an influence of the duration of symptoms on the effect of the injection could not be evaluated. Therefore, for an early injection, there are no data in the litera-

Obere Extremität 2020 · 15:289–294 <https://doi.org/10.1007/s11678-020-00603-y>
© The Author(s) 2020

N. Ott · R. Van Riet · M. Hackl · K. Wegmann · L. P. Müller · T. Leschinger

Medial epicondylopathy—microtrauma and pathologic overuse as a cause of degeneration of the flexor tendons

Abstract

Background. Medial epicondylitis is a common orthopedic condition that typically results from overuse or previous microtrauma of the flexor-pronator mass. Repetitive eccentric loading of the muscles leads to subsequent degeneration of the flexor tendons.

Diagnosis. Patients present with a painful elbow. In the case of concomitant elbow pathologies, including ulnar neuritis and ulnar collateral ligament injury, there should be a detailed examination. Generally, the diagnosis is based on the clinical examination. T2-weighted magnetic resonance imaging

can be useful for chronic courses, over 6 months.

Treatment. Nonsurgical management is the mainstay of treatment. Hence, surgical treatment may be indicated for patients with persistent symptoms after conservative treatment. In the case of a surgical treatment, arthroscopy can be useful to capture concomitant elbow pathologies.

Keywords

Medial epicondylitis · Microtrauma · Flexor-pronator mass · Ulnar collateral ligament injury · Ulnar neuritis

Mediale Epikondylopathie – Mikrotraumata und pathologische Überlastungen als Ursache degenerativer Veränderungen des Flexorenursprungs

Zusammenfassung

Hintergrund. Die mediale Epikondylitis ist ein häufiges orthopädisches Krankheitsbild, das typischerweise durch Mikrotraumata und pathologische Überlastungen des Flexorenursprungs verursacht wird. Die wiederholte exzentrische Belastung der Muskeln führt schließlich zur Degeneration des Beugersehnen. Neben der Einschränkung der Lebensqualität der Patienten ist die berufliche Aktivität meist nicht mehr uneingeschränkt ausführbar.

Diagnostik. Im Vordergrund steht meist ein schmerzhafter Ellenbogen, nicht selten liegt bereits eine sekundäre Instabilität vor. Begleitende Ellenbogenerkrankungen einschließlich einer Ulnarneuritis und einer Läsion des ulnaren Kollateralbands erfordern eine genaue Untersuchung. Die Diagnose ist primär klinisch zu stellen, bei chronischen Verläufen >6 Monaten sollte immer eine T2-

gewichtete magnetresonanztomographische Diagnostik angestrebt werden.

Therapie. Aufgrund der hohen Rate an spontane Remissionen innerhalb der ersten 12 Monate ist die primäre konservative Therapie der Goldstandard. Die konservative Therapie ist als ein multimodales Therapiekonzept zu betrachten. Die operative Therapie sollte streng indiziert sein und nur chronischen Verläufen mit Beschwerdepersistenz nach Ausschöpfung aller konservativen Maßnahmen vorbehalten sein. Im Rahmen einer operativen Therapie kann eine diagnostische Arthroskopie hilfreich sein, um intraartikuläre Begleitpathologie oder eine sekundäre Instabilität zu erfassen.

Schlüsselwörter

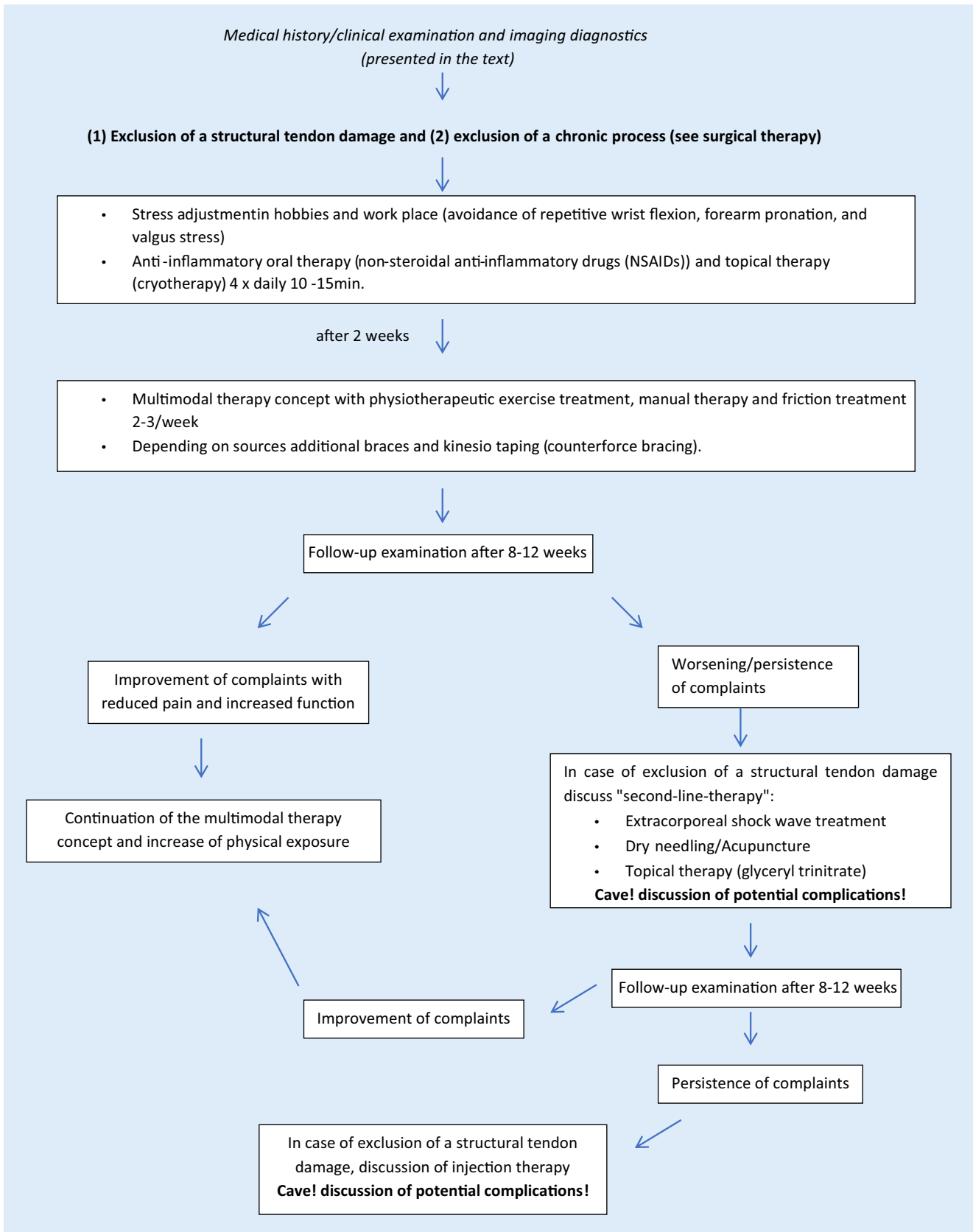
Mediale Epikondylitis · Mikrotrauma · Flexorenursprung · Läsion des ulnaren Kollateralbands · Ulnarneuritis

ture to date to support this recommendation. Electrical and ultrasound therapy and extracorporeal shock wave treatment (ESWT) may promote pain relief. Lee et al. reported worse clinical pain scores at 1 and 2 weeks with EWTS, but better patient satisfaction at 8 weeks [14]. A good or excellent clinical outcome at 1-year-follow-up was observed by Krischek et al.

[13, 23]. An overview of a possible conservative therapy algorithm is presented in **Fig. 4**.

Surgical therapy

The indication for surgical therapy should be strictly limited. Only after exhausting all conservative measures should



↙

Improvement of complaints

↘

↙

Improvement of complaints with reduced pain and increased function

↘

Fig. 4 ▲ Overview of conservative therapy

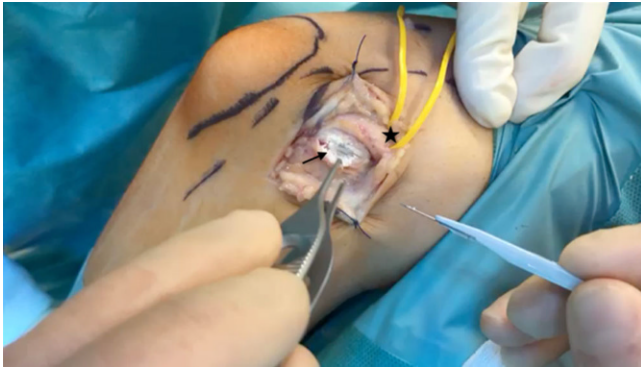

Fig. 5 ◀ Medial view with the ulnar nerve (*black star*). After incision of the flexor tendons, a type of calcine tissue becomes visible

patients with persistent symptoms over 9–12 months and structurally–morphologically proven damage be considered. The good clinical results after operative therapy should be discussed in terms of spontaneous complaint remission and possible intraoperative complications. Therefore, detailed patient information is essential. Based on the available literature, no uniform superiority of one of the methods could be demonstrated, so that compared with lateral epicondylitis no uniform recommendation is possible. Moreover, there are only a few studies dealing with the postoperative follow-up after a surgical therapy for medial epicondylitis. Vangsnæs et al. observed in 88% of patients a reliable clinical outcome after 6 years. Frequently used open procedures are the so-called classic Hohmann operation, as a crescent-shaped release of the flexors, including the degenerative tissue from the medial epicondyle [29]. The “Wilhelm operation” with denervation of nerve structures at the medial epicondyle, and the “operation after Nirschl” [18], in which the flexor group is incised lengthways and the degenerative tissue is subjected to debridement—without detachment of the origins—are further surgical treatment options (■ Fig. 5).

In addition to the open procedures, percutaneous or arthroscopic surgical techniques according to the lateral epicondylitis are the subject of debate [1, 2]. However, arthroscopy in medial epicondylitis is currently of only minor importance due to the close relationship to the ulnar nerve. For lateral epicondylitis, several recent studies have recommended arthroscopy for assessing intra-articular pathologies; for the me-

dial side there are not data so far that support this recommendation. Nonetheless, arthroscopy for assessing hidden instability or intra-articular pathologies should not be underestimated. For this reason, prior diagnostic arthroscopy, especially in the case of chronic illnesses, is often recommended to ensure that the treatment is appropriate for the cause. Taking the clinical symptoms and the MRI findings into account, a holistic operative therapy concept can be considered one or two times. It is not uncommon for diagnostic arthroscopy to show a relevant instability, which can then be treated with additive stabilization (reinsertion/gathering/internal bracing of the LCL/MCL complex or lateral ulnar collateral ligament/medial collateral ligament [LUCL/MCL] plastic). However, most of the patients are in their 5th–6th decade of life and a ligament reconstruction is not indicated for every mild instability. Thus, the indication for surgical therapy should be strictly limited.

Practical conclusion

- Medial epicondylitis is a result of degenerative changes in the origin of the flexor based on microtrauma and pathological overload.
- Any accompanying instability should be checked during the clinical examination.
- In approximately 90% of cases, there is a spontaneous remission of symptoms within the first 12 months.
- The primary therapy of choice is conservative. The available therapy options should be understood as a multimodal therapy concept.

- Stress adjustment is a critical factor in primary treatment.
- The indication for operative therapy should be strictly limited and only reserved for chronic courses with complaint persistence despite exhausting all conservative measures.
- Above all, diagnostic arthroscopy has a role in a causal operative therapy concept.

Corresponding address

Nadine Ott

Department of Trauma, Hand and Elbow Surgery, University Hospital of Cologne
Kerpener Straße 62, 50937 Cologne, Germany
Nadine.ott@uk-koeln.de

Funding. Open Access funding provided by Projekt DEAL.

Compliance with ethical guidelines

Conflict of interest. N. Ott, R. Van Riet, M. Hackl, K. Wegmann, L.P. Müller and T. Leschinger declare that they have no competing interests.

For this article no studies with human participants or animals were performed by any of the authors. All studies performed were in accordance with the ethical standards indicated in each case.

Open Access. This article is licensed under a Creative Commons Attribution 4.0 International License, which permits use, sharing, adaptation, distribution and reproduction in any medium or format, as long as you give appropriate credit to the original author(s) and the source, provide a link to the Creative Commons licence, and indicate if changes were made. The images or other third party material in this article are included in the article's Creative Commons licence, unless indicated otherwise in a credit line to the material. If material is not included in the article's Creative Commons licence and your intended use is not permitted by statutory regulation or exceeds the permitted use, you will need to obtain permission directly from the copyright holder. To view a copy of this licence, visit <http://creativecommons.org/licenses/by/4.0/>.

References

1. Baumgard SH, Schwartz DR (1982) Percutaneous release of the epicondylar muscles for humeral epicondylitis. *Am J Sports Med* 10(4):233–236
2. Burn MB, Mitchell RJ, Liberman SR, Lintner DM, Harris JD, McCulloch PC (2017) Open, arthroscopic, and percutaneous surgical treatment of lateral epicondylitis: a systematic review. *Hand*. <https://doi.org/10.1177/1558944717701244>

3. Cain EL Jr, Dugas JR, Wolf RS, Andrews JR (2003) Elbow injuries in throwing athletes: a current concepts review. *Am J Sports Med* 31(4):621–635
4. Ciccotti MG, Ramani MN (2003) Medial epicondylitis. *Tech Hand Up Extrem Surg* 7(4):190–196
5. Chang HY, Wang CH, Chou KY, Cheng SC (2012) Could forearm kinesio taping improve strength, force sense, and pain in baseball pitchers with medial epicondylitis? *Clin J Sport Med* 22(4):327–333
6. Coombes BK, Bisset L, Vicenzino B (2010) Efficacy and safety of corticosteroid injections and other injections for management of tendinopathy: a systematic review. *Lancet* 376(9754):1751–1767
7. Descatha A, Leclerc A, Chastang JF, Roquelaure Y (2003) Study group on repetitive work: medial epicondylitis in occupational settings: prevalence, incidence and associated risk factors. *J Occup Environ Med* 45(9):993–1001
8. Dingemans R, Randsdorp M, Koes BW, Huisstede BM (2014) Evidence for the effectiveness of electrophysical modalities for treatment of medial and lateral epicondylitis: a systematic review. *Br J Sports Med* 48:957–965. <https://doi.org/10.1136/bjsports-2012-091513>
9. Galloway M, DeMaio M, Mangine R (1992) Rehabilitative techniques in the treatment of medial and lateral epicondylitis. *Orthopedics* 15(9):1089–1096
10. Hoogvliet P, Randsdorp MS, Dingemans R, Koes BW, Huisstede BM (2013) Does effectiveness of exercise therapy and mobilisation techniques offer guidance for the treatment of lateral and medial epicondylitis? A systematic review. *Br J Sports Med* 47(17):1112–1119
11. Hubbard TJ, Denegar CR (2004) Does Cryotherapy Improve Outcomes with Soft Tissue Injury? *J Athl Train* 39:278–279
12. Kijowski R, De Smet AA (2005) Magnetic resonance imaging findings in patients with medial epicondylitis. *Skelet Radiol* 34(4):196–202
13. Krischek O, Hopf C, Nafe B, Rompe JD (1999) Shock-wave therapy for tennis and golfer's elbow: 1 year follow-up. *Arch Orthop Trauma Surg* 119(1–2):62–66
14. Lee SS, Kang S, Park NK et al (2012) Effectiveness of initial extracorporeal shock wave therapy on the newly diagnosed lateral or medial epicondylitis. *Ann Rehabil Med* 36(5):681–687
15. Lin F, Kohli N, Perlmutter S, Lim D, Nuber GW, Makhsous M (2007) Muscle contribution to elbow joint valgus stability. *J Shoulder Elbow Surg* 16(6):795–802
16. McCarroll JR (1990) Evaluation, treatment and prevention of upper extremity injuries in golfers. In: *The upper extremity in sports medicine*. Mosby, St Louis, pp 883–889
17. Nirschl RP, Rodin DM, Ochiai DH, Maartmann-Moe C, DEX-AHE-01-99 Study Group (2003) Iontophoretic administration of dexamethasone sodium phosphate for acute epicondylitis: A randomized, double-blinded, placebo-controlled study. *Am J Sports Med* 31(2):189–195
18. Nirschl RP (1992) Elbow tendinosis/tennis elbow. *Clin Sports Med* 11:851–870
19. Otoshi K, Kikuchi S, Shishido H, Konno S (2014) The proximal origins of the flexor-pronator muscles and their role in the dynamic stabilization of the elbow joint: an anatomical study. *Surg Radiol Anat* 36(3):289–294
20. Park GY, Lee SM, Lee MY (2008) Diagnostic value of ultrasonography for clinical medial epicondylitis. *Arch Phys Med Rehabil* 89(4):738–742
21. Pienimäki T, Siira P, Vanharanta H (2011) Widespread pain in chronic epicondylitis. *Eur J Pain* 15(9):921–927
22. Savnik A, Jensen B, Norregard J et al (2004) MRI in the evaluation of treatment response of the lateral epicondylitis of the elbow. *Eur Radiol* 14(6):964–969
23. Sems A, Dimeff R, Iannotti JP (2006) Extracorporeal shock wave therapy in the treatment of chronic tendinopathies. *J Am Acad Orthop Surg* 14(4):195–204
24. Shiri R, Viikari-Juntura E, Varonen H, Heliövaara M (2006) Prevalence and determinants of lateral and medial epicondylitis: a population study. *Am J Epidemiol* 164(11):1065–1074
25. Stahl S, Kaufman T (1997) The efficacy of an injection of steroids for medial epicondylitis: a prospective study of sixty elbows. *J Bone Joint Surg Am* 79(11):1648–1652
26. Stahl S, Kaufman T (1997) Ulnar nerve injury at the elbow after steroid injection for medial epicondylitis. *J Hand Surg Br* 22(1):69–70
27. Suresh SP, Ali KE, Jones H, Connell DA (2006) Medial epicondylitis: is ultrasound guided autologous blood injection an effective treatment? *Br J Sports Med* 40(11):935–939 (discussion 939)
28. Udall JH, Fitzpatrick MJ, McGarry MH, Leba TB, Lee TQ (2009) Effects of flexor-pronator muscle loading on valgus stability of the elbow with an intact, stretched, and resected medial ulnar collateral ligament. *J Shoulder Elbow Surg* 18(5):773–778
29. Vangsnest CT Jr, Jobe FW (1991) Surgical treatment of medial epicondylitis: results in 35 elbows. *J Bone Joint Surg Br* 73(3):409–411
30. Walz DM, Newman JS, Konin GP, Ross G (2010) Epicondylitis: pathogenesis, imaging, and treatment. *Radiographics* 30(1):167–184
31. Wolf JM, Mountcastle S, Burks R, Sturdivant RX, Owens BD (2010) Epidemiology of lateral and medial epicondylitis in a military population. *Mil Med* 175(5):336–339